


RESEARCH ARTICLE

Correlation between C7–T1 Intervertebral Foramen Area and Sagittal Parameters in Patients with Cervical Spondylotic Myelopathy

Lilong Zhang, MM¹, Zijian Cui, MBBS¹ , Chen Yuan, BE², Xueli Zhang, MBBS¹, Zhishuai Ren, MM¹, Wei Wang, MM³, Ping Xia, MM⁴, Rusen Zhu, MM¹

Department of ¹Spine Surgery and ²Information, Tianjin Union Medical Center and ⁴Graduate School, Nankai University, Tianjin and ³Department of Spine Surgery, Minda Hospital Affiliated to Hubei University for Nationalities, Enshi, China

Objective: Cervical spondylotic myelopathy (CSM) is an incomplete spinal cord injury characterized with pain and stiffness in the neck and motor and sensory dysfunction. This study aims to determine whether C7–T1 intervertebral foramen area could be used as a parameter to evaluate the sagittal curvature of cervical spine.

Methods: Patients with clinical manifestations of spinal cord compression were hospitalized in our hospital from September 2018 to August 2019. All patients were diagnosed with CSM by nuclear magnetic imaging and other imaging methods. C2–C7 Cobb angle and T1 slop (T1S) were measured on the sagittal, T2-weighted magnetic resonance image of cervical spine, and C7–T1 intervertebral foramen area were measured using oblique cervical spine X-rays. Patients were divided into two groups according to the value of C2–C7 Cobb angle, including lordosis group (C2–C7 Cobb angle $>10^\circ$, $n = 45$) and straight group (C2–7 Cobb angle $\leq 10^\circ$, $n = 55$). The reliability of the data was evaluated by intraclass correlation coefficient (ICC), and the correlation of the imaging parameters was analyzed by Pearson correlation.

Results: A total of 100 patients diagnosed with CSM hospitalized in our department were included. The ICC of the cervical parameters was 0.73. C7–T1 intervertebral foramen area was 40.69 ± 11.44 and 39.95 ± 10.94 mm² in lordosis and straight group, respectively. The results showed that C7–T1 intervertebral foramen area was positively correlated with both C2–C7 Cobb angle ($r = 0.23$, $p = 0.02$) and T1S ($r = 0.21$, $p = 0.03$). In lordosis group, there was a positive correlation between C7 and T1 intervertebral foramen area and C2–C7 Cobb angle ($r = 0.69$, $p < 0.01$) and T1S ($r = 0.34$, $p = 0.02$). However, in straight group, C7–T1 intervertebral foramen area was not correlated with either C2–C7 Cobb angle or T1S.

Conclusion: C7–T1 intervertebral foramen area measured by oblique X-ray could be an effective method to evaluate the sagittal balance of cervical vertebrae for CSM patients with cervical lordosis.

Key words: Cervical sagittal parameters; Cervical spondylotic myelopathy; Correlation analysis; Intervertebral foramen area

Introduction

Cervical spondylotic myelopathy (CSM) is an incomplete spinal cord injury characterized with pain and stiffness in the neck and motor and sensory dysfunction. The prevalence of CSM in North America is about 605 per million

population and shows an increasing incidence with age, especially in those aged 50 years and above, although recently there has been an increase in the incidence of CSM in young people. Though current evidence indicates improved neurological function after surgery, symptom relief

Address for correspondence Zijian Cui and Rusen Zhu, Department of Spine Surgery, Tianjin Union Medical Center, No. 190 Jieyuan Road, Hongqiao District, Tianjin, China 300121 Tel: 86-022-27557184; Email: cui_zijian12@21cn.com; zrsspine@126.com
Received 29 March 2021; accepted 25 July 2022

is often dismal or worse in some patients. Neurological function recovery in CSM depends on spinal cord compression and injury and cerebral functional reorganization or plasticity.

Standard treatment of CSM often focuses on surgical decompression with an anterior or posterior approach. Disc degeneration has been recognized as the initiating event of spondylotic changes, which can lead to abnormal cervical spine biomechanics and loss of normal sagittal alignment. Abnormalities of the cervical sagittal alignment, in return, could contribute to spinal cord dysfunction through several mechanisms, including direct compression, repeated flexion/extension injury and vascular compromise. These findings highlight the importance of cervical sagittal alignment in the pathogenesis of CSM. A number of studies have analyzed the cervical sagittal parameters in normal volunteers, patients with idiopathic scoliosis, patients with ankylosing spondylitis and patients with cervical spondylolisthesis. The correlations among cervical lordosis (CL), C2–C7 sagittal vertical axis (C2–C7 SVA), T1 slope (T1S), neck tilt and thoracic inlet angle also present varied results among studies. The interrelations among the cervical sagittal parameters in CSM patients and their correlations with myelopathy have not been fully elucidated. One study on cervical sagittal balance in degenerative cervical spine suggests that T1S has a positive correlation with CL. Instead of kyphosis, worse C2–C7 SVA was found to be correlated with greater myelopathy severity. Degenerative changes associated with CSM can result in the loss of normal sagittal alignment, and the loss of CL may be the initial change of kyphosis and sagittal imbalance. Several studies suggest that cervical alignment contributes to the pathogenesis of cervical myelopathy in the CSM nature history. Preoperative alignment parameters have been demonstrated to predict clinical outcomes after cervical surgery.

The sagittal balance of spine is related to the prognosis and life quality of patients. The lack of sagittal balance increases the incidence of facet joint arthritis, the risk of adjacent segments degeneration, and the probability of postoperative complications.¹ Sagittal parameters are widely used as important indicators for evaluating sagittal balance, and can be a significant guidance for the diagnosis, treatment, and prognosis of non-deformed patients.² At present, X-ray films are mostly used for the observation of the sagittal parameters of cervical spine. Recently, studies have showed that the sagittal section of nuclear magnetic resonance can be a supplement to X-ray films,³ although with a smaller measurement at the supine position.^{4,5} Except for C2–C7 Cobb angle, a previous study has shown that T1S value measured by magnetic resonance imagery (MRI) can be used as the main parameter to evaluate the sagittal curvature of the cervical spine for CSM patients with CL.⁶ MRI can describe the alterations of the cervical spinal canal (CSC) and spinal cord completely. First, morphological changes of CSC can be described through anterior–posterior (a–p) diameter, area, and the Pavlov ratio of CSC. Second, MRI can find the reasons which lead to

cervical spinal canal stenosis, such as, congenital cervical spinal canal stenosis, intervertebral disc bulging or protrusion, hyperosteoegeny, ligament hypertrophy, etc. Third, pathologic changes of cervical spinal cord in gross structure can be reflected by MR signal changes. Long T1 long T2 signal region in cervical spinal cord represents tissue edema and short T1 long T2 signal region in cervical spinal cord represents tissue hemorrhage. Fourth, the microstructure of cervical spinal cord on molecular level also can be described by diffusion tensor imaging (DTI) parameters, such as trace value, fractional anisotropy (FA) value. There were lots of MR study on healthy or CSM volunteers. But the patients showing cervical spine degeneration on medical imaging without clinic symptoms were not mentioned, which was called latent cervical spondylosis (LCS). In this case, the parameters including Pavlov ratio, trace value and FA value of LCS were compared with healthy and CSM volunteers. At the same time, the correlation and clinical applications of the above parameters were also studied. However, these parameters have certain limitations. For example, for patients with obesity and unclear shoulder contours, the increased soft-tissue inhomogeneity is likely to occur from a greater and/or more variable amount of visceral fat surrounding the organs in overweight and obese patients, so that X-ray measurement is difficult to perform,⁷ and lateral radiograph of C7 vertebrae is unclear for many patients.⁸ The MRI measurement is not suitable for patients with metal prostheses. In addition, the MRI measurement is expensive and time-consuming. Therefore, it is necessary to find parameters, which are more suitable to evaluate the sagittal balance of cervical spine.

This study was aimed to evaluate the intervertebral foramen area. Especially, the C7–T1 intervertebral foramen area was evaluated. We aimed at determining whether C7–T1 intervertebral foramen area can be used as a parameter to evaluate the sagittal curvature of cervical vertebra in CSM patients.

Materials and Methods

Patients

Patients with clinical manifestations of spinal cord compression were hospitalized in our hospital from September 2018 to August 2019 were recruited. The included patients underwent the imaging examination.

Inclusion criteria: The patients were diagnosed with CSM, after confirming by nuclear magnetic imaging and other imaging methods according to previous study.⁹

Exclusion criteria: (i) patients with a history of cervical spine surgery and cervical spine injury; (ii) patients with altered spinal cord signals caused by spinal tuberculosis, spinal tumor, syringomyelia, sclerosing muscle atrophy and other causes; and (iii) Patients with congenital kyphosis and cervical kyphosis.

A total of 100 patients were included in this study. This study had been approved by the ethics committee of

our hospital and informed consent has been obtained from all patients prior to the study (No. 2021 [B35]).

Evaluation

MRI Examination

The patients were placed in a supine neutral position and the sagittal T1-weighted, T2-weighted, and cross-sectional T2-weighted scans of cervical spine were performed using a Philips Signa CV/i 3.0T MRI scanner (Philips, Amsterdam, the Netherlands). C2–C7 Cobb angle was measured on the sagittal T2 weighted MRI of cervical spine (the angle between C2 inferior endplate and C7 inferior endplate) and T1S (the angle between superior endplate of T1 and horizontal). The posterior oblique X-ray of cervical spine was taken for the same patient in standing position. The patient was facing the film, with the mandible extended forward, slightly raised, close to the film, and the coronal plane of the body was 60° away from the film. The coronal plane of the head was 45° from the film. The central line of the tube ball inclined to the foot side for 15°. At the lower edge of C3 vertebral body, the film center was injected. The focus distance was 180–200 cm. The exposure condition was 3–5 kv higher than the lateral position. The MAS remained unchanged and the breath was hold during the exposure.

X-ray Examination

X-ray (Philips, Amsterdam, the Netherlands) was set as tube voltage: 73–75 KV, tube current: 16 mAs. C7/T1 intervertebral foramen area was calculated using the MAS-1 system. Because the severity of cervical spondylosis symptoms is related to the size of the cervical intervertebral foramen area, the intervertebral foramen with more severe symptoms was selected. Two spine surgeons were included as overseers for this study. And the average values of the measurements were used.

The measured sagittal parameters of cervical spine included: (i) C2–C7 Cobb angle: the angle between C2 inferior endplate and C7 inferior endplate (Fig. 1A); (ii) T1S: the angle between superior endplate of T1 and horizontal (Fig. 1B); and (iii) C7–T1 intervertebral foramen area: area of the intervertebral foramen between inferior vertebral notch of C7 vertebrae and superior vertebral notch of T1 vertebrae (Fig. 2A–C). In the present study, C2–C7 Cobb angle and T1S were obtained by MRI measurements.

Statistical Analysis

Statistical analyses were performed using the SPSS 24.0 statistical software. The data were expressed as mean \pm standard deviation. The reliability of the data was evaluated by intraclass correlation coefficient (ICC). The correlation of the imaging parameters was analyzed by Pearson correlation. $P < 0.05$ was considered statistically significant.

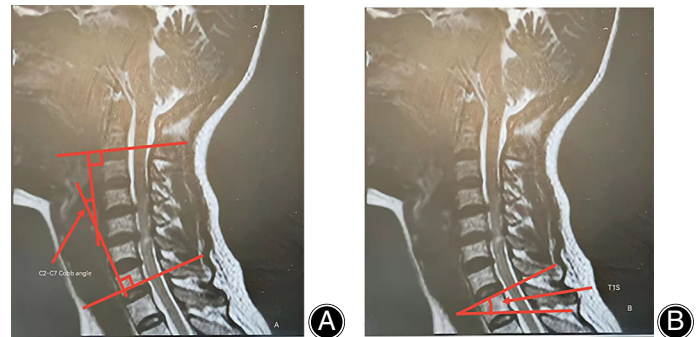


Fig. 1 The sagittal, T2-weighted magnetic resonance image of the cervical spine. (A) The measurement of the C2–C7 Cobb angle: the angle between the C2 inferior endplate and C7 inferior endplate. The measured sagittal parameters of cervical spine included: 1. C2–C7 Cobb angle: the angle between C2 inferior endplate and C7 inferior endplate; (B) The measurement of the T1S: the angle between the superior endplate of T1 and the horizontal. T1S: the angle between superior endplate of T1 and horizontal.

Results

Basic Characteristics

Patients were divided into two groups according to the value of C2–C7 Cobb angle, including lordosis group (C2–C7 Cobb angle $>10^\circ$, $n = 45$) and straight group (C2–C7 Cobb angle $\leq 10^\circ$, $n = 55$). The lordosis group included 26 males and 19 females, aged between 39 and 77, with an average age of 60.3 years. The straight group included 35 males and 20 females, aged between 35 and 81 with an average age of 58.1 years.

Association between C7–T1 Intervertebral Foramen Area and Sagittal Curvature

The ICC of the sagittal parameters was 0.73. In lordosis group, C2–C7 Cobb angle was $19.07 \pm 6.98^\circ$, C7/T1 intervertebral foramen area was $40.69 \pm 11.44 \text{ mm}^2$, and T1S was $26.78 \pm 6.33^\circ$. In straight group, C2–C7 Cobb angle was $3.95 \pm 2.69^\circ$, C7/T1 intervertebral foramen area was $39.95 \pm 10.94 \text{ mm}^2$ and T1S was $18.85 \pm 4.42^\circ$ (Table 1). The correlation of the parameters was calculated. C7–T1 intervertebral foramen area was positively correlated with both C2–C7 Cobb angle ($r = 0.23$, $P = 0.02$) and T1S ($r = 0.21$, $P = 0.03$). In lordosis group, C7–T1 intervertebral foramen area was positively correlated with C2–C7 Cobb angle ($r = 0.69$, $P < 0.01$), and T1S ($r = 0.34$, $p = 0.02$). However, in straight group, C7–T1 intervertebral foramen area had no correlation with C2–C7 Cobb angle ($r = -0.04$, $P = 0.78$) and T1S ($r = 0.14$, $p = 0.32$) (Table 2).

When the age is ≥ 65 years old, there is no correlation between each parameter and age, and there is no statistical difference. When the age is < 65 years old, C7/T1 intervertebral foramen area has a negative correlation with age ($r = -0.236$, $P = 0.044$), and other parameters have no

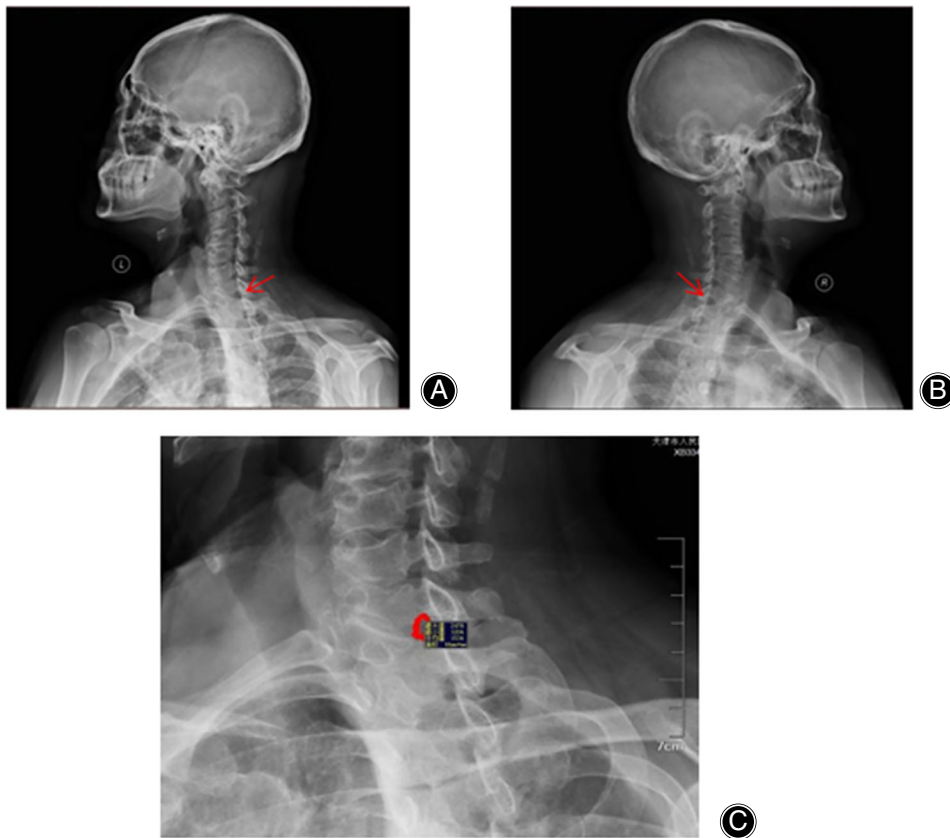


Fig. 2 The sagittal, T2-weighted magnetic resonance image of the cervical spine. (A) Left posterior oblique at 45°. The arrow points to the C7/T1 intervertebral foramen which is the area surrounded by the inferior vertebral notch of upper vertebra and the superior vertebral notch of lower vertebra; (B) Right posterior oblique at 45°. The arrow points to the C7/T1 intervertebral foramen; (C) The C7/T1 intervertebral foramen area circled on the left posterior oblique at 45°, the area measured by the MAS-1 simulation system.

TABLE 1 Measurement of the sagittal parameters

	Lordosis subjects (n = 45)	Straight subjects (n = 55)	t	P
C2–C7 Cobb (°)	19.07 ± 6.98	3.95 ± 2.69	13.72	<0.01
T1S (°)	26.78 ± 6.33	18.85 ± 4.42	7.10	<0.01
C7–T1 intervertebral foramen area (mm ²)	40.69 ± 11.44	39.95 ± 10.94	2.25	<0.05

TABLE 2 Correlation between C7–T1 intervertebral foramen area and C2–C7 Cobb angle and T1S

	Lordosis group (n = 45)		Straight group (n = 55)		Total	
	r	P	r	P	r	p
C7–T1 intervertebral foramen area and C2–C7 Cobb angle	0.69	<0.01	–0.04	0.78	0.23	0.02
C7–T1 intervertebral foramen area and T1S	0.34	0.02	0.14	0.32	0.21	0.03

TABLE 3 The association between the indexes with age

Indexed	≥65 years old		<65 years old	
	r	P	r	P
C2–C7 Cobb	0.047	0.818	–0.019	0.873
T1S	–0.098	0.627	–0.172	0.146
C7/T1 intervertebral foramen area	–0.249	0.210	–0.236*	0.044

*Indicates that C7/T1 intervertebral foramen area has a negative correlation with age.

TABLE 4 The association between the indexes with gender (*r/p*)

Indexed	Male		Female	
	T1S	Intervertebral foramen area	T1S	Intervertebral foramen area (mm ²)
C2-C7 Cobb	0.719/0.000	0.213/0.097	0.696/0.000	0.312/0.057
T1S		0.318/0.012		0.428/0.007

correlation with age (Table 3). In males, there was a positive correlation between T1S and C2-C7Cobb ($r = 0.719$, $P = 0.000$), a positive correlation between T1S and C7/T1 intervertebral foramen area ($r = 0.318$, $P = 0.012$), and no correlation between C2-C7 cobb and C7/T1 intervertebral foramen area ($r = 0.213$, $P = 0.097$). In females, there was a positive correlation between T1S and C2-C7 Cobb ($r = 0.696$, $P = 0.000$), and there was no correlation between other parameters (Table 4).

Discussion

Cervical curvature can be used to assess the sagittal balance of cervical spine, which enables the body to maintain biomechanical stability by consuming the least amount of energy. Previous studies have shown that the CL of patients with CSM is slightly smaller than that of normal people,¹⁰ indicating that patients with CSM need higher energy to maintain the sagittal balance of the cervical spine. The sagittal parameters were used to assess the sagittal balance of the cervical spine. In addition, studies have shown that there is a certain correlation between these parameters.^{11,12}

Intervertebral Foramen Evaluation

The intervertebral foramen is the area surrounded by the inferior vertebral notch of upper vertebra and the superior vertebral notch of lower vertebra, forming the passage for cervical nerve root. The size of intervertebral foramen can directly affect the nerve root.¹³ Siemionow *et al.*¹⁴ found that the placement of an interbody cage during posterior neck surgery could increase the corresponding intervertebral foramen area and relieve nerve root compression. Sun *et al.*¹⁵ confirmed that for CSM patients, intraoperative interbody fusion cages in the intervertebral space could expand intervertebral foramen in various degrees. Zhang *et al.*¹⁶ showed that when the opening was 2–3 mm higher than the original gap, intervertebral foramen area could be increased to achieve the effect of decompression. Other studies also pointed out that an appropriate increase in the area of cervical intervertebral foramen could relieve spinal cord compression symptoms and maintain the sagittal balance.^{17,18} Considering that cervical intervertebral foramen of CSM patients is related to the sagittal balance of cervical spine, this study investigated the relationship between intervertebral foramen measured by posterior oblique X-ray and the

sagittal parameters of cervical spine measured by MRI in CSM patients.

C7/T1 Intervertebral Foramen Area Evaluation

C7/T1 intervertebral foramen is used in this study, since T1 is the base of the entire cervical vertebrae. The size of the C2-C7 Cobb angle can directly reflect the lordosis of cervical vertebra,^{19,20} and there is a positive correlation between C2-C7 Cobb angle and T1S.²¹⁻²³ The current study showed that in lordosis group (Cobb angle $>10^\circ$), C7/T1 intervertebral foramen area was positively correlated with the C2-C7 Cobb angle ($r = 0.69$, $P < 0.01$), and T1S ($r = 0.34$, $P = 0.02$). Therefore, C7/T1 intervertebral foramen can be used as the sagittal parameter of cervical spine for CSM patients with CL. However, in the straight group (C2-C7 Cobb angle $\leq 10^\circ$), there is no correlation between C7-T1 intervertebral foramen area and C2-C7 Cobb angle and T1S. Therefore, for CSM patients in whom the CL has been straightened, C7-T1 intervertebral foramen area cannot be used as a sagittal parameter. We suspect that intervertebral foramen area may be narrowed in the straight group including straightening of the physiological curvature of the cervical spine.

Correlation between C7-T1 Intervertebral Foramen Area and Sagittal Curvature of Cervical Vertebra

For CSM patients with CL, the sagittal balance of cervical vertebrae can be evaluated by a simple and economic method by measuring C7-T1 intervertebral foramen area with oblique X-ray. For CSM patients with straightened CL, multiple parameters such as C2-C7 Cobb angle and T1S are needed to evaluate the sagittal balance of cervical spine. However, our study only included patients with CSM. In addition, the factors affecting the severity of cervical degeneration and the intervertebral foramen of other cervical segments have not been analyzed, which may limit the application of our study. Furthermore, the sample size has not pre-calculated and it is relatively small. Thus, we cannot neglect the influence of bias on the statistical results. Further studies with large sample sizes need to be performed.

Limitations

There were also some limitations in this study. This is an observational study without control. The sample size is small. Further study with control group and large sample size is need. The effect of gender or age on the association has not

been evaluated in this study, which is still needed to be investigated in further study.

Conclusion

In summary, the C7–T1 intervertebral foramen area measured by oblique X-ray can be used as an effective method to evaluate the sagittal balance of cervical vertebrae for CSM patients with CL. From this study, we provide a simple, effective and economic sagittal parameter of the cervical spine.

Author Contributions

Lilong Zhang is responsible for the guarantor of integrity of the entire study, study concepts & design, statistical analysis; Zijian Cui is responsible for the definition of intellectual content, manuscript editing; Chen Yuan is responsible for the data acquisition; Xueli Zhang is responsible for the clinical studies, manuscript preparation; Zhishuai Ren is responsible for the data analysis; Wei Wang is responsible for the literature research; Ping Xia is responsible for the experimental studies; Rusen Zhu is responsible for the manuscript review. All authors read and approved the final manuscript.

References

1. Tang JA, Scheer JK, Smith JS, Deviren V, Bess S, Hart RA, et al. The impact of standing regional cervical sagittal alignment on outcomes in posterior cervical fusion surgery. *Neurosurgery*. 2015;76(Suppl 1):14–21.
2. Xing R, Liu W, Li X, Jiang L, Yishakea M, Dong J. Characteristics of cervical sagittal parameters in healthy cervical spine adults and patients with cervical disc degeneration. *BMC Musculoskelet Disord*. 2018;19(1):37.
3. Hansen BB, Bendix T, Grindsted J, Bliddal H, Christensen R, Hansen P, et al. Effect of lumbar disc degeneration and low-back pain on the lumbar lordosis in supine and standing. *Spine*. 2015;40(21):1690–6.
4. Hu SY, Cui YN, Zhao YX, Lu M, Li SL. Magnetic resonance imaging versus DR for whole spine imaging in patients with degenerative spinal disease. *J South Med Univ*. 2017;37(9):1252–5.
5. Xing R, Zhou G, Chen Q, Liang Y, Dong J. MRI to measure cervical sagittal parameters: a comparison with plain radiographs. *Arch Orthop Trauma Surg*. 2017;137(4):451–5.
6. Zhang LL, Cheng ZZ, Cui ZJ, Ren Z, Peng B, Zhang X. Analysis of cervical sagittal parameters on MRI in patients with cervical spondylotic myelopathy. *Chin J Reparat Reconstr Surg*. 2017;4:451–4.
7. Zhang KB, Zhan HR, Yu B, Wang JR, Chen T, Huang ZW. Differences in X-ray and CT imaging measurements of adult cervical sagittal parameters. *J Third Mil Med Univ*. 2015;37(19):1997–2000.
8. Wu T, Liu J, Wang G. Reliability of evaluating C2–7Cobb angle for cervical degenerative disease with unclear C7 vertebrae on X-ray, CT and MRI. *Chin J Tissue Eng Res*. 2018;22(31):4993–7.
9. McCormick JR, Sama AJ, Schiller NC, Butler AJ, Donnally CJ 3rd. Cervical spondylotic myelopathy: a guide to diagnosis and management. *J Am Board Fam Med*. 2020;33(2):303–13.
10. Yoshida G, Alzakri A, Pointillart V, Boissiere L, Obeid I, Matsuyama Y, et al. Global spinal alignment in patients with cervical spondylotic myelopathy. *Spine*. 2018;43(3):E154–62.
11. Mangione P, Sénégas J. Sagittal balance of the spine. *Rev Chir Orthop Reparatrice Appar Mot*. 1997;83(1):22–32.
12. Ma Z, Liu P, Liu J, Mou J, Wang Z, Sun D, et al. Kinematic analysis of the relationship between Modic changes and sagittal balance parameters in the cervical spine. *Medicine*. 2017;96(33):e7699.
13. Sioutas G, Kapetanakis S. Clinical anatomy and clinical significance of the cervical intervertebral foramen: a review. *Folia Morphol (Warsz)*. 2016;75(2):143–8.
14. Siemionow K, Janusz P, Glowka P. Cervical cages placed bilaterally in the facet joints from a posterior approach significantly increase foraminal area. *Eur Spine J*. 2016;25(7):2279–85.
15. Sun PF, Xie YC, Zhang HC, Xiang LB, Yu HL. The change of intervertebral foramina in anterior cervical discectomy and fusion. *Chin J Spine Spinal Cord*. 2018;28(1):52–6.
16. Zhang ZF, Mei FR. An experimental study of the effect of interbody distraction in increasing cervical foraminal area. *Chin J Spine Spinal Cord*. 1999;1:20–2.
17. Yuan C, Zhu H, Song D, Wei W, Zhu R, Mei X, et al. Impact and clinical significance of pedicle length on spinal canal and intervertebral foramen area. *Int J Clin Exp Med*. 2014;7(1):163–9.
18. Yusof MI, Hassan MN, Abdullah MS. The relationship amongst intervertebral disc vertical diameter, lateral foramen diameter and nerve root impingement in lumbar vertebra. *Malays Orthop J*. 2018;12(1):21–5.
19. Guo GM, Li J, Diao QX, Zhu TH, Song ZX, Guo YY, et al. Cervical lordosis in asymptomatic individuals: a meta-analysis. *J Orthop Surg Res*. 2018;13(1):147.
20. Shen XL, Tian Y, Zhou XH, Ren D, Cao P, Yuan W. A radiographic analysis of cervical sagittal alignment in adolescent idiopathic cervical kyphosis. *Clin Spine Surg*. 2017;30(5):E560–6.
21. Zhao WK, Yu M, Wei F. Analysis of the cervical spine alignment and its correlation with spino-pelvic balance in asymptomatic young adults. *Chin J Spine Spinal Cord*. 2015;25(3):231–8.
22. Hyun SJ, Kim KJ, Jahng TA, Kim HJ. Relationship between T1 slope and cervical alignment following multilevel posterior cervical fusion surgery: impact of T1 slope minus cervical lordosis. *Spine*. 2016;41(7):E396–402.
23. Knott PT, Mardjetko SM, Techy F. The use of the T1 sagittal angle in predicting overall sagittal balance of the spine. *Spine J*. 2010;10(11):994–8.