

Spinal Arteriovenous Fistulas of the Filum Terminale: Case Report and Literature Review

Abstract

Spinal arteriovenous fistulae (AVF) are an uncommon cause of myelopathy that require a high degree of suspicion to diagnose. Treatment strategies have not yet been established. Only a few cases of AVFs of the filum terminale (FT) have been reported. In this review, we describe clinical presentation, imaging, and treatment options for this rare type of spinal AV shunt. A 43-year-old male patient presented with progressive low back pain and paraparesis with gradually worsening bilateral foot paresthesias and sphincter dysfunction. He underwent magnetic resonance imaging, which revealed a hypersignal in the thoracolumbar cord and angiography diagnosed a microfistula of the FT. Surgery was preferred over endovascular treatment and we realized an L5 laminectomy to open the dura mater and found a hypertrophic FT. After identifying the fistula which was closely related to cauda equina, and dissecting the root from the fistula, a permanent clip was placed on the proximal part of the arterialized vein. Surgery was uneventful, and 6 months postoperatively, the patient has fully recovered. FT AVFs although rare should be considered as a differential diagnosis of progressive paraparesis, and successful surgery through clipping relies on the angioarchitecture of the shunt and the clinical manifestations of the patient.

Keywords: *Filum terminale, perimedullary, shunt, spinal arteriovenous fistula*

Introduction

Dural arteriovenous fistulas (DAVFs) are the most common vascular malformations of the spine that may be difficult to properly diagnose, they account for approximately 80% of spinal AV malformations (AVMs). Initially described by Djindjan in 1977,^[1] AVFs at the filum terminale (FTAVFs) have been classified as type IV intradural perimedullary AVFs, and account for only 3% of spinal vascular malformations. To the best of our knowledge, 47 cases of FTAVF have been reported so far in the English literature from 1977 to January 2019 [Table 1]. This report describes the case of a patient with an FTAVF, and the reasoning that allowed the diagnosis and possible therapies proposed with a final satisfactory surgical approach.

Case Report

History and presentation

A 4-year-old male had no particular previous medical history of trauma, surgery, or any other chronic disease, presented with

history, of intermittent and insidious low back pain radiating to both lower limbs for the past 2 years. This symptomatology was not getting relieved despite analgesics and physiotherapy modalities, all evolving toward gait disturbance with sciatic pain, paresthesia in both lower limbs, and sphincter disorder (pollakiuria). Assessment of her neurological condition revealed paraparesis a Grade 3 of the modified McCormick functional schema and a Grade 3 of the sensory pain scale.

The association of these symptoms suggested a cauda equina syndrome, and magnetic resonance imaging (MRI) was performed. T2-weighted MRI revealed the presence of a high intramedullary signal at the level of the thoracolumbar cord predominating at the conus that was associated with abnormal flow voids suggesting the tortuous and dilated perimedullary vessels as a sign of chronic venous congestion.

On T1-W1, spinal cord hypersignal changes that enhanced strongly after injection with gadolinium. These radiological features evoked a spinal vascular malformation excluding other differential diagnosis,

How to cite this article: Lakhdar F, Benzagmout M, Chakour K, Chaoui ME. Spinal arteriovenous fistulas of the filum terminale: Case report and literature review. *Asian J Neurosurg* 2019;14:1277-82.

**Fayçal Lakhdar,
Mohammed
Benzagmout,
Khalid Chakour,
Mohammed El Faiz
Chaoui**

*Department of Neurosurgery,
Hassan II Hospital, University
Medical School of Fez, Sidi
Mohamed Ben Abdellah, Fez,
Morocco*

Address for correspondence:
Prof. Fayçal Lakhdar,
10, Rue Oulad Jerrar Souissi,
BP 10100, Rabat, Morocco.
E-mail: lakhdar.faycal@gmail.
com

Access this article online

Website: www.asianjns.org

DOI: 10.4103/ajns.AJNS_100_19

Quick Response Code:



This is an open access journal, and articles are distributed under the terms of the Creative Commons Attribution-NonCommercial-ShareAlike 4.0 License, which allows others to remix, tweak, and build upon the work non-commercially, as long as appropriate credit is given and the new creations are licensed under the identical terms.

For reprints contact: reprints@medknow.com

mostly a tumoral etiology [Figure 1]. Thereby, a spinal angiogram was done, which showed FTAVF at the lower lumbosacral region with fistulous point projected along the fifth lumbar spine (L5). The AVF was between the distal anterior spinal artery (ASA) and an early filling enlarged and tortuous vein returning cranially along the FT [Figure 2]. The diagnosis of a FTAVF was thus definitively confirmed.

Operation and postoperative course

The therapeutic management options of our patient included surgical or endovascular treatment. Both methods have to identify and disconnect the draining vein to complete interruption of the shunt and to fix the lesion. In the present case, we preferred surgery because the distal anatomical location of the shunt even if embolization is technically possible but carries some risks to distal navigation of the microcatheter in the ASA and difficulties inherent to the small caliber of the feeding artery and the tortuosity. However, we elected for a simple surgical approach through a total laminectomy L5 and partial laminectomy L4 with the removal of the ligamentum flavum, to expose the dura. After opening the dura mater and arachnoid dissection, the roots of the cauda equine are gently displaced to expose the filum. Moreover, the fistula was easily identified. Since the vessels and nerve roots adhered to each other around the fistula, the draining vein was clipped.

The postoperative course was uneventful with successful complete obliteration of shunt vessels. The patient experienced symptomatic improvement postoperatively and at the last follow-up of 1 year later, he was independent for all activities of daily living without any neurological deficit.

On postoperative spinal angiography, the feeding artery (proximal radicular artery) was invisible at the bottom of the conus medullaris and the draining vein was not demonstrated.

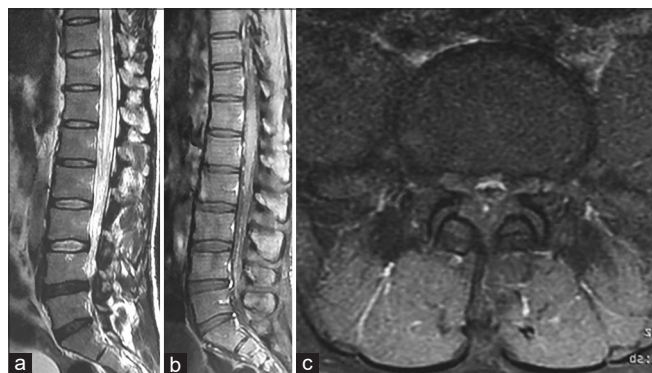


Figure 1: Sagittal (a) T2-weighted, axial (b) and sagittal (c) postcontrast T1-weighted spinal magnetic resonance imaging, showing a high signal intense lesion in the conus medullaris, with increased flow voids over the spinal cord with more evident venous tortuosity and dilated vessels in the subarachnoid space

Discussion

FTAVF are uncommon intradural direct arteriovenous shunt, generally characterized by a single direct communication between the distal caudal continuation of the ASA, the artery of the FT and a single ascending vein which then ascends along the filum. According to the anatomical space in which spinal cord vascular malformations develop, four groups of lesions may be described: paraspinal; epidural; dural; and intradural.^[2,3] Therefore, from the anatomic and embryologic view, FTAVFs are usually classified as “perimedullary fistulas.”

Pathogenesis and histopathology

The pathogenesis of FTAVF still remains unclear with no direct evidence supporting either an acquired or congenital etiology for these lesions. Although some authors speculate that FTAVF is congenital,^[4,5] others believe that FTAVF may be of acquired origin and created by some angiogenic phenomena because most patients present in the latter half of adulthood. It is widely agreed that FTAVF is often presenting with symptoms secondary to venous hypertension and congestive myelopathy. However, some authors report that venous hypertension could cause a secondary AVF.^[6]

Although it is rare, FTAVFs could have multiple shunt points along the FT.^[5] Less commonly, FTAVF can be fed by branches of the lateral and/or the middle sacral arteries which can, in fact, supply the filum.^[7]

Microscopic examination of the fistulous point demonstrates an arterialization of the proximal draining vein,^[8] muscular layer abnormalities, and a fragmented internal elastic lamina of the markedly dilated vein.^[9]

Epidemiology and clinical manifestations

FTAVF represented only 3.1% of all intradural AVF,^[10] and <5% of spinal intradural AVMs.^[10] FTAVF commonly present in male (79%), sex ratio 3.8, with median age of 56 years [Table 1].

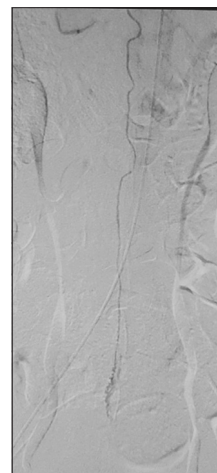


Figure 2: Spinal angiogram shows an arteriovenous fistula of the filum terminale at L4–L5 level

Table 1: Summary of cases (FTAVF) reported in the literature

<i>n</i> ^o	Authors (years)	Age (years)/sex	Length of symptoms (months)	Feeders	Location	Treatment	Outcome
1	Djindjian <i>et al.</i> (1977) ^[1]	37/male	12	ASA	L2	S	PR
2		40/female	48	ASA+LSA	L3	S	SS
3	Gueguen <i>et al.</i> (1987) ^[11]	40/female	36	ASA (T8)	L3	S	SS
4		24/female	15	ASA (T9)	L2	S	↑
5	Meisel <i>et al.</i> (1995) ^[12]	30/male		ASA	L2	S	↑
6	Tender <i>et al.</i> (2005) ^[13]	70/male	84	ASA (T8)	L4	S	↑
7		58/male	12	ASA (T9)	L2	S	↑
8	Mitha <i>et al.</i> (2006) ^[9]	42/male	84		S1	S	↑
9	Jin <i>et al.</i> (2010) ^[14]	61/male	120	LSA	L5/S1	S	↑
10	Witiw <i>et al.</i> (2011) ^[15]	62/male	6	ASA (T8)	S2/3	S	↑ (PSD)
11	Lim <i>et al.</i> (2011) ^[16]	60/male	36	ASA (L1)	L3	S	↑
12		48/male		ASA (T10)	L4/5	S	↑
13		53/female		ASA (L1)	L4/5	E	PR
14		63/female		ASA (L4) + LSA	L3/4	E	↑ (PSD)
15	Trinh and Duckworth (2011) ^[17]	57/male	24			S	↑
16		63/male	48		L4/5	E	↑
17	Saito <i>et al.</i> (2011) ^[18]	68/male	ND	ASA (T9) + LSA	ND	S	↑
18	Kumar <i>et al.</i> (2011) ^[19]	44/male	8	ASA (T9)		S	↑
19	Haddad <i>et al.</i> (2012) ^[20]	60/male	12	ASA (T11)	S1	E	↑
20	Takami <i>et al.</i> (2012) ^[21]	66/female	6	ASA (L1)	L2	S	↑
21		63/male	36	ASA (T11)	L2/3	S	↑
22	Fischer <i>et al.</i> (2013) ^[22]	69/male	>12	ASA (T9)	L4	S	↑ (PSD)
23	Macht <i>et al.</i> (2012) ^[23]	57/male	1	LSA (S2)	S3/4	E	↑
24	Chanthanaphak <i>et al.</i> (2013) ^[24]	70/female	6	ASA (T12)	L5	E	↑
25		55/male	12	ASA (T10)	L4	E	↑
26		63/male	4	ASA (T11)	L5	S	↑
27		39/female	2	ASA (T11)	L2/3	E	↑
28		31/male	24	ASA (T10)	L2/3	E	↑
29		67/male	12	ASA (T9)	L3	E	↑
30		72/male	12	ASA (L1)	L5	E	↑
31		57/female	18	ASA (L4)	S2	S	↑ (PSD)
32		66/male	12	ASA (T9)	L2	S	↑
33		62/male	6	ASA (T8)	S2/3	S	↑
34	Takeuchi <i>et al.</i> (2014) ^[8]	71/male	60	ASA (T9)	L4	S	↑
35	Krishnan <i>et al.</i> (2013) ^[25]	54/male	36	ASA (T12)	L4	S	↑
36	Sharma <i>et al.</i> (2014) ^[26]	48/male	132	ASA (T9)	L4/5	S	↑
37	Wajima <i>et al.</i> (2017) ^[7]	78/male	12	ASA (T8/9) + LSA	S1/2	S	↑
38	Sharma <i>et al.</i> (2016) ^[27]	42/male	48	ASA (L3)	L3	S	ND
39	Ding <i>et al.</i> (2016) ^[10]	43/male	24	ASA (L1)	L3	S	↑
40	Li <i>et al.</i> (2017) ^[4]	65/male	48	ASA (L2)	L2	S	↑
41	Lamsam <i>et al.</i> (2018) ^[28]	50/male	12	ASA (L2)	L2	S	↑
42	Takai <i>et al.</i> (2019) ^[29]	73/male	24	ASA (T10)	L2	S	↓
43		63/female	24	ASA (L1)	L3	S	↓
44		76/male	48	ASA (T10)	L5	S	↓
45		84/male	24	ASA	L4	S	↓
46	Hong <i>et al.</i> (2018) ^[5]	45/male	12	ASA (T10)	L2/3	S	↑
47		31/male	8	ASA	L2	S	↑
48	Lakhdar <i>et al.</i> (2019) (present case)	45/male	43			S	↑

S – Surgery; E – Embolization; ↑ – Improvement; PR – Partial recovery; SS – Symptom stabilization; PSD – Persistent sphincter/sexual disturbance; ASA – Anterior spinal artery; LSA – Lateral spinal artery; ↑ – Deterioration

As in other spinal vascular malformations, these lesions are important neurological entities because the myelopathy seen in FTAVF patients is related to an ascending congestive venopathy, vascular hypertension, and a putative chronic steal phenomenon. Indeed, they could result in progressive Foix–Alajouanine syndrome.^[5,6,30] However, this slowly progressive myelopathy requires a high degree of suspicion to diagnose cause FTAVF are often misdiagnosed with polyneuropathy or as the result of spine degenerative disease (~20% of cases).^[31] Furthermore, few cases have been misdiagnosed and operated for lumbar stenosis and disc prolapse resulting in a failed back surgery syndrome.^[27] Interestingly, hemorrhage has never been reported as a mode of presentation in association with this subtype of spinal vascular malformation.^[6]

Imaging

Spinal MRI demonstrates increased flow voids and T2 changes involving the conus and the FT. Furthermore, prominent vascular flow voids (46%) and vascular enhancement (67%) are extremely common.^[6] As MRI findings are often nonspecific and may sometimes fail to precisely assess the shunt zone, the spinal angiogram is often of considerable help for a proper diagnosis, to localize exactly the site of the fistula and to precisely define the angioarchitecture.

On spinal angiography, FTAVF is generally characterized by a focal, single-hole fistula located well below the conus in the lower lumbar spine. It can be helpful in differentiating these lesions from DAVF and epidural AVF. A good knowledge of angioarchitecture and anatomy gave a proper appreciation of the AV shunt and allowed the appropriate treatment strategy to be made.

Treatment

The ultimate treatment goal of FTAVF consists of complete obliteration of the direct AV shunt with preservation of the normal spinal cord circulation. Both surgical and endovascular embolization are safe and effective therapeutic modalities in achieving complete interruption of the shunt. Indeed, the key factor in treating these lesions is safe isolation of the feeding artery, nidus, and draining vein. Some authors suggest that the distance from the top of the arterial feeder to the fistulous point is determining factor for the choice of treatment.^[7,21] However, because of distal location, the very small caliber of the feeding artery and the tortuosity, endovascular therapy with safe catheterization proximal to the actual AV connection is often not feasible; and thus, surgery is often the preferred treatment. Endovascular treatment in the form of embolization may be associated with high risk related to distal navigation of the microcatheter and tearing or occlusion of ASA, or its

branches in FTAVFs, causing thrombosis and vasospasm. Sometimes, endovascular procedure is technically difficult because of the small caliber of the ASA and the long distance between the origin of the radiculomedullary artery and the fistula. While, microsurgery is considered to be a first-line treatment, more favorable for avoiding arterial ischemic complications despite some risks of injury or occlusion of normal spinal vessels. Furthermore, we recommend surgical treatment considering the low morbidity and the high occlusion rates.^[6]

Surgical treatment is very effective and safe technique for most of these lesions as approximately 77% of the cases in the literature have been treated surgically [Table 1]. The surgical strategy of FTAVFs by ligation or clipping as in our case should include sufficient laminectomy and disconnection of all shunts. After posterior midline exposure at the lumbar level of fistula, dural opening, and arachnoid dissection, the fistula was identified, and the feeding artery and draining vein were coagulated.

Furthermore, some authors report three successful cases of sectioning of the filum above the fistulous point, considering that the FT has no neurologic function.^[15] Therefore, the resection of the FT requires a distance of >2 cm from the normal distal end.^[8]

The authors also illustrate the benefits of repeated indocyanine green (ICG) fluorescein angiography, which is technically feasible, safe, and helpful in identifying vascular angioarchitecture.^[28] Although vascular flow and identification of crucial landmarks also need to be ensured with intraoperative image guidance.^[21] Some authors use the monitoring of somatosensory and motor evoked potentials to secure good clinical outcomes and to avoid spinal cord infarct. However, both intraoperative ICG video angiography and intraoperative neuromonitoring have not been used in this case.

Outcome and follow-up

Regardless of the modality of treatment, after the obliteration of FTAVF, the pressure in the spinal veins will decrease, which invariably results in progressive improvement or at least stabilization of symptoms^[3] [Table 2]. The majority of patients (81%) will experience improvement of their motor and sensory symptoms [Table 2]. Although bladder and bowel dysfunction are less likely to improve,^[28] there

Table 2: Outcome and postoperative clinical status for all cases of the literature

Outcome	Rate (%)
Improvement	81
PR	4
SS	4
Aggravation	8

PR – Partial recovery; SS – Symptom stabilization

is often not a direct correlation between radiological and clinical improvement.^[16]

Conclusion

Besides being a rare entity with no specific clinical manifestations, FTAVF can be successfully treated using multidisciplinary approaches. Surgery is often the primary choice in most cases with good results, especially in progressive neurologic deficit.

Declaration of patient consent

The authors certify that they have obtained all appropriate patient consent forms. In the form the patient(s) has/have given his/her/their consent for his/her/their images and other clinical information to be reported in the journal. The patients understand that their names and initials will not be published and due efforts will be made to conceal their identity, but anonymity cannot be guaranteed.

Financial support and sponsorship

Nil.

Conflicts of interest

There are no conflicts of interest.

References

- Djindjian M, Djindjian R, Rey A, Hurth M, Houdart R. Intradural extramedullary spinal arterio-venous malformations fed by the anterior spinal artery. *Surg Neurol* 1977;8:85-93.
- Kim LJ, Spetzler RF. Classification and surgical management of spinal arteriovenous lesions: Arteriovenous fistulae and arteriovenous malformations. *Neurosurgery* 2006;59:S195-201.
- Rodesch G, Lasjaunias P. Spinal cord arteriovenous shunts: From imaging to management. *Eur J Radiol* 2003;46:221-32.
- Li J, Li G, Bian L, Hong T, Yu J, Zhang H, *et al.* Concomitant lumbosacral perimedullary arteriovenous fistula and spinal dural arteriovenous fistula. *World Neurosurg* 2017;105:1041.e7-1.041E+17.
- Hong T, Yu JX, Liu W, Bian LS, Yang F, Ma YJ, *et al.* Filum terminale arteriovenous fistulas with multiple shunt points: A report of two exceptional cases. *World Neurosurg* 2018;118:235-9.
- Giordan E, Brinjikji W, Ciceri E, Lanzino G. Arteriovenous fistulae of the filum terminale. *J Neurointerv Surg* 2018;10:191-7.
- Wajima D, Nakagawa I, Park HS, Haku T, Wada T, Kichikawa K, *et al.* A case of filum terminale arterial venous fistula needed a long arterial access for trans-arterial shunt obliteration. *Interv Neuroradiol* 2017;23:221-7.
- Takeuchi M, Niwa A, Matsuo N, Joko M, Nakura T, Aoyama M, *et al.* Pathomorphological description of the shunted portion of a filum terminale arteriovenous fistula. *Spine J* 2014;14:e7-10.
- Mitha AP, Murphy EE, Ogilvy CS. Type A intradural spinal arteriovenous fistula. Case report. *J Neurosurg Spine* 2006;5:447-50.
- Ding D, Law AJ, Scotter J, Brew S. Lumbar disc herniation exacerbating venous hypertension from a spinal perimedullary arteriovenous fistula of the filum terminale. *J Neurol Sci* 2016;369:276-7.
- Gueguen B, Merland JJ, Riche MC, Rey A. Vascular malformations of the spinal cord: Intrathecal perimedullary arteriovenous fistulas fed by medullary arteries. *Neurology* 1987;37:969-79.
- Meisel HJ, Lasjaunias P, Brock M. Modern management of spinal and spinal cord vascular lesions. *Minim Invasive Neurosurg* 1995;38:138-45.
- Tender GC, Vortmeyer AO, Oldfield EH. Spinal intradural arteriovenous fistulas acquired in late adulthood: Absent spinal venous drainage in pathogenesis and pathophysiology. Report of two cases. *J Neurosurg Spine* 2005;3:488-94.
- Jin YJ, Kim KJ, Kwon OK, Chung SK. Perimedullary arteriovenous fistula of the filum terminale: Case report. *Neurosurgery* 2010;66:E219-20.
- Witiw CD, Fallah A, Radovanovic I, Wallace MC. Sacral intradural arteriovenous fistula treated indirectly by transection of the filum terminale: Technical case report. *Neurosurgery* 2011;69:E780-4.
- Lim SM, Choi IS, David CA. Spinal arteriovenous fistulas of the filum terminale. *AJNR Am J Neuroradiol* 2011;32:1846-50.
- Trinh VT, Duckworth EA. Surgical excision of filum terminale arteriovenous fistulae after lumbar fusion: Value of indocyanine green and theory on origins (a technical note and report of two cases). *Surg Neurol Int* 2011;2:63.
- Saito H, Hida K, Asano T, Yano S, Aoyama T, Iwasaki Y, *et al.* Conus perimedullary arteriovenous fistula with multiple shunt points including the cauda equina: A case report. *No Shinkei Geka* 2011;39:375-80.
- Kumar A, Deopujari CE, Mhatre M. Misdiagnosis in a case of non-compressive myelopathy due to a lumbar spinal intradural fistula supplied by the artery of adamkiewicz. *Surg Neurol Int* 2011;2:12.
- Haddad S, Condette-Auliac S, Ozanne A, Roccatagliata L, Rodesch G. Arteriovenous fistula of the filum terminale: Radiological diagnosis and therapeutic management by embolization. *J Neuroradiol* 2012;39:368-72.
- Takami T, Yamagata T, Mitsunashi Y, Hayasaki K, Ohata K. Direct surgery for spinal arteriovenous fistulas of the filum terminale with intraoperative image guidance. *Spine (Phila Pa 1976)* 2012;37:E1524-8.
- Fischer S, Aguilar Perez M, Bassiouni H, Hopf N, Bätzner H, Henkes H, *et al.* Arteriovenous fistula of the filum terminale: Diagnosis, treatment, and literature review. *Clin Neuroradiol* 2013;23:309-14.
- Macht S, Chapot R, Bieniek F, Hänggi D, Turowski B. Unique sacral location of an arteriovenous fistula of the filum terminale associated with diastematomyelia and lowered spinal cords. *Neuroradiology* 2012;54:517-9.
- Chanthanaphak E, Pongpech S, Jiarakongmun P, Kobkitsuksakul C, Chi CT, Terbrugge KG, *et al.* Filum terminale arteriovenous fistulas: The role of endovascular treatment. *J Neurosurg Spine* 2013;19:49-56.
- Krishnan P, Banerjee TK, Saha M. Congestive myelopathy (Foix-Alajouanine syndrome) due to intradural arteriovenous fistula of the filum terminale fed by anterior spinal artery: Case report and review of literature. *Ann Indian Acad Neurol* 2013;16:432-6.
- Sharma BB, Sharma SS, Ramachandran P, Jilowa S. Arterial venous fistula (AVF) of filum terminale-MRI diagnosis – A case report. *Andrology (Los Angel)* 2016;5:1000158.
- Sharma P, Ranjan A, Lath R. Arteriovenous fistula of the filum terminale misdiagnosed and previously operated as lower lumbar degenerative disease. *Asian Spine J* 2014;8:365-70.
- Lamsam L, Quon J, Fischbein N, Iv M, Dodd R, Ratliff J. Conus

- medullaris dural arteriovenous fistula arising from the artery of the filum terminale: 2-dimensional operative video. *Oper Neurosurg (Hagerstown)* 2018;15:471.
29. Takai K, Komori T, Taniguchi M. Angioarchitecture of filum terminale arteriovenous fistulas: Relationship with a tethered spinal cord. *World Neurosurg* 2019;122:e795-e804.
 30. Hong T, Park JE, Ling F, terBrugge KG, Tymianski M, Zhang HQ, *et al.* Comparison of 3 different types of spinal arteriovenous shunts below the conus in clinical presentation, radiologic findings, and outcomes. *AJNR Am J Neuroradiol* 2017;38:403-9.
 31. Jellema K, Tijssen CC, van Gijn J. Spinal dural arteriovenous fistulas: A congestive myelopathy that initially mimics a peripheral nerve disorder. *Brain* 2006;129:3150-64.