

Isolated Unilateral Horizontal Semicircular Canal Malformation

Yi-Wei Liu, Ke Sun, Jian-Guo Tang

Department of Otolaryngology-Head and Neck Surgery, Sir Run Run Shaw Hospital, Medical College of Zhejiang University, Hangzhou, Zhejiang 310016, China

To the Editor: Semicircular canal (SCC) malformation (dystrophy, coloboma, or enlargement) is a kind of inner ear anomaly. It is usually found in congenital syndromes along with the malformation(s) of other structure(s) of any of the parts of the ear including the inner ear. Isolated one SCC malformation is extremely rare and might thereby be easily missed. The present study reports a case of the left lateral SCC (LSCC) aplasia.

A 50-year-old woman presented with tinnitus and vertigo for one year, which was relieved by rest. The patient had no history of hearing loss. The vertigo was rotatory, episodic, and positional in nature. She had no relevant personal or family history, and no history of head trauma or use of ototoxic medication. The external auditory canals and tympanic membranes were normal on examination. Pure-tone audiometry was found to be normal [Figure 1a]. Tympanometry revealed a Type A curve. Videonystagmography was normal and revealed no spontaneous nystagmus. The Dix-Hallpike test and roll test were negative as was head-shaking test. Vestibular evoked myogenic potential testing was normal [Figure 1b]. Caloric tests revealed bilateral SCC paresis, which was more on the left side, and persisted for 1 s on the left and 6 s on the right after stimulation with cold water. However, there was no response after stimulating with hot water [Figure 1c].

Magnetic resonance imaging (MRI) of the inner ear with three-dimensional (3D) reconstruction revealed a defect in the LSCC, which was characterized by complete coloboma and interruption of the LSCC in proximity to the posterior SCC. However, no other abnormalities were found in other SCCs, vestibule, cochlea, round window, or oval window. The internal auditory canal and cerebellopontine angle were normal [Figure 1d–1f].

Rest and relaxation, symptomatic treatment with vestibular sedatives, and medications to improve blood circulation, nourish nerves, and improve the general well-being were

added. One-year follow-up revealed that the vertigo had almost fully resolved, and tinnitus only occurred due to fatigue or exertion.

The development of the inner ear begins in the 4th week of intrauterine life. The superior SCC is the first to form at approximately 6 weeks of gestation, followed by the posterior and lateral canals. It is the malformation of the LSCC, which is the last one to develop, that occurs most frequently, and this may be explained by such a sequential development model of inner ear embryogenesis.^[1] However, isolated LSCC malformation with a normal vestibular apparatus and cochlea might present challenges to the sequential development theory of the inner ear.

SCC malformations are mostly reported in congenital syndromes with multiple deformities such as coloboma, heart defects, atresia choanae, growth retardation, genital abnormalities, and ear abnormalities syndrome.^[2] Until the first case was reported by Michel *et al.* in 2016,^[3] the complete breach of just one SCC without congenital syndromes remained completely unknown. Hence, SCC malformations are often overlooked and sidelined in cases with such conditions and do not deserve any special mention in literature, especially if the patient is asymptomatic.

The present patient had tinnitus and vertigo but had no hearing loss. Tinnitus and vertigo/dizziness are common complaints encountered by otologists. Although the dizziness experienced by the patient could be explained by SCC dysfunction, it would be impossible to determine whether this dysfunction was due

Address for correspondence: Prof. Jian-Guo Tang, Department of Otolaryngology-Head and Neck Surgery, Sir Run Run Shaw Hospital, Medical College of Zhejiang University, Hangzhou, Zhejiang 310016, China
E-Mail: 3199037@zju.edu.cn

This is an open access article distributed under the terms of the Creative Commons Attribution-NonCommercial-ShareAlike 3.0 License, which allows others to remix, tweak, and build upon the work non-commercially, as long as the author is credited and the new creations are licensed under the identical terms.

For reprints contact: reprints@medknow.com

© 2018 Chinese Medical Journal | Produced by Wolters Kluwer - Medknow

Received: 17-11-2017 **Edited by:** Peng Lyu
How to cite this article: Liu YW, Sun K, Tang JG. Isolated Unilateral Horizontal Semicircular Canal Malformation. Chin Med J 2018;131:743-5.

Access this article online

Quick Response Code:



Website:
www.cmj.org

DOI:
10.4103/0366-6999.226895

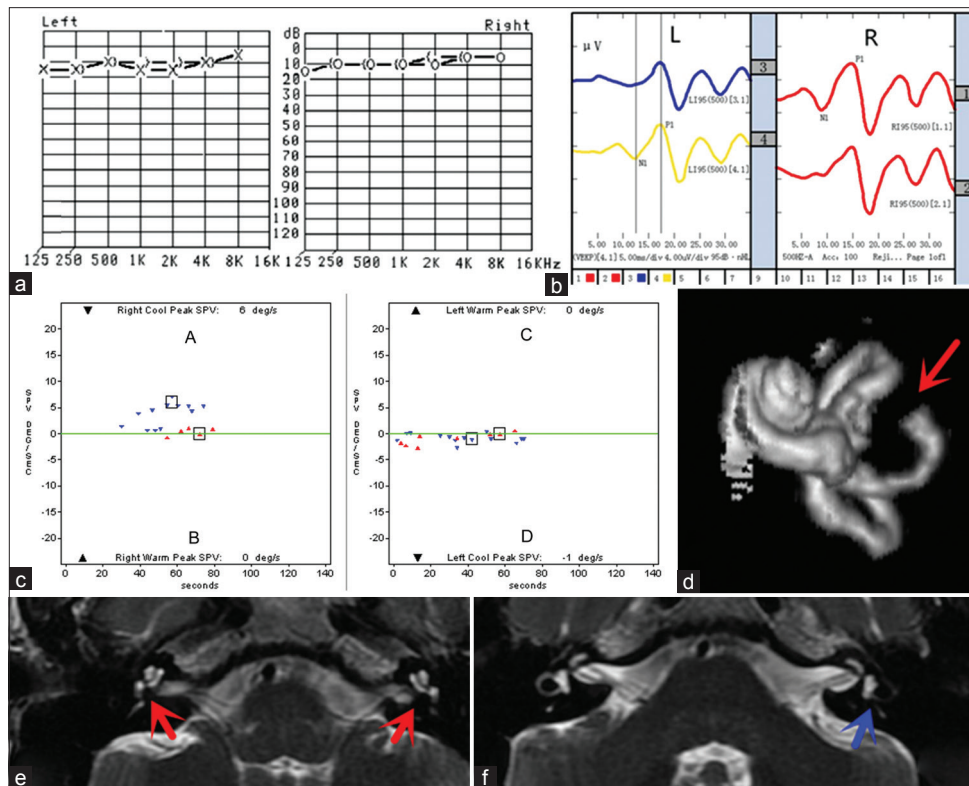


Figure 1: MRI and several functional investigations of isolated malformation of LSCC. (a) Pure-tone threshold audiometry: normal hearing of both ears. (b) VEMP was normal in the bilateral ear. (c) Caloric tests reveal a mild bilateral SCC hypoflexia: (A) right ear with cold air; (B) right ear with hot air; (C) left ear with hot air; (D) left ear with cold air. (d) MRI with 3D reconstruction: the red arrow shows the interruptive deformity of the left LSCC. (e and f) MRI, axial section, T2HR sequence: the red arrows show the bilateral normal cochlea and the blue arrow shows the left defective LSCC. L: Left; R: Right; VEMP: Vestibular evoked myogenic potential; MRI: Magnetic resonance imaging; LSCC: Left semicircular canal; 3D: Three dimensional.

to the SCC malformation or any other lesion since no case that connected dizziness and SCC malformation has been reported to date. The caloric test performed for the patient in the present study demonstrated a weak response for both SCCs although the malformation was unilateral. The absence of hearing loss could be explained by a present research result which indicates that the severity or type of SCC malformation was not correlated with the severity of hearing loss.^[4] In addition, the isolated malformation of SCCs might not affect the process of sound conduction. Thus, we suspected that isolated SCC malformation might not produce hearing loss. As a result, no conclusive evidence could confirm the relationship between the imaging findings and symptoms of the patient. Given the fact that the patient led a healthy lifestyle for nearly five decades, it might be concluded that the rolling movements of amniotic fluid during the fetal period might have led to the acclimatization of rotation and contralateral compensation would develop early, and the presently acquired episode of vertigo might be due to other reasons. Treatment was thereby directed toward the control of the tinnitus and dizziness. The objective of the present case report was to draw attention to the existence of an isolated SCC malformation and its timely detection and further management.

High-resolution computed tomography (HRCT) and MRI allow the accurate detection of inner ear malformations and are

complementary to each other. However, CT is better for imaging bony anatomy, while MRI provides valuable information on the membranous labyrinth, internal acoustic canal, and vestibulo-cochlear nerve. MRI poses no radiation hazard unlike CT. Furthermore, vestibular pathologies diagnosed by both HRCT and MRI are almost similar.^[5] The imaging method might be useful, especially when inner ear malformation is strongly suspected. If the primary complaint of the patient was hearing loss, a CT scan would have been suggested to examine the disease of the middle ear or bony labyrinth.

In large-scale studies with patients that present with tinnitus, hearing loss, or dizziness, the use of MRI with 3D reconstruction, including the internal auditory canal, might be a good idea, to allow for the detection of more such cases and possibly validate these findings.

In summary, the present literature does not satisfactorily describe the relationship between symptom(s), imaging findings, and the pathogenesis of SCC lesions. Hence, empirical and supportive therapy is usually given. However, imaging is crucial for diagnosis and must be combined with the clinical history of the patient, especially the patient's family history and mother's obstetric history. In addition, genetic analysis is also necessary. These would help to determine the treatment and might shed new light on the evolution of this rare and interesting entity, not only

from the clinical standpoint, but also for the purpose of pathophysiology research.

Acknowledgments

The authors would like to thank Dr. W Bo-Zhen for her excellent work in preparing the pure tone audiogram.

Declaration of patient consent

The authors certify that they have obtained all appropriate patient consent forms. In the form, the patient has given her consent for her images and other clinical information to be reported in the journal. The patient understood that their names and initials will not be published and due effort will be made to conceal their identity, but anonymity cannot be guaranteed.

Financial support and sponsorship

Nil.

Conflicts of interest

There are no conflicts of interest.

REFERENCES

1. Jackler RK, Luxford WM, House WF. Congenital malformations of the inner ear: A classification based on embryogenesis. *Laryngoscope* 1987;97(Pt 3) 2 Suppl 40:2-14. doi: 10.1002/lary.5540971301.
2. Wineland A, Menezes MD, Shimony JS, Shinawi MS, Hullar TE, Hirose K, *et al*. Prevalence of semicircular canal hypoplasia in patients with CHARGE syndrome: 3C syndrome. *JAMA Otolaryngol Head Neck Surg* 2017;143:168-77. doi: 10.1001/jamaoto.2016.3175.
3. Michel G, Espitalier F, Delemazure AS, Bordure P. Isolated lateral semicircular canal aplasia: Functional consequences. *Eur Ann Otorhinolaryngol Head Neck Dis* 2016;133:199-201. doi: 10.1016/j.anorl.2015.09.002.
4. Yu KK, Mukherji S, Carrasco V, Pillsbury HC, Shores CG. Molecular genetic advances in semicircular canal abnormalities and sensorineural hearing loss: A report of 16 cases. *Otolaryngol Head Neck Surg* 2003;129:637-46. doi: 10.1016/S0194-59980301593-6.
5. Digge P, Solanki RN, Shah DC, Vishwakarma R, Kumar S. Imaging modality of choice for pre-operative cochlear imaging: HRCT vs. MRI temporal bone. *J Clin Diagn Res* 2016;10:TC01-4. doi: 10.7860/JCDR/2016/18033.8592.