

# Lower Extremity Arteriovenous Fistula Mimicking Deep Venous Thrombosis: A Case Report

Abdullah Alwohaibi<sup>1</sup>, Nashwan Alattab<sup>2</sup>, Mohammed AlSheef<sup>3</sup>

Review began 12/12/2021

Review ended 12/21/2021

Published 12/25/2021

© Copyright 2021

Alwohaibi et al. This is an open access article distributed under the terms of the Creative Commons Attribution License CC-BY 4.0., which permits unrestricted use, distribution, and reproduction in any medium, provided the original author and source are credited.

1. Internal Medicine, King Fahad Medical City, Riyadh, SAU 2. Vascular Surgery, King Fahad Medical City, Riyadh, SAU  
3. Medicine, King Fahad Medical City, Riyadh, SAU

**Corresponding author:** Mohammed AlSheef, malsheef@kfmc.med.sa

---

---

## Abstract

Deep venous thrombosis (DVT) is the most common cause of unilateral lower limb swelling. Common differential diagnosis includes superficial thrombophlebitis and ruptured Baker's cyst. DVT is one of the most common complications diagnosed following lower extremity orthopedic surgery. However, many less frequent causes are often easily overlooked. Here we present a case of a 65-year-old man with a previous hip replacement who developed left-sided progressive leg swelling for years, which was managed initially with anticoagulation for provoked DVT and with compression stockings for post-thrombotic syndrome with no improvement. There was arterialization and spectral broadening of the venous waveform in the Doppler study. Computed tomography angiogram of the lower limbs showed evidence of arteriovenous fistula (AVF) with opacification of the deep left leg veins. Angioplasty and embolization of the fistula resulted in the resolution of leg swelling. We also discussed similar cases found in the literature. AVF needs to be considered in patients presenting with unilateral leg swelling following lower extremity orthopedic surgery.

---

**Categories:** Cardiac/Thoracic/Vascular Surgery, Internal Medicine, Hematology

**Keywords:** unilateral leg swelling, interventional radiology guided embolization, lower extremity dvt, arteriovenous fistula, deep venous thrombosis (dvt)

## Introduction

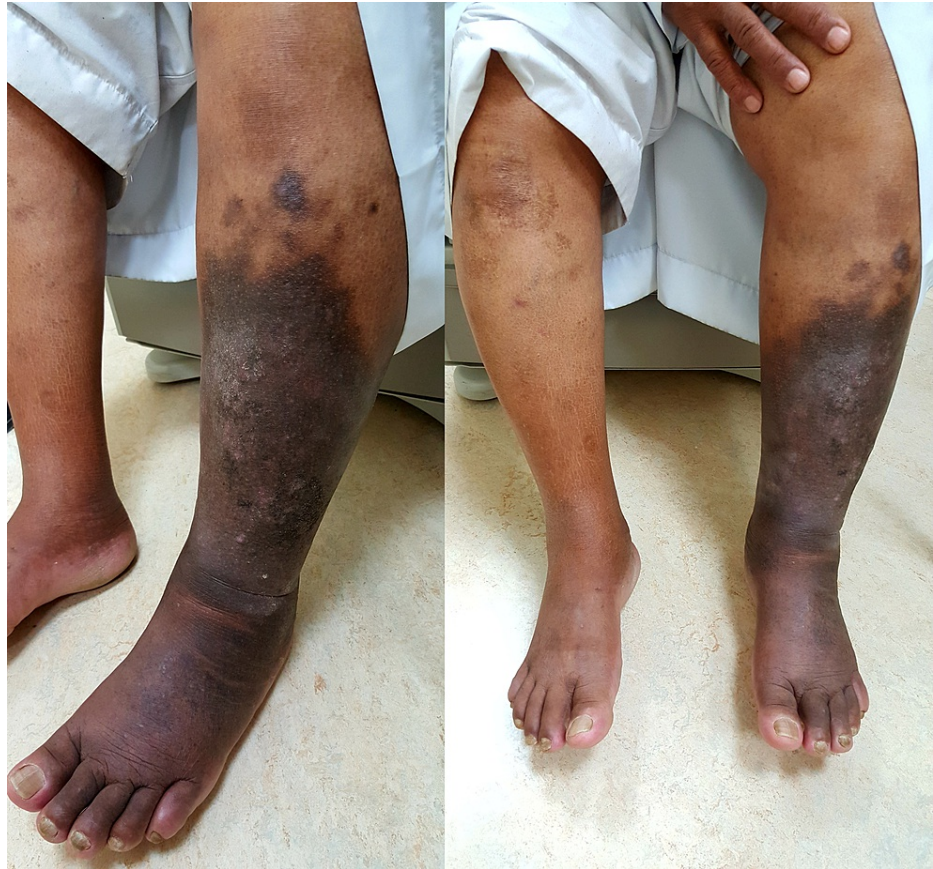Lower extremity deep venous thrombosis (DVT) is one of the most common complications diagnosed following lower extremity orthopedic surgery [1]. Venous thromboembolism occurs in one out of 40 patients undergoing internal fixation after hip fracture [2]. Rarely, arteriovenous fistula (AVF) can complicate orthopedic surgical procedures, causing symptoms similar to DVT [3]. We report a case of AVF masquerading as DVT.

## Case Presentation

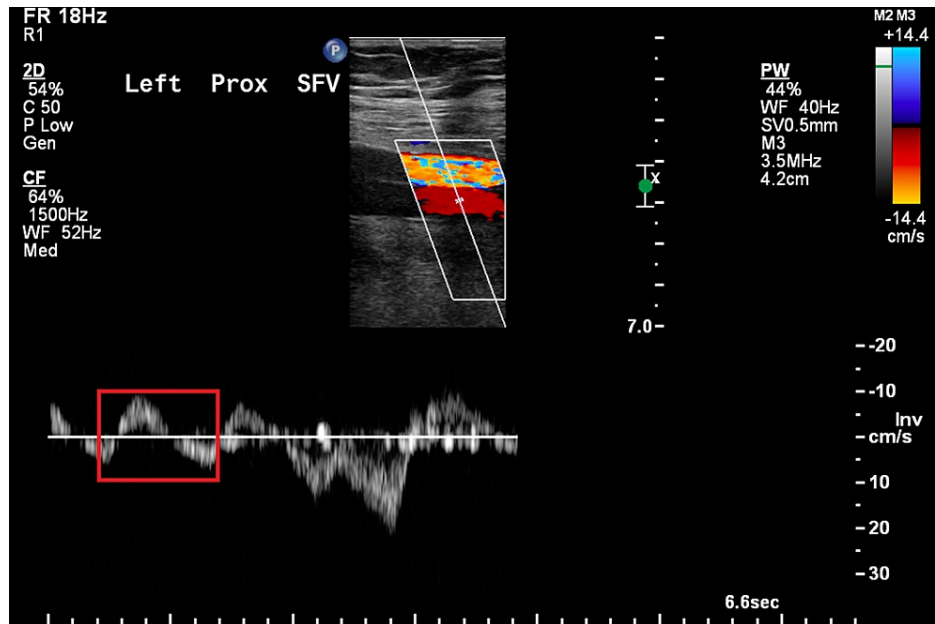
A 65-year-old man with well-controlled type 2 diabetes mellitus and hypertension was referred to our clinic for worsening left leg swelling for one year. He underwent left hip replacement for hip fracture three years before his presentation. He was diagnosed with left leg DVT and treated with oral anticoagulants for three months following his surgery. There was no clear evidence of DVT at that time on review. On examination, his left leg was grossly larger than its counterpart. There was diffuse pitting edema, pigmentation, and lipodermatosclerosis. There were no ulcerations, and pulses were present (Figure 1). He did not have signs of heart failure. We investigated with ultrasonography of the affected limb, and it showed patent and compressible deep veins with an arterialized waveform on Doppler (Figure 2); common femoral vein Doppler showed spectral broadening, indicating turbulent flow. Lymphoscintigraphy revealed no lymphatic obstruction. Computed tomography angiogram of the lower limbs revealed opacification of the left leg venous system in the arterial phase and abnormal vascularity with collaterals (Figures 3, 4). The patient was started on daily compression stockings during work-up with no benefit. The patient underwent a pelvic angiogram that showed a network of communications between the left common femoral artery and common femoral vein, and the median sacral artery and left L5 lumbar artery. Embolization was performed in the left internal iliac artery using coils and Onyx. Next, left common iliac vein (CIV) occlusion was treated with balloon angioplasty, and two stents were inserted. Post-stenting venogram showed patent iliac veins and no collaterals. On follow-up, the patient's left leg edema decreased substantially, improving the patient's quality of life (Figure 5).

### How to cite this article

Alwohaibi A, Alattab N, AlSheef M (December 25, 2021) Lower Extremity Arteriovenous Fistula Mimicking Deep Venous Thrombosis: A Case Report. Cureus 13(12): e20690. DOI 10.7759/cureus.20690

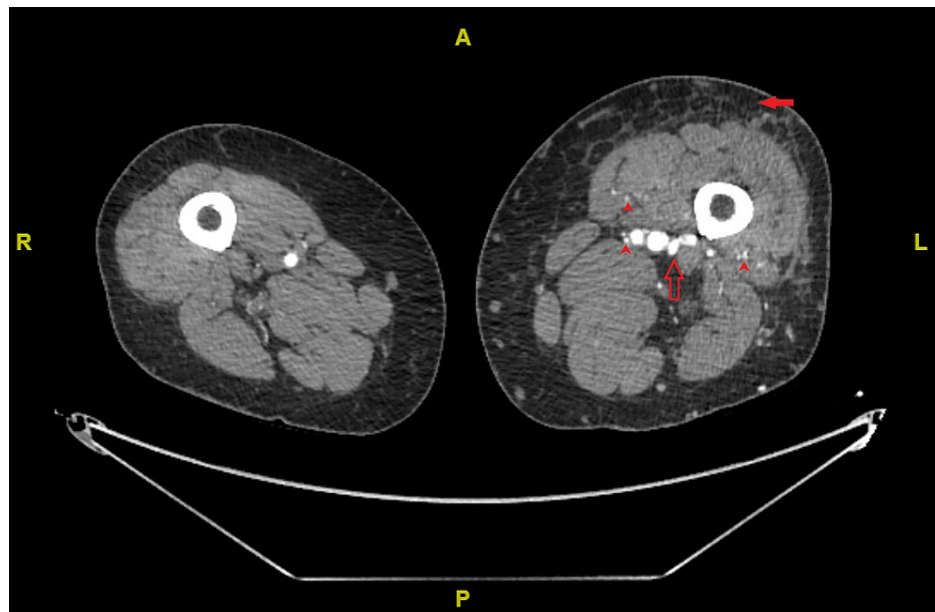


**FIGURE 1: The appearance of the lower limbs on initial presentation showing left leg swelling, marked pigmentation, and lipodermatosclerosis**



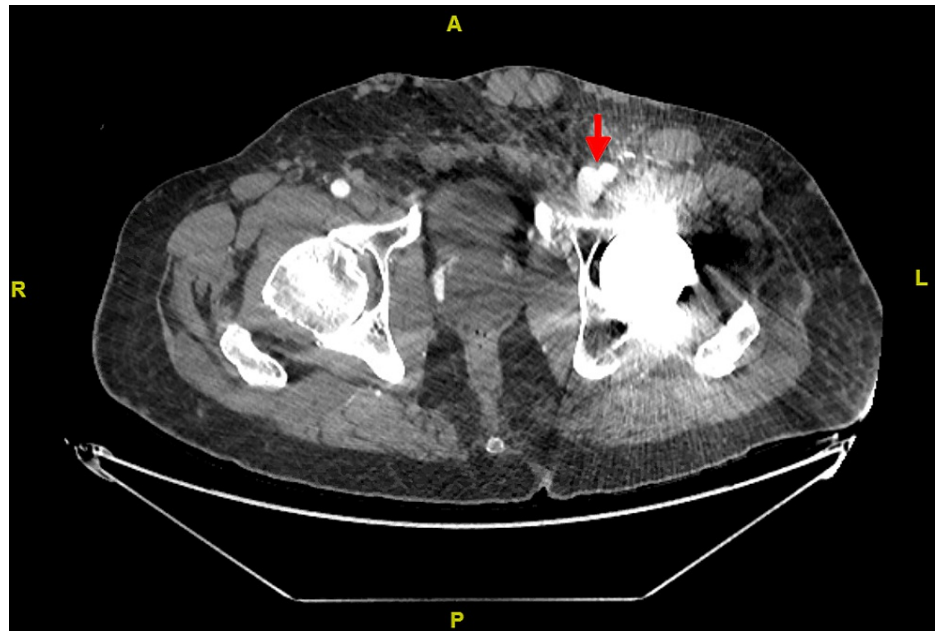
**FIGURE 2: Left proximal superficial femoral vein Doppler showing arterialization of the waveform. Normally, lower extremity vein Doppler shows phasic non-pulsatile waveform.**

Red rectangle indicates biphasic pulsatile waveform, i.e., arterialization of the waveform.



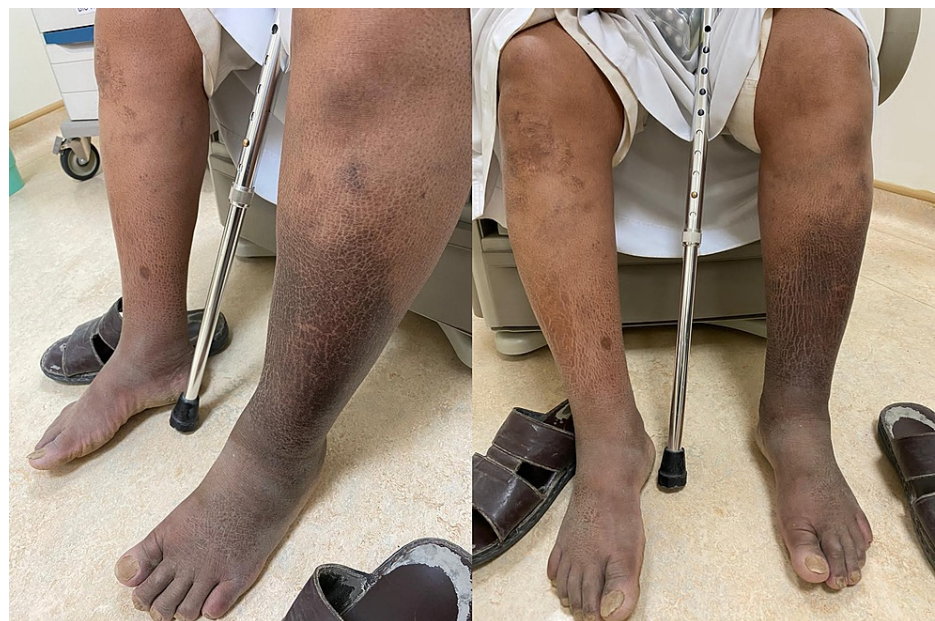**FIGURE 3: Computed tomography angiogram of the lower limbs showing leg asymmetry with opacification of the femoral veins in the arterial phase with substantial subcutaneous edema and formation of collaterals.**

Red-filled arrow indicates subcutaneous edema, red empty arrow indicates opacification of the femoral veins, and red arrowheads indicate opacification of venous collaterals.



**FIGURE 4: Computed tomography angiogram of the lower limbs showing opacification of the left common femoral vein at the level of the femoral head.**

Red arrow indicates opacified left common femoral vein at the level of the femoral head.



**FIGURE 5: The appearance of the left leg following successful embolization and coiling of the arteriovenous fistula. It shows significant improvement in the swelling.**

## Discussion

We searched the literature for similar cases. We found two case reports of patients with no preceding orthopedic surgery presenting with progressive leg swelling and were found to have AVF after clinical suspicion of DVT. One patient developed acute kidney injury due to venous infarction, and the other developed neurological deficits [4,5]. We found several similar case reports with a history of orthopedic surgery. A 40-year-old woman with a one-year history of right leg swelling following laminectomy and

lumbar discectomy was initially diagnosed as DVT on a clinical basis and treated with anticoagulation. However, her symptoms persisted, and later she developed heart failure. The presence of AVF was confirmed, and she underwent vascular surgery complicated by ischemia requiring amputation. Post-operatively, her heart failure resolved [6]. A 91-year-old woman developed extensive left leg DVT following right hip fracture repair; however, her symptoms worsened despite anticoagulation, and she developed superficial ulcerations, cyanosis, and painful toes. She had excellent improvement following the coiling of AVF and stenting CIV [7]. Yuan et al. reported 24 cases of AVF diagnosed after initial diagnosis of DVT not related to previous surgery or trauma. All cases had severe stenosis or occlusion of left CIV, similar to our patient, raising suspicion of a causal relation between DVT and AVF [8].

The main feature common in the case reports we reviewed and our patient is the persistence or progression of symptoms despite adequate anticoagulation after initial diagnosis of DVT. Fortunately, this patient did not develop other complications seen in the reviewed case reports. Thus, lack of improvement with adequate anticoagulation should raise suspicion of alternative diagnoses such as AVF.

## Conclusions

Although DVT is one of the most common causes of leg swelling following lower extremity orthopedic surgery, we have to consider AVF, especially with worsening symptoms despite optimal standard therapy, presence of neurological deficits, heart failure, ulceration, cyanosis, or findings of an arterialized venous waveform on venous Doppler examination.

## Additional Information

### Disclosures

**Human subjects:** Consent was obtained or waived by all participants in this study. **Conflicts of interest:** In compliance with the ICMJE uniform disclosure form, all authors declare the following: **Payment/services info:** All authors have declared that no financial support was received from any organization for the submitted work. **Financial relationships:** All authors have declared that they have no financial relationships at present or within the previous three years with any organizations that might have an interest in the submitted work. **Other relationships:** All authors have declared that there are no other relationships or activities that could appear to have influenced the submitted work.

### Acknowledgements

The authors would like to acknowledge the Research Center, King Fahad Medical City, Riyadh, Saudi Arabia, for the help in editing the final version of the manuscript.

## References

1. Cram P, Vaughan-Sarrazin MS, Wolf B, Katz JN, Rosenthal GE: A comparison of total hip and knee replacement in specialty and general hospitals. *J Bone Joint Surg Am.* 2007, 89:1675-84. [10.2106/JBJS.F.00873](https://doi.org/10.2106/JBJS.F.00873)
2. Fracture fixation in the operative management of hip fractures (FAITH): an international, multicentre, randomised controlled trial. *Lancet.* 2017, 389:1519-27. [10.1016/S0140-6736\(17\)30066-1](https://doi.org/10.1016/S0140-6736(17)30066-1)
3. Barquet A, Gelink A, Giannoudis PV: Proximal femoral fractures and vascular injuries in adults: Incidence, aetiology and outcomes. *Injury.* 2015, 46:2297-313. [10.1016/j.injury.2015.10.021](https://doi.org/10.1016/j.injury.2015.10.021)
4. Jolly EC, Alaeddin F, Farrington K: Aortoiliac arteriovenous fistula masquerading as deep vein thrombosis. *Postgrad Med J.* 2008, 84:643. [10.1136/pgmj.2008.070518](https://doi.org/10.1136/pgmj.2008.070518)
5. Coelho A, Brandão P, Lobo M, Lojo I, Canedo A: Ilio-iliac arteriovenous fistulae-an unusual diagnosis with an even more unusual clinical presentation. *Ann Vasc Surg.* 2018, 50:298.e1-5. [10.1016/j.avsg.2018.01.080](https://doi.org/10.1016/j.avsg.2018.01.080)
6. Teh A, Jeyamalar R, Habib ZA: Arteriovenous fistula simulating deep vein thrombosis as a complication of lumbar disc surgery. *Med J Malaysia.* 1993, 48:440-2.
7. Huynh N, Gates L, Scoutt L, Sumpio B, Sarac T, Ochoa Char CI: May-Thurner syndrome and iliac arteriovenous fistula in an elderly woman. *J Vasc Surg Cases Innov Tech.* 2016, 2:46-9. [10.1016/j.jvsc.2016.02.001](https://doi.org/10.1016/j.jvsc.2016.02.001)
8. Yuan H, Sun J, Zhou Z, Qi H, Wang M, Dong D, Wu X: Diagnosis and treatment of acquired arteriovenous fistula after lower extremity deep vein thrombosis. *Int Angiol.* 2019, 38:10-6. [10.23736/S0392-9590.19.04063-X](https://doi.org/10.23736/S0392-9590.19.04063-X)