

Morphological Study of the Accommodative Apparatus in the Monkey Eye

MARI HIRAOKA,^{1,2*} KENICHI INOUE,² HARUKI SENOO,³
AND MASAHIKO TAKADA²

¹Central Eye Infirmary, 1-24-15 Nukui-kitamachi, Koganei, Tokyo, Japan

²Systems Neuroscience Section, Primate Research Institute,
Kyoto University, Inuyama, Japan

³Department of Cell Biology, Akita University Graduate School of Medicine, Akita, Japan

ABSTRACT

For more than a century there has been debate concerning the mechanism of accommodation—whether the lens capsule or lens material itself determines the functional relationship between ciliary muscle contractility and lens deformation during refractive adaptation. This morphological study in monkey eyes investigates the composition and distribution of several connective tissue components in the accommodative apparatus relaying muscle force to lens organization. Elastin distributes on the marginal surface of the ciliary process. A zonule is composed of fibrillin produced by epithelial cells of the process. In the progress of extension over the posterior chamber, fibrils unite into strands and possess longitudinal plasticity. By induction of the elastin network, strands extend in a concentric direction covering the equatorial region of the capsule. Upon tethering to the lens, the strand ramifies into fibrils, penetrating deeply close to the epithelial layer of the lens and binding with the collagen of the intercellular spaces. Tight linkage of the zonule with the capsule transmits precise contractility. Inside the lens, the cortical layer's elastic connective tissue network forms widely spaced lamellae of crystalline fibers. In contrast, the central nuclear lamellae are tightly opposed. The accumulation of lamellae is greater in the anterior cortex than in the posterior, yielding a more variable anterior chamber depth in the visual axis. The plasticity of the zonule and connective tissue distribution inside the lens produces an adjustable configuration. Thus, tight linkage between the dynamism of the capsule with interaction of the lenticular flexibility provides a novel understanding of accommodation. *Anat Rec*, 298:630–636, 2015. © 2014 The Authors The Anatomical Record: Advances in Integrative Anatomy and Evolutionary Biology Published by Wiley Periodicals, Inc.

Key words: accommodation; zonule; fibrillin; elastin; fibronectin; collagen

This is an open access article under the terms of the Creative Commons Attribution-NonCommercial-NoDerivs License, which permits use and distribution in any medium, provided the original work is properly cited, the use is non-commercial and no modifications or adaptations are made.

Abbreviations used: CB-p = process of ciliary body; FBN = fibrillin; CM = ciliary muscle; ECM = extracellular matrix; EMG = electromyograms.

*Correspondence to: Mari Hiraoka, Central Eye Infirmary, 1-24-15 Nukui-kitamachi, Koganei, Tokyo 184-0015, Japan. Tel.: +81-42-316-1420, Fax: +81-42-387-7900. E-mail: mari9190@true.ocn.ne.jp

Received 13 August 2013; Accepted 21 September 2014.

DOI 10.1002/ar.23100

Published online 18 November 2014 in Wiley Online Library (wileyonlinelibrary.com).

Accommodation is accompanied by precise amplitude changes in the diameter of the anteroposterior axis of the lens in response to ciliary muscle (CM) contraction. The primary stimulus is the sensation of a retinal image, and the efferent pathway then transmits the active motor stimulus to the CM through autonomic nervous innervation. However, understanding the means by which the shape of the lens responds to contraction or relaxation of the CM, and the mechanisms for precisely transforming the lens configuration, is complicated by a lack of innervation within the lens itself.

In 1855 Helmholtz was the first to describe a mechanism for accommodation, although many theories have been proposed since then (Duke-Elder, 1970). The main disagreement in the present theories is whether the elasticity of the lens morphology is due to the lens substance or to the capsule. The Helmholtz theory (or lens theory) is that relaxation of the zonule permits the lens substance to return to a more convex, natural curvature. Another view, the capsular theory of Fincham (1955), is that the relaxation of the zonule makes the elastic capsule more convex. Both schools agree that the zonule acts to alter tension on the mechanical linkage between the CM and lens during accommodation. A variation of the capsular theory holds that the zonule compresses the equator of the lens (Wilson, 1993). Nevertheless, it remains to be determined whether the zonule is capable of changing tension in response to contractility of the CM, thereby causing lens deformation.

The lens contains fibrous networks of elastic extracellular matrix (ECM) around the crystalline fibers, which are composed of mainly collagen and fibronectin. These networks produce the dominant response that allows the lens to withstand tensile and repetitive stresses without rupture (Muiznieks and Keeley, 2013). Zonules are composed of elastic connective tissue, but how this elasticity is associated with the lens substances and with muscle contraction during accommodation is a matter of controversy. Several studies have extensively investigated accommodative physiology and pharmacology in macaque eyes (Glasser and Kaufman, 1999, 2003; Glasser et al., 2006; Croft et al., 2006a, 2009, 2013; Lütjen-Drecoll et al., 2010) and the lens theory has been consistently supported.

We have previously conducted a physiological study on electromyography of the CM using the oculomotor nucleus in the cat (Hiraoka et al., 1989). Then, we followed with morphological studies on the distribution of the ECM (Hiraoka et al., 2002, 2006), intracapsular extension of zonules (Hiraoka et al., 2010) and zonular development in the capsule (Hiraoka et al., 2013) of the monkey eye. The present study provides new morphological characteristics of zonules pertaining to the pattern of tethering between the CM and the lens that relates to mechanisms for accommodation.

MATERIALS AND METHODS

Monkey Eyes

Sixteen eyes were used from adult 7 to 11 year-old monkeys (*Macaca fuscata*) of both sexes and weighing 5.5–7.6 kg. At the completion of a physiological experimentation on the hypothalamic region, the animals were euthanized by systemic perfusion and fixation under

deep anesthesia. Then, the posterior bone was resected and the parieto-posterior brain was removed from the dura mater for histological studies of one of the authors (K.I.). Following this, the optic nerve stalk of both eyes was cut behind the globe and the eyeball was enucleated. The eyes were cut into halves and the anterior segment was used for histology in this study.

All the experiments were conducted according to the Guidelines of the National Institutes of Health Guide for the Care and Use of Laboratory Animals. The Institutional Animal Care and Use Committees of Primate Research Institute, Kyoto University approved the experimental protocols (details are described in Inoue et al., 2012). During the main brain experiment, standard visual tasks pertaining to visual interference were observed and confirmed that the experimental procedure had not disturbed visual function.

Histology

Paraffin sections (6- μ m thick) of 10 eyes were used at random for conventional staining with Hematoxylin-eosin, Masson's Trichrome, Gomori's Aldehyde-fuchsin, Azan' and for immunofluorescence analyses. The cryostat-sectioned (20- μ m thick) specimens of six eyes were used for single or double antibody staining with α -smooth muscle actin, α -elastin, FBN-1, fibronectin and collagen-4. The three-step method was utilized for primary α -smooth muscle actin mouse monoclonal antibody, FBN-1 mouse monoclonal antibody, collagen-4 goat polyclonal antibody, or fibronectin rabbit polyclonal antibody using an avidin-biotin method with Alexa Fluor 488-conjugated streptavidin, followed by α -elastin rabbit polyclonal antibody or fibronectin rabbit polyclonal antibody with Rhodamine 555 (rabbit anti-goat IgG) or propidium iodide (DAPI). Specificity of staining was confirmed by omitting the primary antibody. To activate the reaction of the primary antibody, fixed-on-slide paraffin specimens were treated with microwaves for 15 min and blocked by 1% skim milk in PBS for 1 h. The primary and secondary antibodies and staining substances used in these experiments are listed in Table 1. Details of the method are published elsewhere (Hiraoka et al., 2002, 2013).

Images were examined and photographed using a brightfield and phase contrast microscope (Nikon Eclipse E600), Axioscope (Carl Zeiss) and fluorescent confocal laser microscope (Carl Zeiss, LSM410).

RESULTS

Macroscopic Composition of the Lens and Zonule

Representative examples of structures that were an object of this study and seen in all preparations are shown in the figures (Fig. 1). The lens was situated behind the iris and connected with the ciliary body by the zonules. The shape of the lens was not a simple disc. Instead, the superficial curvature was smoothly convex on its anterior surface, but the posterior surface was more convex in the central region than the periphery, resulting in a wider central horizontal width in the posterior half than in the anterior half (Fig. 1Aa). The visual axis in the anterior segment is the concentric area on the horizontal midline crossing the lens. The

TABLE 1. Materials used for immunofluorescence staining

Primary antibody: 1% cow serum albumin and 2% mouse, donkey, goat, rabbit serum diluted 100 times; incubated 12 hr in 4°C		
Anti-Fibrillin1	Mouse monoclonal	Neomarkers (USA)
Anti- α Elastin	Rabbit polyclonal	Elastin Products (USA)
Anti- α Smooth muscle actin	Mouse monoclonal	Progen Biotech (Germany)
Anti-collagen type IV	Goat polyclonal	Santa Cruz Biotech (USA)
Anti-fibronectin	Rabbit polyclonal	Santa Cruz Biotech (USA)
Secondary antibody: diluted 100 times with phosphate-burred saline and 1% cow serum albumin; kept 45 min in room temperature		
Biotin-conjugated donkey anti-mouse IgG	Jackson Immuno Research (USA)	
Biotin-conjugated mouse anti-rabbit IgG	Jackson Immuno Research (USA)	
Biotin-conjugated rabbit anti-goat IgG	Vector Laboratories (USA)	
Goat anti-rabbit IgG (Fc-specific)	Jackson Immuno Research (USA)	
Fluorescent staining: diluted 100 times with buffered saline; kept 45 min in room temperature		
Alexa Fluor 488 conjugated Streptavidin	Molecular Probe (Netherlands)	
Rhodamine-conjugated rabbit anti-goat IgG	Chemicon International (USA)	
Propidium iodide	Wako Inc (Japan)	

variability of focusing depends upon the distance between the anterior and posterior midpoints of the superficial curvature. The zonules associated with the anterior capsule (a, Fig. 1Ab) were more abundant and thicker than those of the equatorial (e) and posterior (p) capsule (Fig. 1Ac). The lens was composed of a membrane with a single layer of epithelium and multilayered lens fiber lamellae of the lenticular matrices wrapped by the capsule. A single layer of epithelial cells was aligned between the capsule and the lens fiber lamellae. At a specific point in the mid-posterior equatorial region, single nuclei were aligned in an oblique row (Fig. 1B, two small arrows; see also Fig. 3Cb).

Connection of the Zonule Between the Circular Division of Ciliary Smooth Muscle and the Lens Capsule

The structure of these regions is visualized by the immunostaining patterns of α -smooth muscle actin for CM (Alexa 488) and of elastin (Rhodamine) for distribution of connective tissues (Fig. 2A). The CM was composed of longitudinally (CM-l) and circumferentially (CM-c) aligned muscle fibers. The contractile direction of CM-l is centrifugal, whereas the CM-c is centripetal. For lens accommodation, contraction of the CM-c positions the CB-p concentrically toward the anterior apex of the lens. The CB-p did not connect directly with the lens, but instead the ECM components were intercalated. Thus, the contraction of CM-c would bring CB-p indirectly onto the lens by the mediation of the connecting ECM, composed mainly of elastin. Zonules, the principle structures bridging the muscle and lens, were aggregates of fiber strands made of fibrillin (FBN) fibrils (Fig. 2Bb). To facilitate connection of zonules with muscles, elastin was distributed in the surrounding superficial layer of CM-c and internal core of each CB-p (Fig. 2Ba). On the superficial layer of CB-p, the FBN filaments sprouted up from the epithelium, and each fibril united with its neighbors, forming fibers (Fig. 2Bb). These fibers formed bundles throughout the long extension from the CB-p to the lens capsule, traversing the posterior chamber. Flaccid bundles had a transverse striped pattern on their bellies, whereas tensile bundles did not (Fig. 2Bc). On the capsule, zonules ramified into mainly longitudinal and

circumferential branches in the process extending toward the lens (Fig. 2C). Thus, the contractile strength of CM-c was transmitted to the lens indirectly by the mediation of the zonule and associated ECM.

ECM in the Lens Capsule and Epithelial Layer of the Lens

The zonule formed a zonular stalk containing a variable number of bundles on the process extending to the lens capsule in the posterior chamber (Fig. 3A). The stalk divided into bundles near the surface of the capsule and attached superficially (Fig. 3Ba). The bundle ramified into fibers and extended on the lens surface in a concentric direction. In the lens epithelial layer the fibronectin encircled the cells (Fig. 3Ba, Bb) and a network of collagen connected the intercellular spaces between cells (Fig. 3Bc).

The composition of the superficial layer of the lens between the capsule and lens fiber differed with its location. The epithelium in the anterior zone had a layer with uniform cells (Fig. 3Ca), while that in the posterior zone lacked cells (Fig. 3Cc). In the equator, a row of large nuclei aligned in the fiber zone underneath the epithelial layer (Fig. 3Cb). The width of lighter purple staining with aldehyde-fuchsin demonstrated wider interspaces in the anterior fiber zone (Fig. 3Ca) than the posterior zone (Fig. 3Cc), suggesting differences in flexibility.

DISCUSSION

Characteristic Morphology of the Linkage Between CM and the Lens Capsule

We have used histological analysis of each structure related to lens dynamics to investigate the functional morphology underlying the mechanism of accommodation.

The components of the accommodative apparatus that work concomitantly with CM contraction are the coordination between the elasticity of the zonular bundle and the plasticity of the lens fiber laminae. The many zonular fibrils produced by the epithelial cells of the CB-p (Hiraoka et al., 2010) extended to the lens within the aggregated bundles in the posterior chamber. And the zonular bundles were tethered to the lens capsule in a

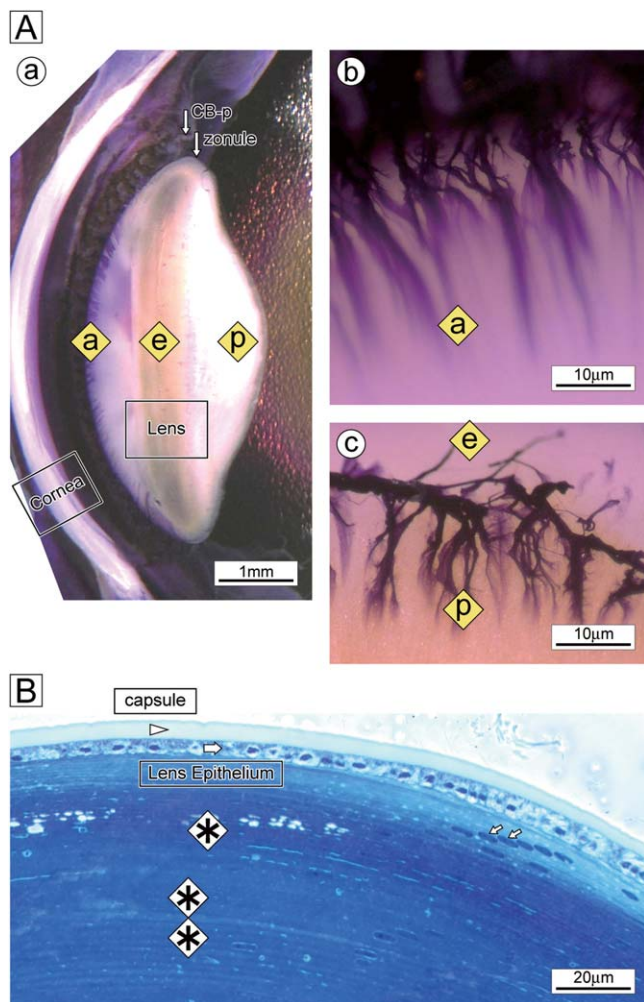


Fig. 1. Orientation of the accommodative components. **A** (a): Stereoscopic view of a sagittal section of adult monkey eye demonstrating the cornea (Cornea), process of the CM (CB-p, upper arrow), zonule (zonule, lower arrow) and lens (Lens) (Aldehyde-fuchsin stain). The shape of the disc lens is different between the anterior (a) and posterior (p) curvature. The anterior curvature is smooth concave, and the posterior curvature shows two steps of central concave with a rather flat peripheral configuration. The width of the middle axis between (a) and (e) is shorter than that between (e) and (p). **A** (b): The anterior zonule attaches to the anterior lens capsule (a) as a thick fan-shaped bundle and diverges in a concentric extension toward the lens apex. The posterior zonule (p) is thinner and shorter than the anterior zonule and sparse in the equator (e). **B**: Sagittal section of the equatorial region of the lens. Zones of the capsule (arrowhead), lens epithelium (large arrow) with nuclear inward alignment (right-to-left) demonstrating the possible process of lens fiber development (small arrows) and fiber lamellae (*) are identified. Interspaces of the newly formed fiber zone of the lens cortex (*) contain wider spaces between lamellae than in the internal zone (double asterisks), where lamellae are closely associated with each other (Trichrome stain).

pattern of fibrils (Fig. 4). The fibrils were connected via components of the ECM, such as elastin (Fig. 2A), fibronectin (Fig. 3Ba, 3Bb), collagen (Fig. 3Bc, Hiraoka et al., 2002, 2010) and laminin (Hiraoka et al., 2013) to the surrounding epithelium of the lens capsule (Fig. 3B).

Elastin acts as a structural lattice over the FBN deposition, thereby determining the direction of zonular fiber

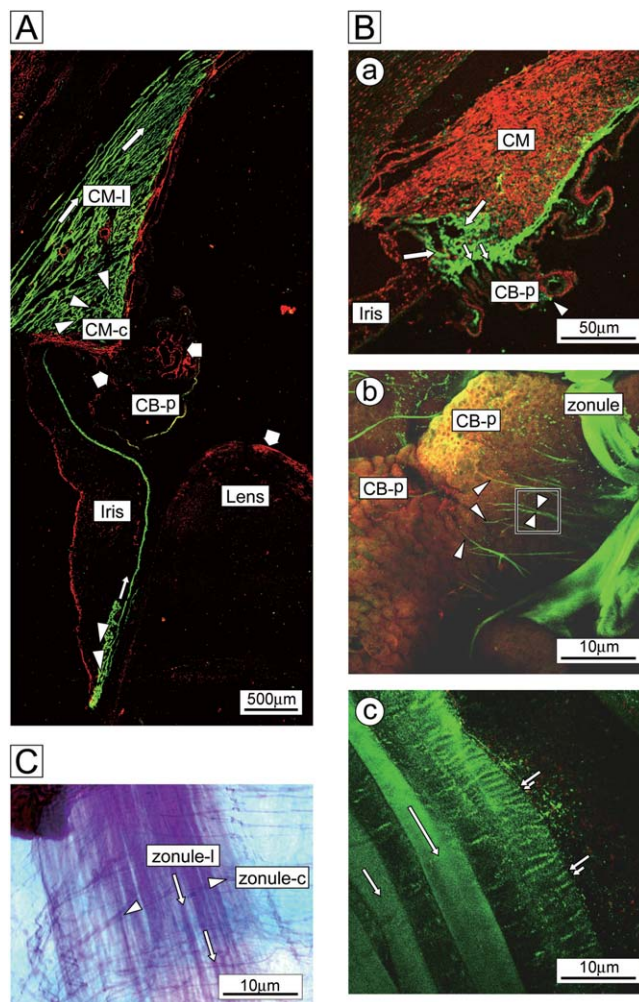


Fig. 2. Linkage of the zonule between lens and CM. **A**: Double immunostaining of α -smooth muscle actin (green) with α -elastin (red) reveals the arrangement of longitudinal (CM-l, long white arrows) and circumferential (CM-c, white arrowheads) muscle fibers. In the iris (Iris), constrictor (direction of constriction shown by the arrowheads) and dilator (by the arrow) muscles are visible near the posterior margin. Elastin surrounds the posterior superficial layers of the CM and distributes on the process of a ciliary body (CB-p) and the lens (Lens) capsule (wide short arrows). **B** (a): Double immunostaining of α -elastin (green) with α -smooth muscle actin (red). Elastin distributes at the CM margins (long arrows), protruding trunks (small arrows) and the superficial layer of the CB-p (arrowhead). **B** (b): Double immunostaining of elastin (red) with fibrillin (green). Fibrillin-stained filaments are tethered to the uneven epithelial surface of CB-p (arrowheads). The filaments unite to form a fibril (boxed area), which, in turn, forms bundles (zonule). Nuclei of the epithelial cells of the processes appear as dots. **B** (c): Immunostaining of fibrillin (green) of zonules. Zonular fascicles in a flaccid fiber are arranged in a horizontal striped pattern (paired arrows) in the muscle belly. In contrast, the tensile fiber is uniform (single arrows). **C**: Conventional staining of zonular fascicles (Aldehyde-fuchsin). The zonule diverges into a bidirectional arrangement of mainly longitudinal (zonule-l, arrows) and fewer circumferential (zonule-c, arrowheads)-branches in the belly of the fascicle in the extension toward the lens.

growth by cross-linkage (Streeten 1982; Kieilty et al., 2001; Sherratt et al., 2001; Kuchtey and Kuchtey, 2014). By this linkage, elastin cores in the stalk of ciliary

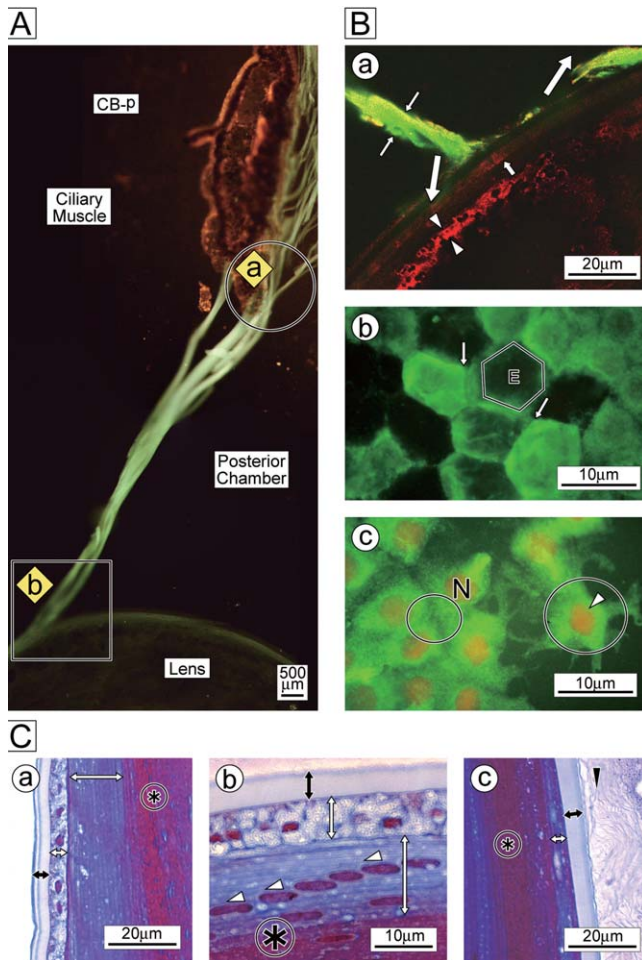


Fig. 3. **A:** Phase-contrast microscopic view of the fascicles of zonular bundles between the CB-p (ciliary body process) and lens (Lens) capsule. The zonules separate from the CB-p (encircled a) and form bundles on the path from the posterior chamber (Posterior Chamber) to the lens capsule (boxed b). The main body of the CM and basal ciliary body process (CB-P) are marked (faintly visible in background) for orientation (Toluidine blue stain). **B:** Immunofluorescent staining of the lens capsule and epithelial cell layer. B (a): A bundle of zonules (fibrillin; green, opposing thin arrows) attaches to the lens capsule and ramifies gradually into fine filaments at its point of termination (large arrows). Fibronectin (red) distributes in the internal layer of the capsule (small arrow) and epithelial cell layer (opposing arrowheads). B (b): The hexagonal epithelial cells (margined as E) bind with surrounding fibronectin (green, arrows). B (c): Collagen-4 (green) connects epithelial cells (small circle). Each epithelial cell has a nucleus (N, arrowhead) and is surrounded by a collagenous net (large circle). **C:** The structure of the capsule, lens epithelium and lens fiber lamellae in the C (a); antero-axial, C (b); mid-equatorial and C (c); postero-axial regions (Aldehyde-fuchsin stain). Lens fibers and the epithelial cell layer are clearly differentiated by the density of purple lamellae and arrangement of nuclei. C (a): The outermost capsular layer (bidirectional black arrow) is double-layered with an intracapsular zonular layer only in the anterior capsule. The epithelium has cells in the anterior [C(a)] and equatorial [C(b)] regions (bidirectional short white arrows), but not in the posterior [C(c)]. The posterior capsule attaches to the vitreous membrane [C(c), arrowhead]. The most prominent feature is the nuclei of newly produced lens fibers aligned obliquely and anteriorly one-by-one. [C(b), arrowheads next to long bidirectional white arrow]. Inside the capsule, the zone of light-purple lamellae contains more elastic ECM than the inner dark red zone [*; C(a), C(b), C(c)].

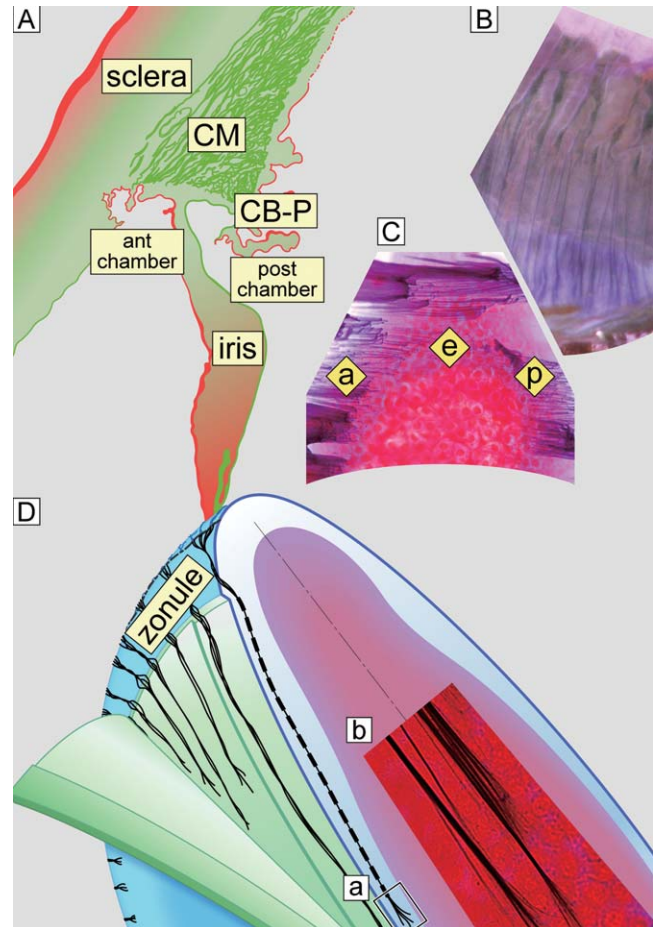


Fig. 4. Diagrammatic orientation and histological images of the morphological organization of the accommodative apparatus. **A:** This diagram shows the relationship between the CM and process of the ciliary body (CB-P). The iris separates the posterior chamber from the anterior ones where the zonule extends to the lens (compare with Fig. 2A). **B:** Stereoscopic view of the zonular tethering pattern with processes of the ciliary body, photographed from the posterior chamber side. Every fold and valley of the processes attaches to the zonule. **C:** A bird's eye view of the equatorial section of the lens shows the attached zonules on the anterior (a), equatorial (e) and posterior (p) zones (surface views are in Fig. 1Ab,Ac). **D:** Schematic diagram of a sagittal-sectioned view of the lens shows the zonular tethering pattern within the layer of the capsule. The lens capsule is peeled back to show different depths. Zonules (black) penetrate the capsule as bundles and separate into fibrils on termination [D(a)]. D(b) Magnified histological image of boxed area [D(a)] shows the innermost broom-shaped untangled filamentous tethering pattern of a zonule within the deep layer close to the epithelial cell layer (margins of an epithelial cell are visible). [Histology B, C, and D(b); Gomori's stain].

bodies cover the FBN mantles, which sprout from CB-p (Fig. 2Bb). This conjugation of FBN with elastin may help reinforce the elastic property of zonules. The plasticity of zonules is clearly visible as the horizontal striped pattern in the longitudinal bellies, mainly in the anterior zonules (Fig. 2Bc). It may be the manifestation of the fact that the lens falls with gravity in vivo regardless of the position of the monkey eye (Glasser and Kaufman, 1999; Croft et al., 2006). A hereditary abnormality of FBN deposition, Marfan syndrome, causes a

paucity of microfibril development in the anterior and posterior lens capsules (Traboulsi et al., 2000). This elastomeric macromolecular structure of zonules has the fundamental function of transmitting the CM contractility to the lens capsule.

The most prominent feature of the zonule is that the ramified fibrils (Fig. 4Db) penetrate deeply and connect with the epithelial cell layer through the mediation of fibronectin (Fig. 3Ba, Bb) and collagen (Fig. 3Bc). The capsule is attached to the lens fiber zone inside by the adhesive molecule laminin (Hiraoka et al., 2013). The final point of linkage between zonules and the capsule is the mesh-like basement membrane of collagen surrounding the epithelial cells (Fig. 3Bc, Muiznieks and Keeley, 2013). Life-long growth of the lens fiber occurs mainly in the anterior half and accumulates in a concentric encircled direction (Figs. 1B and 3Cb, Hiraoka et al., 2006). As a result, the ECM between lens fibers in lamellae is wider in the anterior lens cortex than the posterior cortex (Fig. 3Ca: Cc). Differences between the zonular distribution (Fig. 1Ab) and lens matrix composition account for the shape of the lens being more convex in the posterior than the anterior on radii of curvature in the fixed preparation (Fig. 1Aa). In accommodation the convex curvature of the surface becomes steeper, particularly in the anterior (Croft et al., 2006a). In vivo observations in humans have demonstrated that the width of the lens increases depending on the focusing distance of accommodation, resulting in a decrease of the anterior chamber depth as recorded by three-dimensional Optical Coherence Tomography. Chamber depth is a good index of the accommodative change of the anterior radius of lens curvature. The posterior radius changes slightly (Gambra et al., 2013). This is a well-coordinated manifestation of the in vivo fluctuation of the lens configuration.

The posterior vitreous zonules have been suggested to control the magnitude of centripetal lens movement (Lütjen-Drecoll et al., 2010; Croft et al., 2013). We noted that zonules were distributed mainly in the anterior centripetal directions (Fig. 1Ab); however, zonules at the equator and in the posterior vitreous region were shorter and sparser (Figs. 1Ac and 4C).

We have previously described the development of the lens fiber from a series of specimens in monkey (Hiraoka et al., 2006). Those images suggest that the nuclei of the epithelial cells may have enlarged, diverting from the row of epithelium one by one at the same point in the posterior to sagittal midline. Then the cell could have changed direction toward the fiber zone underneath, converted into a lens fiber cell and accumulated in a layer. These cells have a distinct large nucleus in the center, with the cytoplasm elongated bidirectionally, longer toward the anterior than the posterior arc. These nuclei are lined obliquely in a row on the inward extension in the new fiber zone and they disappear as the lamellar organization develops. Newly produced fibers are more elastic and gradual accumulation into compact lamella might cause them to lose their elasticity, as revealed by the difference in the density of the histological staining (Hiraoka et al., 2006).

The accumulation of lens fibers would make the shape of the lens protrude posteriorly as shown in a sagittal section (Fig. 1A). Compaction of lamellae would result in loss of the connective tissue interspaces, resulting in

decreased plasticity in the anteroposterior axis during accommodation. In addition to changes in CM function with age (Croft et al., 2006a), the amplitude of the flexible width of the anteroposterior axis may decrease with age due to the successive accumulation of lens fibers (Hiraoka et al., 2006). As a result, the intralenticular plasticity may bring about age-related loss of accommodation, "presbyopia."

Relationship Between the Morphology and Physiological Studies

Accommodation is a highly organized sensory-motor interaction between the brain and the eye. The circumferential CMs work with iris constrictor muscles concomitantly to provide the "near reflex." Our study in cats obtained evoked electromyograms (EMG) from both muscles with electrical stimulation of the Edinger-Westphal (E-W) and anteromedian nuclei. The responses were spike waves followed by long refractory periods on both muscles. The EMG did not follow repetitive stimulation for frequencies over 1 Hz. (Hiraoka and Shimamura, 1989). Physiological studies have been carried out on the accommodative refractive changes and the movements of the accommodative apparatus in monkey (Glasser and Kaufman, 1999, 2003; Glasser et al., 2006; Croft et al., 2006a, 2009). A stimulating train of pulses (72 Hz: Glasser et al., 2006, Ostrin and Glasser, 2007 and 100Hz: Croft et al., 2006a) applied to the Edinger-Westphal (E-W) nucleus caused a refractive change of maximum amplitude 20 (Croft et al., 2006a) and 7 (Ostrin and Glasser, 2007) diopters as recorded by refractometry (Glasser et al., 2006; Ostrin and Glasser, 2007). In addition, gonioscopic observation of the ciliary processes detected centripetal movement during stimulation (Glasser et al., 2006; Ostrin and Glasser, 2007; Croft et al., 2006a, 2009).

Discrepancies of results from repetitive electrical stimulation may depend on intrinsic differences in the nature of the muscle between the two species, and also on the method of detection, namely direct observation versus EMG. The contractile dynamics are further confused by the pharmacological reaction to the different receptor subtypes (Kaufman PL, 1992). In vitro experiments with isolated muscle strips of the ciliary body from a human eye demonstrated a dual sympathetic and parasympathetic nerve supply (van Alphen, 1976). We also found α -1 adrenergic receptors of the circumferential CM in cats (Hiraoka et al., 2002). Nevertheless, during accommodation, linkage of autonomic innervation with smooth muscle contraction causes deformation of the lens, which itself lacks muscle or nerve, and it does so in a graded manner.

Therefore the organization and content of the connective tissue components play fundamental roles in the production of zonular elasticity and lens plasticity. This is a departure from the traditional lens or capsule theories of accommodation. Therefore, we propose a new theory related to the dynamism of connective tissue elements working together to link the ciliary process-zonule-lens complex as a mechanism of accommodation.

ACKNOWLEDGEMENTS

The authors thank Teiko Kurada, Naosuke Kojima, and Michiko Imanishi for their technical assistance in

histological analysis. The authors express thanks to Professor Jonathan C. Makielski, University of Wisconsin-Madison, for reading and commenting on the manuscript.

LITERATURE CITED

- Croft MA, Glasser A, Heatley G, McDonald J, Ebbert T, Dahl DB, Nadkarni NV, Kaufman PL. 2006a. Accommodative ciliary body and lens function in rhesus monkeys: normal lens, zonule and ciliary process configuration in the iridectomized eye. *Invest Ophthalmol Vis Sci* 47:1076–1086.
- Croft MA, McDonald JP, Nadkarni NV, Lin T-L, Kaufman PL. 2009. Age-related changes in centripetal ciliary body movement relative to centripetal lens movement in monkeys. *Exp Eye Res* 89:824–832.
- Croft MA, McDonald J, Katz A, Lin TL, Lütjen-Drecoll E, Kaufman PL. 2013. Extralenticular and lenticular aspects of accommodation and presbyopia in human vs. monkey eyes. *Invest Ophthalmol Vis Sci* 54:5035–5048.
- Duke-Elder S. 1970. Ophthalmic optics and refraction. System of ophthalmology. Vol. V. London: Henry Kimpton. p 153–183.
- Fincham EF. 1955. The proportion of ciliary muscular force required for accommodation. *J Physiol* 128:99–112.
- Gambra D, Ortiz S, Perez-Merino P, Gora M, Wojtkowski M, Marcos S. 2013. Static and dynamic crystalline lens accommodation evaluated using quantitative 3-D OCT. *Biomed Opt Exp* 1:1595–1609.
- Glasser A, Kaufman PL. 1999. The mechanism of accommodation in primates. *Ophthalmology* 106:863–872.
- Glasser A, Kaufman PL. 2003. Accommodation and presbyopia. Kaufman PL, Alm A, editors. *Adler's physiology of the eye. Clinical application*. 10th ed. St. Louis, USA: Mosby. p 197–233.
- Glasser A, Wendt M, Ostrin L. 2006. Accommodative changes in lens diameter in rhesus monkey. *Invest Ophthalmol Vis Sci* 47:278–286.
- Hiraoka M, Shimamura M. 1989. The midbrain reticular formation as an integration center for the 'near reflex' in the cat. *Neurosci Res* 7:1–12.
- Hiraoka M, Kojima N, Senoo H. 2002. Immunohistochemical study of the extracellular matrices related to accommodation in monkeys. *J Jap Ophthalmol Soc* 106:565–573.
- Hiraoka M, Kojima N, Masuda Y, Senoo H. 2006. Morphological study of the crystalline lens in monkeys. *J Jap Ophthalmol Soc* 110:370–378.
- Hiraoka M, Inoue K, Ohtaka-Maruyama C, Ohsako S, Kojima N, Senoo H, Takada M. 2010. Intracapsular organization of ciliary zonules in monkey eyes. *Anat Rec* 293:1797–1804.
- Hiraoka M, Kuroda T, Inoue K, Senoo H, Takada M. 2013. Developmental anatomy in the zonular connection with lens capsule in macaque eye. *Anat Rec* 296:726–735.
- Inoue K, Koketsu D, Kato S, Kobayashi K, Nambu A, Takada M. 2012. Immunotoxin-mediated tract tracing in the primate brain: selective elimination of the cortic-subthalamic "hyperdirect" pathway. *PLoS One* 7:e39149.
- Kaufman PL. 1992. Accommodation and presbyopia: Neuromuscular and biophysical aspects. Hart WM, ed. *Adler's physiology of the eye. Clinical application*. St. Louis, Missouri: Mosby Year Book. 9th ed. p 391–411.
- Kielty CM, Sherratt MJ, Shuttleworth CA. 2002. Elastic fibres. *J Cell Sci* 115:2817–2828.
- Kuchtey J and Kuchtey RW. 2014. The microfibril hypothesis of glaucoma: implication for treatment of elevated intraocular pressure. *J Ocul Pharmacol* 30:170–180.
- Lütjen-Drecoll E, Kaufman PL, Wasielewski R, Ting-Li L, Croft MA. 2010. Morphology and accommodative function of the vitreous zonule in human and monkey eyes. *Invest Ophthalmol Vis Sci* 51:1554–1564.
- Muiznieks LD, Keeley FW. 2013. Molecular assembly and mechanical properties of the extracellular matrix: a fibrous protein perspective. *Biochim Biophys Acta* 1832:866–875.
- Ostrin L, Glasser A. 2007. Edinger-Westphal and pharmacologically stimulated accommodative refractive changes and lens and ciliary process movement in rhesus monkeys. *Exp Eye Res* 84:302–313.
- Sherratt MJ, Wess TJ, Baldock C, Ashworth JO, Purslow PP, Shuttleworth CA, Kielty CM. 2001. Fibrillin-rich microfibrils of the extracellular matrix: ultrastructure and assembly. *Micron* 32:185–200.
- Streeten BW. 1982. The nature of the ocular zonule. *Trans Am Ophthalmol Soc* 80:823–854.
- Traboulsi E, Whittum-Hudson JA, Mir SH, Maumenee IH. Microfibril abnormalities of the lens capsule in patients with Marfan syndrome and actopia lentis. *Ophthalmic Genet* 2000. 21:9–15.
- van Alphen G.W.H.M. 1976. The adrenergic receptors of the intraocular muscle of the human eye. *Invest Ophthalmol* 15:502–505.
- Wilson RS. 1993. A new theory of human accommodation: ciliozonular compression of the lens equator. *Trans Am Ophthalmol Soc* 91:401–419.