



## Breast biopsy navigation system with an assisted needle holder tool and 2D graphical user interface

Jackrit Suthakorn<sup>a,\*</sup>, Narucha Tanaiutchawoot<sup>a</sup>, Cholatip Wiratkapan<sup>b</sup>, Songpol Ongwattanakul<sup>a</sup>

<sup>a</sup> Center for Biomedical and Robotics Technology (BART LAB) Department of Biomedical Engineering, Faculty of Engineering, Mahidol University, Salaya, Thailand

<sup>b</sup> Breast Diagnostic Center, Division of Diagnostic Radiology, Department of Radiology, Faculty of Medicine, Ramathibodi Hospital, Mahidol University, Bangkok, Thailand

### ARTICLE INFO

#### Keywords:

Breast biopsy navigation system  
Graphical user interface (GUI)  
Optical tracking device  
Assisted needle holder tool  
Ultrasound image

### ABSTRACT

**Objective:** This paper proposes the development of a breast biopsy navigation system with an assisted needle holder tool for a coaxial needle and a graphical user interface, which utilizes an optical tracking device to localize the needle position relative to the ultrasound image with the aim to improve performance especially for a new radiologist or an inexperienced group.

**Materials and methods:** The system consists of an assisted needle holder tool, which as an attachment for the 2D ultrasound transducer and the graphical user interface (GUI) that shows the needle pathway, needle line and warning signs. An optical tracking system is used to track the needle motion, ultrasound image and transform all information to with respect to the technique. The system is evaluated using a phantom made from gel candle. There were nine experienced and eight inexperienced participants who performed the breast biopsy intervention, using three methods: the freehand method, only the needle holder tool guidance, and the whole navigation guidance (GUI + assisted needle holder).

**Results:** The results demonstrate a success rate of over 90% using only assisted needle holder and the whole system to perform breast biopsy for the experienced and inexperienced groups, whereas for the inexperienced group a success rate of 57.5% was achieved using the freehand method. The use of only assisted needle holder for breast biopsy reduces the time for a procedure in the inexperienced group by 6 s when compared to the freehand method.

**Conclusion:** The authors believe that this navigation system can be applied in a clinical setting and give an advantage to inexperienced radiologists who must successfully perform clinical breast biopsy.

### 1. Introduction

Percutaneous imaging-guided core needle biopsy (CNB) for suspicious breast lesions is a standard diagnostic tool for tissue characterization [1–4]. Ultrasound plays an important role for a real-time breast biopsy [5] and has various other applications, such as carotid artery [6,7]. As the system allows for real-time guidance, no ionizing radiation is required [8], the procedure is inexpensive and it is comfortable for the patient [9–11]. The radiologist uses one hand to hold the ultrasound transducer to scan for suspicious lesions and the other hand is used to perform needle insertion, while the patient lies in a supine or decubitus position [9]: this is referred to as the free-hand technique.

The ultrasound probe is covered with a plastic bag to avoid infections then a coaxial needle is inserted towards the target before using the biopsy needle to avoid scars from multiple needle insertion.

However, the advance of technology and knowledge allow no infection and successful treatment with the covered probe and an uncovered probe [10]. The success of a core needle biopsy to examine breast lesion depends on the accuracy of the diagnostic. High accuracy of the diagnostic leads to high proficiency treatment planning and low sampling error [3]. False negative is an important concern for core needle biopsy because it leads to inappropriate treatment causing the patient to suffer from re-biopsy or re-operation. For 14-gauge (G) CNB under US, the success rate is about 96% [4,12]. The false negative rate is around 2% (1.6 [4], 2.4 [12]). Even ultrasound guided breast biopsy is a conventional method for breast biopsy, difficulties of needle guidance in 2D image is a major problem.

The radiologist needs to control the needle within the ultrasound plane for visualizing the needle. Moreover, the needle has to parallel to the patient's chest wall to avoid chest wall puncture. This procedure is

\* Corresponding author.

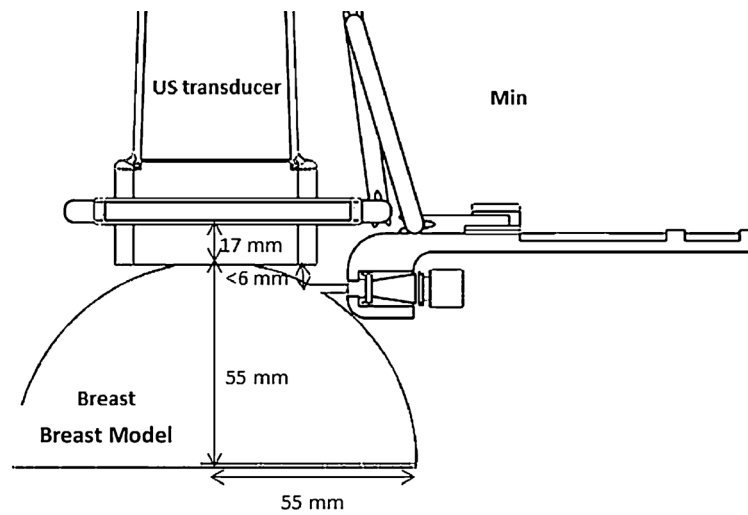
E-mail addresses: [jackrit@bartlab.org](mailto:jackrit@bartlab.org), [jackrit.sut@mahidol.ac.th](mailto:jackrit.sut@mahidol.ac.th) (J. Suthakorn), [narucha@bartlab.org](mailto:narucha@bartlab.org) (N. Tanaiutchawoot), [cholatip.wir@mahidol.ac.th](mailto:cholatip.wir@mahidol.ac.th) (C. Wiratkapan), [songpol.ong@mahidol.ac.th](mailto:songpol.ong@mahidol.ac.th) (S. Ongwattanakul).

<https://doi.org/10.1016/j.ejro.2018.07.001>

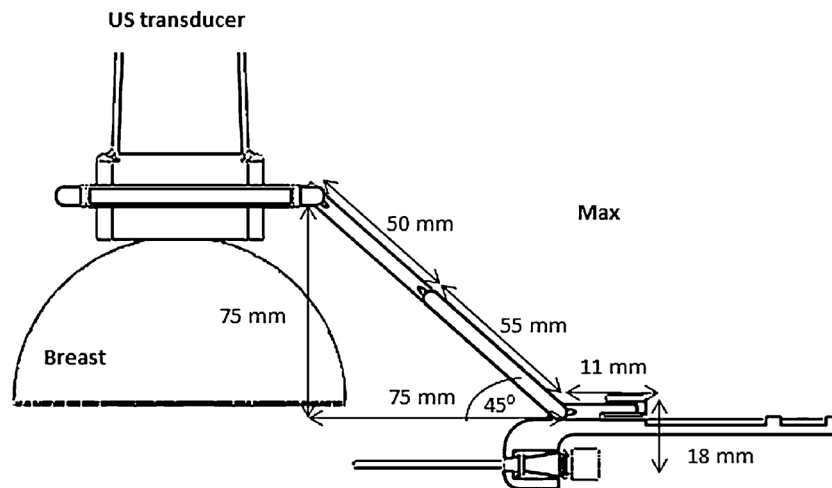
Received 30 March 2018; Received in revised form 20 June 2018; Accepted 2 July 2018

Available online 18 July 2018

2352-0477/ © 2018 Mahidol University, Salaya, Nakhon Pathom, Thailand. Published by Elsevier Ltd. This is an open access article under the CC BY-NC-ND license (<http://creativecommons.org/licenses/by-nc-nd/4.0/>).



(a)



(b)

Fig. 1. (a) minimum and (b) maximum of workspace of assisted needle holder design.

difficult and requires a substantial amount of experience from the radiologist. Improper needle localization within the ultrasound plane can affect the procedure times and needle position accuracy [13]. Some research groups [5,14,15] have developed breast biopsy navigation system in the prone position with different type of modalities; however, these approaches consume a lot of time to setup and are uncomfortable for the patient. Augmented reality system [16] has been developed to display the ultrasound plane during needle insertion, which is similar to an optical needle guidance [17] and displays a line along the patient's skin. An optical needle guide [18] and clear guide one also use camera, mounted on an ultrasound probe, to localize a needle alignment relative to the ultrasound plane.

The result of the needle alignment will be displayed on the ultrasound image. However, all of the above mentioned about problems in intervention technique associated with the control needle alignment in the ultrasound plane and with the hand eye coordination between image guidance system and the biopsy tools such as the needle and the ultrasound probe. This problem has been solved by a mechanical

guidance device attached to the ultrasound transducer to control needle alignment with respect to the ultrasound image for every movement. A few companies have developed a guidance device for the biopsy procedure by fixing the angle of needle insertion within the ultrasound view. A rotary wheel needle-guide on a bracket which is attached to an ultrasound transducer [19] has been developed to move the needle without fixing the angle, but the position of the needle during movement is still a problem. A two planar linkage with 2D guidance system has been developed with the magnetic rotary sensors to detect the angular displacement [20]. This system is tested and compared between an experienced and inexperienced radiologist group [21], which shows high accuracy and lower procedure time. However, the device cannot be sterilized because of its complex structure.

This article proposes a breast biopsy navigation system with an assisted needle holder tool for a coaxial needle and a graphical user interface, which utilizes an optical tracking device to localize the needle position relative to the ultrasound image. Tool tip calibration [22,23] and ultrasound calibration have been performed before starting the

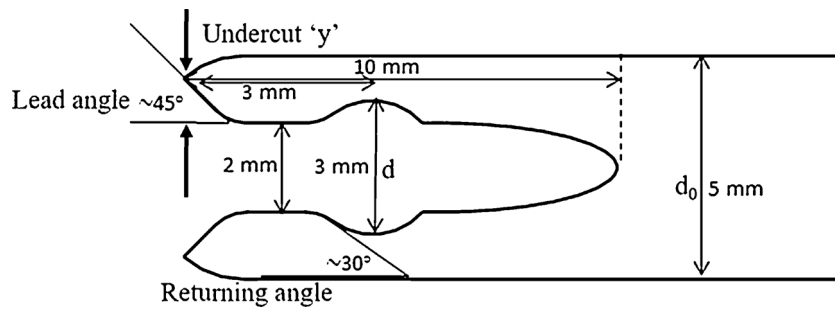


Fig. 2. Annual snap fit design for revolute joints.

guidance system. Assisted needle holder tool controls the needle alignment within the ultrasound plane with a simple structure, which can be sterilized. Needle insertion is overlaid on the ultrasound image with 3-guidance line in different color. The distance and the angle between the needle tip and the target are presented with the number and sign. Success rate and procedure time with and without using this system are evaluated by both experienced and inexperienced participants.

2. Materials and methods

The institutional review board approved the study. Informed consent was waived.

2.1. Participants

Participants in the study were categorized in two groups. The experienced group consists of nine board-certified radiologists with training in body intervention and experience in image-guided CNB ranging from 2 to 15 years. The inexperienced group consists of 5 residents in radiology (year 1 to 3) and 3 radiation technologists.

2.2. Ultrasound and equipment's

US-guided CNB is performed using the freehand technique and a high-resolution US unit with 5-12-MHz linear-array transducer (iU22, Philips Advanced Technology Laboratories, Bothell, WA, U.S.A.) CNB obtained using a long-throw (22 mm.), 14-guage cutting needle (MDTECH; Gainesville, FL, USA) with an automated biopsy gun (Magnum; Bard peripheral technologies, Covington, GA, U.S.A.)

2.3. Assisted needle holder tool

Assisted needle holder tool is designed to attach with the US transducer. A coaxial needle with a 2 mm in diameter, is used before biopsy needle, is attached to this guidance assisted needle holder. If the coaxial needle can reach the target, a biopsy needle is also inserted towards the target and any changes in direction relate to the coaxial needle and lesion position. The structure of this assisted needle holder is a planar system, which lies on the same ultrasound-scanning plane. This helps control the needle alignment in plane to an ultrasound-scanning plane and reach on the target. Depths of ultrasound machine start at 2.5 cm–8 cm, and the standard breast size in diameter is approximately 110 mm. The minimum and maximum workspaces of this assisted needle holder are as shown in Fig. 1.

The needle holder tool is designed without a locking mechanism because a lesion is moveable during needle insertion. This phenomenon is occurred because human breast consists of fat that is deformable. The position of lesion is changed related to the outer force. Hoop-strain technique is utilized for each joint to hold into place and assist adjustment in fine adaptation. Plastic is an appropriate material for hoop-strain technique, which is the expansion of the circumference of the

more elastic piece as it is pushed onto the more rigid piece. This material is usually applied in the snap fit joints design. The details of snap fit technique design will be described in the following section. Moreover, gaseous chemicals can sterilize this material, which is a conventional method for the sterilization of a medical device. ABS plastic is chosen to form this needle holder tool using 3D machine printing.

The design of the joints is called the snap fit method. Snap fit is a simple, economical and rapid way for connecting two links. The links are either separable or inseparable depending on the undercut (snap fit height) design. Transverse force and mating force are also important factors to the design with the assignment of an appropriate force for separation. All parameters are calculated to design this needle holder tool and form separable components for sterilization and assembly. Mating force is the last parameter to calculate after finding appropriate value in the following equation:

$$W = y * d * Es * 0.62 \frac{\sqrt{\left(\frac{d_0}{d} - 1\right) \left(\frac{d_0}{d} + 1\right)}}{\left[\left(\frac{d_0}{d}\right)^2 + 1\right] + \nu} * \frac{\mu + \tan \alpha}{1 - \mu \tan \alpha}$$

Where *W* is the mating force, *y* is the snap fit height, *d* is the diameter at a joint, *Es* secant modulus, *d<sub>0</sub>* external diameter of the tube, *μ* friction coefficient and *α* lead angle

*Es* and *μ* are constant values depending on a material; *d* and *α* are assumed to be a constant of 3 mm, which is related to the shaft diameter of 5 mm. and 45 degrees of angle for a suitable lead angle. Therefore, *y* and *d<sub>i</sub>* have been adjusted to produce an appropriate mating force as shown in Fig. 2. The hollow's depth should be lower than 1.8 √*d* \**t*, where *d* is the joint diameter and *t* is the wall thickness, to avoid a triple force. Thus, the distance of the hole from the end of the tube is 3 mm. The undercut and thickness have been adjusted to be 1.5 mm. and 1 mm. to increase elasticity and still allow locking of the shaft at the hole position during rotation without any support. The returning angle is around 30 degrees angle with filleted edges to create a curve that is easier for attaching and detaching the links. If the returning angle is too high, the components are difficult to detach. If the returning angle is too low, the components will slip out from the hole. All revolute joints as shown in Fig. 2 were designed using snap fit technique.

There are 7 parts in the needle holder tool design. Probe mounting (1), which is attached to the ultrasound probe. The reference marker attached on the marker probe (2) a locking part with ladder phantom (3) is used for ultrasound calibration procedure. There are three linkages (4, 5, 6) to move in the planar plane. The last linkage is connected with the coaxial needle attachment (7). All components are shown in Fig. 3(a), and the prototype of this assisted needle holder tool, attached to an ultrasound transducer, is shown in Fig. 3(b).

The optical tracking device (*NDI Polaris*) is used to localize the lesion position from the ultrasound image and needle holder tool position. There are two passive markers on the needle holder tool: the marker for the ultrasound transducer and the marker for the coaxial


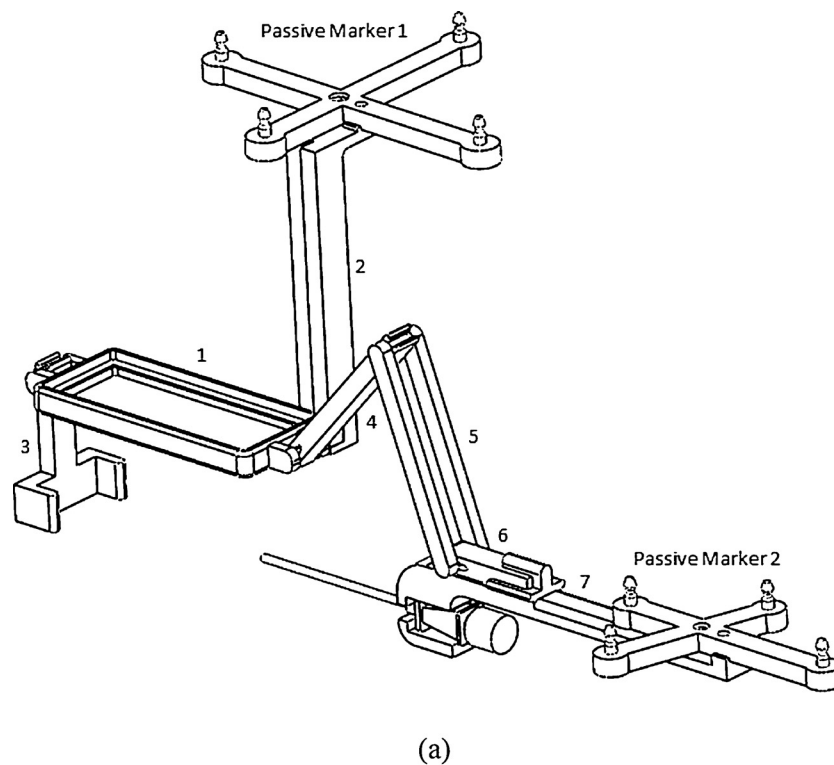


Fig. 3. (a) the components and (b) the prototype of the assisted needle holder.

needle. These markers are attached to the needle holder tool to maintain the same orientation, which allows for easier determination of the ultrasound calibration and tool tip calibration. The first marker is set to be the reference coordinates in this system. Ultrasound calibration is a procedure that is used to find the relationship between the passive marker attached on the ultrasound transducer and the origin of an ultrasound image. The information in the ultrasound image is converted into the optical tracking coordinate system. Tool tip calibration is another procedure used to find a relationship between the passive marker attached on the needle and the needle tip, so the position of needle tip is known in the optical tracking coordinate system.

#### 2.4. Graphical user interface (GUI)

The image guidance displays a trajectory path to a user before

starting a needle insertion. The trajectory path between the lesion and the entry point, needle orientation and needle line are overlaid on the real-time ultrasound image as shown in Fig. 4. This figure is captured from the ultrasound machine through a video capture card (AVerMedia AVerTV Volar go). The small dotted line (No.1) represents the trajectory path that is shown after choosing the breast lesion. The big dotted line (No.2) represents the needle orientation which shows a reality of needle's movement by the user. This line should be controlled to lie on the same path as the trajectory path before needle insertion. Therefore, the needle orientation is roughly set from outside the breast to reduce tissue damage. The end of this point is called an entry point. The white line is the simulated needle, which represents the real needle.

There are four components in the graphical user interface within the breast biopsy navigation system, which are shown in Fig. 5. The navigation system consists of an instruction panel, ultrasound depths,

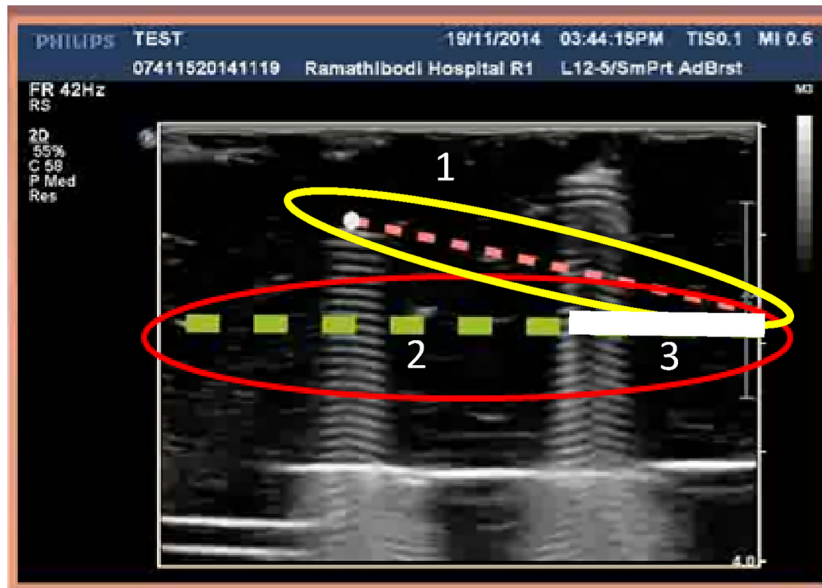


Fig. 4. Guidance image for needle insertion with the trajectory path (1), needle orientation (2) and simulated needle (3).

ultrasound image guide and a navigation mode.

The instruction panel uses the angle and distance between the real coaxial needle and the target and shows a green light when the error is lower than absolute one degree and 1 mm. (*acceptable error*) respectively. Warning sign is displayed to warn the user when the markers from each device are not in the workspace. This warning sign consists of a status of the marker on the ultrasound transducer, the marker on the coaxial needle and the needle alignment with respect to the ultrasound plane. The ultrasound depths are selected relative to the actual depths in an ultrasound machine before starting the breast biopsy navigation system. The system will automatically adjust the guidance image to fit with the real ultrasound image. The final part is a navigation mode, in which the user can choose to turn on or off the navigation mode depending on the purpose or their experience.

The breast phantom, in this study, is made of a gel candle (95% mineral oil and 5% polymer resin) in a hemisphere shape, which is 110 mm. in diameter embedded with many breast lesions made of clay in the range of 15–20 mm. in diameters. These range of diameters are in the ranges of visible diagnosis and examination in the clinical application. Even a texture of clay is not definitely similar to real lesion and possible to have a shadow in the ultrasound image, but the thickness of this shadow was lower than 2 mm. and did not influence decision-making from the radiologist. This phantom is for system tests and the evaluation of system performance. This phantom is covered by a black plastic bag, so the user cannot see the target (lesions) in the breast phantom. Nine experienced and eight inexperienced radiologists at the hospital perform biopsy 5 times in each person and in each condition. The user starts the experiment with the freehand method 5 times, then

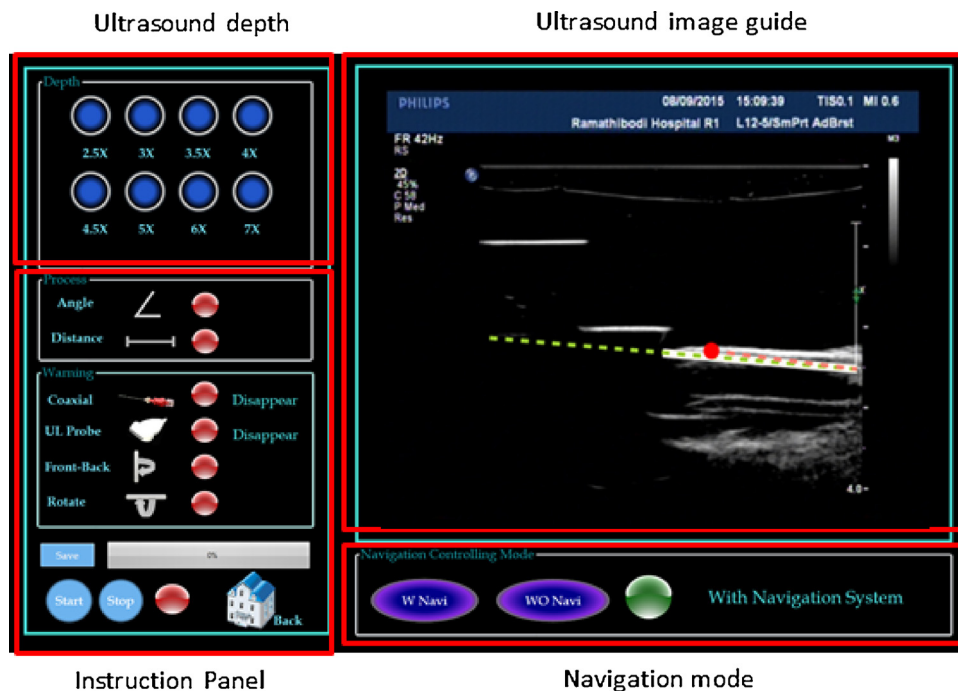


Fig. 5. Graphical user interface for breast biopsy navigation system.

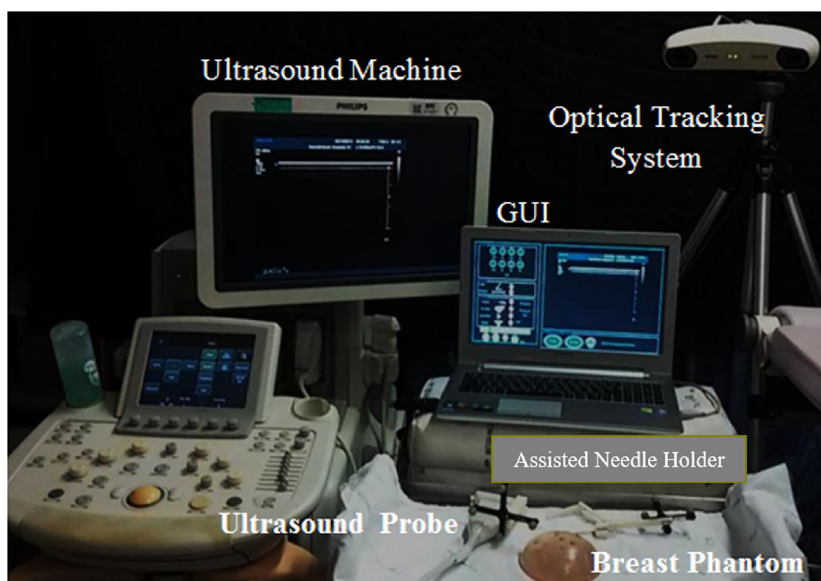

Fig. 6. The experiment setup.

using an assisted needle holder tool 5 times, and lastly, the integration of the whole system (assisted needle holder tool and GUI) in this experiment. Success rate and time are collected and evaluated to analyze the proficiency of this system. If the needle can reach the target, the breast biopsy procedure is successful. Starting time begins when the needle is at the entry point and ready for insertion. Fig. 6 shows the experimental setup that consists of the ultrasound machine, an assisted needle holder tool, a personal computer to display the image guidance, the optical tracking system and the breast phantom (not covered with a black plastic bag).

### 3. Results

The results from the experiments are evaluated using the procedure time and success rate, which are two important factors for the breast biopsy procedure. There are six groups of results with different conditions and groups of participants. Fig. 7(a) and Fig. 7(b) show comparison of result in time and success rate for the experienced and inexperienced participants in each condition.

The experienced group spent most time to finish the procedure using the whole system (*Assisted Needle Holder + GUI*). For the condition of using the freehand method and using only the needle holder tool, the procedure time is similar. On the other hand, the inexperienced group spent the least amount of time to finish the experiment when using only the needle holder tool and spent much time when using the freehand and the whole system method. There are three comparisons to investigate the system's performance with respect to each component, using data from both groups and determining the statistically significant difference in success rate and procedure time. Wilcoxon's Z statistic 2 tails and one-proportion z-test, statistical method for nonparametric data, are applied to analyze the different result in spending time and success rate between two conditions in the same samples. There is a significant different when the  $p$  value is lower than 0.01 ( $p < 0.01$ ).

#### 3.1. The performance of the breast biopsy procedure with and without assisted needle holder tool

This comparison investigates the effectiveness of an assisted needle holder tool with respect to the experienced and inexperienced groups' skills in the breast biopsy procedure. The results of breast biopsy using the freehand method and assisted needle holder tool are analyzed as

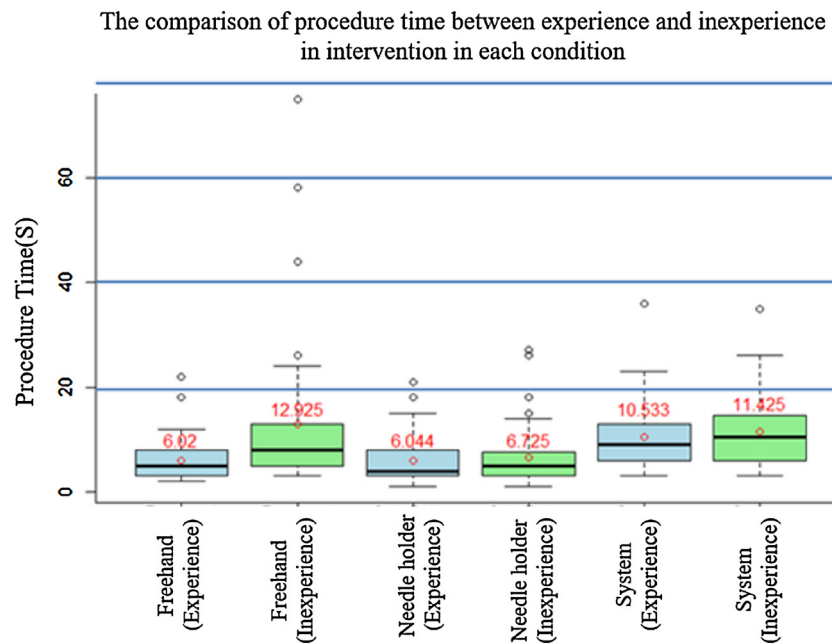
shown in Table 1.

The average time for the experienced group are  $6.022 \pm 4.191(SD)$  seconds and  $6.044 \pm 4.462(SD)$  seconds using freehand method and assisted needle holder method respectively. The results of success rate from both methods in experienced group are also similar with 95.56% for the freehand method and 100% for an assisted needle holder method. Statistical analysis shows no significant difference in procedure time and success rate between the freehand method and an assisted needle holder method for the experienced group. The results in the inexperienced group, in contrast, are significant different in procedure time and success rate between the freehand methods and assisted needle holder method. The inexperienced group spends more time when using the freehand method, around  $12.925 \pm 14.88(SD)$  seconds, with a low success rate of 57.5%. Using an assisted needle holder, the procedure time is  $6.725 \pm 5.996(SD)$  seconds and the success rate is 97.5%. The procedure time for this group is lower when using an assisted needle holder in comparison to using the freehand method; conversely, the success rate when using an assisted needle holder is higher than using freehand method.

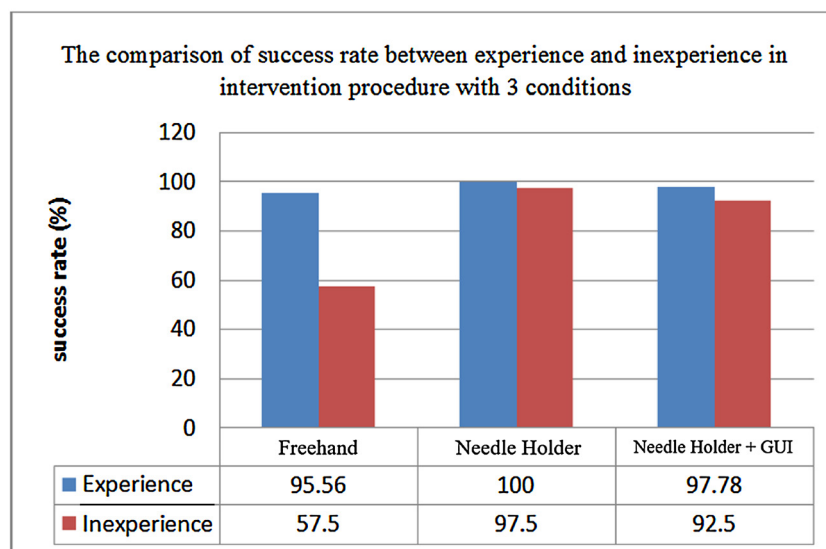
#### 3.2. The performance of the breast biopsy procedure with and without the graphical user interface (GUI)

The graphical user interface or image guidance system is another component that is very important in the breast biopsy navigation system. The results for biopsy completion time and success rate using only an assisted needle holder and the whole navigation system (*GUI + Assisted Needle Holder*) for both groups of participants are compared to investigate the effectiveness of the graphical user interface as shown in Table 2.

The average time for the experienced group using only an assisted needle holder method and an assisted needle holder with GUI method are  $6.044 \pm 4.462(SD)$  seconds and  $10.533 \pm 6.416(SD)$  seconds respectively. There is a significant difference in time between two methods, found using Wilcoxon's z statistic 2 tails. The success rate for the experienced group with only assisted needle holder is 100% and with assisted needle holder and GUI is 97.78%, which shows no significant difference between the success rates for the two scenarios based on statistical analysis. The results for the inexperienced group also show insignificant difference in success rate but have significant difference in time for the two scenarios. The time to task completion when using only an assisted needle holder and using an assisted needle holder with GUI



(a)



(b)

Fig. 7. The result comparison of (a) time and (b) success rate to finish the procedure by the experience and inexperience intervention.

Table 1

Biopsy procedure time and success rate for experience and inexperience groups using freehand and assisted needle holder method with statistical analysis.

		Time (s)		Wilcoxon's Z statistic 2 tails	Success Rate (%)	One-proportion Z-test
		Average	SD			
Experience	Freehand	6.022	4.191	Not significant (p = 0.88)	95.56	Not significant (p = 0.311)
	Assisted Needle Holder	6.044	4.462			
Inexperience	Freehand	12.925	14.880	Significant (p = 0.0006)	57.5	Significant (p < 0.0001)
	Assisted Needle Holder	6.725	5.996			

are  $6.725 \pm 5.996(SD)$  and  $11.425 \pm 6.917(SD)$  seconds respectively. The success rates are 97.5%, using only an assisted needle holder and 92.5%, using assisted needle holder with GUI, which shows similarity in success rates for both procedures.

### 3.3. The performance of the breast biopsy procedure with and without the breast biopsy navigation system

The previous comparison shows the efficiency and effectiveness of each component in the breast biopsy navigation system. This comparison, using freehand technique and the whole system (Assisted Needle

**Table 2**

Biopsy procedure time and success rate for experience and inexperience groups using the assisted needle holder and the system (Assisted Needle Holder and GUI) method with statistical analysis.

		Time (s)		Wilcoxon's Z statistic 2 tails	Success Rate (%)	One-proportion Z-test
		Average	SD			
Experience	Assisted Needle Holder	6.044	4.462	Significant (p < 0.0001)	100	Not significant (p = 0.312)
	Assisted Needle Holder + GUI	10.533	6.416		97.78	
Inexperience	Assisted Needle Holder	6.725	5.996	Significant (p = 0.0026)	97.5	Not significant (p = 0.0428)
	Assisted Needle Holder + GUI	11.425	6.917		92.5	

**Table 3**

Biopsy procedure time and success rate for experience and inexperience groups using freehand method and the breast biopsy navigation system method with statistical analysis.

		Time (s)		Wilcoxon's Z statistic 2 tails	Success Rate (%)	One-proportion Z-test
		Average	SD			
Experience	Freehand	6.022	4.191	Significant (p = 0.0002)	95.56	Not significant (p = 0.4936)
	Assisted Needle Holder + GUI	10.533	6.416		97.78	
Inexperience	Freehand	12.925	14.880	Significant (p = 0.0026)	57.5	Significant (p < 0.0001)
	Assisted Needle Holder + GUI	11.425	6.917		92.5	

Holder + GUI), observes the effectiveness of the breast biopsy navigation system with respect to the conventional breast biopsy procedure for experienced and inexperienced groups. Table 3 shows the result and statistical analysis of this condition.

The average time in the experienced group and inexperienced group using freehand method are  $6.022 \pm 4.191(SD)$  second and  $12.925 \pm 14.880(SD)$  seconds. Using the navigation system the time taken for the experienced group is  $10.533 \pm 6.416(SD)$  seconds, and for the inexperienced group is  $11.425 \pm 6.917(SD)$  seconds. The success rate also shows the same results as the average time. The success rate in the experienced group using freehand and the navigation system are 95.56% and 97.78% respectively. On the other hand, the success rate in the inexperienced group is 57.5% using the freehand method and 92.5% using the navigation system. Wilcoxon's Z statistic 2 tails shows a significant difference in time between the freehand method and the navigation system method in both the experience and inexperienced groups. However, one-proportion Z-test shows a significant difference between the two procedures for the inexperienced group but not for the experienced group.

**4. Conclusion and discussion**

The results from the experienced group indicate that the time taken to perform a breast biopsy using the whole navigation system is highest, freehand method comes in the second, and the fastest time is when breast biopsy is performed using only an assisted needle holder. The results imply that the GUI in the navigation system effect the procedure time in breast biopsy procedure for trained professionals. The user has to concentrate on the needle line and needle insertion path, which should lie on the same path during needle insertion. However, the breast biopsy navigation system increases the success rate for the inexperienced group when compared with the freehand method [24]. The experienced group also get high success rate in all conditions. More time spend on biopsy when using the whole navigation system; most participants prefer this system because the system guides the insertion path and avoids mistakes in needle insertion direction. An assisted needle holder tool helps the inexperienced group control the needle's orientation within the ultrasound plane, which is the main problem for new radiologists when performing breast biopsy. The user needs to align the ultrasound plane and the needle axis while attempting to maintain the visualization of the target lesion in the freehand procedure that leads to multiple reinsertions [25]. The GUI helps the user predict

the needle insertion line before starting and calculates the distance between the target and the entry point, which help the user to approximate the distance with respect to the actual length of the needle. Moreover, the breast biopsy navigation system controls needle motion, which leads to low tissue trauma and no multiple reinsertion.

An assisted needle holder tool is designed and developed to use with two functions: with and without the navigation system. The user can choose to use freehand method, only an assisted needle holder or the whole system depending on each user's experience in the procedure. Adaptation mode is designed to consider the variety of skill and personality of each user. However, using only image guidance or graphical user interface (*without assisted needle holder*) should be implemented in the breast biopsy navigation system. Assisted needle holder has been designed with no electronic part and plastic material, so it is easy to sterile and put each part together in a short period.

The breast biopsy navigation system can improve efficiency and accuracy of breast biopsy in an inexperienced group by decreasing the procedure time for successful clinical breast biopsy. The system encourages new radiologists to finish the procedure with high confidence and limit the injuries accidents and discomfort to the patient. For experience radiologist, the breast biopsy navigation system is a new chance to perform breast biopsy with high success rate, low accidents, no needle reinsertions and low awareness. The researcher believes that this breast biopsy navigation system has potential for clinical application allowing the radiologists more accuracy and efficiency.

**Competing interests**

The authors of this paper have no conflicts of interest or financial ties to disclose.

**Acknowledgements**

This research has been funded by the Computer-Integrated Intelligent Medical System Project under the Thailand National Research University Grant through Mahidol University, Thailand. Another fund resource is the Integration of Surgical Navigation and Surgical Assisted needle holder for Breast Biopsy in Breast Cancer using Mammogram and Ultrasound Images on Breast Mathematical Model Project under the Thai Government Research Budget through Mahidol University (Grant No. 111-2558), Mahidol University, Thailand. We would like to thank Ramathibodi Hospital staff and radiologists for



their valuable knowledge and recommendations towards the development of this system. Another group we would like to thank are the BARTLAB members who presented us with knowledge in mechanical design, programming and statistical analysis.

## References

- [1] V. Ames, P.D. Britton, Stereotactically guided breast biopsy: a review, *Insights Imaging* 2 (2) (2011) 171–176, <https://doi.org/10.1007/s13244-010-0064-1>.
- [2] P. Crystal, M. Koretz, S. Shcharynsky, V. Makarov, S. Strano, Accuracy of sonographically guided 14-gauge core-needle biopsy: results of 715 consecutive breast biopsied with at least two-year follow-up of benign lesions, *J. Clin. Ultras.* 33 (2) (2005) 47–52, <https://doi.org/10.1002/jcu.20089>.
- [3] D.L. Monticciolo, R.L. Hajdik, M.G. Hicks, J.K. Winford, W.R. Larkin, J.V. Vasek, B.M. Ashton, Six-month short-interval imaging follow-up for benign concordant core needle biopsy of the breast: outcomes in 1444 cases with long-term follow-up, *AJR Am. J. Roentgenol.* 24 (1) (2016) 1–6, <https://doi.org/10.2214/AJR.15.15853>.
- [4] G. Schueller, S. Jaromi, L. Ponthold, M. Fuchsjaeger, M. Memarsadeghi, M. Rudas, M. Weber, L. Liberman, T.H. Helbich, US-guided 14-gauge core-needle breast biopsy: results of a validation study in 1352 cases, *Radiology* 248 (2) (2008) 406–413, <https://doi.org/10.1148/radiol.2482071994>.
- [5] B.D. Fornage, B.E. Dogan, N. Sneige, G.A. Staerckel, Ultrasound-guided fine-needle aspiration biopsy of internal Mammary nodes: technique and preliminary results in breast cancer patients, *AJR Am. J. Roentgenol.* 203 (2) (2014) W213–20, <https://doi.org/10.2214/AJR.13.11148>.
- [6] A. Gupta, H.K. Verma, S. Gupta, A hybrid framework for registration of carotid ultrasound images combining iconic and geometric features, *Med. Biol. Eng. Comput.* 51 (9) (2013) 1043–1050, <https://doi.org/10.1007/s11517-013-1086-x>.
- [7] L.C. Sousa, C.F. Castro, C.C. António, A.M. Santos, R.M. dos Santos, P.M. Castro, E. Azevedo, J.M. Tavares, Toward hemodynamic diagnosis of carotid artery stenosis based on ultrasound image data and computational modeling, *Med. Biol. Eng. Comput.* 52 (11) (2014) 971–983, <https://doi.org/10.1007/s11517-014-1197-z>.
- [8] I. Sechopoulos, S. Suryanarayanan, S. Vedantham, C.J. D'Orsi, A. Karellas, Radiation dose to organs and tissues from mammography: Monte Carlo and phantom study, *Radiology* 246 (2) (2008) 434–443, <https://doi.org/10.1148/radiol.2462070256>.
- [9] A.V. Bolívar, B.P. Alonso, G.E. Ortega, A.F. Garijo, Ultrasound-guided core needle biopsy of Non-palpable breast lesions: a prospective analysis in 204 cases, *Acta Radiol.* 46 (7) (2005) 690–695, <https://doi.org/10.1080/02841850500225740>.
- [10] M.B. Mainiero, I.F. Gareen, C.E. Bird, W. Smith, C. Cobb, B. Schepps, Preferential use of sonographically guided biopsy to minimize patient discomfort and procedure time in a percutaneous image-guided breast biopsy program, *J. Ultrasound Med.* 21 (11) (2002) 1221–1226.
- [11] G.Y. Cho, L. Gennaro, E.J. Sutton, et al., Intravoxel incoherent motion (IVIM) histogram biomarkers for prediction of neoadjuvant treatment response in breast cancer patients, *Eur. J. Radiol. Open* 4 (1) (2017) 101–107, <https://doi.org/10.1016/j.ejro.2017.07.002>.
- [12] J.H. Youk, E.K. Kim, M.J. Kim, K.K. Oh, Sonographically guided 14-gauge core needle biopsy of breast masses: a review of 2,420 cases with Long-term follow-up, *AJR Am. J. Roentgenol.* 190 (1) (2008) 202–207, <https://doi.org/10.2214/AJR.07.2419>.
- [13] R.D. Rocha, R.R. Pinto, D.P.B.A. Tavares, et al., Step-by-step of ultrasound-guided core-needle biopsy of the breast: review and technique, *Radiol. Bras.* 46 (1) (2013) 234–241, <https://doi.org/10.1590/S0100-39842013000400010>.
- [14] A. Krieger, R.C. Susil, C. Ménard, J.A. Coleman, G. Fichtinger, E. Atalar, L.L. Whitcomb, Design of a novel MRI compatible manipulator for image guided prostate interventions, *IEEE Trans. Biomed. Eng.* 52 (2) (2005) 306–313, <https://doi.org/10.1109/TBME.2004.840497>.
- [15] T.A. Matalon, B. Silver, US guidance of interventional procedures, *Radiology* 174 (1) (1990) 43–47, <https://doi.org/10.1148/radiology.174.1.2403684>.
- [16] K.J. Surry, G.R. Mills, K. Bevan, D.B. Downey, A. Fenster, Stereotactic mammography imaging combined with 3D US imaging for image guided breast biopsy, *Med. Phys.* 34 (11) (2007) 4348–4358, <https://doi.org/10.1118/1.2794175>.
- [17] T.R. Nelson, Amy Tran, F. Hourieh, N. Jakob, Ultrasound image-guided assisted needle holder breast biopsy, *IEEE Ultrasonics Symposium (IUS)* (2010) 2352–2355, <https://doi.org/10.1109/ULTSYM.2010.5935964>.
- [18] M. Rosenthal, A. State, J. Lee, et al., Augmented reality guidance for needle biopsies: an initial randomized, controlled trial in phantoms, *Med. Image Anal.* 6 (3) (2002) 313–320, [https://doi.org/10.1016/S1361-8415\(02\)00088-9](https://doi.org/10.1016/S1361-8415(02)00088-9).
- [19] D. Magee, Y. Zhu, R. Ratnalingam, P. Gardner, D. Kessel, An augmented reality simulator for ultrasound guided needle placement training, *Med. Biol. Eng. Comput.* 45 (10) (2007) 957–967, <https://doi.org/10.1007/s11517-007-0231-9>.
- [20] Y. Paltieli, S. Degani, A. Zrayek, R. Gonen, M.R. Lewinski, Y. Zamberg, G. Ohel, A new guidance system for freehand, obstetric ultrasound-guided procedures, *Ultrasound Obstet. Gynecol.* 19 (3) (2002) 269–273, <https://doi.org/10.1046/j.1469-0705.2002.00607.x>.
- [21] G. Paladini, F. Sauer, Optical needle guide for ultrasound guided needle biopsy, US20030028112 A1, (2004) Google Patents.
- [22] D. Han, Y. Lan Seo, C. Soon Choi, H. Chul Kim, D. Young Yoon, S. Hoon Bae, J. Hee Moon, S. Hyup Kim, S. Soo Kim, H. Han, A steerable guiding device: the new method in ultrasound guidance, *Invest. Radiol.* 37 (11) (2002) 626–631, <https://doi.org/10.1097/01.RLI.0000031074.37936.D9>.
- [23] N. Bluvol, A. Sheikh, A. Kornecki, R. Fernandez Ddel, D. Downey, A. Fenster, A needle guidance system for biopsy and therapy using two-dimensional ultrasound, *Med. Phys.* 35 (2) (2008) 617–628, <https://doi.org/10.1118/1.2829871>.
- [24] N. Bluvol, A. Kornecki, A. Shaikh, D. Del Rey Fernandez, D.H. Taves, A. Fenster, A, freehand versus guided breast biopsy: comparison of accuracy, needle motion, and biopsy time in a tissue model, *AJR Am. J. Roentgenol.* 192 (6) (2009) 1720–1725, <https://doi.org/10.2214/AJR.08.1434>.
- [25] W. Onprasert, S. Ongwattanakul, J. Suthakorn, Implementation on a New tool tip calibration method for biomedical applications, *Recent Advances in Computer Science and Information Engineering*, Springer, Berlin Heidelberg, 2012, pp. 385–392, [https://doi.org/10.1007/978-3-642-25778-0\\_53](https://doi.org/10.1007/978-3-642-25778-0_53).