




Case Report

Intracranial anaplastic hemangiopericytoma presenting with simultaneous extra-cranial metastases: A case report and review of the literature

Sumanth Reddy¹, Aaron Plitt¹, Jack Raisanen², Ankur R. Patel¹, Purva Gopal², Robert Timmerman³, Toral R. Patel¹

Departments of ¹Neurological Surgery, ²Pathology, ³Radiation Oncology, University of Texas Southwestern Medical Center, Dallas, Texas, United States.

E-mail: Sumanth Reddy - sumanth.reddy@utsouthwestern.edu; Aaron Plitt - aaron.plitt@phhs.org; Jack Raisanen - jack.raisanen@utsouthwestern.edu; Ankur Patel - ankur.patel@phhs.org; Purva Gopal - purva.gopal@utsouthwestern.edu; Robert Timmerman - robert.timmerman@utsouthwestern.edu; *Toral Patel - toral.patel@utsouthwestern.edu



***Corresponding author:**

Toral R. Patel, MD,
Department of Neurological
Surgery, University of Texas
Southwestern Medical Center,
Dallas, Texas 75390,
United States.

toral.patel@utsouthwestern.edu

Received : 17 February 19

Accepted : 06 June 19

Published : 26 July 19

DOI

10.25259/SNI_111_2019

Quick Response Code:



ABSTRACT

Background: Intracranial solitary fibrous tumor/hemangiopericytoma (SFT/HPC) is a rare mesenchymal tumor with a propensity to recur and metastasize extracranially years after treatment. Accordingly, there are no reported cases of a patient presenting with a simultaneous intracranial primary and extracranial metastases. We present the case of a patient presenting with an intracranial SFT/HPC and simultaneous liver metastases and propose a treatment paradigm.

Case Description: A 74-year-old male smoker presented with confusion. An MRI of the brain revealed a heterogeneously enhancing left frontal extra-axial mass. Systemic workup revealed multiple small liver lesions concerning for metastases. The patient underwent gross total resection (GTR) of the intracranial lesion with adjuvant CyberKnife stereotactic radiotherapy to the resection cavity. Pathology was consistent with a WHO Grade III SFT/HPC (previously known as anaplastic HPC). The liver lesions were biopsied and confirmed to be metastases. They were subsequently treated with stereotactic body radiation therapy, temozolomide, and bevacizumab. Eighteen months postoperatively, the patient is alive with no evidence of intracranial malignancy and regression of the hepatic lesions.

Conclusion: Several studies support GTR and adjuvant radiotherapy to treat intracranial SFT/HPC. The role of adjuvant chemotherapy is less clear. Metastatic disease is typically detected several years after the initial diagnosis, and there is no consensus regarding the optimal treatment strategy. We propose that the rare presentation of intracranial SFT/HPC with simultaneous extracranial metastases should be treated in a multidisciplinary fashion with surgical resection, adjuvant radiotherapy, and chemotherapy.

Keywords: Extracranial metastasis, Hemangiopericytoma, Intracranial, Simultaneous, Solitary fibrous tumor, Synchronous

INTRODUCTION

Intracranial solitary fibrous tumor/hemangiopericytoma (SFT/HPC) is a rare tumor of mesenchymal origin.^[21] Analysis of the Surveillance, Epidemiology, and End Results Program data reveals an age-adjusted incidence of 3.77 per 10,000,000 people.^[23] Evaluation of the National Cancer Database demonstrates that SFT/HPC comprises 0.22% of all intracranial tumors.^[39] Before the updated WHO 2016 classification of central nervous system tumors, intracranial SFT and

HPC were classified as two separate pathological entities. SFTs were designated as WHO Grade I lesions, while HPCs were designated as WHO Grade II or III lesions. Recently, whole-exome sequencing has revealed a unique *NAB2-STAT6* fusion gene common to both SFTs and HPCs.^[11] In recognition of this common molecular pathophysiology, the 2016 WHO classification combined these two tumors into a single entity known as SFT/HPC, with three distinct grades.^[26]

Grade I SFT/HPC is characterized by low cellularity and dense collagen deposition, which corresponds to the prior diagnosis of SFT. Grade II SFT/HPC is characterized by “staghorn” vasculature and increased cellularity. The presence of at least five mitoses per 10 high-power fields denotes a Grade III SFT/HPC, previously recognized as an anaplastic HPC.^[11,26] More recent data have revealed that, with time, even low-grade SFT/HPCs can undergo malignant transformation.^[2]

Intracranial SFT/HPCs metastasize to extracranial locations at a rate of 11.6 to 69% within 10 years of initial diagnosis, most commonly to the lung/pleura, liver, and bone.^[34] In the published literature, the reported time frame from diagnosis of the primary tumor to the diagnosis of extracranial metastases is wide and ranges from 3 to 372 months.^[34] High-grade SFT/HPCs (WHO Grade III) are significantly more likely to develop extracranial metastases than low-grade tumors.^[34] The typical clinical course consists of the initial identification of a solitary intracranial lesion, followed by the discovery of extracranial metastases during a long-term surveillance period. There are no reported cases describing the simultaneous diagnosis of an intracranial SFT/HPC and an extracranial metastasis.

In this report, we detail the case of a patient presenting with a symptomatic anterior cranial fossa WHO Grade III SFT/HPC and synchronous liver metastases. We will describe the patient’s clinical course and briefly review the literature in an effort to provide a rational treatment approach to this unusual clinical scenario.

CASE DESCRIPTION

A 74-year-old, right-handed, male smoker was taken to an outside hospital after he became confused at a gas station. This episode was preceded by 1 month of cognitive decline, personality changes, and urinary incontinence, as well as self-reported clear rhinorrhea while eating. His neurologic exam was notable for a flat affect and a relative paucity of speech.

A head computed tomography (CT) was obtained and demonstrated a large, hyperdense left frontal extra-axial mass along the floor of the anterior cranial fossa, with bony erosion into the frontal sinus [Figure 1]. A subsequent magnetic resonance imaging (MRI) revealed a 7.0 cm×5.0 cm×4.9 cm heterogeneously enhancing mass

with intrinsic T1 shortening, suggestive of prior hemorrhage, and subacute blood products posterior to the tumor margin, abutting the frontal horn of the left lateral ventricle. T1 postcontrast imaging revealed a dural tail and T2-weighted images demonstrated a partial cerebrospinal fluid cleft around the periphery of the lesion; both findings suggested that the mass was extra-axial in origin [Figure 2]. Given the

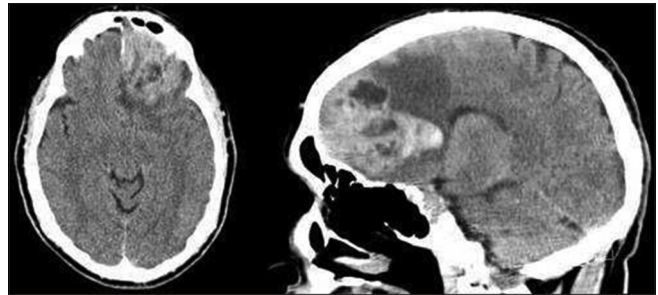


Figure 1: CT head without contrast demonstrates a hyperdense left frontal mass with the erosion of the inner table of the frontal sinus, near midline.

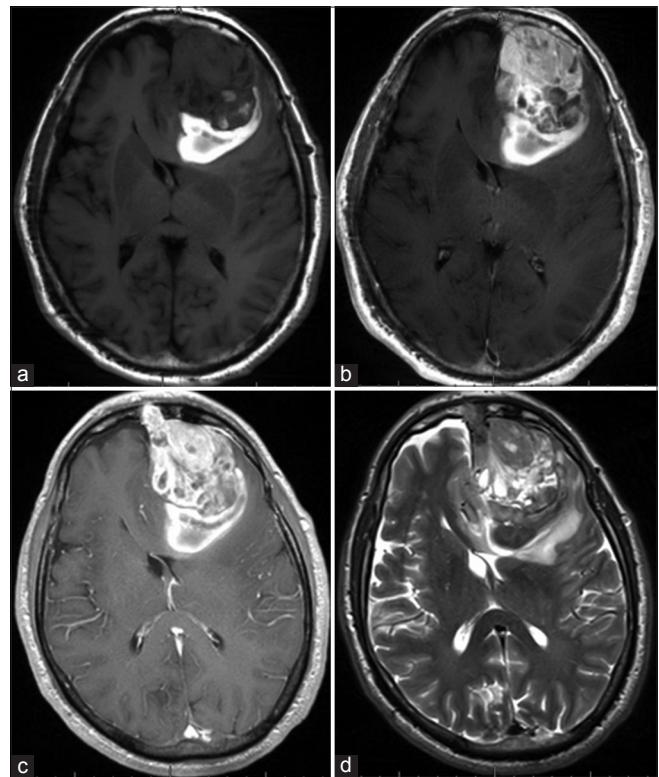


Figure 2: MRI brain. (a) T1 noncontrast and (b) T1 postcontrast sequences demonstrate a 7.0 cm×5.0 cm×4.9 cm heterogeneously enhancing left frontal mass with T1 shortening at the posterior aspect of the lesion, suggestive of prior hemorrhage. (c) T1 postcontrast sequences also reveal a dural tail and (d) T2-weighted sequences demonstrate a partial cerebrospinal fluid cleft around the periphery of the lesion; both findings suggest that the mass is extra-axial in origin.

aggressive appearance of the lesion and the patient's smoking history, there was a concern that the lesion was a dural-based metastasis from an unknown primary. Therefore, a metastatic workup was completed, including a contrasted CT of the chest, abdomen, and pelvis. The CT scans revealed multiple small, hypodense liver lesions concerning for metastases [Figure 3] as well as pulmonary emboli.

An inferior vena cava filter was placed, and the patient was subsequently taken to the operating room for resection of the intracranial tumor. A two-piece bifrontal craniotomy was performed since the tumor was noted to invade both the frontal sinus and the superior sagittal sinus on the preoperative imaging. The lesion was of mixed consistency, with both firm and soft components. There was significant hypervascularity, which was controlled with bipolar electrocautery. The involved portions of the superior sagittal sinus and frontal sinus were removed. The frontal sinus was subsequently obliterated with an abdominal fat graft and reconstructed with a combination of methyl methacrylate and titanium plates. Intraoperative frozen section analysis was consistent with a high-grade neoplasm (SFT/HPC vs. anaplastic meningioma vs. metastasis). A gross total resection (GTR) was achieved. The patient tolerated the procedure well; his speech and affect improved postoperatively. A postoperative MRI confirmed GTR.

The pathological assessment revealed that the left frontal tumor was a SFT/HPC. The tumor was histologically characterized by a proliferation of relatively small cells with round to oval nuclei, some with small nucleoli, and scant or indistinguishable cytoplasm. The cells were arranged haphazardly among staghorn-like vessels. There were >5 mitotic figures in 10 high-power microscopic fields and foci of tumor necrosis, and thus, the neoplasm was designated as anaplastic (WHO Grade III). Immunoperoxidase stains demonstrated nuclear expression of *STAT6* by many of the neoplastic cells indicating fusion of the *NAB2* and *STAT6* genes [Figure 4]. Three weeks postoperatively, a CT-guided biopsy of one of the liver lesions was performed. Histologic sections revealed neoplastic cells that were morphologically similar to those in the intracranial tumor specimen and immunohistochemistry confirmed the *NAB2/STAT6* fusion [Figure 5].

The patient underwent adjuvant CyberKnife stereotactic radiation therapy to the intracranial resection cavity. He received a total dose of 50 Gy (in 25 fractions). In addition, stereotactic body radiation therapy (SBRT) was used to treat the liver lesions: a segment 6 liver lesion was treated with 40 Gy in one fraction and a segment eight liver lesion was treated with 60 Gy in five fractions.

Sequential surveillance MRIs of the brain and abdomen were obtained following the completion of radiation treatment. MRIs of the brain remained stable, with no evidence of

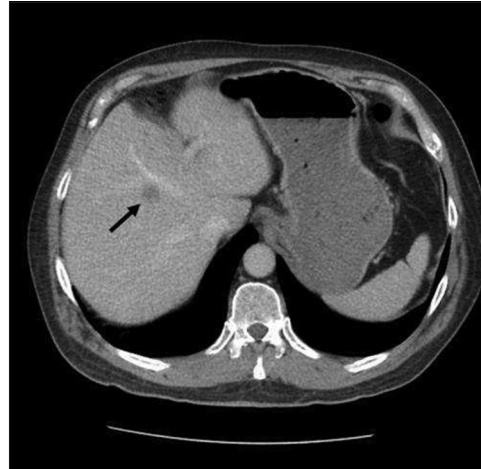

Figure 3: CT abdomen/pelvis demonstrates a hypodense hepatic lesion (arrow) concerning for metastatic disease.

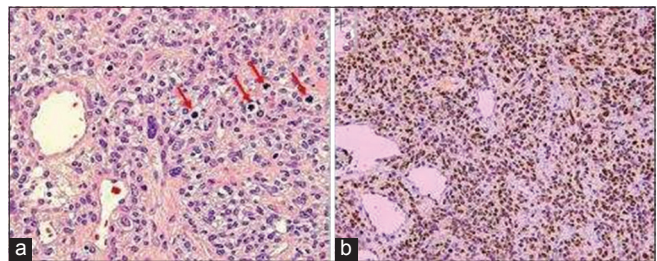


Figure 4: (a) Histologic sections of the left frontal mass demonstrate a high-grade SFT/HPC. Note the four mitotic figures in the mid-upper right (red arrows). (H & E, 200×). (b) Nuclei of the neoplastic cells express *STAT6*, indicating a fusion of the *NAB2* and *STAT6* genes (Diaminobenzidine, 100×).

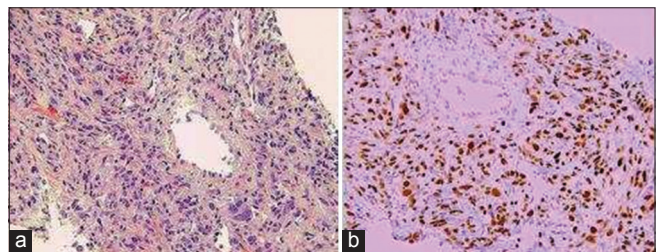


Figure 5: (a) Metastatic hemangiopericytoma in liver core biopsy (H & E, 200×). (b) Expression of *STAT6* by the neoplastic cells (Diaminobenzidine, 100×).

disease recurrence at 18 months postoperatively [Figure 6]. An MRI of the abdomen obtained 6 weeks following liver SBRT demonstrated mild growth of the previously noted lesions. These were initially observed; subsequent MRI 2 months later demonstrated persistent, but stable hepatic tumors. Given the abdominal MRI findings, the patient was offered additional treatment with chemotherapy. Two regimens were discussed: (1) pazopanib (800 mg daily)

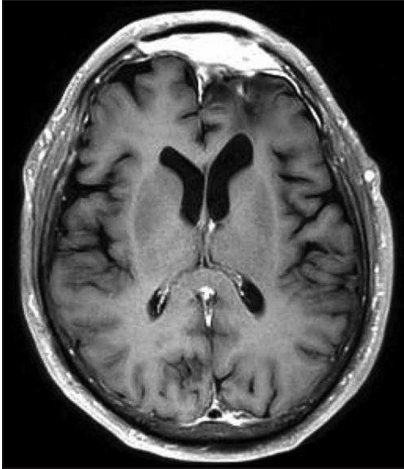


Figure 6: Postoperative surveillance MRI brain (T1 postcontrast) demonstrates no evidence of residual or recurrent disease.

versus (2) temozolomide (150 mg/m² on days 1–7 and 15–21/28-day cycle) and bevacizumab (5 mg/kg on days 8- and 22/28-day cycle). The patient ultimately opted to proceed with temozolomide and bevacizumab, and he completed 6 cycles and was then placed on observation. Follow-up abdominal MRIs over the next 6 months have demonstrated partial regression of the liver lesions. The patient is now 18 months from initial diagnosis and is alive and doing well, with no evidence of disease progression. He is on observation, with surveillance MRIs of the brain and abdomen obtained every 3 months.

DISCUSSION

Surgical resection remains the primary treatment for SFT/HPCs. Numerous studies have demonstrated that GTR improves both overall survival (OS) and progression-free survival (PFS) in patients with SFT/HPC, as compared to subtotal resection (STR).^[6,7,10,28,33,41] A meta-analysis of 277 patients with intracranial SFT/HPC found that GTR prolonged OS by 3.25 years, compared to STR.^[35] Importantly, the authors noted this benefit was independent of adjuvant radiotherapy.

The role of adjuvant radiotherapy for treatment of intracranial SFT/HPC remains controversial. Some studies have found that postoperative radiotherapy prolongs PFS, but that it does not provide a survival benefit.^[22,28,35,39] Other studies have found an increase in OS in patients receiving postoperative radiotherapy.^[12,15,36] Our own institutional experience suggests that postoperative radiotherapy does not improve PFS or OS in patients who undergo GTR.^[32] However, it is worth noting that each of these studies included a heterogeneous cohort of patients, with both low- and high-grade SFT/HPCs. Thus, it is difficult to generalize these

results to patients with the WHO grade III SFT/HPC. The largest study of patients with anaplastic SFT/HPCs followed 52 patients for a mean of 36.8 months and determined that postoperative radiotherapy did improve both PFS and OS. The 5-year PFS was 66.3% in patients who received postoperative radiotherapy versus 38.3% in patients who did not. Furthermore, the 5-year OS was 90% in patients who received postoperative radiotherapy versus 47.1% in patients who did not.^[41] The standard treatment dose for adjuvant radiotherapy in this setting is 50 Gy.^[4,13,15,35]

There is a paucity of published literature addressing the role of adjuvant systemic chemotherapy for SFT/HPC. In general, treatment with traditional cytotoxic chemotherapeutic agents has yielded disappointing results.^[3,41,42] The use of targeted chemotherapies for the management of SFT/HPC remains an area of interest and is emerging. Pazopanib is a tyrosine kinase inhibitor that acts as an antiangiogenic agent by binding to vascular endothelial growth factor receptor (VEGFR), and platelet-derived growth factor receptor (PDGFR).^[37] A case report of two patients with recurrent intracranial SFT/HPC treated with pazopanib demonstrated excellent radiographic results, with decreases in tumor volume of 84% and 43% after 3 months of therapy.^[11] Genomic analyses have revealed increased expression of several tyrosine kinase sequences targeted by pazopanib in intracranial SFT/HPC, as compared to systemic SFT/HPC. This difference may explain the increased efficacy of pazopanib in treating intracranial SFT/HPC versus systemic SFT/HPC, although this observation is based on limited case studies. The primary limitations of pazopanib therapy are hepatotoxicity and thrombosis.^[9]

Of note, a Phase II trial of sunitinib (another tyrosine kinase inhibitor, which targets VEGFR, PDGFR, and c-KIT) for atypical and anaplastic meningioma included an exploratory cohort of six patients with SFT/HPC. Three patients discontinued therapy due to toxicity, two withdrew, and one had a progression of disease at 1.6 months.^[18] An additional potential target is programmed death-ligand 1 (PD-L1), an immune checkpoint molecule that allows tumor cells to evade the host immune response by inactivating host T-cells. Kamamoto *et al.* have recently demonstrated that PD-L1 is commonly expressed in intracranial SFT/HPCs and that increased PD-L1 expression is associated with earlier extracranial metastases.^[19] Further research into the use of PD-L1 inhibitors for the treatment of SFT/HPC is necessary.

Finally, combination therapy with temozolomide and bevacizumab has been shown to be effective in the treatment of patients with refractory disease, although it is unclear if this benefit is from temozolomide, bevacizumab, or a synergistic response. A case series of 14 patients, with a median follow-up of 34 months, demonstrated either partial response (11 patients) or stable disease (2 patients) in all but

Table 1: Treatment modalities and outcomes for intracranial SFT/HPC with liver metastases*.

Year of publication	Author	Age/Sex	Other sites of metastatic disease	Interval† (years)	Treatment	Outcome (follow-up time, in months)
1960	Hukill and Lowman ^[16]	33/F	None	1.5	Surgical resection	DOD (18)
1988	Yoshida <i>et al.</i> ^[40]	39/M	None	6	Surgical resection	AWD (31)
1991	Chakravarty <i>et al.</i> ^[5]	41/F	None	6	Surgical resection	DF (7)
1993	Kaneko <i>et al.</i> ^[20]	54/M	None	19	Surgical resection	AWD (9)
1998	Niwa <i>et al.</i> ^[30]	55/M	Lung, vertebrae, pancreas	20	Surgical resection, Radiotherapy	AWD (84)
2004	Spatola and Privitera ^[38]	48/F	Kidney	8	Surgical resection, Radiotherapy, Chemotherapy	DOD (~48)
2009	Iwamuro <i>et al.</i> ^[17]	54/F	Bone	10	RFA, TACE	DF (60)
2014	Lee <i>et al.</i> ^[24]	52/M	Pancreas	8	RFA, Radiotherapy, Surgical resection, Chemotherapy	AWD (~24)
2015	De Martin <i>et al.</i> ^[8]	48/F	N/A	4	Liver transplant	DF (60)
2015	Nickerson <i>et al.</i> ^[29]	63/M	Small bowel, peritoneum	23	Surgical resection, Chemotherapy	AWD (~48)
2015	Manatakis <i>et al.</i> ^[27]	35/M	Vertebrae	7	Surgical resection, RFA, TAE	DF (~12)
2016	Lo <i>et al.</i> ^[25]	35/M	N/A	5	Chemotherapy	AWD (34)
2016	Lo <i>et al.</i> ^[25]	51/F	N/A	19	Surgical resection	DF (26)
2016	Lo <i>et al.</i> ^[25]	60/M	N/A	16	Surgical resection	DF (39)
2016	Lo <i>et al.</i> ^[25]	31/F	N/A	7	Surgical resection, RFA	AWD (36)
2016	Lo <i>et al.</i> ^[25]	48/M	N/A	12	RFA	DOD (36)

*DOD: Died of disease, AWD: Alive with disease, DF: Disease free, TACE: Transcatheter arterial chemoembolization, TAE: Transarterial embolization, RFA: Radiofrequency ablation. SFT/HPC: Solitary fibrous tumor/hemangiopericytoma. †Interval between diagnosis of primary intracranial SFT/HPC to diagnosis of liver metastases.

one patient. For those patients with a partial response, the treatment effect was observed after 2 to 4 cycles of therapy, at a median of 2.5 months. Median PFS was 9.67 months and 78.6% of patients were progression-free at 6 months. Five patients had a PFS of at least 20 months.^[31]

Extracranial metastases are a relatively common finding in patients with SFT/HPC. A recent large case review found that 28% of all patients with intracranial SFT/HPC will develop extracranial metastases, most commonly to the bone, lung, or liver.^[34] Approximately 17% of all extracranial SFT/HPC metastases occur in the liver.^[34] Proposed treatment strategies for hepatic metastases include surgical resection, radiotherapy, radiofrequency ablation, transarterial embolization, and chemotherapy. Although various combinations of these treatment modalities have been described [Table 1], there is no consensus regarding the optimal approach, and clinical outcomes vary widely.

Given that our patient had an excellent performance status and GTR of his intracranial disease, we felt that the aggressive treatment of his liver metastases was indicated. Due to his recent intracranial surgery and the preoperative pulmonary emboli, the decision was made to initially treat the hepatic lesions with SBRT alone. In addition, given the WHO

Grade III histology, we also opted to treat the intracranial resection cavity with adjuvant CyberKnife stereotactic radiosurgery. When follow-up imaging demonstrated the mild progression of the liver metastases, systemic chemotherapy was advised. Two different regimens were offered: pazopanib alone versus combination temozolomide and bevacizumab. Given the hepatic location of the metastases and the history of pulmonary emboli, the decision was made to treat with temozolomide and bevacizumab. The patient completed 6 cycles and his subsequent MRIs demonstrated improvement in his disease burden. He is now 18 months from initial diagnosis and is being observed with surveillance MRIs of the brain and abdomen every 3 months. If future imaging studies demonstrate disease progression, evaluation of his original tumor specimens (brain and liver) for expression of pazopanib-targeted tyrosine kinase sequences and/or PD-L1 activity would be of particular utility to guide the selection of salvage therapies.

CONCLUSION

The average time from diagnosis of a primary intracranial SFT/HPC to the detection of metastatic disease is approximately 7.5 years.^[14] There are no reported cases

of a patient presenting with an intracranial primary and synchronous extracranial metastasis. We believe that our patient may have a particularly aggressive SFT/HPC, given the WHO Grade III histology and presence of metastatic disease at presentation. In addition, the tumor's infiltration of the superior sagittal sinus may have provided it with early access to the venous system, thus increasing the risk of hematogenous metastases. We present this rare case to provide clinical guidance to others who may encounter a similar patient. We believe that this type of patient should be treated in a multidisciplinary fashion, with initial maximal safe surgical resection, followed by a combination of radiotherapy and chemotherapy, tailored specifically to the patient's systemic disease burden.

Declaration of patient consent

The authors certify that they have obtained IRB approval for this retrospective review and that all appropriate patient consent forms have been obtained. In the form, the patient has given his consent for his images and other clinical information to be reported in the journal. The patient understands that their names and initials will not be published and due efforts will be made to conceal their identity, but anonymity cannot be guaranteed.

Financial support and sponsorship

Nil.

Conflicts of interest

There are no conflicts of interest.

REFERENCES

- Apra C, Alentorn A, Mokhtari K, Kalamarides M, Sanson M. Pazopanib efficacy in recurrent central nervous system hemangiopericytomas. *J Neurooncol* 2018;139:369-72.
- Apra C, Mokhtari K, Cornu P, Peyre M, Kalamarides M. Intracranial solitary fibrous tumors/hemangiopericytomas: First report of malignant progression. *J Neurosurg* 2018;128:1719-24.
- Bassiouni H, Asgari S, Hübschen U, König HJ, Stolke D. Intracranial hemangiopericytoma: Treatment outcomes in a consecutive series. *Zentralbl Neurochir* 2007;68:111-8.
- Bastin KT, Mehta MP. Meningeal hemangiopericytoma: Defining the role for radiation therapy. *J Neurooncol* 1992;14:277-87.
- Chakravarty BJ, Munn S, Lane MR. Hepatic metastasis from a meningeal haemangiopericytoma. *Aust N Z J Med* 1991;21:884-5.
- Chen H, Zeng XW, Wu JS, Dou YF, Wang Y, Zhong P, *et al.* Solitary fibrous tumor of the central nervous system: A clinicopathologic study of 24 cases. *Acta Neurochir (Wien)* 2012;154:237-48.
- Chen LF, Yang Y, Yu XG, Gui QP, Xu BN, Zhou DB, *et al.* Multimodal treatment and management strategies for intracranial hemangiopericytoma. *J Clin Neurosci* 2015;22:718-25.
- De Martin E, Coilly A, Guettier C, Samuel D. Liver metastases from meningeal hemangiopericytoma. *Liver Int* 2015;35:2337.
- Ebata T, Shimoi T, Bun S, Miyake M, Yoshida A, Shimomura A, *et al.* Efficacy and safety of pazopanib for recurrent or metastatic solitary fibrous tumor. *Oncology* 2018;94:340-4.
- Fargen KM, Opalach KJ, Wakefield D, Jacob RP, Yachnis AT, Lister JR, *et al.* The central nervous system solitary fibrous tumor: A review of clinical, imaging and pathologic findings among all reported cases from 1996 to 2010. *Clin Neurol Neurosurg* 2011;113:703-10.
- Fritchie K, Jensch K, Moskalev EA, Caron A, Jenkins S, Link M, *et al.* The impact of histopathology and NAB2-STAT6 fusion subtype in classification and grading of meningeal solitary fibrous tumor/hemangiopericytoma. *Acta Neuropathol* 2019;137:307-19.
- Ghia AJ, Allen PK, Mahajan A, Penas-Prado M, McCutcheon IE, Brown PD, *et al.* Intracranial hemangiopericytoma and the role of radiation therapy: A population based analysis. *Neurosurgery* 2013;72:203-9.
- Ghia AJ, Chang EL, Allen PK, Mahajan A, Penas-Prado M, McCutcheon IE, *et al.* Intracranial hemangiopericytoma: Patterns of failure and the role of radiation therapy. *Neurosurgery* 2013;73:624-30.
- Ghose A, Guha G, Kundu R, Tew J, Chaudhary R. CNS hemangiopericytoma: A systematic review of 523 patients. *Am J Clin Oncol* 2017;40:223-7.
- Guthrie BL, Ebersold MJ, Scheithauer BW, Shaw EG. Meningeal hemangiopericytoma: Histopathological features, treatment, and long-term follow-up of 44 cases. *Neurosurgery* 1989;25:514-22.
- Hukill PB, Lowman RM. Visceral metastasis from a meningioma: Report of a case. *Ann Surg* 1960;152:804-8.
- Iwamuro M, Nakamura S, Shiraha H, Kobayashi Y, Fukatsu H, Yamamoto K, *et al.* A case of primary intracranial hemangiopericytoma with hepatic metastases: Successful treatment with radiofrequency ablation and transcatheter arterial chemoembolization. *Clin J Gastroenterol* 2009;2:30-5.
- Kaley TJ, Wen P, Schiff D, Ligon K, Haidar S, Karimi S, *et al.* Phase II trial of sunitinib for recurrent and progressive atypical and anaplastic meningioma. *Neuro Oncol* 2015;17:116-21.
- Kamamoto D, Ohara K, Kitamura Y, Yoshida K, Kawakami Y, Sasaki H, *et al.* Association between programmed cell death ligand-1 expression and extracranial metastasis in intracranial solitary fibrous tumor/hemangiopericytoma. *J Neurooncol* 2018;139:251-9.
- Kaneko T, Harada A, Isshiki K, Murakami H, Nakao A, Nonami T, *et al.* Hemangiopericytomatous meningioma metastasized to the liver: Report of a case and review of the literature. *Surg Today* 1993;23:644-8.
- Kim BS, Kim Y, Kong DS, Nam DH, Lee JI, Suh YL, *et al.* Clinical outcomes of intracranial solitary fibrous tumor and hemangiopericytoma: Analysis according to the 2016 WHO classification of central nervous system tumors. *J Neurosurg* 2018;129:1384-96.
- Kim JH, Jung HW, Kim YS, Kim CJ, Hwang SK, Paek SH, *et al.* Meningeal hemangiopericytomas: Long-term outcome and biological behavior. *Surg Neurol* 2003;59:47-53.

23. Kinslow CJ, Bruce SS, Rae AI, Sheth SA, McKhann GM, Sisti MB, *et al.* Solitary-fibrous tumor/hemangiopericytoma of the central nervous system: A population-based study. *J Neurooncol* 2018;138:173-82.
24. Lee SJ, Kim ST, Park SH, Choi YL, Park JB, Kim SJ, *et al.* Successful use of pazopanib for treatment of refractory metastatic hemangiopericytoma. *Clin Sarcoma Res* 2014;4:13.
25. Lo RC, Suriawinata AA, Rubin BP. Liver metastasis of meningeal hemangiopericytoma: A study of 5 cases. *Clin Mol Hepatol* 2016;22:188-91.
26. Louis DN, Perry A, Reifenberger G, von Deimling A, Figarella-Branger D, Cavenee WK, *et al.* The 2016 world health organization classification of tumors of the central nervous system: A summary. *Acta Neuropathol* 2016;131:803-20.
27. Manatakis DK, Delis SG, Ptohis N, Korkolopoulou P, Dervenis C. Multidisciplinary approach to hepatic metastases of intracranial hemangiopericytoma: A case report and review of the literature. *Case Rep Oncol Med* 2015;2015:214306.
28. Melone AG, D'Elia A, Santoro F, Salvati M, Delfini R, Cantore G, *et al.* Intracranial hemangiopericytoma our experience in 30 years: A series of 43 cases and review of the literature. *World Neurosurg* 2014;81:556-62.
29. Nickerson TP, Fahy AS, Bingener J. Laparoscopic resection of intra-abdominal metastasis from intracranial hemangiopericytoma. *Int J Surg Case Rep* 2015;15:50-3.
30. Niwa M, Kobayashi T, Kuchiwaki H, Furuse M. A case of hemangiopericytoma with multiple extracranial metastasis: A case report. *No Shinkei Geka* 1998;26:241-5.
31. Park MS, Patel SR, Ludwig JA, Trent JC, Conrad CA, Lazar AJ, *et al.* Activity of temozolomide and bevacizumab in the treatment of locally advanced, recurrent, and metastatic hemangiopericytoma and malignant solitary fibrous tumor. *Cancer* 2011;117:4939-47.
32. Patel AR, Flores BC, Ban VS, Hatanpaa KJ, Mickey BE, Barnett SL, *et al.* Intracranial hemangiopericytomas: Recurrence, metastasis, and radiotherapy. *J Neurol Surg B Skull Base* 2017;78:324-30.
33. Ramakrishna R, Rostomily R, Sekhar L, Rockhill J, Ferreira M. Hemangiopericytoma: Radical resection remains the cornerstone of therapy. *J Clin Neurosci* 2014;21:612-5.
34. Ratneswaren T, Hogg FR, Gallagher MJ, Ashkan K. Surveillance for metastatic hemangiopericytoma-solitary fibrous tumors-systematic literature review on incidence, predictors and diagnosis of extra-cranial disease. *J Neurooncol* 2018;138:447-67.
35. Rutkowski MJ, Sughrue ME, Kane AJ, Aranda D, Mills SA, Barani IJ, *et al.* Predictors of mortality following treatment of intracranial hemangiopericytoma. *J Neurosurg* 2010;113:333-9.
36. Schiariti M, Goetz P, El-Maghraby H, Tailor J, Kitchen N. Hemangiopericytoma: Long-term outcome revisited. *Clinical article. J Neurosurg* 2011;114:747-55.
37. Schutz FA, Choueiri TK, Sternberg CN. Pazopanib: Clinical development of a potent anti-angiogenic drug. *Crit Rev Oncol Hematol* 2011;77:163-71.
38. Spatola C, Privitera G. Recurrent intracranial hemangiopericytoma with extracranial and unusual multiple metastases: Case report and review of the literature. *Tumori* 2004;90:265-8.
39. Trifiletti DM, Mehta GU, Grover S, Sheehan JP. Clinical management and survival of patients with central nervous system hemangiopericytoma in the national cancer database. *J Clin Neurosci* 2017;44:169-74.
40. Yoshida K, Yamazaki S, Ota K, Makuuchi M, Hasegawa H, Takayasu K, *et al.* A case report of meningioma with multiple liver metastases. *Kanzo* 1988;29:1528-34.
41. Zhang GJ, Zhang LW, Li D, Wu Z, Zhang JT. Analysis of prognostic factors, survival rates, and treatment in anaplastic hemangiopericytoma. *World Neurosurg* 2017;104:795-801.
42. Zweckberger K, Jung CS, Mueller W, Unterberg AW, Schick U. Hemangiopericytomas grade II are not benign tumors. *Acta Neurochir (Wien)* 2011;153:385-94.

How to cite this article: Reddy S, Plitt A, Raisanen J, Patel AR, Gopal P, Timmerman R, *et al.* Intracranial anaplastic hemangiopericytoma presenting with simultaneous extracranial metastases: A case report and review of the literature. *Surg Neurol Int* 2019;10:148.