

# Comparison of mid-term outcomes of posterior or postero-anterior approach using different bone grafting in children with lumbar tuberculosis

Hongqi Zhang, MD, Qiang Guo, MD, Shaohua Liu, MD, Chaofeng Guo, MD, Qile Gao, MD, Mingxing Tang, MD\*

## Abstract

The anterior and middle columns instead of the posterior column of spine are usually destroyed by tuberculosis which could aggravate the kyphosis accompanying the growth imbalance of spine in children. The surgical method needs to be selected cautiously for effective treatment. To our knowledge, few studies have evaluated mid-term outcomes of 2 surgeries (posterior-only approach and combined posterior and anterior approaches) with allograft or shaped titanium mesh cages for the treatment of lumbar tuberculosis in children. The study aims to compare the surgical mid-term outcomes of the posterior-only approach and the combined approaches using different bone grafting for the treatment of pediatric lumbar tuberculosis.

Between January 2007 and June 2013 at our spine center, 51 consecutive pediatric lumbar tuberculosis with an average age of  $7.3 \pm 3.93$  years treated with combined posterior and anterior approaches (PA, 22 cases) or posterior-only approach (PO, 29 cases) were enrolled. Two types of interbody bone graft were applied in this study: fresh-frozen tricortical iliac-bone allograft (AG, 21 cases) and shaped titanium mesh cages (TM, 30 cases). All medical records and radiographs were retrospectively reviewed. The Japanese Orthopaedic Association (JOA) is applied to evaluate the neurological function. The average visual analogue (VAS) and Oswestry Disability Index (ODI) were used to evaluate the quality of life.

The average follow-up was  $6.7 \pm 1.9$  years. The mean operation time, average blood loss, complication rate, and lengths of hospital stay of PO were less than those of the PA. The postoperative VAS (1 day after surgery) of PA was significantly higher than that of PO. The ODI, VAS and JOA scores at the final follow-up had been improved significantly compared with preoperative scores. The ODI, VAS and JOA scores at the final follow-up were similar between PA and PO as well as between AG and TM. There was no statistically significant difference about the fusion times between PO and PA groups. The final follow-up kyphosis correction rate and the correction loss at the final follow-up between the PO and PA groups showed no statistically significant difference. However, the final follow-up correction rate of the AG group was lower than that of TM group. The correction loss of the AG group was higher than that of TM group.

The posterior only approach in experienced hands provides satisfying treatment for the children lumbar tuberculosis with less invasive, much safer, and more effective compared with combined posterior and anterior approach. The shaped titanium mesh cages are noted to be a valuable tool in surgical decision making.

**Abbreviations:** AG group = fresh-frozen tricortical iliac-bone allograft group, E = ethambutol, ESR = erythrocyte sedimentation rate, H = isoniazid, HIV = human immunodeficiency virus, JOA = Japanese Orthopaedic Association, ODI = Oswestry Disability Index, PA approach = combined posterior and anterior approaches, PO approach = posterior-only approach, R = rifampin, STB = spine tuberculosis, TB = tuberculosis, TM group = shaped titanium mesh cages group, VAS = average visual analogue, WHO = world health organization.

**Keywords:** allograft, combined posterior and anterior approach, lumbar tuberculosis, outcomes, pediatrics, posterior approach only, surgical approach, titanium mesh

Editor: Johannes Mayr.

This study was supported by the Natural Science Foundation of Hunan Province (No. 2017JJ3338), China.

This study was approved by Xiangya Hospital Ethics Committee of Xiangya Hospital Central South University.

Written informed consent was acquired from the guardian of each patient to authorize treatment, image findings, and photographic documentation.

The authors declare that they have no conflict of interest.

Department of Spine Surgery, Xiangya Hospital of Central South University, Changsha, China.

\* Correspondence: Mingxing Tang, Department of Spine Surgery, Xiangya Hospital of Central-South University, 87 XiangYa Road, Changsha 410008, Hunan, China (e-mail: spinetmx@sina.com).

Copyright © 2019 the Author(s). Published by Wolters Kluwer Health, Inc.

This is an open access article distributed under the terms of the Creative Commons Attribution-Non Commercial-No Derivatives License 4.0 (CCBY-NC-ND), where it is permissible to download and share the work provided it is properly cited. The work cannot be changed in any way or used commercially without permission from the journal.

Medicine (2019) 98:10(e14760)

Received: 30 October 2018 / Received in final form: 25 January 2019 / Accepted: 6 February 2019

<http://dx.doi.org/10.1097/MD.00000000000014760>

## 1. Introduction

According to the World Health Organization global tuberculosis report 2017, an estimated 10.4 million incident tuberculosis cases occurred worldwide in 2016, of which 1 million were children. Children are more likely to develop a serious form of spinal tuberculosis (STB) because of the combined effects of risk factors such as malnutrition, human immunodeficiency virus, and weak immune systems.<sup>[1]</sup> The plight of children with tuberculosis (TB) has been widely recognized and is increasingly becoming a priority for national TB control programs.<sup>[2]</sup>

STB needs to be treated carefully in children owing to their anatomical features and potential for bone growth.<sup>[3]</sup> Otherwise, kyphosis can develop that will not only affect the child's appearance of children but often leads to cardiopulmonary insufficiency, nerve compression, and paralysis. Drugs are still the cornerstone of anti-tuberculosis management. However, it should be noted kyphosis may still progress if using chemotherapy alone, even after clinical cure. Although various surgical approaches have been reported,<sup>[4–6]</sup> children with STB are still challenging to treat. A combined posterior and anterior approach (PA approach) is the standard surgical intervention, but large trauma leading to an extended recovery time cannot be ignored, especially for children.<sup>[7,8]</sup> Recently, the posterior-only approach (PO approach) has been reported to be an effective treatment for STB with a minimum amount of trauma in an adult-based study with a medium-term follow-up duration.<sup>[9–11]</sup> We have also conducted a preliminary study concluding that the PO approach was an effective treatment for children with STB and could prevent the progression of kyphosis.<sup>[12–15]</sup> There is very little information in the current literature regarding long-term follow-up of any type of surgery for STB in children.

Thus, we conducted a retrospective comparative study on the mid-term surgical outcomes of the PO and PA approaches for the treatment of pediatric lumbar tuberculosis.

## 2. Patients and methods

### 2.1. Population and clinical presentation

The inclusion criteria for the study were: age <18 years; the lesions were restricted to 1 segment or 2 adjacent segments (or if multiple segments were involved, only 1 or 2 vertebral bodies needed to be addressed surgically); active lumbar tuberculosis confirmed pathologically; failure of chemotherapy only; a minimum of 5 years of follow-up. Patients with a history of spinal surgery, congenital spinal deformity, or other medical history that would influence the postoperative evaluation were excluded.

Between January 2007 and June 2013 at our spine center, a total of 51 consecutive pediatric patients with lumbar tuberculosis

treated with a PA approach (22 cases) or a PO approach (29 cases) were enrolled. The ratio of boys to girls was 1:3. The average age was  $7.3 \pm 3.93$  years (range, 2–17) at the time of surgery. Two types of interbody bone graft were applied in this study: fresh-frozen tricortical iliac-bone allograft (AG group, 21 cases) and shaped titanium mesh cages (TM group, 30 cases). The average erythrocyte sedimentation rate (ESR) was  $53.25 \pm 10.37$  mm/h (range, 19–78) preoperatively (Table 1). The local kyphosis angle was measured on the lateral plain film by drawing 2 lines, one parallel to the superior surface of the cephalic vertebra of the diseased segments and the other parallel to the inferior surface of the caudal vertebra of the diseased segments, with the kyphosis angle at their intersection. The kyphosis angle value was negative for lumbar lordosis and positive for local kyphosis. The average preoperative local kyphosis angle was  $26.53 \pm 8.17^\circ$  (range, 3–42°). The mean preoperative Japanese Orthopaedic Association (JOA) score was  $20.1 \pm 4.6$  (range, 13–29). The average preoperative visual analog scale (VAS) was  $5.5 \pm 2.5$ . Clinical outcomes were also assessed using the Oswestry Disability Index (ODI) questionnaire.

Anti-tuberculosis treatment lasted at least 2 weeks preoperatively. Children weighing <10 kg were treated with rifampin 75 mg/d, isoniazid 75 mg/d, and ethambutol 200 mg/d. The doses were doubled, tripled, and quadrupled when the weight ranges were 10 to 17 kg, 18 to 25 kg, and >25 kg, respectively.<sup>[16]</sup> The treatment plans were formed in consultation with pediatricians, and the side effects were monitored closely and carefully. The same surgeons assessed the surgical indications and performed the procedures. This study was approved by the ethics committee at our institution (No. 201303232). Written informed consent was acquired from the patients' legal guardians to authorize treatment, imaging, and photographic documentation.

### 2.2. Surgical procedures

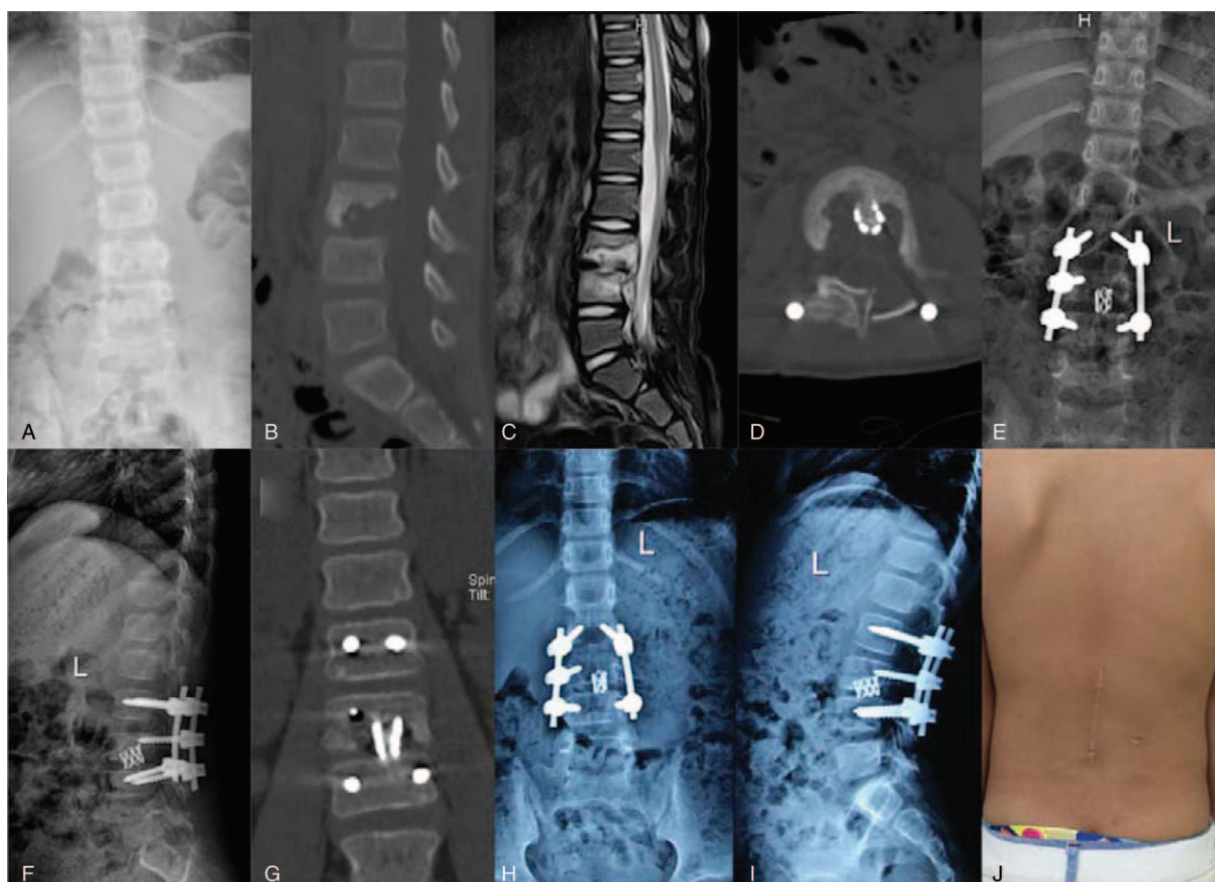
**2.2.1. PO approach.** Under general anesthesia with somatosensory-evoked potential monitoring, the children were placed prone position. A midline incision was made, and the vertebral levels were exposed subperiosteally. Pedicle screws were installed at 1 or 2 levels above and below to the level of decompression to provide short segmental fixation. The affected vertebrae were also affixed by the screw if the upper part had not been destroyed. One rod at the mildly affected side of the lesion was then fixed temporarily to avoid spinal cord injury and focal debridement during decompression and focal debridement. The next step included lesion debridement to drain the prevertebral abscess and expose the diseased vertebral bodies at the worse side of the affected vertebrae. After that, all lesions (sequestra, abscesses, and granulated tissue) were removed by using various spatulas under direct vision. Abscesses were drained by inserting a catheter directly into the cavity. Permanent rods were then placed to correct the deformity. The prepared fresh-frozen tricortical iliac-bone allograft or shaped titanium mesh cages filled with autogenous bone (healthy lamina, spinous process) on both sides and allograft bone in the middle according to the cavity width and length were installed into the interbody. The 2 rods were compressed to tighten the cage and then fixed in position. The strip-sized autogenous or allograft bone was imbedded in the posterior body to fuse the segments of the defect. Drainage was performed properly (Fig. 1).

**2.2.2. PA approach.** Under general anesthesia with somatosensory-evoked potential monitoring, we conducted single-stage or two-stage posterior instrumentation, anterior debridement, and reconstruction. The posterior instrumentation was the same as

**Table 1**  
Clinical data of patients.

	PO group	PA group	P
Gender (M/F)	12/17	10/12	.771
Age, y	$7.0 \pm 3.93$	$8.17 \pm 4.27$	.775
Duration of the disease, mo	$5.30 \pm 1.90$	$5.45 \pm 2.23$	.934
Follow-up, y	$6.9 \pm 1.5$	$6.5 \pm 2.0$	.800
ESR, mm/h	$54.33 \pm 17.21$	$54.12 \pm 17.99$	.990
Complication rate (%)	10.30%	22.70%	.415

Analysis of variance is used to assess the differences between the clinical results for each group. When the *P* value >.05, there is no statistically significant difference between the groups. ESR = erythrocyte sedimentation rate; PA = posterior and anterior approach; PO = posterior-only approach.



**Figure 1.** A 7-year-old boy with spinal tuberculosis in L3 to L4. (A–C) Preoperative images showing the collapse of vertebral body and formation of sequestra and abscess. (D) The patient was treated with posterior-only approach with shaped titanium mesh cage; (E–F) postoperative x-ray demonstrating good internal fixation; (G) 7-month follow-up image showing good bone fusion; (H–J) 5-year follow-up images showing good bone fusion and no looseness, displacement, dislocation of cage.

that of the PO approach. For patients in a poor general condition, 2-stage management was preferred and the interval between the 2 operations was 2 weeks. In the anterior procedure, a lateral decubitus position was used, placing the severely involved side upward. An oblique hypogastric incision was made according to the tuberculosis lesion segment. After routine retroperitoneal exposure, the focus was cleared completely, and allograft or shaped titanium mesh cages were installed into the interbody. Finally, hemostasis was obtained, and the incision was closed in layers over the suction drains (Fig. 2).

### 2.3. Postoperative management

For children with low compliance and weakened bones, both the PO and PA groups were directed to stay in bed and wear the external brace to prevent spine over-activity, which could result in internal fixation loosening and screw cutting. We adopted a chemotherapy regimen of 2HRE/9-12HR. Other postoperative treatments included improved nutritional intake, with specific nutrition for the nerves, and functional rehabilitation exercises. Regular follow-ups were performed.

### 3. Statistical analysis

The results were recorded and analyzed using paired Student *t* tests, Student–Newman–Keuls tests and analyses of variance

using SPSS software version 22.0 (IBM Corp. Armonk, NY). A *P* value of  $<.05$  was considered to be statistically significant.

## 4. Results

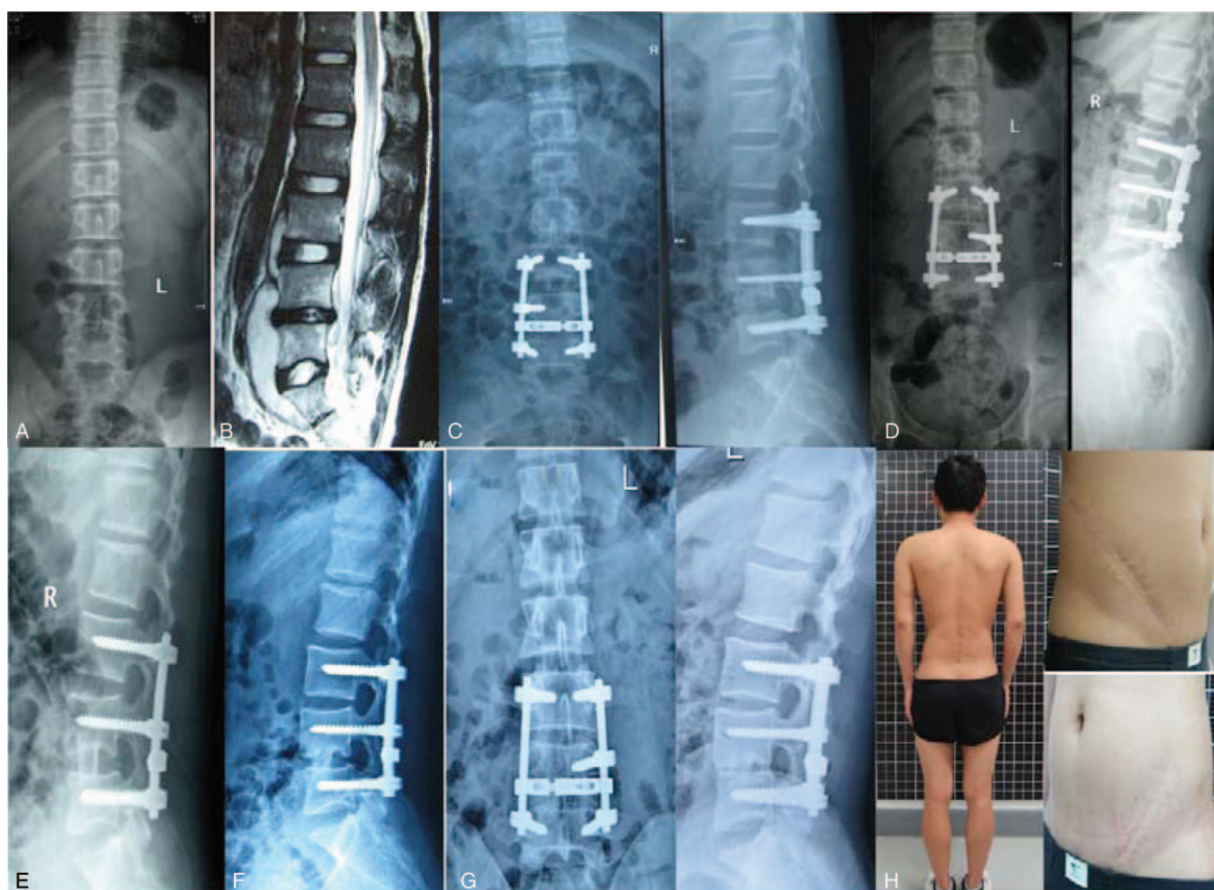
### 4.1. Clinical data

The average follow-up duration was  $6.7 \pm 1.9$  years. At the final follow-up visit, all patients were diagnosed with a clinical cure of STB based on the following: good general condition, normal body temperature, and good appetite; no pain, no abscess, and no inflammation on imaging studies; and normal ESR on at least 3 tests. The ESR was back to normal in all patients in 3 months postoperatively.

### 4.2. Injury indicators

For the PO group, the mean operation time and average blood loss were  $210.63 \pm 29.08$  minutes (range, 176–250) and  $329.5 \pm 60.87$  mL (range, 210–415) respectively; in the PA group, they were  $329.5 \pm 60.87$  minutes (range, 200–350) and 420 mL (range, 150–450), respectively. The mean operation time of the PO group was less than that of the PA group ( $P=.013$ ). The average blood loss of the PO group was less than that of the PA group ( $P=.009$ ). The average lengths of hospital stay for the PO and PA groups was  $13 \pm 3.2$  days and  $19 \pm 2.1$  days, respectively ( $P=.032$ ) (Table 2).





**Figure 2.** A 14-year-old boy with spinal tuberculosis in L4 to L5 and large abscess. (A–B) Preoperative images showed destruction of vertebral body and large abscess resulted in the spinal instability; (C) the patient was treated with combined posterior and anterior approaches with allograft. As the patients had large abscess on both sides, another incision was made on the other side to remove the abscess. Postoperative x-ray displayed good internal fixation and the satisfied height of the graft; (D–F) 3 months, 6 months, 18 months follow-up after operation showed bone fusion; (G) 7-year follow-up x-ray displayed the loss of correction angle and graft height; (H) the incisions of the patients in 7-year follow-up.

The mean preoperative VAS of the PA group, PO group, AG group, and TM group was  $5.2 \pm 2.5$ ,  $5.8 \pm 2.6$ ,  $5.3 \pm 2.2$ , and  $5.7 \pm 2.7$ , respectively; the mean postoperative VAS (1 day after surgery) was  $6.4 \pm 1.5$ ,  $4.8 \pm 1.2$ ,  $5.7 \pm 2.8$ , and  $5.9 \pm 2.2$ , respectively. The mean VAS at the last follow-up visit in the PO group, PA group, AG group, and TM group were  $1.5 \pm 1.0$ ,  $1.6 \pm 1.2$ ,  $1.5 \pm 1.1$ , and  $1.6 \pm 1.2$ , respectively. There was no difference in VAS preoperatively. However, the postoperative VAS (1 day after surgery) in the PO group was lower than that in the PA group. No significant difference in VAS was found among the groups at the final follow-up (Table 3).

**Table 2**  
Injury indicators of 2 groups for lumbar tuberculosis in children.

	PO group	PA group
Operation time, min	$210.63 \pm 29.08$	$292.30 \pm 44.52^*$
Blood loss, mL	$282.42 \pm 62.35$	$366.92 \pm 74.39^*$
The length of hospital-stay, d	$13 \pm 3.2$	$19 \pm 2.1^*$
Mean fusion time, mo	$5.2 \pm 1.1$	$4.9 \pm 1.3$

PA=posterior and anterior approach, PO=posterior-only approach.

\*  $P < .05$  compared with PO group.

#### 4.3. Radiological indicators

Fusion times in the PO and PA groups were  $5.2 \pm 1.1$  months and  $4.9 \pm 1.3$  months, respectively. There was no statistically significant difference (Table 2).

In the PO group, the kyphosis angle was  $11^\circ$  to  $45^\circ$  with mean kyphosis angle of  $31.9 \pm 10.4^\circ$  preoperatively; it significantly decreased to  $-2^\circ$  to  $19^\circ$  with a mean kyphosis angle of  $5.3 \pm 6.7^\circ$  postoperatively; the kyphosis angle was  $-4^\circ$  to  $21^\circ$  with a mean kyphosis angle of  $6.6 \pm 8.0^\circ$  at the final follow-up. In the PA group, the kyphosis angle was  $18^\circ$  to  $49^\circ$  with a mean kyphosis angle of  $30.1 \pm 10.2^\circ$  preoperatively; it significantly decreased to  $-2^\circ$  to  $13^\circ$  with a mean kyphosis angle of  $4.8 \pm 5.6^\circ$  postoperatively; the kyphosis angle was  $-4^\circ$  to  $11^\circ$  with a mean kyphosis angle of  $5.6 \pm 6.0^\circ$  at the final follow-up. In the AG group, the kyphosis angle was  $13^\circ$  to  $49^\circ$  with a mean kyphosis angle of  $30.7 \pm 10.9^\circ$  preoperatively; it significantly decreased to  $-2^\circ$  to  $16^\circ$  with a mean kyphosis angle of  $5.7 \pm 6.0^\circ$  postoperatively; the kyphosis angle was  $-2^\circ$  to  $20^\circ$  with a mean kyphosis angle of  $6.9 \pm 6.3^\circ$  at the final follow-up. In the TM group, the kyphosis angle was  $11^\circ$  to  $42^\circ$  with a mean kyphosis angle of  $31.3 \pm 10.4^\circ$  preoperatively; it significantly decreased to  $-2^\circ$  to  $19^\circ$  with a mean kyphosis angle of  $4.4 \pm 6.4^\circ$  postoperatively; the kyphosis angle was  $-4^\circ$  to  $21^\circ$  with a mean kyphosis angle of  $5.3 \pm 6.2^\circ$  at the final follow-up (Table 4).

The final follow-up kyphosis correction rate and the correction loss at the final follow-up between the PO and PA groups showed

**Table 3**  
**VAS and ODI of 4 groups for lumbar tuberculosis in children.**

	VAS			ODI	
	Preop	Postop <sup>§</sup>	Final follow-up	Preop	Final follow-up
PA group	5.2±2.5	6.4±1.5*	1.5±1.0 <sup>#</sup>	46.2±3.0	11.3±3.4 <sup>#</sup>
PO group	5.8±2.6	4.8±1.2	1.6±1.2 <sup>#</sup>	44.4±3.2	9.8±3.5 <sup>#</sup>
AG group	5.3±2.2	5.7±2.8	1.5±1.1 <sup>#</sup>	43.6±3.1	11.5±3.0 <sup>#</sup>
TM group	5.7±2.7	5.9±2.2	1.6±1.2 <sup>#</sup>	45.0±3.3	11.6±3.6 <sup>#</sup>

AG=allograft, ODI=Oswestry Disability Index, PA=posterior and anterior approach, PO=posterior-only approach, TM=titanium mesh, VAS=average visual analogue.

<sup>§</sup> 1 day after surgery.

\*  $P < .05$  compared with PO group.

<sup>#</sup>  $P < .05$  compared with preoperation.

no statistically significant difference. The final follow-up correction rate of the AG group was lower than that of TM group ( $P = .001$ ). The correction loss of the AG group was higher than that of TM group ( $P = .021$ ).

#### 4.4. Neurological indicators

The JOA of the PO and PA groups changed from 22 (range, 14–29) and 21.53 (range, 14–27) preoperatively to 28.3 (range, 28–29) and 28.6 (range, 27–29), respectively, postoperatively. The mean ODI scores were 46.2±3.0 versus 44.4±3.2 preoperatively and 11.3±3.4 versus 9.8±3.5 postoperatively for PA and PO, respectively. The average ODI scores were 43.6±3.1 versus 45.0±3.3 preoperatively and 11.5±3.0 versus 11.6±3.6 postoperatively for the AG and TM groups, respectively (Tables 3 and 4).

#### 4.5. Complications

In the PO group: 1 patient had a dural tear and an intraoperative cerebrospinal fluid leak caused by intraoperative separation of the spinal dura mater. One patient had delayed wound healing due to malnutrition. Abscess recurrence occurred in 1 patient owing to poor compliance, mainly premature removal of the external brace and irregular medical treatment. In the PA group, 2 patients had postoperative infection despite antibiotic treatment, and both patients recovered. One patient had sinus formation. Two patients displayed paralytic ileus after routine nasogastric decompression treatments, and this was relieved.

### 5. Discussion

STB in children has distinguishing features from adult STB: more segments of the spine are often involved in children compared with adults owing to children's cartilage composition containing

rich blood and lymphatic vessels; STB in children is more likely to cause spinal cord compression because of the narrower spinal canal; abscesses spread more easily owing to loose attachment between the fascia and the vertebrae; kyphosis and gibbus deformities are more likely to occur as a result of imbalanced growth between the easily affected anterior-middle and posterior parts of the spine, especially during the growth spurt; and TB poisoning symptoms such as comorbid night crying, growth retardation, or anorexia are not typical.

The option of chemotherapy treatment only should be offered to children with mild spinal tuberculosis although the indication for conservative treatment for children with STB is a matter of continuing debate. Chemotherapy treatment with bed rest and bracing often requires a very long recovery time. For some children with STB, surgery is urgently needed combined with chemotherapy, if treated improperly, spinal deformation and impaired nerve function will develop and even worsen.<sup>[17]</sup> Adult STB, when treated conservatively, has a mean 15° increase in kyphosis, and 5% of these patients eventually develop over a 60° deformity.<sup>[18,19]</sup> The risk in children is even higher, with severe deformities of >90° developing in 10% of patients. Kyphosis may increase even after cure of tuberculosis in children.<sup>[20]</sup> In addition, the altered biomechanics could affect the child's deformed spine morphology and initiate a vicious cycle.<sup>[21–24]</sup> It is vital to identify patients susceptible to kyphosis and take effective measures to prevent and correct spinal deformities.

The surgical purpose of pediatric spinal surgery is to remove the focus, decompress the nerves, correct the spinal deformity, and retain spinal stability with full consideration of the growth characteristics of children. Two commonly used approaches adopted in childhood spinal TB are the PO approach and the PA approach. Our study showed that the kyphosis correction effect, neurological improvement, and ODI scores of the 2 approaches are similar without a significant difference. The PA approach,

**Table 4**  
**Radiological and neurological indicators of 4 groups for lumbar tuberculosis in children.**

	Local kyphotic angle (°)			JOA	
	Preop	Postop	Final follow-up	Preop	Final follow-up
PO group	31.9±10.4	5.3±6.7*	6.6±8.0*	19.2±6.3	28.33±0.47*
PA group	30.1±10.2	4.8±5.6*	5.6±6.0*	18±6.1	28.67±0.47*
AG group	30.7±10.9	5.7±6.0*	6.9±6.3*	18.7±6.0	28.35±0.42*
TM group	31.3±10.4	4.4±6.4*	5.3±6.2*	18.5±6.5	28.65±0.45*

There is no statistic difference between postop group and final follow-up group. AG=allograft, JOA=Japanese Orthopaedic Association, PA=posterior and anterior approach, PO=posterior-only approach, TM=titanium mesh.

\*  $P < .05$  compared with preop data.

however, has the disadvantage of longer operating times, more blood loss, a longer hospital stay, more extensive surgical trauma, and more complications compared with the PO approach. Moreover, the VAS (1 day after surgery) in the PO group was lower than that of the PA group from which we can infer that children in the PA group suffered more pain mainly because of the dual incisions. A less invasive, more effective, and much safer posterior only approach is the purpose of the current trend in surgical developments, especially for children. It avoids complex anatomical structures in the retroperitoneal region and reduces the possibility of injury of large vessels and vital organs. Through only one incision in the posterior spine, we can remove the focus and abscess as completely as possible on or around the vertebral body at a 270° angle under direct visualization without injury to the spinal cord. The range of debridement includes dead bone and abscess, necrotic, and granulated tissues. Concurrently, the kyphosis can be corrected by using a suitable pedicle screw to maintain as much healthy bone tissue as possible to fix segments as short as possible to avoid interference with spinal growth. One way to reduce the range of fixed segments is to implant a pedicle screw in the affected segment. To increase the holding power of the screw, it is better not to use the screw tap when reaming holes. This approach partially destroys the posterior vertebra and some are concerned that it may cause iatrogenic spinal instability. However, no implant or fusion failures occurred in our study. This appears to be owing to several reasons: a suitable strong pedicle screw; adequate bone grafts (allografts or shaped titanium mesh cages and posterior bone grafts); and strict operative indications (<2 vertebral bodies affected with a small paravertebral abscess).

Postoperative complications are usually linked to drug resistance, irregular medication, low compliance, malnutrition, and the wrong choice of surgical method instead of the surgical method itself. The surgery cannot correct kyphosis but induces deformity if improperly used. A detailed and carefully prepared preoperative program can improve the success rate of surgery and reduce complications. For multi-level STB in children, we still prefer to use a combined approach. There still remain concerns regarding the best time to remove the implants. If removed too early, we may risk further progress of kyphosis. According to a report that the usage of pedicle screws is possible without adverse effects in a growing child,<sup>[25]</sup> we recommend at present to remove the implants after 18 years of age. Of course, frequent follow-up will be necessary, especially during growth spurts.

Various kinds of graft materials such as autogenous rib, iliac crest, and allograft have been used for interbody fusion. Autogenous bone grafting is considered to be the standard in bone defect management. For children, the source of the autogenous bone is limited; the graft can fail because of subsequent slippage, fracture, absorption, or subsidence. For the allograft, limited source and graft failure may also occur. Some once argued against the use of metal materials because of the adherence of *Staphylococcus epidermidis* to orthopedic biomaterials and the possibility of bacterial infection.<sup>[26,27]</sup> Several researchers have recently confirmed the safety of titanium cages for the treatment of vertebral osteomyelitis.<sup>[28–30]</sup>

Device fracture complications related to titanium mesh cages are relatively uncommon,<sup>[31]</sup> which was verified in our study results. We used shaped titanium mesh cages filled with autogenous bone and allogeneic bone (if necessary) and obtained satisfactory correction results compared with the allograft group. However, the loss of correction in the allograft group is slightly more than that of the titanium mesh cage group (Fig. 2G). In

previous studies, fusion rates with titanium mesh were significantly higher than those with allograft bone fusion rates.<sup>[32]</sup> Bone fusion was seen in all cases, and no looseness, displacement, or dislocation of the bone grafts was found. There was no significant difference in the bone fusion time between the AG and TM groups. The rigidity and strength bearing quality of the shaped titanium mesh cages play a vital supporting role in combination with the pedicle screw. We can implant 1 or 2 shaped titanium mesh cages to ensure that sufficient contact area between the surface of the bone groove and bone graft area is achieved to satisfy the requirements for bone fusion. The device reduces the trauma and complications caused by autogenous iliac bone and resolves the problem of bone graft absorption in the long-term. It also overcomes the lack of autogenous bone and allograft in children. What is more important, titanium mesh cages can be shaped based on the intraoperative conditions and can thus meet the individual treatment needs. It is also helpful for patients with osteoporosis and poor iliac bone quality.<sup>[33]</sup> Moreover, the shaped cages can easily pass through the narrow operative opening can be placed at the ideal location. In turn, we also found minor correction loss in the titanium mesh cage group. We think the reason for the subsidence of the implant is the stiffness of the implant, which is different from that of bone. In the future, more research is needed to identify implant materials that are closer to the properties of bone.

Our study is not without limitations. These include its retrospective design, the small patient cohort, and its abbreviated postoperative follow-up. After maturity, the effect of fusion on the proximal and distal junction segments and the influence of degenerative changes is worthy of investigation. Secondly, more studies are warranted on some present shortcomings such as the best time for implant removal and more compatible implant material.

In conclusion, treatment with the posterior only approach conducted by experienced surgeons provides satisfying results for children with lumbar tuberculosis and is less invasive, much safer, and more effective than the PA approach. Shaped titanium mesh cages are also a valuable tool in surgical treatment.

## Author contributions

**Data curation:** Qile Gao.

**Formal analysis:** Qiang Guo, Shaohua Liu.

**Investigation:** Qiang Guo, Chaofeng Guo, Mingxing tang.

**Methodology:** Hongqi Zhang.

**Project administration:** Hongqi Zhang.

**Writing – original draft:** Qiang Guo, Chaofeng Guo, Qile Gao, Mingxing Tang.

**Writing – review & editing:** Hongqi Zhang, Shaohua Liu.

## References

- [1] Perez-Velez CM, Marais BJ. Tuberculosis in children. *N Engl J Med* 2012;367:348–61.
- [2] Marais BJ, Graham SM, Maeurer M, et al. Progress and challenges in childhood tuberculosis. *Lancet Infect Dis* 2013;13:287–9.
- [3] Sarwark J, Aubin CE. Growth considerations of the immature spine. *J Bone Joint Surg Am* 2007;89(suppl):8–13.
- [4] Zheng C, Li P, Kan W. Video-assisted thoracoscopic anterior surgery combined posterior instrumentation for children with spinal tuberculosis. *Eur J Pediatr Surg* 2014;24:83–7.
- [5] Vamvanij V, Ruangchainikom M, Thanapitsiri S, et al. The outcomes of combined posterior instrumentation and anterior radical debridement with fusion for multilevel spinal tuberculosis. *J Med Assoc Thai* 2014;97(suppl):S50–5.



- [6] Wang XT, Zhou CL, Xi CY, et al. Surgical treatment of cervicothoracic junction spinal tuberculosis via combined anterior and posterior approaches in children. *Chin Med J* 2012;125:1443–7.
- [7] Yin XH, Zhou ZH, Yu HG, et al. Comparison between the antero-posterior and posterior only approaches for treating thoracolumbar tuberculosis (T10-L2) with kyphosis in children: a minimum 3-year follow-up. *Childs Nerv Syst* 2016;32:127–33.
- [8] Zhang HQ, Li JS, Guo CF, et al. Two-stage surgical management using posterior instrumentation, anterior debridement and allografting for tuberculosis of the lower lumbar spine in children of elementary school age: minimum 3-year follow-up of 14 patients. *Arch Orthop Trauma Surg* 2012;132:1273–9.
- [9] Wang LJ, Zhang HQ, Tang MX, et al. Comparison of three surgical approaches for thoracic spinal tuberculosis in adult: minimum 5-year follow-up. *Spine (Phila Pa 1976)* 2017;42:808–17.
- [10] Zhang H, Guo Q, Guo C, et al. A medium-term follow-up of adult lumbar tuberculosis treating with 3 surgical approaches. *Medicine (Baltimore)* 2017;96:e8574.
- [11] Tang MX, Zhang HQ, Wang YX, et al. Treatment of spinal tuberculosis by debridement, interbody fusion and internal fixation via posterior approach only. *Orthop Surg* 2016;8:89–93.
- [12] Wang YX, Zhang HQ, Tang MX, et al. One-stage posterior focus debridement, interbody grafts, and posterior instrumentation and fusion in the surgical treatment of thoracolumbar spinal tuberculosis with kyphosis in children: a preliminary report. *Childs Nerv Syst* 2016;32:1495–502.
- [13] Hu X, Zhang H, Yin X, et al. One-stage posterior focus debridement, fusion, and instrumentation in the surgical treatment of lumbar spinal tuberculosis with kyphosis in children. *Childs Nerv Syst* 2016;32:535–9.
- [14] Zhang HQ, Wang YX, Guo CF, et al. One-stage posterior focus debridement, fusion, and instrumentation in the surgical treatment of cervicothoracic spinal tuberculosis with kyphosis in children: a preliminary report. *Childs Nerv Syst* 2011;27:735–42.
- [15] Zhang H, Guo Q, Wang Y, et al. The efficiency of the posterior-only approach using shaped titanium mesh cage for the surgical treatment of spine tuberculosis in children: a preliminary study. *J Orthop Surg (Hong Kong)* 2018;26:1–7.
- [16] Lodha R, Menon PR, Kabra SK. Concerns on the dosing of antitubercular drugs for children in RNTCP. *Indian Pediatr* 2008;45: 852–4.
- [17] Rajasekaran S. Buckling collapse of the spine in childhood spinal tuberculosis. *Clin Orthop Relat Res* 2007;460:86–92.
- [18] Rajasekaran S, Shanmugasundaram TK. Prediction of the angle of gibbus deformity in tuberculosis of the spine. *J Bone Joint Surg Am* 1987;69:503–9.
- [19] Tuli SM. Severe kyphotic deformity in tuberculosis of the spine. *Int Orthop* 1995;19:327–31.
- [20] Jain AK, Dhammi IK, Jain S, et al. Kyphosis in spinal tuberculosis - prevention and correction. *Indian J Orthop* 2010;44:127–36.
- [21] Moon MS, Kim I, Woo YK, et al. Conservative treatment of tuberculosis of the thoracic and lumbar spine in adults and children. *Int Orthop* 1987;11:315–22.
- [22] Moon MS. Tuberculosis of the spine. Controversies and a new challenge. *Spine (Phila Pa 1976)* 1997;22:1791–7.
- [23] Moon MS, Moon YW, Moon JL, et al. Conservative treatment of tuberculosis of the lumbar and lumbosacral spine. *Clin Orthop Relat Res* 2002;398:40–9.
- [24] Moon MS, Kim SS, Lee BJ, et al. Surgical management of severe rigid tuberculous kyphosis of dorsolumbar spine. *Int Orthop* 2011;35:75–81.
- [25] Ruf M, Harms J. Pedicle screws in 1- and 2-year-old children: technique, complications, and effect on further growth. *Spine (Phila Pa 1976)* 2002;27:E460–6.
- [26] Shida T, Koseki H, Yoda I, et al. Adherence ability of *Staphylococcus epidermidis* on prosthetic biomaterials: an in vitro study. *Int J Nanomedicine* 2013;8:3955–61.
- [27] Castellanos J, Gonzalez-Cuevas A, Sierra JM, et al. Adherence of *S. epidermidis* on different metals. A comparative in vitro study. *J Appl Biomater Funct Mater* 2014;12:141–4.
- [28] Lu DC, Wang V, Chou D. The use of allograft or autograft and expandable titanium cages for the treatment of vertebral osteomyelitis. *Neurosurgery* 2009;64:122–9. discussion 9-30.
- [29] Bhatia K, Frydenberg E, Steel T, et al. An anterior expandable titanium cage in *Mycobacterium avium* vertebral osteomyelitis. *J Clin Neurosci* 2011;18:431–4.
- [30] Talia AJ, Wong ML, Lau HC, et al. Safety of instrumentation and fusion at the time of surgical debridement for spinal infection. *J Clin Neurosci* 2015;22:1111–6.
- [31] Zhang H, Zeng K, Yin X, et al. Debridement, internal fixation, and reconstruction using titanium mesh for the surgical treatment of thoracic and lumbar spinal tuberculosis via a posterior-only approach: a 4-year follow-up of 28 patients. *J Orthop Surg Res* 2015;10:150.
- [32] Jacobs WC, Vreeling A, De Kleuver M. Fusion for low-grade adult isthmic spondylolisthesis: a systematic review of the literature. *Eur Spine J* 2006;15:391–402.
- [33] Yin XH, Liu ZK, He BR, et al. Single posterior surgical management for lumbosacral tuberculosis: titanium mesh versus iliac bone graft: a retrospective case-control study. *Medicine (Baltimore)* 2017;96:e9449.