

## Comparative study of outcomes between locking plates and three-dimensional plates in mandibular fractures

### ABSTRACT

**Objectives:** The objective was to compare the efficiency and assess postoperative complications of 2.00 mm unicortical locking plates and three-dimensional (3D) plates in surgical correction of uncomplicated mandibular fracture.

**Materials and Methods:** A prospective cohort study of twenty patients of uncomplicated mandibular fractures, who were operated either by noncompression unicortical 2-mm locking mini-plate or by noncompression unicortical 2-mm 3D mini-plate, were enrolled and followed up for the study outcomes such as operative time, postoperative infection, and postoperative occlusion.

**Results:** Majority of the patients (90%) were male who had road traffic accident. In 80% of cases, mandibular fracture site was parasymphysis. The mean operating time for 3D plates (43.20 min) was significantly lower than that for locking plates (54.82 min),  $P < 0.001$ . All cases operated by 3D plates compared to 60% by locking mini-plates did not need intermaxillary fixation,  $P = 0.025$ . The 80% of cases operated by 3D plates did not require postoperative occlusion correction compared to 30% in another group,  $P = 0.01$ . For other parameters such as postoperative sensory disturbance, postoperative infection, incidence tooth damage, vertical displacement of mandible, feeling of plate after plating, and chewing efficiency after 1 week, there were no statistical significant differences between the two groups.

**Conclusions:** The outcome of 2.0mm 3D mini-plate is better in terms of operating time required, post-operative need of intermaxillary fixation and occlusal correction. While the outcome is similar to the use of non-compression unicortical 2.00mm locking miniplate in parameters like infection rate and incidence of tooth damage etc.

**Keywords:** Locking plate, mandibular fracture, three-dimensional plate

### INTRODUCTION

The position of the mandible on face makes it vulnerable to fracture when someone is involved in an unfortunate event leading to maxillofacial trauma. Over the years, the management of mandibular fractures has evolved significantly. The treatment modalities have ranged from conservative measures such as splints or arch bar fixation to open reduction with fixation.<sup>[1,2]</sup> Open reduction and internal fixation should be preferred unless contraindicated. However, un-displaced hairline fracture may be treated by closed reduction only.

In the contemporary surgical scenario, mandibular fractures are treated utilizing rigid or without the need of additional fixation techniques, which allow immediate function which

is necessary for most of the mandibular fractures. Recently, new techniques using internal fixation have been introduced which allows immediate function not necessitating the need

**SHAIKH AMJAD, MD KALIM ANSARI<sup>1</sup>, SYED S. AHMAD<sup>1</sup>, TABISHUR RAHMAN<sup>1</sup>**

Department of Dentistry, Indian Institute of Medical Sciences and Research, Jalna, Maharashtra, <sup>1</sup>Department of Oral and Maxillofacial Surgery, Aligarh Muslim University, Aligarh, Uttar Pradesh, India


**Address for correspondence:** Dr. Shaikh Amjad, Department of Dentistry, Indian Institute of Medical Sciences, Jalna - 431 202, Maharashtra, India.  
E-mail: drshaikhamjad@gmail.com

**Received:** 30 August 2019, **Revised:** 03 January 2020, **Accepted:** 09 May 2020, **Published:** 16 December 2020

This is an open access journal, and articles are distributed under the terms of the Creative Commons Attribution-NonCommercial-ShareAlike 4.0 License, which allows others to remix, tweak, and build upon the work non-commercially, as long as appropriate credit is given and the new creations are licensed under the identical terms.

**For reprints contact:** WKHLRPMedknow\_reprints@wolterskluwer.com

**How to cite this article:** Amjad S, Kalim Ansari MD, Ahmad SS, Rahman T. Comparative study of outcomes between locking plates and three-dimensional plates in mandibular fractures. Natl J Maxillofac Surg 2020;11:263-9.

Access this article online	
<b>Website:</b> www.njms.in	<b>Quick Response Code</b> 
<b>DOI:</b> 10.4103/njms.NJMS_53_19	

of additional inter maxillary fixation, increased comfort, improved diet, minimal temporomandibular joint damage secondary to immobilization, and a possible earlier return to work also; in the compromised patients with potential airway problems or seizure disorders, there is an additional benefit of not requiring intermaxillary fixation.<sup>[3,4]</sup>

Rigid fixation of mandibular fracture is technique sensitive and demanding and requires more operative time and more thickness of plate associated with discomfort to patient. Since, Champy and Pape described the principle of osteosynthesis along with an 'ideal osteosynthesis line'<sup>[5-7]</sup>, monocortical fixation (semirigid fixation) utilizing miniplate is commonly practiced.<sup>[5-7]</sup>

Among the latest innovations, a major impetus to the field of maxillofacial trauma has been the introduction of locking plates/screws plating systems for the treatment of mandibular fractures. The screws, plate, and bone form a solid framework with higher stability than the traditional nonlocking plate screw system. It is also postulated that the locking system requires less precise adaptation of the plate to the underlying bone and decreases the chances of screw stripping, and its application via noncompression mechanism decreases the risk of necrosis of the fracture segments and produces less stress shielding.<sup>[8]</sup>

Another development in the field of oral and maxillofacial surgery is three-dimensional (3D) plates, consisting of two 4-hole plate interconnected by vertical cross struts. Unlike compression and reconstruction plates, their stability is not derived from the thickness of the plate. In combination with the screws monocortically fixed to outer cortex, the rectangular plate forms a cuboid, which possesses 3D.

In 1992, Farmand and Dupoirieux developed a 3D plate with quadrangular design formed by joining two miniplates with interconnecting crossbars. The stability of 3D plates unlike traditional plate does not depend on thickness, but depends on its structural design and formation. The stabilization of plates with monocortical screws forms a cuboid that gives to the system 3D stability. These plates can be inserted through intraoral techniques and have shown low complications rates. Because of smaller size, these are easy to handle and adjust.<sup>[9]</sup>

Considering the current concepts of locking plates and 3D plates, this prospective cohort study was carried out to evaluate the comparative efficacy of 2.00-mm locking plates and 3D plates in mandibular fracture and complications encountered during and after the procedures.

## MATERIALS AND METHODS

### Study design

A prospective cohort study between April 2012 and October 2013 was designed to enroll uncomplicated mandibular fracture patients in the department of oral and maxillofacial surgery. Patients above 18 years of age with symphysis, parasymphysis, and body fractures of the mandible were selected for the study. [Figures 1 and 4 shows the Preoperative Orthopantomogram of mandibular fracture]. Other patients who had any one of the following complications at the time of presentation were excluded from the study:

- Patients with pan facial fractures or comminuted fractures of the mandible
- Patients showing large displacement with fracture segments
- Patients with mental nerve injury due to trauma
- Medically compromised patients
- Patients with poor dental hygiene
- Patients with gross infection at the site of fracture
- Patients reporting more than 7 days after injury
- Patients with less mandibular vertical height between the root apex of teeth and lower border of the mandible.

Preoperative evaluation of the enrolled patients was done with clinical history including the time and date of accident, time of reporting, mechanism of injury, and history of bleeding from ear, nose, and oral cavity. The patient was also questioned about the history of unconsciousness, vomiting, and convulsions as well as the history of amnesia. This was followed by a detailed clinical examination. The oral cavity was cleaned of blood clots, fractured tooth edges, and other foreign bodies. A temporary stabilization was provided by ligature wire and barrel bandage when deemed necessary. The face and the oral cavity were examined for signs of soft-tissue injuries. All wounds were debrided, and lacerated wounds were sutured with 3-0 silk and 3-0 vicryl. Injection tetanus toxoid 0.5 ml intramuscular was administered, and the patients were started on antibiotics and analgesics. A well-informed written consent was taken before the surgical procedure.

### Selection of mini-plates

The choice of selection of either regular locking plates or 3D plates was taken independently of the enrollment of patients in the study. This cohort of patients who underwent the bone plate osteosynthesis were divided into two groups on the basis of type plate used:

- Group I: Treated using noncompression unicortical 2-mm locking miniplate
- Group II: Treated using noncompression unicortical 2-mm 3D miniplate.

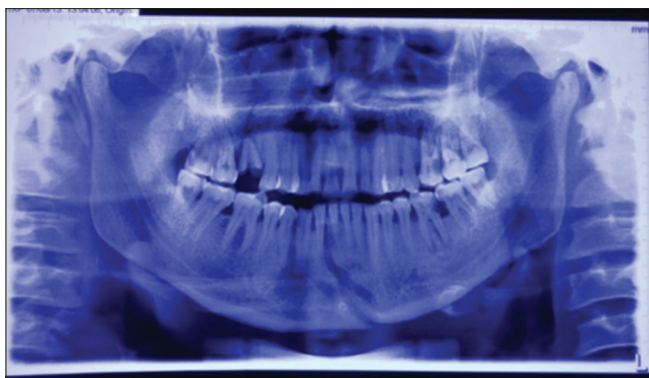


Figure 1: Preoperative orthopantomogram of mandibular fracture

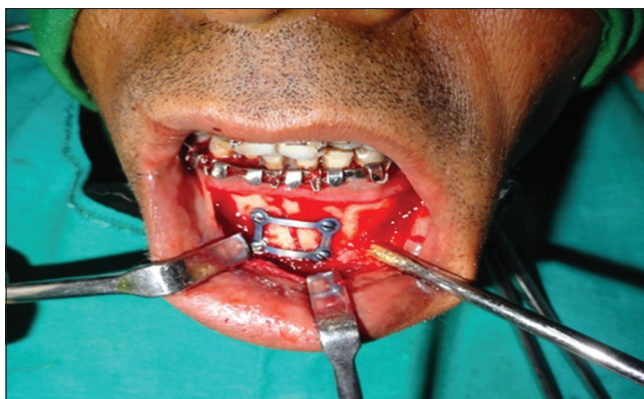

Figure 2: Intraoperative three-dimensional plate applied

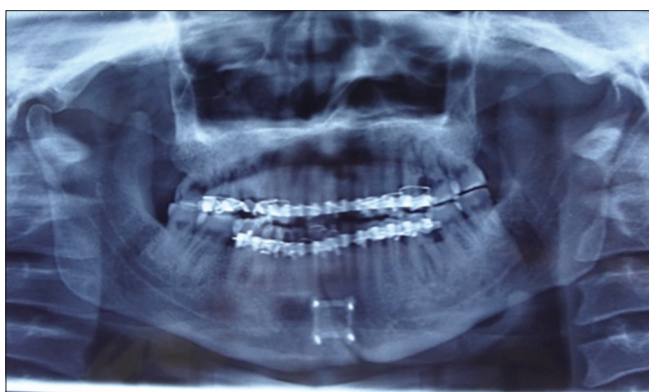


Figure 3: Postoperative orthopantomogram of mandibular fracture

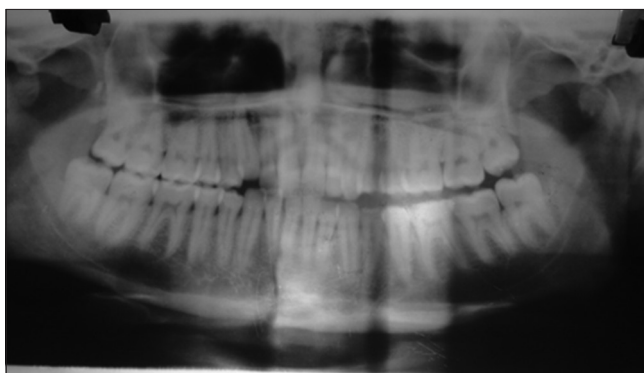


Figure 4: Preoperative orthopantomogram of mandibular fracture

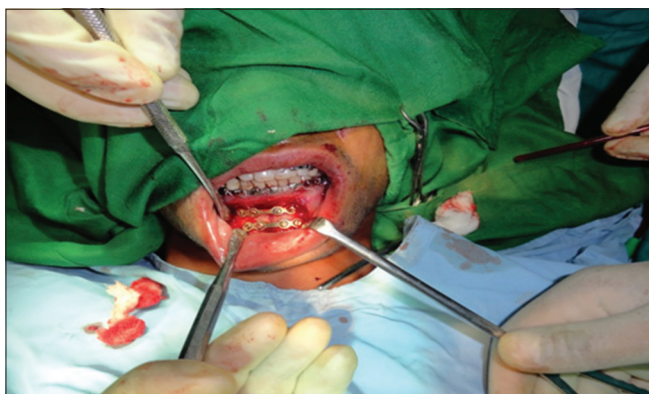

Figure 5: Intraoperative locking plate applied

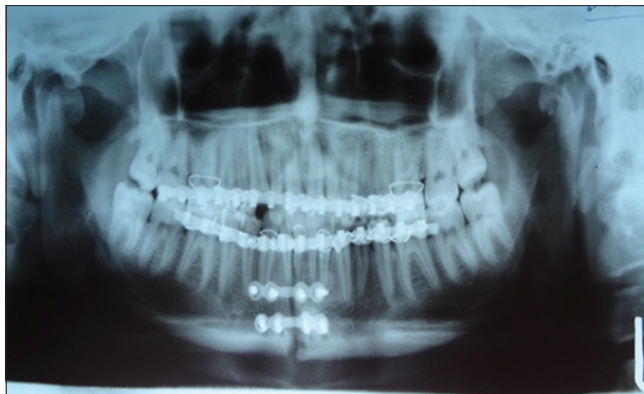


Figure 6: Postoperative orthopantomogram of mandibular fracture

### Follow-up of the study participants

All patients in both groups were followed up daily for postoperative complications when they were admitted to the hospital. Afterward, they were followed up weekly for outcome parameters such as postoperative sensory disturbance, postoperative infection, vertical displacement of mandible, feeling of plate after plating, and chewing efficiency after 1 week, up to 4 weeks.

### Materials used in the study

#### Bone plates

Noncorrosive heat-resistant titanium plates with an alloy of Ti (99.5%) and Fe (0.5%) with 0.08% carbon ensuring

good flexibility were used in this study. The elastic limit of flexibility lay between 70 and 80 DaN/mm and the rupture point between 95 and 110 DaN/mm. This is sufficient to withstand the bending and torsional forces of 60–100 DaN/mm, which develop in the mandible in function.

#### 2.0-mm locking plates

The thickness of the plate was 1 mm, length was 2.7 cm, screw hole diameter was 2 mm and there was 30° bevel with an added lock to accommodate for the screw and sinking of the head of the screw. [Figures 5 and 6] shows the intraoperative and postoperative application of 2mm Locking plate]



### 2.0-mm locking plate screw

Titanium locking, cross-pin, self-tapping screws were used. The length of the screws was 8 mm or 10 mm. The diameter of the screw head was 3 mm and that of screw was 2 mm.

### 2.0-mm three-dimensional plates

Fourhole 3D titanium miniplates were used in this study with 2mm screw hole diameter and 30° bevel to accommodate for the screw and sinking of the head of the screw. [Figures 2 and 3 shows the intraoperative and postoperative application of 2mm 3D plate].

### 2.0-mm three-dimensional screw

Titanium self-tapping screws were used to fix the plate. The screws had an average thread of 10/10. The distance between the turn of the thread is 1 mm. A finer thread would lead to microfractures in the drilled hole. The diameter of the screw head was 3 mm and that of screw was 2 mm, with countersinking of the head corresponding to the 30° beveled hole in the plate.

### Statistical analysis

The data were analyzed using IBM SPSS version 20.0 (Armonk, NY, IBM Corp.) software. Fisher's exact test was applied to check significant difference between the two groups. In addition, unpaired *t*-test was applied for operating time. The *P* value was taken as statistically significant when  $<0.05$ .

## RESULTS

Overall, 27 patients with uncomplicated mandibular fracture presented in the department of oral and maxillofacial surgery between April 2012 and October 2013 fulfilling inclusion and exclusion criteria of the study. Seven patients were not ready for surgery in our hospital, and they were referred to other

health center. The remaining twenty patients (ten patients in each group) were enrolled.

Majority of the patients (90%) were males in both groups. The age of all the patients was 27.68 years, with a standard deviation of 7.93 years. The age of the patients ranged in both groups between 18 and 50 years. In both groups, 50% of patients were aged 18–30 years. The etiological factors responsible for mandibular fractures were assessed. Road traffic accident was found to be the most common cause of mandibular fractures in each group, followed by assault. In 80% of cases, mandibular fracture site was parasymphysis [Table 1].

The mean operating time in minutes for locking plates was more 54.82 (standard deviation [SD] = 17.26) than the mean operating time for 3D plates, which was 43.20 (SD = 5.37),  $P < 0.0001$  [Table 2].

None of the patient required postoperative intermaxillary fixation in 3D plate group as compared to locking mini-plate group in which 60% of patient required postoperative intermaxillary fixation,  $P = 0.025$ . The 80% of cases operated by 3D plates did not require postoperative occlusal correction compared to 30% in another group,  $P = 0.01$ . Although there was no statistically significant difference, the postoperative infection and minor tooth damage were seen only in one and three cases of Group II of 3D plate, respectively.

Postoperative sensory disturbance was noted in one (10%) patient in Group I and four (40.0%) in Group II,  $P = 0.12$ . No vertical displacement of mandible was noted in both the groups. Postoperative feeling of plate after plating varied in the two groups. One (10.0%) patient in Group

**Table 1: General characteristics of the study participants in both groups**

Patients characteristics	Group I* (n=10), n (%)	Group II# (n=10), n (%)	Total (n=20), n (%)
Gender			
Male	9 (90)	9 (90)	18 (85)
Female	1 (10)	1 (10)	2 (10)
Age group			
18-30	5 (50)	5 (50)	10 (50)
31-40	3 (30)	4 (40)	7 (35)
41-50	2 (20)	1 (10)	3 (15)
Etiology			
Road traffic accidents	8 (80)	9 (90)	17 (85)
Assault	1 (10)	1 (10)	2 (10)
Fall	1 (10)	0	1 (5)
Mandibular fracture site			
Symphysis	1 (10)	2 (20)	3 (15)
Parasymphysis	8 (80)	8 (80)	16 (80)
Body	1 (10)	0	1 (5)

\*Group I: Treatment using noncompression unicortical 2-mm locking miniplate, #Group II: Treatment using noncompression unicortical 2-mm three-dimensional miniplate

I and 2 (20%) patients in Group II showed worse feeling,  $P = 0.53$ . Chewing efficiency after 1 week of plating was not statistically significant. However chewing efficiency varied in two groups, 3 patients (30.0%) in Group I and 1 patient (10%) in Group II showed difficulty in chewing after 1 week [Table 3].

## DISCUSSION

The strategic position of the mandible on the facial skeleton and its unique role in mastication, deglutition, phonation, and esthetics need immediate attention by clinicians whenever it is fractured. With increasing industrialization, mandibular fractures are more common in facial trauma. The fixation method of mandibular fractures has become an increasingly important decision for the maxillofacial surgeon. The key to successful management of these fractures is to understand the principles of accurate re-establishment of occlusion, fracture reduction, and stable internal fixation.<sup>[10]</sup>

**Table 2: Comparison of mean operating time between the two groups**

Study group	n	Mean	SD
Group I	10	54.82	17.26
Group II	10	43.20	5.37

$t=5.79, P<0.0001$

In the present study, a total of twenty patients were studied, ten from each group, i.e., ten patients of 2.0-mm locking plates and ten patients of 3D plate. In both the groups, majority of the patients were male, i.e., 9 (90.0%) in Group I and 9 (90.0%) in Group II. Similar male predominance was noted by Sadhwani and Anchlia<sup>[11]</sup> with 64.29% of males and 35.71% of females. In addition, this male dominance was also reported by Haug *et al.*<sup>[12]</sup> in their studies. This higher prevalence in males could be attributed to the fact that males are more involved in outdoor activities in this part of globe and also, the inherent aggressive behavior accounts for further higher incidence.

Road traffic accident (85%) was the common cause of mandibular fractures in each group, followed by assault. Similar etiological factor was noted by Sadhwani and Anchlia,<sup>[11]</sup> who found that road traffic accidents were responsible for the majority of cases (57.14%) of mandible fractures. In addition, this finding was in accordance with the study by Bormann *et al.*<sup>[13]</sup> The factors contributing to this variation could be bad roads, poor implementation of traffic rules, and not using safety measures in developing countries.

In this study, parasymphysis was the most common site of fracture (16 cases) followed by symphysis (three cases) and

**Table 3: Comparison of operative and postoperative outcomes between the two groups**

	Group I (n=10), n (%)	Group II (n=10), n (%)	Total (n=20), n (%)	Fisher's exact test P
Need for intermaxillary fixation				
Needed	4 (40)	0	3 (15)	0.025*
Not needed	6 (60)	10 (100)	17 (85)	
Postoperative occlusion				
No need for occlusal correction	3 (30)	8 (80)	11 (55)	0.014*
Minor occlusal correction	6 (60)	0	6 (30)	
Major occlusal correction	1 (10)	2 (20)	3 (15)	
Postoperative infection				
No infection	10 (100)	9 (90)	19 (95)	0.305 (NS)
Infection present	0	1 (10)	1 (5)	
Incidence tooth damage				
No damage	10 (100)	7 (70)	17 (85)	0.060 (NS)
Minor contact	0	3 (30)	3 (15)	
Postoperative sensory disturbance				
No disturbance	9 (90)	6 (60)	15 (75)	0.121 (NS)
Disturbance present	1 (10)	4 (40)	5 (25)	
Vertical displacement of mandible				
No displacement	10 (100)	10 (100)	20 (100)	1.00 (NS)
Displacement	0	0	0	
Feeling of plate after plating				
No feeling	9 (90)	8 (80)	17 (85)	0.531 (NS)
Bad feeling	1 (10)	2 (20)	3 (15)	
Chewing efficiency after 1 week				
No difficulty	7 (70)	9 (90)	16 (80)	0.264 (NS)
Difficulty present	3 (30)	1 (10)	4 (20)	

\*Statistically significant. NS: Statistically not significant

body of mandible (one case). Similar findings were noted by Sadhwani and Anchlial<sup>[11]</sup> The most common site of mandible fracture was parasymphysis (35%) and angle (35%), followed by body (20%) and symphysis (10%), which is contradictory to the findings of Haug *et al.*<sup>[12]</sup> who found body of the mandible to be the most common site (29.5%).

However, in particular reference to the symphysis/ parasymphysis region, 3D miniplate fixation was an easy-to-use alternative compared to the conventional miniplates as the surgical site was markedly reduced by the use of only a single plate for stabilization at both the superior and inferior borders. They concluded that the surgical trauma was also comparatively lesser. A similar conclusion was drawn in another study conducted by Balakrishnan *et al.* who analyzed the efficacy of using 3D titanium miniplates for the management of mandibular fractures. They concluded that 3D titanium miniplates were a viable option for the management of mandibular fractures with the advantages of placement through an intraoral approach, minimizing surgical period and trauma with the added advantage of simple techniques for adaptation to the bone.<sup>[14]</sup>

The mean operating time in minutes for locking plates was 54.82 (SD = 17.26). Whereas the mean operating time in minutes for 3D plates was 43.20 (SD = 5.37). Similar findings were noted by Feledy *et al.*<sup>[15]</sup> and Zix *et al.*<sup>[16]</sup> on 3D plate. Mittal *et al.*<sup>[17]</sup> quoted the reason for reduced time to fix 3D plates as less surgical exposure, minimal soft-tissue retraction, and no need to bend the plates. Khalifa *et al.*<sup>[18]</sup> compared miniplate and 3D plates and opined that the reduced time for fixing 3D plate was due to nonbending of plates when compared with miniplates which require near-surface adaptation. In addition, simplified adaptation to bone as well as simultaneous stabilization at both the superior and inferior borders makes the 3D locking plate a time-saving alternative to the conventional miniplates.

With the use of open reduction and internal fixation, the reported incidence of infection ranged from 3% to 32%.<sup>[19]</sup> Postoperative infection was not seen in locking plate group, while one patient (10%) in 3D plate group developed Postoperative infection ( $P > 0.05$ ) which was managed by wound debridement and antibiotic coverage for 5 days (Tablet Cefixime 200 mg bid and Tablet Metronidazole 400 mg tid). Ellis and Graham<sup>[20]</sup> found in their study that 9% of patients developed postsurgical infections. Guimond *et al.*<sup>[21]</sup> reported an infection rate of 5.4% with the use of 3D plate, Feledy *et al.*<sup>[15]</sup> reported 9% infection rate, and Zix *et al.*<sup>[16]</sup> reported 0% infection rate in their study. As it has been claimed that mobility of fractured segments is a causative factor in

postoperative infections, the improvement of plate stability might be a way to minimize this problem.

In the present study, none of the cases showed injury to the tooth; only three patients had minor contact in 3D miniplate. Malhotra *et al.*<sup>[22]</sup> reported two cases of injury to the roots while treating the fractures near mental foramen using 3D miniplate fixation.

Postoperative feeling of plate after plating varied in two groups: one (10.0%) patient in Group I and 20.0% of cases in 3D plates. This could be explained by the presence of excessive implant material due to the extra vertical bars incorporated for countering the torque forces. There was no statistically significant association between postoperative feeling of plate after plating in both groups ( $P = 0.531$ ).

Chewing efficiency after 1 week of plating varied in both groups: three (30.0%) patients in Group I and one (10%) in Group II showed difficulty in chewing after 1 week.

Hence, in the locking system, the screw and plate becomes a single rigid functional unit that no longer relies on the bone-to-plate interface for stabilization. The locking system combines two principles: first, the locking system prevents stripping of screws and prevents movement and loosening of screws; second, the fixator principle simplifies bending of plates and decreases torsion or opening at the fracture site. The absence of pressure underneath the plate prevents interference with vascular supply of bone and allows the periosteum to grow which promotes fracture healing.<sup>[23]</sup>

On the other hand, principles of 3D locking design rely on the principles of 3D miniplate system and locking system. First, when the mandible is in function, the primary forces of concern are bending, vertical displacement, and shearing. In 3D plate, the vertical bars connecting the two horizontal bars resist bending forces. The box configuration of the plate distributes the forces over a surface area and not along a single line; this provides more stability in three dimensions; against torsion forces, vertical displacement, and bending and shearing forces. Thus, the stability is gained in three dimensions, hence the name 3D plate.<sup>[24]</sup>

The results suggest that fixation of mandibular anterior fracture with 3D locking plates provides 3D stability and carries low infection rates and shorter operative time because of simplified adaptation to the bone and simultaneous stabilization at both superior and inferior borders. As far as the cost–benefit ratio is considered, the single 3D plate costs

less than Champy's plate as their reduction in the number of screws is 50%.<sup>[6]</sup> The 3D locking miniplate system may be considered inconvenient to use in cases of oblique fractures and in fractures involving the mental nerve area. The other probable limitations of these plates could be the excessive implant material due to extra vertical bars incorporated for countering the torque forces, which is in agreement with Parmar *et al.*<sup>[25]</sup>

## CONCLUSIONS

We concluded that the use of noncompression unicortical 2-mm 3D mini-plate is a better approach for uncomplicated mandibular fracture with respect to operating time, no need for inter-maxillary fixation, and no need of postoperative occlusal correction, while sharing similar outcome profile in other parameters such as infection rate, incidence of tooth damage, vertical displacement, and chewing difficulty as that of noncompression unicortical 2-mm locking miniplate.

## Acknowledgment

The authors acknowledge the contribution of Dr. Momin Kashif, Associate Professor in Community Medicine, Prathima Institutes of Medical Sciences, Karimnagar, Telangana, India, for helping in data analysis and editing of the original manuscript.

## Financial support and sponsorship

Nil.

## Conflicts of interest

There are no conflicts of interest.

## REFERENCES

- Hsieh TY, Funamura JL, Dedhia R, Durbin-Johnson B, Dunbar C, Tollefson TT. Risk factors associated with complications after treatment of mandible fractures. *JAMA Facial Plast Surg* 2019;21:213-20.
- Aggarwal S, Singh M, Modi P, Walia E, Aggarwal R. Comparison of 3D plate and locking plate in treatment of mandibular fracture – A clinical study. *Oral Maxillofac Surg* 2017;21:383-90.
- Fonseca RJ. *Oral and Maxillofacial Surgery*. Vol. 3. St. Louis: WB Saunders Co; 2000. p. 85.
- Barak M, Bahouth H, Leiser Y, ElNaaj IA. Airway management of the patient with maxillofacial trauma: Review of the literature and suggested clinical approach. *Biomed Res Int* 2015;9.
- Gilardino MS, Chen E, Bartlett SP. Choice of internal rigid fixation materials in the treatment of facial fractures. *Craniomaxillofac Trauma Reconstr* 2009;2:49-60.
- Champy M, Pape HD. *The strasbourg miniplate osteosynthesis*. Chicago, USA: Quintessence; 1986. p. 19-43.
- Barde DH, Mudhol A, Ali FM, Madan RS, Kar S, Ustaad F. Efficacy of 3-dimensional plates over Champy's miniplates in mandibular anterior fractures. *J Int Oral Health* 2014;6:20-6.
- Giri KY, Sahu P, Rastogi S, Dandriyal R, Mall S, Singh AP, *et al.* Bite force evaluation of conventional plating system versus locking plating system for mandibular fracture. *J Maxillofac Oral Surg* 2015;14:972-8.
- Farmand M, Dupoirieux L. The value of 3-dimensional plates in maxillofacial surgery. *Rev Stomatol Chir Maxillofac* 1992;93:353-7.
- Kelley P, Crawford M, Higuera S, Hollier LH. Two hundred ninety-four consecutive facial fractures in an urban trauma center: Lessons learned. *Plast Reconstr Surg* 2005;116:42e-9.
- Sadhvani BS, Anclia S. Conventional 2.0 mm miniplates versus 3-D plates in mandibular fractures. *Ann Maxillofac Surg* 2013;3:154-9.
- Haug RH, Street CC, Goltz M. Does plate adaptation affect stability? A biomechanical comparison of locking and nonlocking plates. *J Oral Maxillofac Surg* 2002;60:1319-26.
- Bormann KH, Wild S, Gellrich NC, Kokemüller H, Stühmer C, Schmelzeisen R, *et al.* Five-year retrospective study of mandibular fractures in Freiburg, Germany: Incidence, etiology, treatment, and complications. *J Oral Maxillofac Surg* 2009;67:1251-5.
- Balakrishnan R, Ebenezer V, Dakir A. Three dimensional titanium mini plates in management of mandibular fractures. *Biomed Pharmacol J* 2014;7:241-6.
- Feledy J, Cateson EJ, Steger S, Stal S, Hollier L. Treatment of mandibular angle fractures with a matrix miniplate: A preliminary report. *Plast Reconstr Surg* 2004;114:1711-6.
- Zix J, Lieger O, Iizuka T. Use of straight and curved 3-dimensional titanium miniplates for fracture fixation at the mandibular angle. *J Oral Maxillofac Surg* 2007;65:1758-63.
- Mittal G, Dubbudu RR, Cariappa KM. Three dimensional titanium mini plates in oral and maxillofacial surgery: A prospective clinical trial. *J Maxillofac Oral Surg* 2012;11:152-9.
- Khalifa EM, Hawary HE, Hussein MM. Titanium three dimensional miniplate versus conventional titanium miniplate in fixation of anterior mandibular fractures. *LSJ* 2012;9:1006-10.
- Engroff SL, Blanchaert RH Jr., von Fraunhofer JA. Mandibulotomy fixation: A laboratory analysis. *J Oral Maxillofac Surg* 2003;61:1297-301.
- Ellis E 3<sup>rd</sup>, Graham J. Use of a 2.0-mm locking plate/screw system for mandibular fracture surgery. *J Oral Maxillofac Surg* 2002;60:642.
- Guimond C, Johnson JV, Marchena JM. Fixation of mandibular angle fractures with a 2.0-mm 3-dimensional curved angle strut plate. *J Oral Maxillofac Surg* 2005;63:209-14.
- Malhotra K, Sharma A, Giraddi G. Versatility of titanium 3D plate in comparison with conventional miniplate fixation for the management of mandibular fracture. *JMOS* 2012;11:284-90.
- Bouloux GF, Chen S, Threadgill JM. Small and large titanium plates are equally effective for treating mandible fractures. *JOMS* 2012;70:1613-21.
- Kumar N, Malhan S, Mahajan S, Asi KS. Titanium miniplate osteosynthesis of mandibular fractures. *IJDS* 2012;1:21-4.
- Parmar BS, Menat S, Raghani M, Kapadia T. Three dimensional miniplate rigid fixation in fracture mandible. *J Maxillofac Oral Surg* 2007;6:14-6.