



BRAZILIAN JOURNAL
OF MEDICAL AND BIOLOGICAL RESEARCH

www.bjournal.com.br

ISSN 1414-431X
Volume 45 (10) 875-994 October 2012

BIOMEDICAL SCIENCES

Braz J Med Biol Res, October 2012, Volume 45(10) 968-976

doi: 10.1590/S0100-879X2012007500102

Psychological stress alters the ultrastructure and increases IL-1 β and TNF- α in mandibular condylar cartilage

Xin Lv, Qiang Li, Shun Wu, Jing Sun, Min Zhang and Yong-Jin Chen

The Brazilian Journal of Medical and Biological Research is partially financed by



Ministério da Ciência e Tecnologia



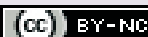
Ministério da Educação



Institutional Sponsors



Explore High - Performance MS Orbitrap Technology In Proteomics & Metabolomics



All the contents of this journal, except where otherwise noted, is licensed under a [Creative Commons Attribution License](http://creativecommons.org/licenses/by-nc/4.0/)

Psychological stress alters the ultrastructure and increases IL-1 β and TNF- α in mandibular condylar cartilage

Xin Lv*, Qiang Li*, Shun Wu, Jing Sun, Min Zhang and Yong-Jin Chen

Department of General Dentistry and Emergency, School of Stomatology,
Fourth Military Medical University, Xi'an, Shaanxi, China

Abstract

Psychological factors can be correlated with temporomandibular disorders (TMDs), but the mechanisms are unknown. In the present study, we examined the microstructural changes and expression of proinflammatory cytokines in mandibular condylar cartilage of the temporomandibular joint (TMJ) in a psychological stress animal model. Male Sprague-Dawley rats (8 weeks old, 210 \pm 10 g) were randomly divided into 3 groups: psychological stress (PS, N = 48), foot shock (FS, N = 24), and control (N = 48). After inducing psychological stress using a communication box with the FS rats for 1, 3, or 5 weeks, PS rats were sacrificed and compared to their matched control littermates, which received no stress and were killed at the same times as the PS rats. Body and adrenal gland weight were measured and corticosterone and adrenocorticotropic hormone levels were determined by radioimmunoassay. After hematoxylin-eosin staining for histological observation, the ultrastructure of the TMJ was examined by scanning electron microscopy. Transcription and protein levels of interleukin-1 β (IL-1 β) and tumor necrosis factor- α (TNF- α) were evaluated by ELISA and semi-quantitative RT-PCR. The PS group showed a significantly higher adrenal gland weight after 3 weeks of stress and higher hormone levels at weeks 1, 3, and 5. Histopathological changes and thinning cartilage were apparent at weeks 3 and 5. In the PS group, TNF- α increased at 1, 3, and 5 weeks and IL-1 β increased significantly after 1 and 3 weeks of stress, and then decreased to normal levels by 5 weeks. Psychological stress increased plasma hormone levels and RT-PCR indicated increased IL-1 β and TNF- α expression in the TMJ in a time-dependent manner. These results suggest that cytokine up-regulation was accompanied by stress-induced cartilage degeneration in the mandibular condyle. The proinflammatory cytokines play a potential role in initiating the cartilage destruction that eventually leads to the TMDs.

Key words: Psychological stress; Temporomandibular joint; IL-1 β ; TNF- α

Introduction

Temporomandibular disorder (TMD) is a common frequent condition that includes a number of clinical problems involving the masticatory musculature, the temporomandibular joint (TMJ), associated structures or both (1). Despite an increase in studies related to TMD over the last century, the mechanisms of TMD pathogenesis remain controversial. It is commonly believed that both occlusal abnormalities (2) and psychological stress (3) are strongly related to the occurrence of TMD. In recent years, with the transformation of the medical mode from the simple biomedical mode to the biological-psychological-social medical mode, more researchers have paid attention to the

role of psychological factors in the etiology of TMD. Studies conducted by List et al. (4) have shown that psychological factors such as high stress levels, somatic complaints, and emotional problems play a more important role than dental factors in TMD. Similarly, using data from questionnaires, clinical histories and dental panoramic tomography, Kafas and Leeson (5) have demonstrated that TMD are closely related to the mood of the patients.

Previous studies have shown that proinflammatory cytokines such as interleukin-1 β (IL-1 β) and tumor necrosis factor- α (TNF- α) play important roles in mediating the inflammatory and immune responses in the TMJ (6).

Correspondence: Min Zhang and/or Yong-Jin Chen, Department of General Dentistry and Emergency, School of Stomatology, Fourth Military Medical University, Xi'an, Shanxi, 710032, China. Fax: +86-29-8477-6488. E-mail: zhangmin@fmmu.edu.cn and/or cyj1229@fmmu.edu.cn

*These authors contributed equally to this study.

Received November 16, 2011. Accepted May 28, 2012. Available online June 22, 2012. Published September 3, 2012.

Inflammatory stimulus-induced up-regulations of IL-1 β and TNF- α result in the production, release, and/or activation of matrix-degrading enzymes and lead to the production of inflammatory mediators such as prostaglandin and leukotriene (7-9). Increased levels of IL-1 β and TNF- α detected in the synovial fluid in patients with TMD also suggest the involvement of these cytokines in the pathogenesis of synovitis and in the degeneration of the cartilaginous tissue and bone of the temporomandibular joint (10,11).

Fibrocartilage, an important component of the TMJ, overlies the mandibular condyle. The functions of the TMJ depend on a normal structure of the mandibular condyle and condylar remodeling and cartilage destruction are characteristics of TMD, in which the TMJ exhibits progressive degradation characterized by marginal proliferation, loss of proteoglycan and fibrillation in the cartilage (12). Increased cytokines have been reported in TMD; however, whether the expression of these cytokines is associated with alterations of the ultrastructure of the mandibular condylar cartilage in conditions of psychological stress is not well understood. The objective of the present study is to identify the relationship between psychological stress-induced alterations in the ultrastructure of the TMJ and the expression of IL-1 β and TNF- α in the mandibular condyle of Sprague-Dawley rats. We also focused on the question of whether psychological stress is related to inflammatory progress in the mandibular condyle and on the role of psychological factors in the pathogenesis of TMD.

Material and Methods

Animals

Male Sprague-Dawley rats (8 weeks old, 210 \pm 10 g) were obtained from the animal center of the Fourth Military Medical University (Xi'an, China). All experimental and animal care procedures were approved by the University Ethics Committee and performed according to institutional guidelines. All rats were acclimated to laboratory conditions one week before the experiment with food and water available *ad libitum* and then randomly assigned to 3 groups: psychological stress (PS, N = 48), control (N = 48) and foot shock (FS, N = 24). PS animals and control littermates, which did not receive any stress, were further divided into 3 subgroups (N = 16 each) for 3 observation periods (1, 3, and 5 weeks). FS rats received foot shocks and thus merely served as a source of psychological stress for PS rats but were not sampled for experimental observation. Therefore, the number of rats in the FS group was 24. Eight rats were randomly selected from this group each day to receive a shock in order to minimize anticipation and to prevent adaptation to the stress.

Communication box for the psychological stress model

Psychological stress was induced using a communication box as previously described, with modifications

(13,14). The box (64 x 64 x 16 cm) was made of 5-mm thick transparent plastic boards and had a floor grid composed of stainless steel wires placed 3 mm apart (Figure 1). It consisted of 16 small compartments (16 x 16 cm) separated by transparent plastic walls. PS rats were placed in 8 compartments separated by plastic plates on the grid floors to prevent receiving electric shocks. FS rats were placed in the remaining compartments with the electric grid floor. They were running and vocalizing when receiving electrical shock directly from a homemade electric foot-shock generator (48 V, 0.5 Hz, 2 mA) for 30 min every morning (9:00-9:30 am), whereas the neighboring PS rats with no physical contact with FS animals received visual, auditory and olfactory sensations from FS rats in response to foot shocks. After the psychological stress experiment, control rats were placed in the communication box for 30 min during which no foot shocks or stimuli were administered. All rats had free access to regular solid food and water.

At 1, 3, and 5 weeks, PS rats and control rats were sacrificed with intraperitoneal injections of an overdose of pentobarbital sodium (50 mg/kg body weight) after the behavioral test at each experimental time. Body and adrenal gland weight were then recorded. Blood samples were collected for hormone analysis. Eight rats were then randomly selected from each group and the right condyles were used for histological observation with hematoxylin-eosin (H&E) staining. The right condyles of other animals (N = 8) were prepared for ultrastructural analysis by scanning electron microscopy. After adherent connective tissue was cleaned, the left mandibular condyles (N = 8) were frozen in liquid

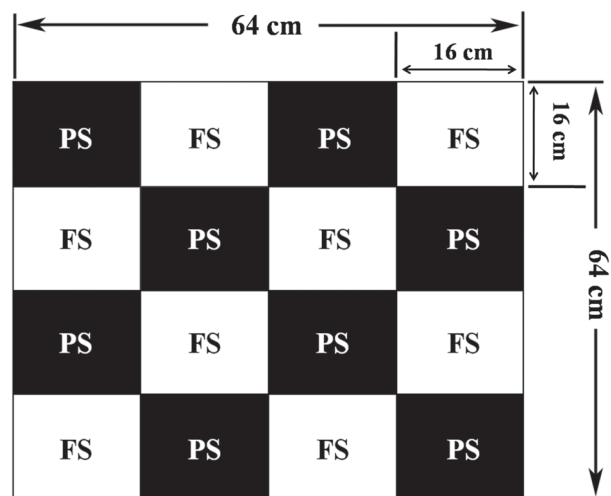


Figure 1. Schematic diagram of the communication box. It consisted of 16 small compartments (16 x 16 cm) with 1 rat in each compartment. The FS rats received foot shock for 30 min at each time, while the neighboring PS rats had no physical contact with FS animals and received sensory sensations from FS rats in response to foot shocks. FS = foot-shock group; PS = psychological stress group.

nitrogen and stored to measure the expression of IL-1 β and TNF- α at the transcription and protein level by RT-PCR and ELISA, respectively.

Measurement of plasma corticosterone and adrenocorticotropic hormone (ACTH) by radioimmunoassay

Blood samples were collected into ice-cold tubes containing EDTA, centrifuged at 700 *g* for 20 min, and then stored at -20°C until hormone assays were carried out. ACTH and corticosterone levels were measured by radioimmunoassay (MP Biomedicals, USA) as described in Ref. 15. The intra-assay coefficients of variation for ACTH and corticosterone were 7.6 and 8.6%, respectively.

Histological observation

For histological observation, the TMJs were fixed in 10% buffered paraformaldehyde and decalcified with 10% EDTA at 4°C for 4 weeks. They were then embedded in paraffin, and serial 5- μ m sections were cut on the sagittal plane and stained with H&E for histological examination (Leica DM 2500, Germany). Condylar cartilage thickness was measured from the upper surface of the fibrous layer to the lower surface of the hypertrophic layer.

Ultrastructural changes in the mandibular condyle

The right TMJ samples were rapidly excised and washed in phosphate-buffered saline. Isolated tissue was fixed in Karnovsky's fixative, rinsed in 0.1 M phosphate buffer, postfixed in 1% phosphate-buffered osmium tetroxide, dehydrated and dried with carbon dioxide. Subsequently, the samples were coated with gold-palladium and examined with a Hitachi S-3400N scanning electron microscope.

RT-PCR assay for expression of IL-1 β and TNF- α

The left condylar cartilages were homogenized with a Mikro-Dismembrator (Fisher-Scientific, USA). RNA was isolated with the Trizol[®] reagent (Invitrogen Life Technologies, USA) and reverse-transcribed using the PrimeScript[™] 1st Strand cDNA Synthesis Kit (TaKaRa Inc., Japan) according to manufacturer instructions. PCR was carried out in a total volume of 25 μ L containing DNA template, TaKaRa Ex Taq[™] Premix (TaKaRa Ex Taq[™], Ex Taq[™] Buffer, 4 mM MgCl₂ and dNTPs) and primers (20 pmol per reaction). The gene sequences were searched from GeneBank with Pubmed. Then, Primer Premier 5.0 (Premier Inc., Canada) was used to design the primer sequences, and the highest rated primer was selected as the candidate primer. The final primer sequences were decided according to the assessment result by Oligo 6.0 and tested in preliminary experiments. Primers used for IL-1 β mRNA were: forward: 5'-CCAGGATGAGGACCCAAGCA-3' and reverse: 5'-TCCCGACCATTGCTGTTTCC-3' (519 bp, GeneBank NM_031512.2). Primers used for TNF- α were: forward: 5'-CCACGCTCTTCTGTCTACTG-3' and reverse:

5'-GCTACGGGCTTGCTCACTCGA-3' (145 bp, GeneBank NM_012675.3). Primers used for β -actin mRNA were: forward: 5'-GCGTCCACCCGCGAGTACAAC-3' and reverse: 5'-CGACGACGAGCGCAGCGATA-3' (100 bp, GeneBank NM_031144.2). The amplification conditions consisted of 94°C for 5 min, followed by 30 cycles of 94°C for 60 s, 56°C for 60 s and 72°C for 60 s. This sequence was terminated with a final elongation at 72°C for 10 min. PCR products were separated and visualized by 1% agarose gel electrophoresis. The integrated absorbances of the resulting bands were collected and analyzed using the software package Quantity One[®] (Bio-Rad Laboratories GmbH, Germany). Briefly, the volume contour tool was used to quantify bands. Values of the bands were normalized to their corresponding β -actin values and reported as fold change.

ELISA for the expression of IL-1 β and TNF- α

Condylar cartilages were homogenized and treated with RPMI lysis buffer with proteinase inhibitor at 4°C for 10 min. The lysates were centrifuged at 11,000 *g* for 10 min. IL-1 β and TNF- α protein were quantified with ELISA kits (Endogen Inc., USA) following manufacturer instructions. Total protein assay was performed using the bicinchoninic acid assay method (Pierce, USA). Cytokine concentrations were reported per 100 μ g total protein. These experiments were repeated three times.

Statistical analysis

Statistical analyses were performed using SPSS 13.0 for Windows (SPSS Inc., USA). All data acquisition and analyses were performed blindly. Data are reported as means \pm SD. Statistical comparisons between the PS and control groups at different times were performed by one-way ANOVA. When a significant effect was found, *post hoc* comparisons between subgroups were made with the Bonferroni modification of the Student *t*-test. The chi-square test was used to compare the percentage of histologically changed TMJs in the PS group at each time. Resulting P values of less than 0.05 were considered to be significant.

Results

Comparisons of body and adrenal gland weight between the PS and control groups

Both the PS and control groups showed gradually increased body weight over time during the experiment (Table 1). However, at each time, the PS group had a significantly lower body weight than the control group ($P < 0.05$). Adrenal gland weight was significantly higher in the PS group than that in the control group only at 3 weeks ($P < 0.05$), with no differences detected at other times (Table 1).

PS groups had significant higher levels of plasma corticosterone and ACTH

The concentration of plasma corticosterone was sig-

nificantly higher in the PS group than that in the control group ($P < 0.05$) after 1, 3, and 5 weeks of stress, with the maximum level occurring at week 3 (Figure 2A). The PS group also had a significantly higher level of plasma ACTH at each time studied ($P < 0.05$; Figure 2B). PS rats subjected to 3 or 5 weeks of stress had a significantly higher level of plasma ACTH than rats subjected to one week of stress ($P < 0.05$). These results suggest that psychological stress significantly increased the hormonal response in a time-dependent manner.

Histological changes of TMJs

H&E specimens revealed a smooth cartilage surface and regular chondrocyte alignment in control TMJs. Obvious changes with a rough or even slack superficial fibrous layer in the condylar cartilage were found in the experimental groups (Figure 3B-D). These changes became more prominent at weeks 3 and 5 with a cracked superficial fibrous layer (Figure 3C and D) and decreased cartilage thickness ($P < 0.05$; Figure 3F). Additionally, the histological changes of the TMJs were counted in each PS group, i.e., in 2 of 8 rats in the 1-week group, 6 of 8 rats in the 3-week group, and 6 of 8 rats in the 5-week group. TMJ changes increased when rats were subjected to long-term stress (Figure 3E; $P < 0.05$). The fact that histopathological changes occurred in the TMJ after psychological stress was confirmed.

Psychological stress-induced ultrastructural changes in the mandibular condyle

Lower and higher magnification views of the condylar surface obtained by scanning electron microscopy are shown in Figure 4.

Notably, the surface of the mandibular condyle was smooth and entirely covered with a thin and intact gel-like layer (Figure 4A and E). After 1 week of psychological stress, the PS group had a less smooth condyle surface with a few collagen fibrils in a random arrangement detected in some regions (Figure 4B and F). At week 3, irregular gaps between the fibrils were detected on the condylar surface. The collagen fibrils in the deep layer were exposed and the fibers around these gaps were in a disordered arrangement (Figure 4C and G). At week 5, the collagen fibrils had partially formed bundles. However, the number and depth of the gaps that exposed the deep layer decreased and signs of healing were noted to some extent around these gaps (Figure 4D and H).

Psychological stress-induced expression of IL-1 β and TNF- α

In order to explore the possible mechanisms underlying psychological stress-induced pathological changes, we investigated the expression of IL-1 β and TNF- α in mandibular condylar cartilage (Figure 5) in response to stress over time. RT-PCR showed that IL-1 β mRNA levels

Table 1. Body and adrenal gland weights of rats in the psychological stress (PS) and control groups.

Time	Body weight (g)		Adrenal gland weight (mg)	
	Control group	PS group	Control group	PS group
1 week	227.01 \pm 7.60	217.01 \pm 6.90*	46.89 \pm 2.47	45.76 \pm 3.64
3 weeks	300.64 \pm 8.61	261.23 \pm 11.44*	47.72 \pm 1.92	50.31 \pm 2.46*
5 weeks	348.35 \pm 11.61	317.30 \pm 10.39*	49.50 \pm 2.64	51.18 \pm 2.79

Data are reported as means \pm SD for N = 8/group. * $P < 0.05$ vs control (Student *t*-test).

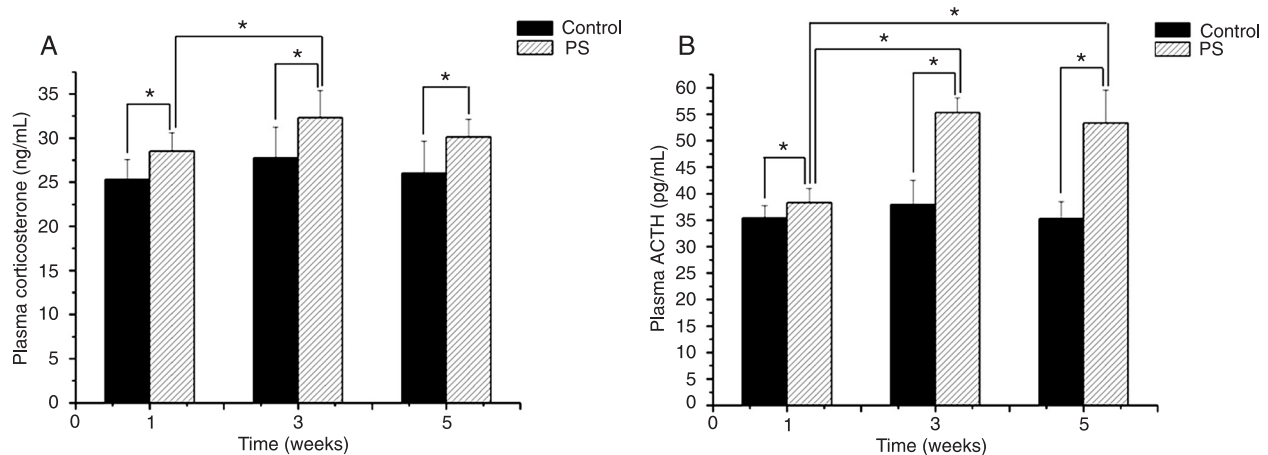


Figure 2. Plasma corticosterone and ACTH in the psychological stress (PS) and control groups at different times of stress. * $P < 0.05$ (Student *t*-test with the Bonferroni modification).

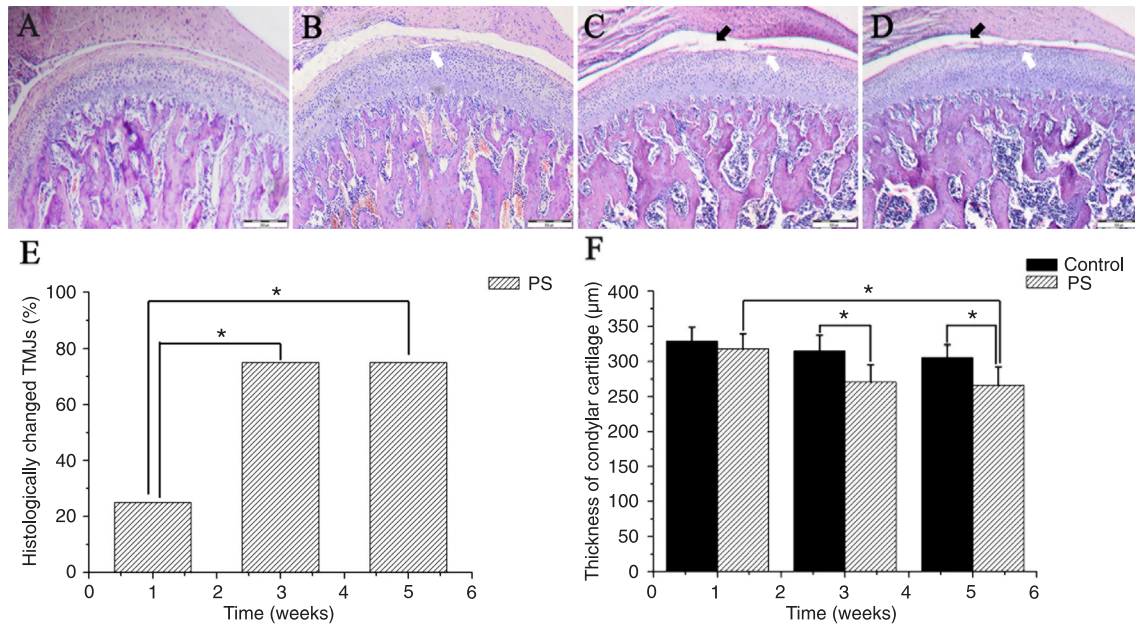


Figure 3. Representative H&E staining of condylar cartilages in control rats (A), 1-week PS rats (B), 3-week PS rats (C), and 5-week PS rats (D). Percentage of histologically changed TMJs in the PS group at each time (E). Condylar cartilage thickness (F). White arrows indicate a slack superficial surface and black arrows indicate a cracked surface. PS = psychological stress; TMJs = temporomandibular joints. Scale bar: 500 µm. * $P < 0.05$ (chi-square test for comparing the percentage of histologically changed TMJs in the PS group at each time; Student *t*-test with the Bonferroni modification for comparing condylar cartilage thickness).

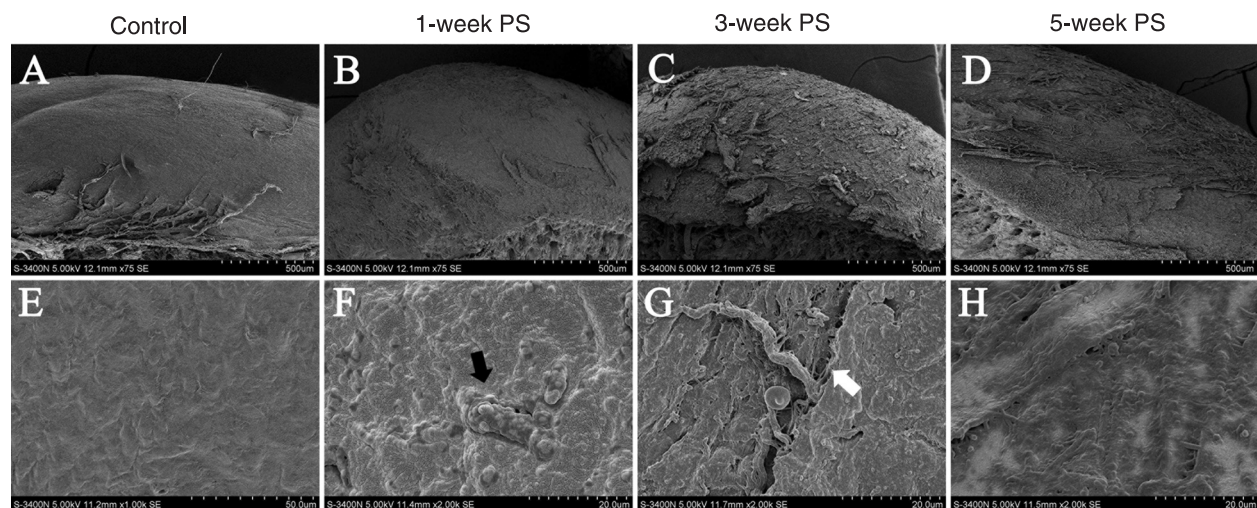


Figure 4. Ultrastructural changes of the mandibular condylar surface in the control (A, E) and psychological stress (PS) rats (B, F: 1-week stress; C, G: 3-week stress; D, H: 5-week stress) examined by scanning electron microscopy. The black arrow indicates the exposed collagen fibrils in the deep layer. The white arrow indicates the gap and exposed fibrils. Scale bars: 500 µm (A, B, C, D); 50 µm (E); 20 µm (F, G, H).

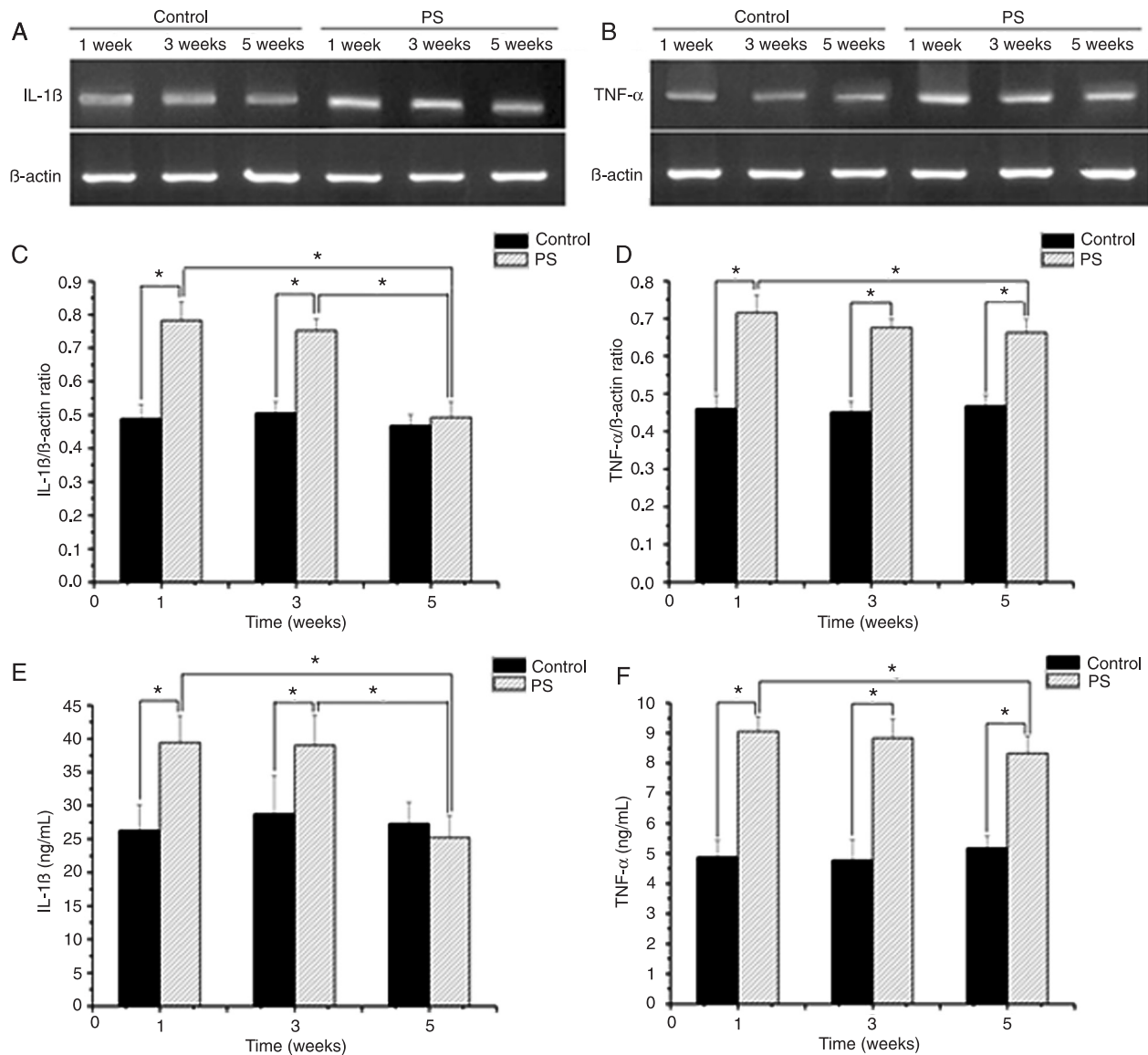


Figure 5. RT-PCR and ELISA quantification of IL-1 β and TNF- α expression. *A, B*, Representative gels of IL-1 β and TNF- α expression. *C, D*, RT-PCR analysis of IL-1 β and TNF- α expression in mandibular condyles of control and PS rats at different times. Expression levels are presented as band intensities, normalized by β -actin expression. *E, F*, ELISA analysis of IL-1 β and TNF- α protein expression in mandibular condyles under different treatment conditions. PS = psychological stress. * $P < 0.05$ (Student *t*-test with the Bonferroni modification).

increased in PS rats at weeks 1 and 3 ($P < 0.05$) and then gradually decreased to normal levels by week 5 ($P > 0.05$; Figure 5A and C). The protein level of IL-1 changed with a pattern similar to that of transcription (Figure 5E). The transcription of TNF- α in PS rats was significantly elevated compared to controls at all times tested ($P < 0.05$; Figure 5B and D) and its protein level was correlated with its mRNA alteration in response to psychological stress (Figure 5F). These results indicate that psychological stress increased the expression of IL-1 β and TNF- α in mandibular condyles

and these alterations occurred in a time-dependent manner. Moreover, the changes in the expression of IL-1 β and TNF- α were correlated with the psychological stress-induced ultrastructural changes in mandibular condyles, indicating the involvement of proinflammatory cytokines in structural changes that might contribute to functional abnormality.

Discussion

Since the discovery that emotional factors are involved

in TMD, many studies have shown that psychological stress plays a prominent role in its etiology. Furthermore, recent studies have shown that emotional factors also strongly influence the progression of TMD and the efficacy of therapeutic measures (5,16). Emotional factors are so important for TMD that some researchers consider TMD to be a purely psychological disease (17). In the present study, we employed a widely used communication box paradigm to experimentally induce anxiety in rats and to investigate the effects of psychological stress on factors, including cytokine response and ultrastructural alterations in the condyle, that are believed to contribute to the development of TMD. Our results showed that psychological stress induced high levels of corticosterone and ACTH in plasma and increases in proinflammatory cytokines IL-1 β and TNF- α in a time-dependent manner. Moreover, these alterations correlated with the extent of the histopathological changes and ultrastructural injury in the condyle, suggesting an involvement of a proinflammatory cytokine-mediated response in the development of tissue damage and subsequent functional abnormality in TMD.

Psychological stress is a powerful modulator of hormonal, behavioral, and immunological functions (18,19). Stress influences body weight possibly by regulating hypothalamic control of food intake with a consequent change in metabolism. In the present study, we detected a prominent stress-induced loss of body weight during the experimental period, which was not accompanied by significant changes in food or water intake. Stress also induces neuroendocrine alterations via stimulation of the hypothalamus-pituitary-adrenal (HPA) axis. As a part of this axis, the adrenal gland is highly sensitive to stress and chronic stress can increase its weight. In the present study, the rats that experienced psychological stress had a gradual increase in the weight of the adrenal gland in a stress time-dependent manner. Moreover, levels of plasma corticosterone and ACTH, which normally reflect activity in the HPA axis in response to stress and are frequently used as indices of stress levels (20-22), were significantly increased in PS rats. Taken together, these findings indicate that our communication box paradigm successfully induced psychological stress in the PS group.

The TMJ is a paired diarthrodial joint that contributes to the articulation of the lower jaw and the skull. Fibrocartilage, an important component of the TMJ, overlies the mandibular condyle and directly withstands the mechanical forces generated during jaw movement and clenching. Researchers have proven that condylar remodeling and cartilage destruction are closely linked to the activities of masticatory muscles (23,24). If the stress from the masticatory muscles exceeds the loading of the mandibular condyle, the TMJ exhibits progressive degradation characterized by marginal proliferation, early loss of proteoglycan and fibrillation in the cartilage and changes in the subchondral bone (12). It has been reported that muscle tension, especially in the

masticatory muscles, changes with emotional state and bruxism-like activity has been observed in anxious rats (14). Also, anxious patients show a significant clinical increase in masseter electromyography levels (25).

In the current study, the fact that psychological stress could lead to TMJ abnormality was demonstrated by the histopathological changes and ultrastructural injury of condylar cartilage in stressed rats. The changes over time indicate the remodeling of condylar cartilage, reflecting the alteration of local biomechanics when animals were under stress. However, the molecular mechanism by which stress-induced muscle activities regulate condyle remodeling in the TMJ remains unclear. Recently, Cairns et al. (26) reported a role of proinflammatory cytokines in regulating the response of chondrocytes and mediating cartilage destruction in *in vitro* experiments (26). In the present study, we examined the levels of the typical proinflammatory cytokines, IL-1 β and TNF- α , in the condylar cartilage, and observed a time-dependent up-regulation of cytokines in response to stress, suggesting an involvement of proinflammatory cytokines in the cartilage degradation occurring in psychological stress-induced TMD (26). IL-1 β and TNF- α may be produced by mononuclear phagocytes and regulate the expression of adhesion molecules, nitric oxide synthesis, production of matrix metalloproteinase and the secretion of other cytokines (11,27).

Up-regulation of proinflammatory cytokines in TMD has been reported previously. Kaneyama et al. (28) found significantly increased concentrations of IL-1 β and TNF- α in the synovial fluid of patients with degenerative condyles, although no correlation was found between the concentration of any cytokine and the severity of symptoms. In patients with synovitis, correlations between the concentrations of IL-1 β and TNF- α and the degree of synovitis have been observed (29). Gulen et al. (30) also found that levels of IL-1 β and TNF- α in TMJ synovial fluid of patients with internal derangement were decreased significantly 2 weeks after arthrocentesis. These findings suggest that the proinflammatory cytokines IL-1 β and TNF- α play a vital role in TMD. In the present study, we observed stress-induced up-regulations of IL-1 β and TNF- α and concomitant cartilage destruction in the condyle, suggesting that an increase of IL-1 β and TNF- α might initiate stress-associated TMD. Cytokines released at the mandibular condyle level might further alter the normal processes of cartilage turnover, resulting in pathologic destruction or formation of cartilage. It has been reported that IL-1 β and TNF- α play important roles in the destruction of cartilage in synovitis by disrupting the anabolic and catabolic activities of the chondrocytes (31,32). A link between their up-regulation and chondrocyte metabolism in the condyle under conditions of psychological stress needs further study. In the present study, we also noted that IL-1 β expression increased at 1 week and gradually returned to normal levels thereafter, suggesting the temporary and reversible up-regulation of IL-1 β . In addition,

stress-induced alterations of IL-1 β and TNF- α levels were not fully synchronized, suggesting different roles for these two inflammatory cytokines in the pathological progress of TMJ under psychological stress. Their unique roles need further study.

The present study showed increased expression of IL-1 β and TNF- α in mandibular condyles under conditions of psychological stress, suggesting their role in the pathogenesis of stress-induced mandibular cartilage degeneration. Given the importance of IL-1 β and TNF- α in the preservation of cellular and biochemical homeostasis under normal circumstances and participation in the processes of tissue remodeling and host defense, their alteration might also contribute to the pathogenesis of TMD. They might both participate directly, or through mediation by the receptor activator of NF- κ B ligand (RANKL) and osteoprotegerin

induction, in the differentiation and activation of cartilage and bone resorbing cells (33-35). Given the important role of IL-1 β and TNF- α in the inflammatory response, anti-inflammatory medicines or antagonists of IL-1 β and/or TNF- α may alleviate or block the phenomenon found in our experiment (36). However, this hypothesis requires further investigation. Further study on the molecular mechanisms underlying the effect of psychological stress on the occurrence of TMD is also needed to identify effective treatment strategies and to improve the quality of life of TMD patients.

Acknowledgments

Research supported by the National Nature Science Foundation of China (#30801315, #81070851, #31170888).

References

- McNeill C, Mohl ND, Rugh JD, Tanaka TT. Temporomandibular disorders: diagnosis, management, education, and research. *J Am Dent Assoc* 1990; 120: 253, 255, 257.
- Hagag G, Yoshida K, Miura H. Occlusion, prosthodontic treatment, and temporomandibular disorders: a review. *J Med Dent Sci* 2000; 47: 61-66.
- Slade GD, Diatchenko L, Bhalang K, Sigurdsson A, Fillingim RB, Belfer I, et al. Influence of psychological factors on risk of temporomandibular disorders. *J Dent Res* 2007; 86: 1120-1125.
- List T, Wahlund K, Larsson B. Psychosocial functioning and dental factors in adolescents with temporomandibular disorders: a case-control study. *J Orofac Pain* 2001; 15: 218-227.
- Kafas P, Leeson R. Assessment of pain in temporomandibular disorders: the bio-psychosocial complexity. *Int J Oral Maxillofac Surg* 2006; 35: 145-149.
- Lobbezoo F, Drangsholt M, Peck C, Sato H, Kopp S, Svensson P. Topical review: new insights into the pathology and diagnosis of disorders of the temporomandibular joint. *J Orofac Pain* 2004; 18: 181-191.
- Whiteside TL. Cytokine measurements and interpretation of cytokine assays in human disease. *J Clin Immunol* 1994; 14: 327-339.
- Arend WP, Dayer JM. Cytokines and cytokine inhibitors or antagonists in rheumatoid arthritis. *Arthritis Rheum* 1990; 33: 305-315.
- Pelletier JP, DiBattista JA, Roughley P, McCollum R, Martel-Pelletier J. Cytokines and inflammation in cartilage degradation. *Rheum Dis Clin North Am* 1993; 19: 545-568.
- Takahashi T, Kondoh T, Fukuda M, Yamazaki Y, Toyosaki T, Suzuki R. Proinflammatory cytokines detectable in synovial fluids from patients with temporomandibular disorders. *Oral Surg Oral Med Oral Pathol Oral Radiol Endod* 1998; 85: 135-141.
- Kaneyama K, Segami N, Sun W, Sato J, Fujimura K. Analysis of tumor necrosis factor-alpha, interleukin-6, interleukin-1beta, soluble tumor necrosis factor receptors I and II, interleukin-6 soluble receptor, interleukin-1 soluble receptor type II, interleukin-1 receptor antagonist, and protein in the synovial fluid of patients with temporomandibular joint disorders. *Oral Surg Oral Med Oral Pathol Oral Radiol Endod* 2005; 99: 276-284.
- Dijkgraaf LC, de Bont LG, Boering G, Liem RS. The structure, biochemistry, and metabolism of osteoarthritic cartilage: a review of the literature. *J Oral Maxillofac Surg* 1995; 53: 1182-1192.
- Cui R, Suemaru K, Li B, Araki H. The effects of atropine on changes in the sleep patterns induced by psychological stress in rats. *Eur J Pharmacol* 2008; 579: 153-159.
- Rosales VP, Ikeda K, Hizaki K, Naruo T, Nozoe S, Ito G. Emotional stress and brux-like activity of the masseter muscle in rats. *Eur J Orthod* 2002; 24: 107-117.
- Zelena D, Domokos A, Barna I, Mergl Z, Haller J, Makara GB. Control of the hypothalamo-pituitary-adrenal axis in the neonatal period: adrenocorticotropin and corticosterone stress responses dissociate in vasopressin-deficient brattleboro rats. *Endocrinology* 2008; 149: 2576-2583.
- Turner JA, Mancl L, Aaron LA. Brief cognitive-behavioral therapy for temporomandibular disorder pain: effects on daily electronic outcome and process measures. *Pain* 2005; 117: 377-387.
- Wright AR, Gatchel RJ, Wildenstein L, Riggs R, Buschang P, Ellis E III. Biopsychosocial differences between high-risk and low-risk patients with acute TMD-related pain. *J Am Dent Assoc* 2004; 135: 474-483.
- Depke M, Fusch G, Domanska G, Geffers R, Volker U, Schuett C, et al. Hypermetabolic syndrome as a consequence of repeated psychological stress in mice. *Endocrinology* 2008; 149: 2714-2723.
- Kiank C, Holtfreter B, Starke A, Mundt A, Wilke C, Schutt C. Stress susceptibility predicts the severity of immune depression and the failure to combat bacterial infections in chronically stressed mice. *Brain Behav Immun* 2006; 20: 359-368.
- Fukumitsu N, Ogi S, Uchiyama M, Mori Y. Benzodiazepine effect of (125)I-iomazenil-benzodiazepine receptor binding and serum corticosterone level in a rat model. *Nucl Med Biol*

- 2005; 32: 95-100.
21. Knuth ED, Etgen AM. Corticosterone secretion induced by chronic isolation in neonatal rats is sexually dimorphic and accompanied by elevated ACTH. *Horm Behav* 2005; 47: 65-75.
 22. Rentesi G, Antoniou K, Marselos M, Fotopoulos A, Alboycharali J, Konstandi M. Long-term consequences of early maternal deprivation in serotonergic activity and HPA function in adult rat. *Neurosci Lett* 2010; 480: 7-11.
 23. Nicholson EK, Stock SR, Hamrick MW, Ravosa MJ. Biomimetic mineralization and adaptive plasticity of the temporomandibular joint in myostatin knockout mice. *Arch Oral Biol* 2006; 51: 37-49.
 24. Odman A, Mavropoulos A, Kiliaridis S. Do masticatory functional changes influence the mandibular morphology in adult rats. *Arch Oral Biol* 2008; 53: 1149-1154.
 25. Nicholson RA, Townsend DR, Gramling SE. Influence of a scheduled-waiting task on EMG reactivity and oral habits among facial pain patients and no-pain controls. *Appl Psychophysiol Biofeedback* 2000; 25: 203-219.
 26. Cairns DM, Uchimura T, Kwon H, Lee PG, Seufert CR, Matzkin E, et al. Muscle cells enhance resistance to pro-inflammatory cytokine-induced cartilage destruction. *Biochem Biophys Res Commun* 2010; 392: 22-28.
 27. Goldring MB, Birkhead JR, Suen LF, Yamin R, Mizuno S, Glowacki J, et al. Interleukin-1 beta-modulated gene expression in immortalized human chondrocytes. *J Clin Invest* 1994; 94: 2307-2316.
 28. Kaneyama K, Segami N, Nishimura M, Suzuki T, Sato J. Importance of proinflammatory cytokines in synovial fluid from 121 joints with temporomandibular disorders. *Br J Oral Maxillofac Surg* 2002; 40: 418-423.
 29. Nishimura M, Segami N, Kaneyama K, Suzuki T, Miyamaru M. Proinflammatory cytokines and arthroscopic findings of patients with internal derangement and osteoarthritis of the temporomandibular joint. *Br J Oral Maxillofac Surg* 2002; 40: 68-71.
 30. Gulen H, Ataoglu H, Haliloglu S, Isik K. Proinflammatory cytokines in temporomandibular joint synovial fluid before and after arthrocentesis. *Oral Surg Oral Med Oral Pathol Oral Radiol Endod* 2009; 107: e1-e4.
 31. Aida Y, Maeno M, Suzuki N, Namba A, Motohashi M, Matsumoto M, et al. The effect of IL-1beta on the expression of inflammatory cytokines and their receptors in human chondrocytes. *Life Sci* 2006; 79: 764-771.
 32. Roman-Blas JA, Stokes DG, Jimenez SA. Modulation of TGF-beta signaling by proinflammatory cytokines in articular chondrocytes. *Osteoarthritis Cartilage* 2007; 15: 1367-1377.
 33. Inanir A, Ozoran K, Tutkak H, Mermerci B. The effects of calcitriol therapy on serum interleukin-1, interleukin-6 and tumour necrosis factor-alpha concentrations in post-menopausal patients with osteoporosis. *J Int Med Res* 2004; 32: 570-582.
 34. Kay J, Calabrese L. The role of interleukin-1 in the pathogenesis of rheumatoid arthritis. *Rheumatology* 2004; 43 (Suppl 3): iii2-iii9.
 35. Naguwa SM. Tumor necrosis factor inhibitor therapy for rheumatoid arthritis. *Ann N Y Acad Sci* 2005; 1051: 709-715.
 36. Vernal R, Velasquez E, Gamonal J, Garcia-Sanz JA, Silva A, Sanz M. Expression of proinflammatory cytokines in osteoarthritis of the temporomandibular joint. *Arch Oral Biol* 2008; 53: 910-915.