

Holoprosencephaly with Clefts: Data of 85 Patients, Treatment, and Outcome: Part 2: Management, Surgical Treatment, and Unexpected Aspects of Holoprosencephaly Cleft Patients

Kurt W. Butow^{1,2}, Roger Arthur Zwahlen³

¹Department of Maxillofacial and Oral Surgery, Facial Cleft Deformity Clinic, University of Pretoria, ²Suite A2-Maxillo-Facial Surgery, The Life Wilgers Hospital, Pretoria, South Africa, ³Private Practice in Oral and Maxillofacial Surgery, Grand-Places 16, Fribourg, Switzerland

Abstract

Context: Cleft patients with holoprosencephaly (HPE) provide a wide clinical spectrum. Besides accessory agenesis of facial tissue structures, spanning from a single central incisor to the columella, up to the entire prolabium-premaxilla complex, brain deformities with various functional deficits may prevail, just like normal brain development. Making a precise diagnosis, just like choosing the most appropriate treatment plan often is challenging. A literature and chart review comprising 85 HPE cleft cases at the Cleft Clinic of the University of Pretoria, South Africa, was performed. It yielded pertinent diagnostic criteria and collected information about pregnancy history, brain development and survival rate as well as the initial perioperative management and the course of postsurgical midfacial growth. **Aims of Part 2:** The aim is to highlight how the here presented classification system of HPE cleft patients according to their clinical picture may facilitate the most appropriate treatment protocol. **Materials and Methods:** The classification system elaborated in Part I due to diagnostic criteria facilitated establishing classification related treatment protocol for 85 cleft cases with HPE. **Results:** According to diagnostic criteria, HPE cleft cases can be subdivided into (1) columella complex agenesis (Ag-Colum), (2) prolabium-premaxilla-columella complex agenesis in cleft lip-alveolus deformities (Ag-CLA), (3) prolabium-premaxilla-columella complex agenesis in complete hard and soft palate clefts (Ag-CLAP), and (4) “standard” uni- or bilateral CLA or CLAP (HPE-Std-cleft), including cases with an atrophic premaxilla with or without single central incisors. Relevant treatment protocols according to the particular classification are highlighted with figures and intra-operative pictures. **Conclusion:** This paper addresses the following aspects in cleft patients with HPE: A subdivision into four groups, the 3-in-1 surgical approach, the anteriorly directed midfacial growth and maternal HIV infection.

Keywords: Agnesis of cleft lip-alveolus, agnesis of prolabium-premaxilla, holoprosencephaly, treatment protocol

INTRODUCTION

Treatment strategies for various structural agnesis in cleft lip and palate patients with holoprosencephaly (HPE) do still lie in a gray zone. To shed some light into this issue, relevant literature together with a database of 4693 cleft cases in the largest cleft lip and palate unit in Southern Africa were reviewed. An overall of 85 cleft lip and palate patients with HPE^[1] (HPE-Cleft) were detected retrospectively, showing various degrees of structural agnesis. Distinctive clinical criteria exist between patients with (1) columella-nasal-septum complex agnesis (Ag-Colum), (2) prolabium-premaxilla-columella complex agnesis in cleft lip-alveolus deformity (Ag-CLA), (3) prolabium-premaxilla-columella agnesis in complete

hard and soft palate clefts (Ag-CLAP), these latter three subdivisions may be also designated agnesis-HPE (Ag-HPE) and finally, a 4) “standard” type (HPE-Std-Cleft) with unilateral or bilateral clefts (CLA or CLAP).

Related to these proposed four groups of distinctive structural agnesis, particular treatment processes have been established. Further on epigenetic factors possibly leading to HPE in cleft lip and palate patients have been discussed.

Address for correspondence: Prof. Roger Arthur Zwahlen,
Private Practice in Oral and Maxillofacial Surgery,
Grand-Places 16, 1700 Fribourg, Switzerland.
E-mail: rozwahlen@gmail.com

This is an open access journal, and articles are distributed under the terms of the Creative Commons Attribution-NonCommercial-ShareAlike 4.0 License, which allows others to remix, tweak, and build upon the work non-commercially, as long as appropriate credit is given and the new creations are licensed under the identical terms.

For reprints contact: reprints@medknow.com

How to cite this article: Butow KW, Zwahlen RA. Holoprosencephaly with clefts: Data of 85 patients, treatment, and outcome: Part 2: Management, surgical treatment, and unexpected aspects of holoprosencephaly cleft patients. *Ann Maxillofac Surg* 2019;9:146-51.

Access this article online

Quick Response Code:



Website:
www.amsjournal.com

DOI:
10.4103/ams.ams_52_19

MATERIALS AND METHODS

The following points regarding the management of cleft lip and palate patients with HPE were searched for in the clinical and electronic databases of the Cleft Clinic in the Department of Maxillo-Facial and Oral Surgery of the University of Pretoria and the Wilgers Hospital, Pretoria:

1. Epilepsy, with or without airway obstruction during an epileptic episode
2. Feeding difficulties
3. Timing and sequence of the cleft reconstruction related to the specific subdivision
4. Primary reconstruction of the midfacial agenesis
5. Long-term growth evaluation in children with one of the three Ag-HPE subdivisions and the HPE-Std-Cleft.

Epilepsy

As the severity of epilepsy affects the survival rate in patients with Ag-HPE, mostly with alobular or semilobular brain disorder (78.7%), neonates up to 3 weeks of age in this subdivision could never be consulted. This may be attributed to epileptic seizures or other major health issues during the neonatal period. However, in HPE-Std-cleft patients, the survival was found to be slightly better, with only around half of them presenting epileptic seizures.

Feeding difficulties

More serious feeding difficulties were observed in cleft lip and palate patients suffering from HPE, compared to those without additional HPE and were characterized by:

1. More severe underweight at birth
2. Midfacial hypoplasia.

Timing and sequence of cleft reconstruction

The standard treatment protocol of the cleft clinic^[2] was applied for HPE-Std-Cleft patients. For patients within the Ag-Colum, Ag-CLA, and Ag-CLAP subdivisions, however, the treatment strategy depended on the severity of the oromotor dysfunction and the epileptic seizures and the risk of postoperative aspiration. For the latter, the strategy should encompass the following:

1. Successful weight gain
2. Control of epileptic seizures
3. Control of gastroesophageal reflux; none of the patients presented here had to undergo a laparoscopically-assisted Nissen fundoplication
4. Presence and the successful wearing of a palatal obturator for the Ag-CLAP
5. One-year survival.

As the survival rate, particularly among the three subdivisions with agenesis HPE, is rather low, the surgical treatment protocol for Ag-Colum, Ag-CLA, and Ag-CLAP^[2] including the columella reconstruction, the repair of the cleft lip deformity, and the creation of an anterior nasal floor only starts at the age of 12 months. The palatal reconstruction in Ag-CLAP is performed later, at around 21 months of age.

Primary reconstruction of the midfacial agenesis

Due to the delicate general state in patients with midfacial agenesis and concomitant severe brain deformity, it is of utmost importance to avoid any unnecessary anesthetic and sequence surgery. In addition, to facilitate children's acceptance within the community, facial features should be dealt with as soon as possible, however, not before 12 months of age and a minimum of 5 kg body weight. The reconstruction of the columella, prolabium, and the oro-nasal defect in the premaxillary region is being performed in one go.^[2] This so-called 3-in-1 approach comprises the:

1. Identification of intranasal cutaneous tissue to create a columella^[3]
2. Utilization of vertical labial tissue of the lateral cleft lip border to create an anterior nasal floor in the premaxilla region
3. Reconstruction of the cleft lip in the area of the prolabium.

Secondary reconstruction of holoprosencephaly -cleft

Only a few HPE-Std-Cleft patients received some secondary reconstructions, whereas, none of the Ag-HPE cleft patients either due to their low survival rate or due to their parents who refrained from any further reconstruction.

RESULTS

General findings

The surgical 3-in-1 approach, in Ag-CLA and Ag-CLAP patients with midfacial agenesis encompasses the:

1. Use of vertical labial tissue next to the cleft lip to create the anterior nasal floor in the premaxillary region [Figure 1a-c]
2. Columella reconstruction using cutaneous intranasal tissue [Figures 2a-c and 3a-c]
3. Midline cleft lip reconstruction at the prolabium area of the [Figure 4a-c].

Though under comprehensive pediatric intensive care unit monitoring, a few postoperative complications occurred such as respiratory distress in one and aspiration pneumonia due to epileptic seizures in two cases. Some parents of Ag-HPE patients initially evaluated in the cleft lip and palate clinic, sought surgery before 12 months of age elsewhere, with some of them succumbing during the anesthesia or immediately postoperative.

Only three patients with an HPE-Std-cleft (12.0%) received secondary reconstructions and/or orthognathic treatment for (1) velopharyngeal incompetency, (2) secondary osteoplasty, (3) maxillary deformity, and (4) cleft lip revision and/or secondary cleft rhinoplasty. These reconstructions turned out to be as successful as in cleft lip and palate patients without HPE. On the other hand, mainly due to persistent medical problems or due to reduced survival rates, none of the Ag-HPE (88.0%) subdivision underwent any secondary reconstruction.

Special observations

Midfacial growth in cleft lip and palate patients with agenesis- holoprosencephaly

Unexpected midfacial growth occurred after reconstruction in some patients with agenesis of the columella, prolabium, and premaxilla [Figure 5a-e].

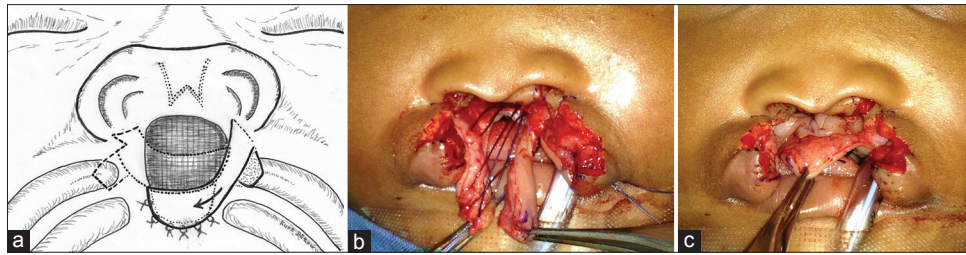


Figure 1: (a) Design and placement of the anterior nasal floor flap, (b) dissection of the bilateral anterior nasal floor flaps from the medial cleft lips for the premaxillary area, (c) the left anterior nasal floor flap for oblique positioning in the premaxillary area

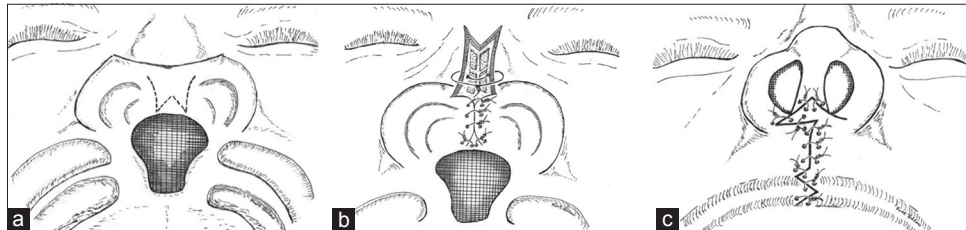


Figure 2: (a) Design of the cutaneous intranasal flap, (b) rotation of the cutaneous intranasal flap to form the columella, (c) schematic repair of a midline labial cleft with the positioned cutaneous intranasal flap as neocolumella

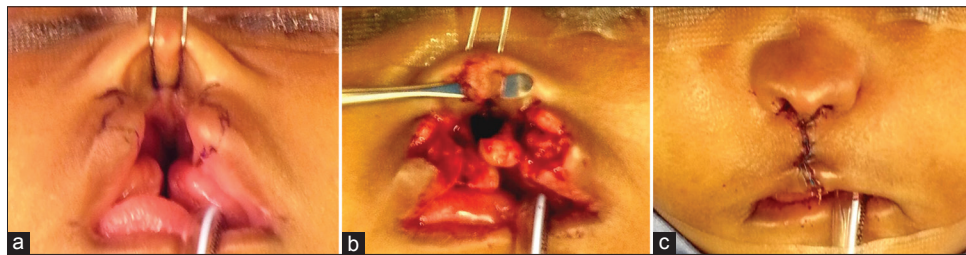


Figure 3: (a) Outlined intranasal cutaneous flap for the columella, (b) raising the intranasal flap for the columella, (c) connecting the inferior part to the repaired cleft lip

Potential viral influence on the course of cleft lip and palate patients with holoprosencephaly

Potential influence of the human immunodeficiency virus (HIV) on the course of HPE cannot be fully disregarded according to statistical findings in the database [Table 1].

DISCUSSION

Allocation of cleft lip and palate patients with HPE to one of the suggested four subdivisions provides an adequate tool to provide appropriate treatment protocols according to the extent of concomitant health related issues and structural facial agenesis.

The management of cleft lip and palate patients with HPE is multifaceted. It mainly depends on whether agenesis of facial structures prevails or not and on co-existing health issues, such as the: (1) postnatal survival rate, (2) weight gain, (3) control of epileptic seizures, (4) severity of the prevailing structural agenesis in the midface, and the (5) severity of the concomitant brain involvement.

Not all HPE-cleft patients necessarily presented with epilepsy; however, in the reviewed database, patients with Ag-CLA and Ag-CLAP suffered in 63.0% from epilepsy,

presenting with intermittently compromised airways during epileptic seizures. One of the major threats to cleft lip and palate patients with Ag-HPE and concomitant alobular or semilobular brain deformity are uncontrollable or only partially controllable epileptic seizures that might cause aspiration pneumonia and death in the peri-operative situation.

A comprehensive clinical examination and initial monitoring are mandatory. The examination has to focus on the investigation and management of epileptic seizures, respiratory obstruction, and nutritional status. A magnetic resonance imaging (MRI) determines the amount of brain deformity. This first examination might well remain the only one. Many times patients will not even survive until the date of the planned MRI imaging or of its follow-up control. Concerning follow-up controls in outpatient clinics, HPE affected cleft lip; palate patients need special monitoring, as well as on-going investigations related to their facial and neuropathological condition. Dysphagia in these patients might not only be due to severely impaired motor function^[4] similarly to that one in patients with Pierre Robin sequence, where oro-esophageal motor disorders and/or brainstem dysfunction may be detected.^[5-8] In this patient group, multiple ageneses of midfacial structures exists side by side with other disorders due to brain malformations. This contributes

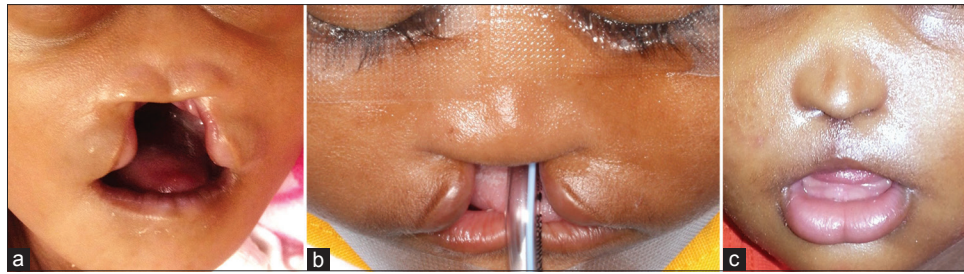

Figure 4: (a) Agenesis of cleft-lip-alveolus holoprosencephaly patient; 1 month old, (b) same agenesia of cleft-lip-alveolus holoprosencephaly patient; 12 months of age, orotracheal intubation, (c) the same agenesia of cleft-lip-alveolus holoprosencephaly patient; 14 months of age

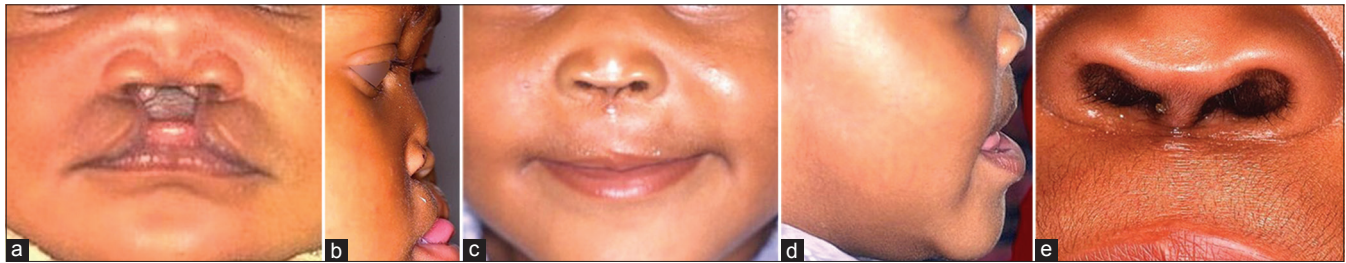

Figure 5: (a and b) Frontal and lateral views of agenesia of cleft-lip-alveolus holoprosencephaly patient at 3 months of age, (c and d) frontal and lateral views of the same patient at 6 years, (e) close view of the prolabium and columella area of the same patient

to more complex and more difficult treatable dysphagia with a delayed increase in weight, the latter an important factor in the decision whether a patient is fit for surgery.

HPE-Std-Cleft cases (12%), with or without an atrophic premaxilla, are undergoing the clinic’s standard surgical protocol for cleft lip and palate patients.^[2] However, patients from one of the three subdivisions of the Ag-HPE cleft lip and palate patients (Ag-Colum, Ag-CLA, Ag-CLAP) (88%), undergo surgery at 12 months of age only. A poor survival rate within their 1st year of life determines this timing. In 1964, already Demyer *et al.* stated: “The face predicts the brain,” a statement that certainly prevails until today in regard to the survival rate in cleft lip and palate patients with HPE.^[9] The mortality rate of Ag-HPE in this database is high [Figure 6]. Levey *et al.*, in 2010,^[4] found varying mortality rates of 58% in the first (North England), of 50% during the 4th and 5th month of life (New York State), and of 70%–80% in the 1st year and beyond. To ensure improved postoperative survival rates, surgery is performed relatively late. Slightly decreased mortality rates in this database might be attributed to this circumstance [Figure 6], particularly because the sequential treatment protocols differ for cleft lip, palate patients with or without agenesia of facial structures and concomitant facial and neuropathological disorders [Table 2].

Reviewing the literature did not reveal any information pertinent to timing or sequencing of structural midface reconstruction. It is understood that defects due to agenesia of facial structures in both Ag-CLA and Ag-CLAP patients may vary significantly in their dimensions, therefore constituting different surgical reconstructive challenges.

Commonly, a Sabattini flap^[10] is used to reconstruct a prolabium and also columella defect in cleft lip and palate patients of

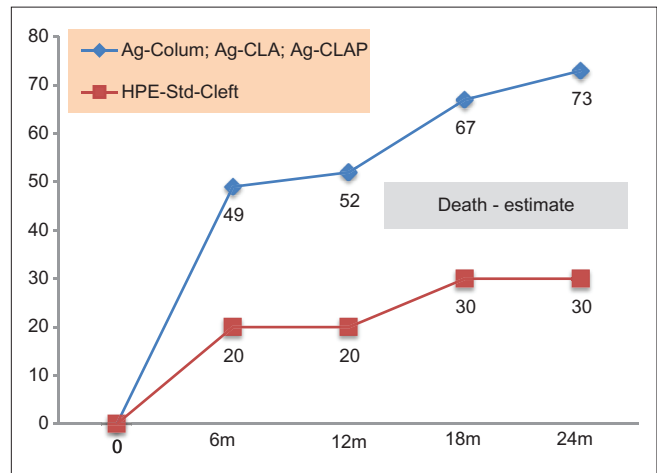


Figure 6: Neonatal/child death in percentage in a 24 months period

the Ag-CLA and Ag-CLAP subdivisions, however, without reconstructing the defect of the nasal floor in the premaxilla area. Although this approach needs two surgical interventions in medically compromised HPE patients, numerous other possibilities possibly avoiding such shortcomings do not find their way to publication. In the here presented database a three-in-one approach is somewhat exceptional as lacking midfacial structures such as columella, prolabium, and the premaxilla can be reconstructed in one go, the latter by reconstructing a two-layer anterior nasal floor. Patients in the HPE-Std-Cleft subdivision, presenting a single^[11] or two central maxillary incisors are treated according to the clinic’s standard protocol.^[2]

An extraordinary midfacial growth was observed in patients of the Ag-CLA subdivision where the midface pre-, as well as

Table 1: HIV-mother versus death of HPE cleft patient

Total number of patients	HIV+ mothers (in % of overall)	Death "HIV" (in % of respective mothers)
85	21 (24.7%)	18 (85.7%)

Table 2: Treatment protocols for Agenetic-HPE and HPE-Std-Cleft

		Agenetic HPE	HPE-Std-Cleft
Main problems	Death/survival [Figure 7]	Very high risk	High risk
	Epileptic seizures	High risk	Medium risk
	Feeding/weight gain	High/medium risk	Medium/low risk
	Brain deformity	Vast majority – a+s	Mainly – m+l
Surgical repair		Few – m+l	Few – a+s
	1. Time of repair	12 months	Standard protocol for clefts
	2. Type of repair	3 – in – 1 special repair	Standard procedures for clefts
	3. Post-op care	Paed-ICU	Paed-ICU or Standard care
	4. Aspiration	High risk – especially in cases with epileptic episodes	Low risk
	5. Airways	Medium risk	Low risk

*a+s=alobar + semilobar/m+l=middle hemisphere variation (MIH) + lobar

directly postoperatively was severely retrognathic. To the best of authors' knowledge, such a spontaneous midfacial growth cannot be found in facial cleft literature until today. It might, therefore, be speculated that the midfacial growth occurs despite or possibly even because of the lack of an anterior nasal septum, hence even if the inferior part of the frontonasal process is lacking its embryonic anlage.

Nearly 75% of HPE patients have no chromosomal mutations,^[12] However, there are at least 13 known HPE-associated genes.^[13] Maternal diabetes, influenza, ethyl alcohol, cigarette smoking, steroidal alkaloids, and retinoic acid have been listed as possible etiological factors.^[12,14] In this database, only two of those above-mentioned epigenetic factors were found: (1) maternal influenza in overall 7.1% mothers and (2) cigarette smoking in one mother. Viral infections, such as cytomegalovirus, toxoplasma, and rubella have been previously reported to be related to HPE,^[15] as well as an HPE-noncleft case with an HIV-positive mother.^[16] The occurrence of HPE babies born to HIV-positive mothers was recorded at 24.7%, with ten mothers under the antiretroviral medication and an eventual neonatal/child death rate of 85.7% [Table 1]. Possibly, the estimated number of HIV-positive mothers of children with Ag-HPE may be considerably higher. The incidence of HIV-positive mothers among all cleft patients in the database is 2.5%, whereas the prevalence in South African adults (age 15–49 years)

is 17.98%.^[17] Ag-HPE infants of HIV affected mothers are estimated to be mainly born with alobular or semilobular brain deformities (90.5%), hence with a variation of microcephaly. The question rises, whether the maternal HIV-virus may in a way contribute to some Ag-HPE in cleft lip and palate patients? Similarly, would a maternal HIV-viral conversion not be very similar to the maternal Zika viral conversion in neonates' microcephaly? The latter was reported with an apparently not conclusive prevalence of 6.0%,^[18] a percentage appreciably lower than the coincidence of maternal HIV and HPE-Clefts with severe brain deformities.

CONCLUSION

This second paper dealing with HPE in cleft lip and palate patients found and discussed four very important aspects. (1) Subdividing HPE affected cleft lip and palate patients into four groups facilitate the choice of the appropriate treatment type and sequence. (2) A 3-in-1 surgical approach has become established for cleft lip and palate patients with HPE and agenesis of the columella, prolabium, and premaxilla (subdivisions Ag-CLA and Ag-CLAP). (3) Gradual anteriorly directed growth could be detected in a preoperative and immediately postoperative retrognathic midface of a cleft lip and palate patient with HPE. (4) A high incidence of maternal HIV infection was found in cleft lip and palate patients with HPE. Treating HPE patients, particularly those three subdivisions with agenesis of facial structures (Ag-colum, Ag-CLA, and Ag-CLAP), remains a very challenging task as each case presents with particular agenesis and/or deformities of midfacial structures and various degrees of medical compromise. HPE-Std-Clefts, the here presented fourth subdivision, accounted for the second smallest subdivision; their treatment sequence may follow that of standard cleft lip and palate protocols. Nevertheless, particular steps of such treatment sequences might prove inappropriate under certain circumstances, such as due to particular facial and neurologic deformities. The severity of alobular and semilobular brain defects with midfacial deformities varies from patient to patient, thus determining specific treatment needs. Consequently, a 3-in-1 repair for cleft lip and palate patients with Ag-HPE, in particular, subdivisions Ag-CLA and Ag-CLAP, has been implemented, based on its clinical outcome and decreased perioperative morbidity. This retrospective analysis raises the question, if the development of more severe brain deformities in Ag-HPE-Clefts may be linked to some extent to maternal HIV infection.

Acknowledgment

Some of the figures presented are published in the book: Cleft – Ultimate Treatment, with permission of the authors, who hold the publishing rights.

RN Hester van der Berg, Facial Cleft Deformity Clinic, research assistant.

Declaration of patient consent

The authors certify that they have obtained all appropriate patient consent forms. In the form, the legal guardian has

given his consent for images and other clinical information to be reported in the journal. The guardian understands that names and initials will not be published and due efforts will be made to conceal identity, but anonymity cannot be guaranteed.

Financial support and sponsorship

Nil.

Conflicts of interest

There are no conflicts of interest.

REFERENCES

1. Demyer W, Zeman W. Alobar holoprosencephaly (arhinencephaly) with median cleft lip and palate: Clinical, electroencephalographic and nosologic considerations. *Confin Neurol* 1963;23:1-36.
2. Bütow KW, Zwahlen RA. Treatment protocols from neonates to adult & Median cleft reconstruction with agenesis of premaxilla-prolabium-columella. In: *Cleft – Ultimate Treatment*. 2nd ed. Durban: Reach Publisher; 2016. p. 42-3;367-74.
3. Bütow KW. Construction of the congenitally missing Columella in midline clefts. *J Craniomaxillofac Surg* 2007;35:287-92.
4. Levey EB, Stashinko E, Clegg NJ, Delgado MR. Management of children with holoprosencephaly. *Am J Med Genet C Semin Med Genet* 2010;154C:183-90.
5. Abadie V, Morisseau-Durand MP, Beyler C, Manach Y, Couly G. Brainstem dysfunction: A possible neuroembryological pathogenesis of isolated Pierre robin sequence. *Eur J Pediatr* 2002;161:275-80.
6. Renault F, Flores-Guevara R, Soupre V, Vazquez MP, Baudon JJ. Neurophysiological brainstem investigations in isolated Pierre Robin sequence. *Early Hum Dev* 2000;58:141-52.
7. Baujat G, Faure C, Zaouche A, Viarme F, Couly G, Abadie V, *et al.* Oroesophageal motor disorders in Pierre Robin syndrome. *J Pediatr Gastroenterol Nutr* 2001;32:297-302.
8. Baudon JJ, Renault F, Goutet JM, Flores-Guevara R, Soupre V, Gold F, *et al.* Motor dysfunction of the upper digestive tract in Pierre Robin sequence as assessed by sucking-swallowing electromyography and esophageal manometry. *J Pediatr* 2002;140:719-23.
9. Demyer W, Zeman W, Palmer CG. The face predicts the brain: Diagnostic significance of median facial anomalies for holoprosencephaly (arhinencephaly). *Pediatrics* 1964;34:256-63.
10. Sabbatini P. Rinoplastica e cheiloplastica operate sopra un solo individuo. *Bull Sci Med* 1838;10:387-9.
11. Richieri-Costa A, Ribeiro LA. Single maxillary central incisor, holoprosencephaly, and holoprosencephaly-like phenotype. *Am J Med Genet A* 2006;140:2594-7.
12. Winter TC, Kennedy AM, Woodward PJ. Holoprosencephaly: A survey of the entity, with embryology and fetal imaging. *Radiographics* 2015;35:275-90.
13. Solomon BD, Mercier S, Vélez JI, Pineda-Alvarez DE, Wyllie A, Zhou N, *et al.* Analysis of genotype-phenotype correlations in human holoprosencephaly. *Am J Med Genet C Semin Med Genet* 2010;154C: 133-41.
14. Richieri-Costa A, Ribeiro LA. Holoprosencephaly and holoprosencephaly-like phenotypes: Review of facial and molecular findings in patients from a craniofacial hospital in Brazil. *Am J Med Genet C Semin Med Genet* 2010;154C:149-57.
15. Dubourg C, Bendavid C, Pasquier L, Henry C, Odent S, David V, *et al.* Holoprosencephaly. *Orphanet J Rare Dis* 2007;2:8.
16. Liu DP, Burrowes DM, Qureshi MN. Cyclopia: Craniofacial appearance on MR and three-dimensional CT. *AJNR Am J Neuroradiol* 1997;18:543-6.
17. Statistics South Africa Mid-year Population Estimates 2017. HIV Statistics for South Africa – Prevalence, Incidence, ARVs, Death. Available from: <https://www.tbfacts.org/hiv-statistics-south-africa/>:P.1.
18. Haby MM, Pinart M, Elias V, Reveiz L. Prevalence of asymptomatic zika virus infection: A systematic review. *Bull World Health Organ* 2018;96:402-13D.