

Incidental finding of tracheobronchial foreign body during double lumen tube placement-lessons learned

ABSTRACT

Tracheobronchial foreign bodies are common in pediatric patients, but also seen in adult patients. Most of these patients present with history of foreign body inhalation, or with the symptoms like cough, respiratory distress. In this paper, we would like to report an incidental finding of a tablet in tracheobronchial tree during double lumen tube placement with fiberoptic bronchoscopy in a middle-aged patient scheduled for right lung decortication for hemothorax. We also learned that delay in removing the tablet would make the removal of foreign body complicated. The patient did not report any history of aspiration or have any signs and symptoms consistent with aspiration. We also discussed the difficult in diagnosing foreign-body aspiration in adults with nonspecific symptoms.


Key words: Airway; double lumen tube; fiberoptic bronchoscopy; foreign body

Introduction

Foreign bodies in the airway are common in the pediatric population and can be life threatening, but also be seen in adults. Most cases of foreign body aspiration present with history of aspiration, cough, shortness of breath, and severe obstruction with hypoxia. Foreign body aspiration signs and symptoms are nonspecific and 25% patient's chest x-rays are normal.^[1] Medications in the form of pills adversely affect the airway depend on physical and chemical properties and duration before the intervention. We would like to report a patient with tracheobronchial foreign body (tablet) during double lumen tube (DLT) placement for right lung surgery.

Case Report

A 43-year-old male with past medical history of end stage renal disease (ESRD), cirrhosis and chronic obstructive pulmonary disease, presented for a right lung decortication for a hemothorax. Preoperative airway examination revealed an edentulous Mallampati one, and no notable risk factors for aspiration. After an uneventful induction, the patient was intubated with a 37 mm left sided double lumen tube (DLT) for lung isolation using a Miller#2 blade. Bilateral air entry and ET_{CO}₂ were confirmed. Fiberoptic bronchoscopy performed through the tracheal lumen of DLT. Upon the bronchoscope exiting the tracheal lumen we visualized a tablet sticking to the junction of carina and right main bronchus with no major

| Access this article online | |
|---------------------------------------|---|
| Website: www.saudija.org | Quick Response Code  |
| DOI: 10.4103/sja.SJA_237_20 | |

This is an open access journal, and articles are distributed under the terms of the Creative Commons Attribution-NonCommercial-ShareAlike 4.0 License, which allows others to remix, tweak, and build upon the work non-commercially, as long as appropriate credit is given and the new creations are licensed under the identical terms.

For reprints contact: reprints@medknow.com

How to cite this article: Kurnutala LN, Strother AW, Hierlmeier BJ. Incidental finding of tracheobronchial foreign body during double lumen tube placement-lessons learned. Saudi J Anaesth 2020;14:514-6.

LAKSHMI N. KURNUTALA, ANGELA W. STROTHER, BRYAN J. HIERLMEIER

Department of Anesthesiology, University of Mississippi Medical Center, Mississippi, USA

Address for correspondence: Dr. Lakshmi N Kurnutala,
Department of Anesthesiology, University of Mississippi Medical Center, 2500, N State St, Jackson, MS 39216 USA.
E-mail: lkurnutala@umc.edu

Submitted: 25-Mar-2020, **Accepted:** 06-Apr-2020, **Published:** 24-Sep-2020

obstruction [Figure 1]. The surgeon immediately notified, but decided to proceed with surgery prior to retrieving the tablet due to the need to switch out the DLT for a single lumen endotracheal tube. At the end of procedure, the DLT changed to an 8.0 mm single lumen endotracheal tube and the tablet was removed in pieces using a flexible fiberoptic bronchoscopy and lavage with difficulty. The patient was extubated uneventfully in the OR and transferred to the ICU. The postoperative period was uneventful. X-ray chest of the patient on the day of surgery and CT chest two days prior to surgery did not show any radio opacity in tracheobronchial tree [Figure 2]. From the patient's medication history, we suspect the pictured tablet was a Sevelamer 800 mg given the evening before the day of surgery [Figure 3].

Discussion

Diagnosis of medication pill aspiration is often challenging, especially if there is no history of aspiration or aspiration risk.^[2] Silent aspiration described as aspiration without coughing or other distress. Mechanisms include local or central weakness/incoordination of the pharyngeal musculature, reduced airway reflexes with impaired reflexive cough and low sputum substance P or dopamine levels.^[3] Multiple studies have identified aspiration of pills can be silent and two major mechanisms of airway involvement in the form of inflammation, obstruction or both.^[4] Radiographic imaging of the airway may not be sufficient to identify tablets and a high index of suspicion can be required for timely removal of the foreign body.^[5,6] Airway involvement of medication pills divided into multiple categories including, Obstructive (capsule endoscopy, cocaine bag, sucralfate), local inflammatory (charcol, potassium pills, iron pills, sevelamer, alendronate, metformin, phenytoin), systemic effects (ACEI, amiodarone, cocaine, clopidogrel, epinephrine, heroin, rapamycin) and iatrogenic administration (N-Acetylcysteine, insulin, inhaled steroids, pentamidine).^[3,5] Flexible fiberoptic bronchoscopy or rigid bronchoscopy are the preferred methods of diagnosis and removal of foreign bodies in the tracheobronchial tree.^[7] In our case, the patient initially presented to hospital with history of cough, difficulty in breathing and right pleural effusion. Silent aspiration of the pill did not produce any major airway obstruction because it is sticking to the junction of carina and right main stem bronchus that created enough room for airflow to right lung. There was no history in preoperative period about aspiration although he had a history of cough and difficulty in breathing. Sevelamer is an ion exchange resin, used in ESRD patients to treat hyperphosphatemia. In elderly patients sevelamer aspiration infrequently causes asphyxia, but in long term it causes airway inflammation, ulceration, and

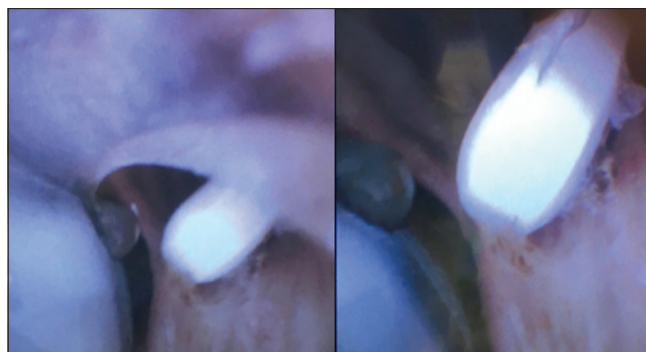

Figure 1: Fiberoptic bronchoscopy view through tracheal lumen of DLT, Carina with Bronchial cuff on left side and tablet on right

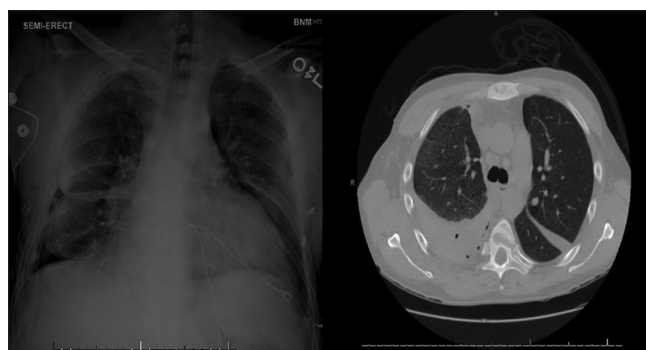

Figure 2: X-ray image on the day of surgery, CT chest image at the level of carina with no obstruction 2 days before surgery



Figure 3: Sevelamer Carbonate 800 mg

stricture formation, leading to lobar atelectasis.^[7] Sevelamer tablets are radiolucent and not visible on radiography or CT-scan so it can be difficult to diagnose without history.^[8] Diagnosis and treatment of sevelamer aspiration is done by flexible or rigid bronchoscopy and removal of tablet along with tissue biopsy of airway. Pathological examination of inflamed bronchial mucosa can show broad, curved internal fish scale appearance with deposition of sevelamer.^[8,9] As the duration between the aspiration of sevelamer pill and flexible bronchoscopic removal was ~16 h in our patient, we

did not see any major mucosal changes of tracheobronchial tree. This is the first kind of case report in literature reporting an incidental finding of tracheobronchial tree tablet during double lumen tube placement.

Conclusion

Silent aspiration is a real phenomenon, it can occur in healthier individuals along with other pathological conditions. High degree of suspicion and early diagnosis and timely management prevent serious complications after aspiration of medications. The lessons we learned in this case it is better to remove the foreign body like tablets immediately at the beginning of procedures rather than waiting for longer time like in our case. Because delaying the removal of foreign body causes softening, make it difficult to remove and cause more damage to respiratory mucosa. The foreign body may dislodge to distal airway make it worse for surgeon to access.

Declaration of patient consent

The authors certify that they have obtained all appropriate patient consent forms. In the form the patient(s) has/have given his/her/their consent for his/her/their images and other clinical information to be reported in the journal. The patients understand that their names and initials will not be published

and due efforts will be made to conceal their identity, but anonymity cannot be guaranteed.

Financial support and sponsorship

Nil.

Conflicts of interest

There are no conflicts of interest.

References

1. Limper AH, Prakash UB. Tracheobronchial foreign bodies in adults. *Ann Intern Med* 1990;112:604-9.
2. Ramsey D, Smithard D, Kalra L. Silent aspiration: What do we know? *Dysphagia* 2005;20:218-25.
3. Mehta AC, Khemasuwan. D. A foreign body of a different kind: Pill aspiration. *Ann Thorac Med* 2014;9:1-2.
4. Horner J, Massey EW. Silent aspiration following stroke. *Neurology* 1988;38:317-9.
5. Küpeli E, Khemasuwan D, Lee P, Mehta AC. Pills and air passage. *Chest* 2013;144:651-60.
6. Poudel P, Chu A, Mirchia K, Paul M. A patient with a chronic cough: An unexpected case of calcium pill aspiration. *J Investig Med High Impact Case Rep* 2019;7:2324709619828771.
7. Zaher S, Ali A, Babu P. Sevelamer crystals in the bronchus: A case report. *Thorax* 2017;72:98-9.
8. David S, Merscher S, Schmidt-Guertler H, Kielstein JT, Kirchhoff T, Meier M. A bitter pill to swallow. *ClinNephrol* 2009;72:319-21.
9. Roy CF, Roy SF, Richer L, Fraser R, Gilman S. Sevelamer aspiration. *J BroncholIntervPulmonol* 2018;25:e36-7.