



Contents lists available at ScienceDirect

International Journal of Surgery Case Reports

journal homepage: www.casereports.com

Freiberg's infraction: A modified closing wedge osteotomy for an undiagnosed case

Carlo Biz*, Alessandro Zornetta, Ilaria Fantoni, Alberto Crimi, Enrico Bordignon¹, P. Ruggieri

Orthopaedic Clinic, Department of Surgery, Oncology and Gastroenterology (DiSCOG), University of Padua, via Giustiniani 2, 35128 Padova, Italy

ARTICLE INFO

Article history:

Received 12 April 2017

Received in revised form 29 June 2017

Accepted 3 July 2017

Available online 10 July 2017

Keywords:

Case report

Avascular necrosis

Foot pain

Freiberg's infraction

Osteochondrosis

Wedge osteotomy

ABSTRACT

INTRODUCTION: Freiberg's infraction is an osteonecrosis affecting the metatarsal head whose pathogenesis is not fully understood, although stress overloading by multiple microtraumas remains the most widely accepted cause. Operative treatment, by different techniques, is necessary when conservative treatment fails.

PRESENTATION OF CASE: A 31-year old woman presented with left foot severe pain, especially at the level of the metatarsophalangeal joint (MTPJ) of the second ray, underestimated upon initial evaluation. She had a history of repetitive microtraumas, a long second metatarsal bone and altered forefoot kinematics. Clinical and radiographic findings were compatible with Freiberg's infraction. A dorsal closing-wedge osteotomy with single screw stabilization was performed. At last follow-up, the patient was completely asymptomatic with a normal MTPJ range of motion.

DISCUSSION: Our patient had a history of repetitive microtraumas combined with a long second metatarsal bone and altered forefoot kinematics. Initially, because of the low frequency of the disease and lack of knowledge about it, even among general orthopaedic surgeons, the infraction was not diagnosed. However, the radiological characteristics of the lesion, combined with intra-operative observation and histological exams associated with the medical history and clinical exam of the patient, revealed a disease compatible with Freiberg's syndrome. A closing-wedge osteotomy, performed by using a straight burr, appeared to be the most correct treatment.

CONCLUSION: This case shows how Freiberg's infraction can pass unrecognized or underestimated and how dorsal closing-wedge osteotomy can be an efficient surgical treatment.

© 2017 The Authors. Published by Elsevier Ltd on behalf of IJS Publishing Group Ltd. This is an open access article under the CC BY-NC-ND license (<http://creativecommons.org/licenses/by-nc-nd/4.0/>).

1. Introduction

Osteochondrosis of the metatarsal head was first described by A. Freiberg in 1914 [1]. Most commonly, it affects the second metatarsal head (68%), the third is harmed in 27%, the fourth in 3% of cases, while the fifth is rarely affected. Bilateral involvement is possible in 7–10% of cases [2,3]. It is 5 times more frequent in females, often healthy and athletic, and more common at a young age (10–18 years) [4]. However, in a recent paper, Lee [5] found that 6 patients in a 13-case series were obese. In 2013, Al-Ashhab [6] noted that it is occasionally found in patients whose second metatarsal bone results longer than the first, which leads to increased weight on the second metatarsal head.

Onset is insidious, clinically characterized by vague pain, sometimes similar to a chronic unilateral metatarsalgia, tenderness and swelling around the forefoot, and limited range of motion of the metatarsophalangeal joint [6,7]. The most common differential diagnoses include metatarsalgia, Morton's neuroma, stress fracture of the metatarsal and synovitis.

Freiberg [1] and later other authors [2,3] theorized that the ischemic necrosis is caused by multiple microtraumas to the second metatarsal head. Gauthier and Elbaz [8] hypothesized that the disease was the result of a subchondral insufficiency fracture; since the second metatarsal is the longest and the least mobile, excessive pressure on the metatarsal head can lead to loss of vascular connection in the subchondral bone with consequent necrosis and chondral collapse [9]. Viladot and Viladot [10] maintained that a mechanical arterial spasm occurring at the joint capsule ultimately compromises blood supply to the metatarsal epiphysis. However, stress overloading remains the most widely accepted cause.

In 1957, Smillie [2] described 5 radiographic progressive stages of degeneration caused by the disease. Stage I is characterized by a subtle fracture of the subchondral epiphysis; stage II shows a cen-

* Corresponding author.

E-mail addresses: carlo.biz@unipd.it (C. Biz), alessandro.zornetta@gmail.com (A. Zornetta), ilaria.fantoni89@gmail.com (I. Fantoni), albe.crimi@gmail.com (A. Crimi), pietro.ruggieri@unipd.it (P. Ruggieri).

¹ Enrico Bordignon was an unavoidable colleague who disappeared prematurely.

tral collapse and flattening of the metatarsal head; stage III presents a further collapse; stage IV shows a loose body formation from the periphery and complete separation of the articular fragment; in stage V, a complete degeneration of the MTPJ is observed with marked flattening and widening of the head and critical loss of joint space. Conservative treatment in the early stages (I–III) of the disorders are aimed directly at protection of the toe and alleviation of discomfort [11]. Patients who do not respond to more than 3 months of conservative approach should be considered for surgery [6]; for stages IV and V, surgical treatment is required [2].

Several surgical options have been described: resection of the metatarsal head, elevation of the depressed fragment of the metatarsal head and bone grafting of the defect, resection of the base of the proximal phalanx with syndactylization of the second and third toes, joint debridement and metatarsal head remodelling, arthroplasty, metatarsal neck shortening osteotomy without exposition of the joint, dorsal closing-wedge osteotomy of the metatarsal head, modified Weil osteotomy and arthroscopic management of lesions with debridement and microfractures [6,7,12–16].

We present a case of Freiberg's infraction treated with debridement of the metatarsophalangeal joint and an extra-articular dorsal closing-wedge osteotomy with screw fixation. The present work has been reported in line with the SCARE criteria [17].

2. Presentation of case

A 31-year-old woman, a nurse by profession, came to our orthopaedic unit in October 2012 with an 8-month history of severe pain in her left foot. She complained of constant dorsal and plantar pain, especially at the level of MTPJ of the second ray, radiating to the leg and exacerbated by walking. Sometimes the pain became constant and so intense also accompanied by swelling, causing her to limp. She had been seen for the same problem several times by her general practitioner (GP) and 6 months before at a different institution. On the basis of clinical signs, she was given pain killers and insoles and was suggested to rest, but without any benefit.

At the time of presentation, the patient was healthy, physically active and without family history of forefoot pain. She had no allergies to medications. She did not drink or smoke, and denied any drug use. She did not report a specific history of previous trauma. However, she recalled that as a child she usually walked barefoot and often stumbled, even if she did not remember any particular trauma to her feet at that age. Since adolescence, she experienced occasional dorsal pain and swelling in correspondence to the second metatarsal head of her left forefoot after sustained walking, but the symptoms regressed with rest. Over years, the pain became more frequent, not only during physical activities but even at rest, also radiating to the lateral side of the leg.

Physical examination revealed light diffuse swelling on the anterior dorsal region of the foot and painful tenderness at the level of the second metatarsal head. Active dorsal and plantar flexions of the second metatarsophalangeal joint were limited to 10° and 15°, respectively. The patient admitted constant limitation of range of motion and pain on forced hyperextension and hyperflexion of the first metatarsophalangeal joint. There was mild hallux valgus deformity and a hypermobile medial column.

Weight-bearing x-rays of antero-posterior and latero-lateral projections and an oblique view of her left foot were taken at our clinic (Fig. 1). The radiographic evaluation showed no signs of fracture. However, we noticed a flattened and sclerotic second metatarsal head, whose central portion had sunk below the surface, becoming a loose body; projections were visible in the proximal phalanx, and more little bone fragments were found in soft periarticular tissues. In addition, a bipartite medial sesamoid was found.

The patient underwent a computerized tomographic (CT) scan of her foot (Fig. 2a–e). It confirmed the flattened head of the second metatarsal, characterized by diffuse irregularity and pseudocystic subcortical formations. The cortical surface was interrupted by many erosive lesions, and many bone fragments filled the joint line, in particular, closer to the lateral and inferior part of the metatarsal head. Hence, the CT imaging study led to the identification of the disorder as Smillie stage IV [2]. This diagnosis, in addition to the clinical condition of the patient, characterized by severe and persistent pain that compromised daily activities, suggested a surgical approach.

2.1. Operative technique

After clear explanation of the procedure with the patient, the decision to proceed with surgery was made. The operation was performed under ankle-block loco-regional anesthesia with the patient in supine position on a radiolucent table. A tourniquet was applied and inflated. A dorsal 3.5 cm skin incision was centred over the midline of the second ray metatarsophalangeal joint. The extensor digitorum longus and brevis were retracted laterally, and the capsule was opened along the midline. The metatarsal distal shaft and the metatarsophalangeal joint were then exposed.

Intraoperatively, we observed an osteophyte formation in the shape of a shell, which completely covered the dorsal part of the metatarsal head, surrounded by minute bone fragments and extending to the proximal phalanx. Synovectomy, debridement and removal of loose bodies were carried out carefully before the osteotomy. After resecting the osteophyte crown gently, in order to not damage the head further, a degenerated osteochondral lesion with necrotic signs of the second metatarsal head was visible.

Using a straight burr (2–15 mm), a dorsal closing-wedge osteotomy was performed at the level of metatarsal neck. It was begun on the lateral cortex with a cut angle of approximately 50°–60° relative to the long axis of the metatarsal diaphysis and in a proximal-dorsal to distal-plantar direction. The bone cut process continued to the medial surface and then to the dorsal one, always sparing a few millimeters of the plantar surface of the metatarsal neck. The burr was applied a few times to the proximal edge of the osteotomy until it was placed almost perpendicular to the metatarsal bone axis in order to open the wedge. Manual pressure was then applied distally to close the wedge by osteoclasia and make the metatarsal head shift dorsally and proximally. In this way, the second metatarsal bone was shortened, and a functional and adequate joint connection was recreated, providing a new articular surface. A single compression screw was then applied in proximal-dorsal to distal-plantar direction to stabilize the osteotomy (Fig. 3a). Finally, the capsule and skin were closed with absorbable suture.

During the operation, specimens of hyperplastic synovium and the necrotic portion of the bone were obtained. Histological analysis showed sections of articular tissue with slight chronic inflammation and a section of necrotic bone material with neutrophil leukocyte infiltration of tissues as a result of chronic inflammation.

The post-operative course was uneventful. The patient was allowed to bear weight as tolerated on a heel-bearing shoe for 4 weeks and afterwards to rehabilitate to normal walking. The patient underwent periodic clinical and radiographic follow-up at 2, 4 and 12 weeks, and the final follow-up at 42 months (Fig. 3b). She had no complications; the skin incision and the osteotomy healed well within 4 weeks. At 3-month follow-up, the patient had resumed all of her regular activities and described no limitations in the use of shoes. Finally, after 60 months from surgery, the patient is completely asymptomatic with a normal metatarsophalangeal range of motion (Fig. 4a–d).

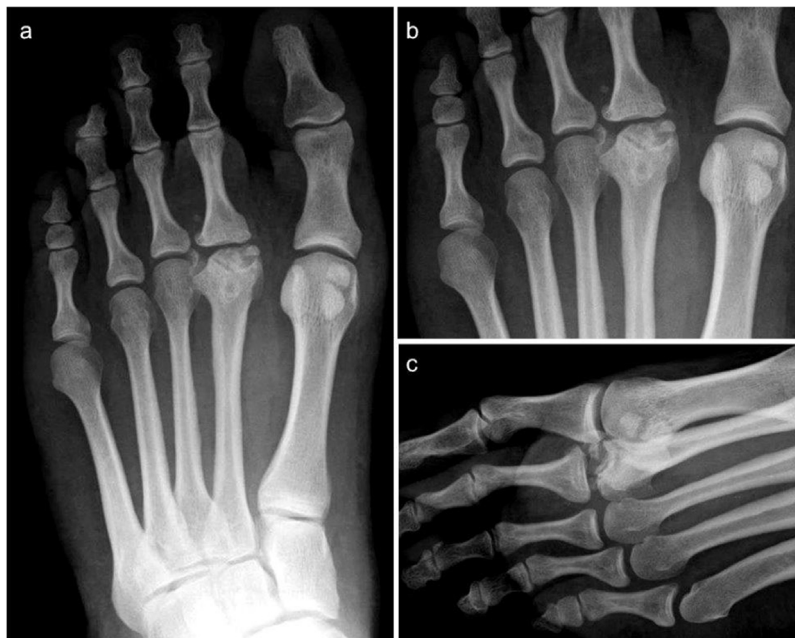

Fig. 1. Preoperative weight bearing x-rays of the left foot: **a)** antero-posterior view showing an alteration of the articular surface of the head of the second metatarsal, which appears flattened and sclerotic; **b)** particular of the first figure of the second metatarsal head. In this figure the alteration is clearly visible and it seems that the head is fragmented; **c)** lateral (lateral oblique) view showing the lesion. In this figure, Freiberg's infraction grade IV could be conceivable.

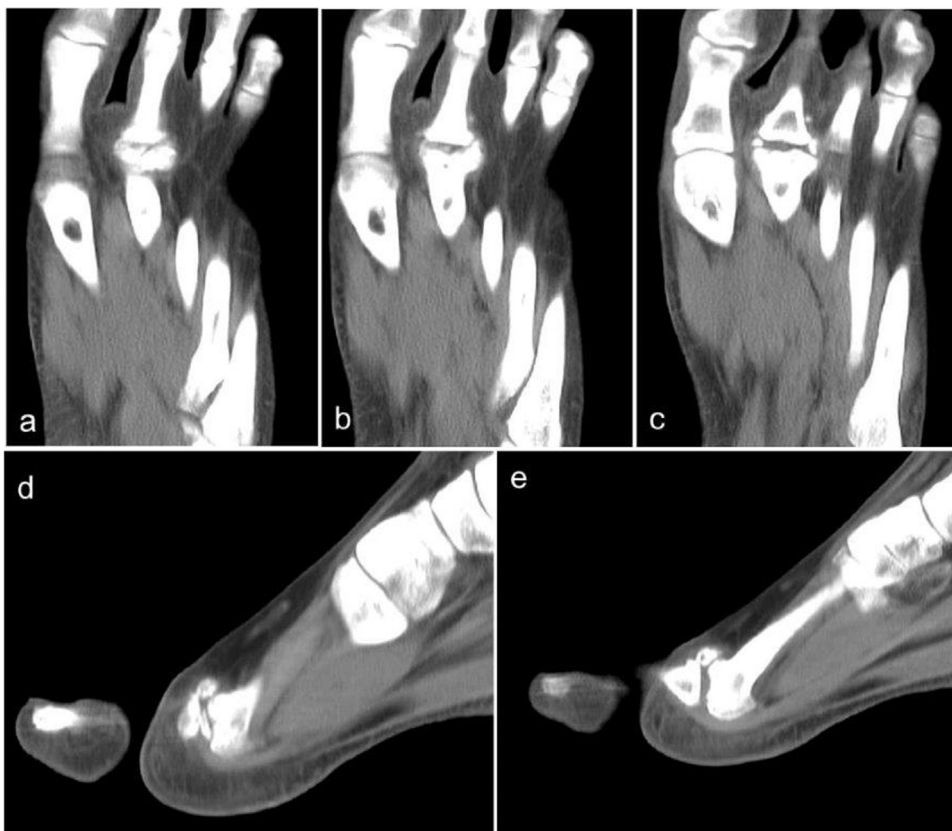


Fig. 2. **a–c)** antero-posterior CT images of the left foot showing the fragmentation and flattening of the second metatarsal head; **d, e)** Sagittal CT images showing flattening and fragmentation of the second metatarsal head, in particular in its superior part, confirming the diagnosis.

3. Discussion

Freiberg's infraction is a form of osteonecrosis affecting the metatarsal head [1]. It typically causes activity-related forefoot

pain, often even elicited by walking. Although most patients, particularly those in the early stages of the disease, can be treated conservatively, failure of conservative treatment necessitates operative treatment. Several methods have been proposed; however,

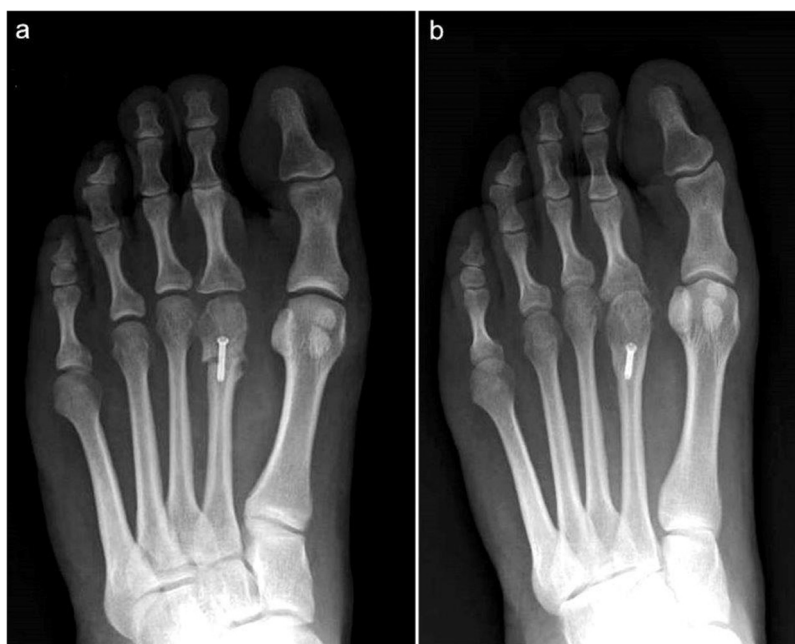

Fig. 3. a) post-operative antero-posterior view of the foot; b) weight bearing view, four weeks post-operative, showing the restoration of a normal articular surface of the second metatarsal head.

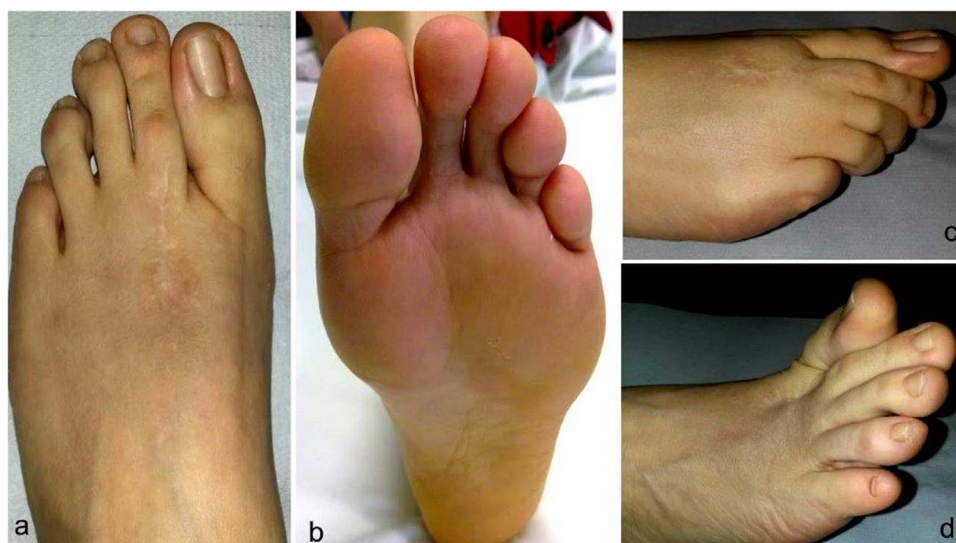

Fig. 4. clinical examination 42 months after surgery: a) dorsal and b) plantar view of the foot; c) Flexion and d) extension of the MTPJ of the second ray.

dorsal closing-wedge osteotomy has been widely performed with good results since Gauthier [8] first described this technique.

Our patient had a history of repetitive microtraumas combined with a long second metatarsal bone according to Maestro's criteria [18] and altered forefoot kinematics. Initially, because of the low frequency of the disease and the lack of knowledge about it, even among general orthopaedic surgeons, the infraction was not diagnosed. In fact, the patient was treated as if she was affected by a consolidation disturbance, such as hypertrophic pseudarthrosis of an old stress fracture. However, the radiological characteristics of the lesion, in particular those pointed out by CT, combined with intraoperative observation and histological exams associated with the medical history and clinical exam of the patient, revealed a disease compatible with Freiberg's syndrome.

Bone scan and magnetic resonance imaging (MRI) may be useful early in the disease process before radiographic changes are

evident, the latter being particularly useful as an early detector of progressive joint degeneration [19]. In our case however, the CT images played an essential role for the definitive diagnosis, showing the necrosis of the metatarsal head, the joint surface degeneration and the bone fragments, otherwise hidden by the external bony shell.

A closing-wedge osteotomy, performed by using a straight burr, appeared to be the most correct treatment, since it can restore articular congruity at the MTPJ by rotating the uninvolved articular portion to the centre of rotation [20]. Unfortunately, despite our experience in minimally invasive surgery [21,22], because of the dimensions of the lesion, it was not possible to treat it percutaneously. Hence, we performed the osteotomy in the usual way, fixing it by metalwork. Although the second metatarsal bone was shortened by the dorsal closing-wedge osteotomy, no transfer

metatarsalgia appeared later or any other complications such as delayed union, malunion or dorsal elevation of the metatarsal head.

Lee et al. [5] reported good results fixing their osteotomies with absorbable pins; drawbacks were cost and a similar duration of cast immobilization. We opted for screw fixation with no need for a second surgery to remove the screw as is necessary in osteotomies temporarily fixed with k-wires [18]. Unlike several authors [5–7,16], our patient did not have limited motion; the osteotomy healed well and complete return to normal activity was achieved. We postulate our different outcome is essentially due to precise and thin closing-wedge osteotomy (less than 5 mm) performed by a small straight burr, usually used for minimally invasive surgery, without removing too much healthy bone. In this way, when the fashioned wedge was closed by osteoclasia, the metatarsal head was allowed not only to shift dorsally and proximally, increasing the joint space, but also to derotate dorsally. Thus, the remaining part of plantar cartilage could cover most of the metatarsal joint surface. Finally, further compression of the applied screw maintained the achieved result, promoting bone vascularization, until its definitive consolidation.

4. Conclusion

This case suggests that metatarsal overload and microtraumas can lead to infraction and that a dorsal closing-wedge osteotomy, performed when conservative treatment would have been useless, can be a correct and efficient treatment. Moreover, symptoms are not clearly correlated with Freiberg's infraction in its early stages; this can lead the physician to a wrong diagnosis and treatment, permitting progression of the disease and need for surgery.

Conflicts of interest

The Authors declare that there is no conflict of interest.

Funding

This research received no specific grant from any funding agency in the public, commercial, or not-for-profit sectors.

Ethical approval

Not applicable. No research study involved.

Consent

The patient received a thorough explanation of this report gave her oral and written informed consent to be included in this report as well as for publication of these case, anonymous data, and pictures. A copy of the written consent is available for review on request.

Author contribution

Carlo Biz and Alessandro Zorretta: study concept and design; drafting the paper.

Iliaria Fantoni, Alberto Crimi and Enrico Bordignon: data collection, analysis and discussion of data.

Pietro Ruggieri: final approval of the version to be published.

Registration of research studies

Not applicable. No research study involved.

Guarantor

The corresponding author is the guarantor of submission.

References

- [1] A.H. Freiberg, *Infraction of the second metatarsal bone*, *Surg. Gynecol. Obstet.* 19 (1914) 191–193.
- [2] I.S. Smillie, *Freiberg's infraction (Kohler's second disease)*, *J. Bone Joint Surg. Br.* 39B (1957) 580.
- [3] G.A. Mandell, H.T. Harcke, *Scintigraphic manifestations of infraction of the second metatarsal (Freiberg's disease)*, *J. Nucl. Med.* 28 (1987) 249–251.
- [4] M. Uslu, M. Okur, I. Gonen, *Low-grade Osteomyelitis of the fifth metatarsal with possible concomitant Freiberg's disease of the metatarsal head*, *J. Foot Ankle Surg.* 51 (2012) 798–800.
- [5] H.J. Lee, J.W. Kim, W.K. Min, *Operative treatment of Freiberg Disease using extra-articular dorsal closing wedge osteotomy: technical tip and clinical outcomes in 13 patients*, *Foot Ankle Int.* 34 (2013) 111.
- [6] M.E.A. Al-Ashhab, W.A. Kandel, A.S. Rizk, *A simple surgical technique for treatment of Freiberg's disease*, *Foot* 23 (2013) 29–33.
- [7] S.Y. Lin, Y.M. Cheng, P.J. Huang, *Freiberg's infraction – treatment with metatarsal neck dorsal closing wedge osteotomy: report of two cases*, *Kaohsiung J. Med. Sci.* 22 (2006) 580–585.
- [8] G. Gauthier, R. Elbaz, *Freiberg's infraction: a subchondral bone fatigue fracture: a new surgical treatment*, *Clin. Orthop. Relat. Res.* 142 (1979) 93–95.
- [9] E. Özkul, M. Gem, C. Alemdar, H. Arslan, F. Boğatekin, B. Kişin, *Results of two different surgical techniques in the treatment of advanced-stage Freiberg's disease*, *Indian J. Orthop.* 50 (January-February (1)) (2016) 70–73.
- [10] A. Viladot Sr., A. Viladot Jr., *Osteochondrosis: aseptic necrosis of the foot*, *Foot Ankle Disord.* 61 (1991) 7–638.
- [11] S.T. Canale, J.H. Beaty, *Freiberg infraction*, in: *Campbell's Operative Orthopaedics*, 11th edition, Elsevier, Philadelphia, 2007.
- [12] J. Kim, W.J. Choi, Y.J. Park, J.W. Lee, *Modified Weil osteotomy for treatment of Freiberg's disease*, *Clin. Orthop. Surg.* 4 (2012) 300–306.
- [13] K.H. Chao, C.H. Lee, L.C. Lin, *Surgery for symptomatic Freiberg's disease: extrarticular dorsal closing-wedge osteotomy in 13 patients followed for 2–4 years*, *Acta Orthop. Scand.* 70 (1999) 483–486.
- [14] Y. Ozkan, A. Ozturk, R. Ozdemir, S. Aykut, N. Yalcin, *Interpositional arthroplasty with extensor digitorum brevis tendon in Freiberg's disease: a new surgical technique*, *Foot Ankle Int.* 29 (5) (2008) 488–492.
- [15] E. Tsuda, Y. Ishibashi, Y. Yamamoto, S. Maeda, Y. Kimura, H. Sato, *Osteochondral autograft transplantation for advanced stage Freiberg disease in adolescent athletes. A report of 3 cases and surgical procedures*, *Am. J. Sports Med.* 39 (11) (2011) 2470–2475.
- [16] T.W.D. Smith, D. Stanley, D.I. Rowley, *Treatment of Freiberg's disease: a new operative technique*, *J. Bone Joint Surg. Br.* 73 (1) (1991) 129–130.
- [17] R.A. Agha, A.J. Fowler, A. Saetta, I. Barai, S. Rajmohan, D.P. Orgill, *for the SCARE group, The SCARE statement: consensus-based surgical case report guidelines*, *Int. J. Surg.* 34 (2016) 180–186.
- [18] M. Maestro, J.L. Besse, M. Ragusa, E. Berthonnaud, *Forefoot morphotype study and planning method for forefoot osteotomy*, *Foot Ankle Clin.* 8 (December (4)) (2003) 695–710.
- [19] P.G. Talusan, P.J. Diaz-Collado, J.S. Reach Jr., *Freiberg's infraction: diagnosis and treatment*, *Foot Ankle Spec.* 7 (1) (2014) 52–56.
- [20] S.K. Lee, M.S. Chung, G.H. Baek, J.H. Oh, Y.H. Lee, H.S. Gong, *Treatment of Freiberg disease with intra-articular dorsal wedge osteotomy and absorbable pin fixation*, *Foot Ankle Int.* 28 (2007) 43–48.
- [21] C. Biz, M. Fossier, M. Dalmau-Pastor, M. Corradin, M.G. Rodà, R. Aldegheri, P. Ruggieri, *Functional and radiographic outcomes of hallux valgus correction by mini-invasive surgery with Reverdin-Isham and Akin percutaneous osteotomies: a longitudinal prospective study with a 48-month follow-up*, *J. Orthop. Surg. Res.* 11 (1) (2016) 157.
- [22] C. Biz, B. Hoxhaj, R. Aldegheri, C. Iacobellis, *Minimally invasive surgery for tibiotalarcalcaneal arthrodesis using a retrograde intramedullary nail: preliminary results of an innovative modified technique*, *J. Foot Ankle Surg.* 55 (6) (2016) 1130–1138.

Open Access

This article is published Open Access at [sciencedirect.com](https://www.sciencedirect.com). It is distributed under the [IJSCR Supplemental terms and conditions](#), which permits unrestricted non commercial use, distribution, and reproduction in any medium, provided the original authors and source are credited.