

Outcomes of Single Segment Implantation of Conventional Intacs versus Intacs SK for Keratoconus

Mohammad Nasser Hashemian, MD; Mohammad Ali Zare, MD; Mehrdad Mohammadpour, MD
Firouzeh Rahimi, MD; Mohammad Reza Fallah, MD; Fereydoun Keramat Panah, MD

Cornea Department, Eye Research Center, Farabi Eye Hospital, Tehran University of Medical Sciences, Tehran, Iran

Abstract

Purpose: To compare the visual, refractive, and keratometric outcomes of single-segment conventional and severe keratoconus (SK) types of Intacs for correction of inferior keratoconus (KCN).

Methods: A total number of 41 consecutive eyes of 23 patients with a diagnosis of inferior KCN underwent Intacs implantation. Eight eyes were excluded due to postoperative complications (4 eyes) and loss to follow-up (4 eyes) and finally 33 eyes underwent statistical analysis. Two groups were created according to Intacs type insertion; conventional group (17 eyes) and SK groups (16 eyes). Intracorneal ring segments (ICRS) implantation was indicated in keratoconic patients with contact-lens intolerance or reduced best spectacle-corrected visual acuity (BSCVA).

Results: In the conventional group, mean uncorrected distance visual acuity (UCDVA) improved from 0.45 ± 0.41 preoperatively to 0.69 ± 0.39 six months after surgery representing a gain of 2 Snellen lines, and in the SK group mean UCDVA changed from 0.40 ± 0.35 preoperatively to 0.58 ± 0.48 equivalent to two Snellen lines improvement 6 months after operation ($P = 0.48$). Mean preoperative BSCVA in the conventional group improved from 0.72 ± 0.41 to 0.86 ± 0.39 (2 lines improvement) postoperatively and in the SK group improved from 0.71 ± 0.69 to 0.75 ± 0.45 (0.50 line improvement) ($P = 0.29$). Mean preoperative spherical equivalent (SE) decreased from -4.86 ± 2.26 D to -3.57 ± 2.21 D (conventional group) and from -4.20 ± 1.82 D to -3.60 ± 1.89 D ($P = 0.34$), mean astigmatism (AST) decreased from -5.20 ± 2.07 D and -4.50 ± 2.26 D to -4.02 ± 2.57 D and -3.18 ± 2.14 D in the conventional and SK groups, respectively ($P = 0.68$). Finally, mean K min decreased from 47.11 ± 2.51 D to 45.40 ± 3.30 D in the conventional group and from 45.05 ± 2.59 D to 44 ± 3.88 D in the SK group ($P = 0.63$) and mean K max was decreased from 52.82 ± 3.23 D to 50.52 ± 3.57 D and from 49.72 ± 3.17 D to 48.55 ± 4.50 D, respectively ($P = 0.48$).

Conclusion: Single-segment implantation of conventional and SK Intacs improved UCDVA and BSCVA, decreased corneal AST and keratometry in both groups with comparable outcomes.

Keywords: Intacs; Keratoconus; Single-Segment

J Ophthalmic Vis Res 2014; 9 (3): 305-309.

INTRODUCTION

Keratoconus (KCN) is a bilateral noninflammatory, naturally occurring ectatic corneal condition in which the cornea gets thinner and steeper over time leading to myopia, irregular astigmatism (AST), distortion and sometimes corneal scarring which results in loss of best spectacle-corrected visual acuity (BSCVA).^[1-7]

Improvement of visual acuity is conventionally achieved by spectacles and hard contact lenses. However, with progression of the disease, spectacles and contact lenses cannot satisfy the keratoconus patient and minimally invasive surgical techniques such as intracorneal ring segment (ICRS) may be offered.^[8-10]

Correspondence to:

Mehrdad Mohammadpour, MD. Eye Research Center, Farabi Eye Hospital, Tehran University of Medical Sciences, Tehran, Iran.
E-mail: mahammadpour@yahoo.com

Received: 23-10-2013

Accepted: 15-02-2014

Access this article online

Quick Response Code:



Website:

www.jovr.org

DOI:

10.4103/2008-322X.143359

The first-ever approval for an implant to be permanently placed in the human cornea was granted by the Food and Drug Administration (FDA) in 1999. ICRS are small pieces made of synthetic materials which are implanted in the deep corneal stroma in order to make modifications in corneal curvature.^[11-17]

Two types of ICRS have been developed and used for ectatic corneal management: Intacs and Ferrara rings. Intacs consist of a pair of semicircular pieces of poly(methyl methacrylate)(PMMA) with arc length of 150° and a hexagonal transverse shape, external diameter of 8.10 mm and internal diameter of 6.77 mm with different thicknesses (0.25-0.45 mm) in 0.05 mm increments. There is an additional Intacs design named severe keratoconus (SK) with an inner diameter of 6.00 mm, oval cross section and two different thicknesses (0.40, 0.45 mm).^[11,18] Intacs is manufactured by Addition Technology Inc., Des Plaines, IL, USA.

Intacs act as a passive spacing element which shortens the arc length of the corneal anterior surface, thereby flattening the cornea.^[13]

In the majority of KCN cases, there is an inferior cone with steepening and superior flattening. Double-segments flatten the cornea inferiorly as well as superiorly, but single-segment induce inferior flattening and superior steepening resulting in greater change in I/S ratio and AST, thus reasonable optical result.^[7]

There are some studies comparing the effects of single-segment and double-segment implantation of Intacs in treatment of KCN^[10-18] however, no study has evaluated outcomes of conventional versus SK Intacs for management of inferior KCN.

Herein, the outcomes of conventional single-segment and SK single-segment implantation for inferior KCN management have been compared.

METHODS

This study was a prospective consecutive randomized interventional case series. All surgeries were performed at Farabi Eye Hospital, Tehran, Iran by a single surgeon since September 2010.

Patients aged ≥ 18 years with KCN with noncentral cone in respect to horizontal line as documented by Orbscan II or Pentacam recording, contact-lens intolerance and clear central cornea were enrolled. The corneal thickness should be at least 450 μ at 7 mm optical zone or over the area in which the Intacs were to be inserted. Contact-lens intolerance was defined as poor fitting, intolerable foreign body sensation, and visual disturbance such as low vision, glare, diplopia, halos and scatter.

Exclusion criteria included previous ocular surgery, herpetic keratitis and connective tissue disorders. All patients provided written informed consent.

The types of Intacs were selected by block randomized technique. Patients were evaluated preoperatively and 1, 3 and 12 months after surgery. Postoperative examinations included uncorrected distance visual acuity (UCDVA), best spectacle-corrected visual acuity (BSCVA), manifest and cycloplegic refraction, slit lamp biomicroscopy, Goldmann tonometry, indirect ophthalmoscopy, keratometry and Orbscan II or pentacam.

Surgical Procedure

Operations were performed under topical anesthesia, using a diamond knife set at 70% thinnest point. A 1.8 mm radial incision was formed in the marked position, set on the steep axis of the cornea. Corneal inferior pocket were created using Sinsky and Suarez spreader. One inferior tunnel was then formed using dissector under suction created by a vacuum-centering guide. The single-segment Intacs (conventional 450 or SK 450) was implanted in the corneal tunnel. Incision was sutured using a single 10/0 nylon stitch. All procedures were uneventful, all eyes received betamethasone and chloramphenicol eye drops 4 times daily. Sutures were removed 4 weeks after surgery.

Statistical Analysis

Data were analyzed for all patients who successfully completed at least 9-months' follow-up. Statistical comparisons between preoperative and postoperative values were performed using the Wilcoxon test for UCDVA, BSCVA, manifest refraction spherical equivalent, Kflat and Ksteep (SPSS 15, SPSS Inc., Chicago, Illinois, USA).

Changes in all parameters were compared using independent sample *t*-test and $P < 0.05$ was considered as statistically significant.

RESULTS

Of a total of 41 eyes in 23 patients successfully implanted with Intacs (Addition Technology Inc., Des Plaines, IL, USA), 33 eyes of 22 patients including 19 male (57.6%) and 14 female (42.4%), 21 OD (63.6%), and 12 OS (36.4%) subjects with mean age of 27.6 ± 5.98 (range 21 to 43) years were enrolled for statistical analysis. In four eyes the Intacs were removed due to segment extrusion including one eye with suture infection not responding to antibiotics 3 weeks after implantation, one eye with incision site vascularization 3 months postoperatively and 2 eyes with surface perforation 4 months after surgery. Four other eyes were excluded because of loss to follow-up. Mean follow-up was 13.33 ± 1.94 (range 11 to 180) months. Intacs was 450 μ m in conventional and SK-type.

In the conventional group, mean UCDVA improved from 0.45 ± 0.41 preoperatively to better than 0.69 ± 0.39

six months after surgery representing a gain of 2 Snellen lines. In the SK group, mean UCDVA changed from 0.40 ± 0.35 preoperatively to 0.58 ± 0.48 representing two Snellen lines of improvement 6 months after operation ($P = 0.48$). Mean preoperative BSCVA in the conventional group improved from 0.72 ± 0.41 to 0.86 ± 0.39 (2 lines improvement) postoperatively and in the SK group improved from 0.71 ± 0.69 to 0.75 ± 0.45 (0.50 line improvement) ($P = 0.29$) [Figures 1-3]. Mean preoperative SE decreased from -4.86 ± 2.26 D to -3.57 ± 2.21 D (conventional group) and from -4.20 ± 1.82 D to -3.60 ± 1.89 D (SK group) ($P = 0.34$), Mean AST decreased from 5.20 ± 2.07 D and 4.50 ± 2.26 D to 4.02 ± 2.57 D and 3.18 ± 2.14 D in conventional and SK groups, respectively ($P = 0.68$). Finally, K min (K flat) decreased from 47.11 ± 2.51 D to 45.40 ± 3.30 D in the conventional group and from 45.05 ± 2.59 D to 44 ± 3.88 D in the SK group ($P = 0.63$) and K max (K steep) reduced from 52.82 ± 3.23 D to 50.52 ± 3.57 D and from 49.72 ± 3.17 D to 48.55 ± 4.50 D in the conventional and SK groups, respectively ($P = 0.48$) [Tables 1-3].

DISCUSSION

Intacs are relatively new devices for reinforcing the cornea though the arc-shortening effect of the corneal lamellae that flattens the central cornea. The keratoconic tissue with thinner structure than normal corneal tissue can be flattened more easily. It is also more logical to reinforce the weak cornea by adding tissue and to avoid further weakening by incisional or ablative measures such as photorefractive keratectomy and laser *in situ* keratomileusis.^[1-4]

Inserting Intacs for KCN treatment does not eliminate the corneal disease but decreases associated corneal abnormality and improves visual acuity and delays or eliminates the necessity for corneal grafting.

Alió et al^[1] evaluated the effect of implanting intracorneal rings on best corrected visual acuity (BCVA) of patients with clear corneal KCN and concluded that 1 or 2 Intacs implantation, according to the preoperative corneal topographic appearance of KCN, safely and effectively reduced corneal steepening and AST in patients with clear corneal KCN along with contact-lens intolerance. Mean postoperative UCDVA and BSCVA were significantly improved, and mean keratometric reading was significantly reduced after one year follow-up. The rate of complications reported in their series was low. Implantation of 1 or 2 segments can be performed safely and effectively on the basis of the preoperative corneal topographic aspect of KCN. More ideal outcomes of single-segment implantation may be due to the anatomical change in the keratoconic cornea, which usually occurs asymmetrically in the inferior cornea.

Postoperative results in the current series demonstrated

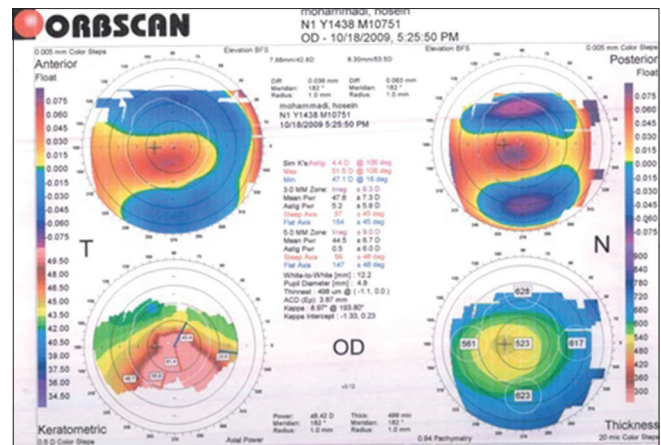


Figure 1. Preoperative Orbscan of the right eye of a case with inferior keratometry.

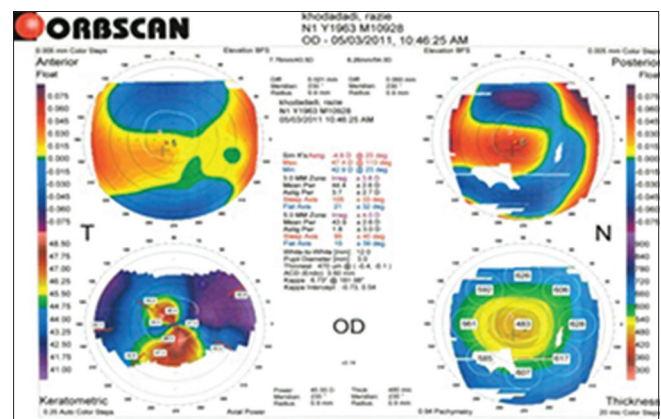


Figure 2. Postoperative Orbscan of the right eye shows a decrease in keratometry and astigmatism.

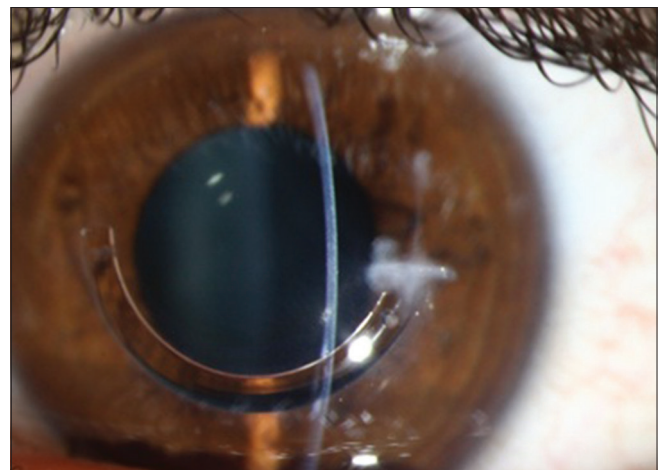


Figure 3. Anterior segment photography of incisional infectious keratitis.

that spherical equivalent error, AST, K steep and K flat significantly decreased and visual acuity improved in almost all cases in both groups. Corneal curvature also decreased in both K steep and K flat parameters, with

Table 1. Comparison of preoperative parameters in conventional Intacs group and SK group

Variable	Conventional group	SK group	P value
UCDVA	0.45±0.41	0.40±0.35	0.76
BSCVA	0.72±0.41	0.71±0.69	0.9
MRSE (D)	-4.86±2.26	-4.2±1.82	0.36
AST (D)	-5.20±4.50	-0.450±2.26	0.36
K flat	47.11±2.50	45.05±2.59	0.02
K steep	52.8±3.2	49.7±3.1	0.009

UCDVA, uncorrected distance visual acuity; BSCVA, best spectacle-corrected visual acuity; MRSE, manifest refraction spherical equivalent; AST, astigmatism; SK, severe keratoconus; D, diopter

Table 2. Comparison of postoperative parameters in conventional Intacs and SK Intacs

Variable	Conventional Intacs	SK Intacs	P value
UCDVA	0.69±0.39	0.58±0.48	0.28
BSCVA	0.86±0.39	0.75±0.45	0.07
MRSE (D)	-3.57±2.21	-3.60±1.89	0.96
AST (D)	-4.02±2.57	-3.18±2.14	0.32
K flat	45.40±3.30	44.00±3.88	0.27
K steep	50.52±3.57	48.55±4.50	0.17

UCDVA, uncorrected distance visual acuity; BSCVA, best spectacle-corrected visual acuity; MRSE, manifest refraction spherical equivalent; SK, severe keratoconus; AST, astigmatism; D, diopter

Table 3. Comparison of variance between conventional Intacs and SK Intacs groups

Variance	Intacs	Mean±SD	P value
Difference of UCDVA	Conventional	0.54 (SD±0.33)	0.48
	SK	0.11 (SD±0.48)	
Difference of BCDVA	Conventional	0.69 (SD±0.69)	0.29
	SK	0.30 (SD±0.47)	
Difference of MRSE (D)	Conventional	1.29±1.23	0.34
	SK	0.50±0.73	
Difference of AST (D)	Conventional	1.17±1.41	0.68
	SK	1.31±1.50	
Difference of K flat	Conventional	2.3±2.82	0.63
	SK	1.17±3.59	
Difference of K steep	Conventional	1.71±2.6	0.48
	SK	1.05±2.93	

UCDVA, uncorrected distance visual acuity; BSCVA, best spectacle-corrected visual acuity; MRSE, manifest refraction spherical equivalent; AST, astigmatism; SK, severe keratoconus; SD, standard deviation; D, diopter

slightly more reduction in K steep which is consistent with the results of earlier studies.^[1-12]

In both groups, any line-loss in UCDVA and BSCVA over a period of one year after implantation was not detected as compared to one-month post operation. After the procedure, from 27 eyes with contact-lens intolerance

13 eyes including 6 eyes of SK group and 7 eyes of conventional group became contact-lens-tolerant.

Although the treatment of clear corneal KCN with Intacs seems to be a minimally invasive technique for reducing the corneal steepening, AST and improving the visual acuity, further follow-up is required to draw out the ultimate effect of Intacs on the natural progression of KCN and to determine their probable impact on clinical indications and outcomes of penetrating keratoplasty procedure (PKP) or any other surgical procedure which may be performed for involved eyes in the future.^[5-14]

In summary, implanting conventional or SK types of single-segment intracorneal ring is an effective procedure for the treatment of inferior KCN with no significant difference in refraction and visual outcomes and keratometry in two groups.

REFERENCES

- Alió JL, Artola A, Hassanein A, Haroun H, Galal A. One or 2 Intacs segments for the correction of keratoconus. *J Cataract Refract Surg* 2005;31:943-953.
- Hellstedt T, Mäkelä J, Uusitalo R, Emre S, Uusitalo R. Treating keratoconus with intacs corneal ring segments. *J Refract Surg* 2005;21:236-246.
- Pokroy R, Levinger S. Intacs adjustment surgery for keratoconus. *J Cataract Refract Surg* 2006;32:986-992.
- Rabinowitz YS. Intacs for keratoconus. *Curr Opin Ophthalmol* 2007;18:279-283.
- Colin J, Cochener B, Savary G, Malet F, Holmes-Higgin D. INTACS inserts for treating keratoconus: One-year results. *Ophthalmology* 2001;108:1409-1414.
- Colin J, Cochener B, Savary G, Malet F. Correcting keratoconus with intracorneal rings. *J Cataract Refract Surg* 2000;26:1117-1122.
- Sharma M, Boxer Wachler BS. Comparison of single-segment and double-segment Intacs for keratoconus and post-LASIK ectasia. *Am J Ophthalmol* 2006;141:891-895.
- Chan CC, Sharma M, Wachler BS. Effect of inferior-segment Intacs with and without C3-R on keratoconus. *J Cataract Refract Surg* 2007;33:75-80.
- Coskunseven E, Jankov MR 2nd, Hafezi F, Atun S, Arslan E, Kymionis GD. Effect of treatment sequence in combined intrastromal corneal rings and corneal collagen crosslinking for keratoconus. *J Cataract Refract Surg* 2009;35:2084-2091.
- Sansanayudh W, Bahar I, Kumar NL, Shehadeh-Mashour R, Ritenour R, Singal N, et al. Intrastromal corneal ring segment SK implantation for moderate to severe keratoconus. *J Cataract Refract Surg* 2010;36:110-113.
- Pokroy R, Levinger S, Hirsh A. Single Intacs segment for post-laser *in situ* keratomileusis keratectasia. *J Cataract Refract Surg* 2004;30:1685-1695.
- Piñero DP, Alio JL, El Kady B, Coskunseven E, Morbelli H, Uceda-Montanes A, et al. Refractive and aberrometric outcomes of intracorneal ring segments for keratoconus: Mechanical versus femtosecond-assisted procedures. *Ophthalmology* 2009;116:1675-1687.
- Colin J, Malet FJ. Intacs for the correction of keratoconus: Two-year follow-up. *J Cataract Refract Surg* 2007;33:69-74.
- Bourcier T, Borderie V, Laroche L. Late bacterial keratitis after implantation of intrastromal corneal ring segments. *J Cataract Refract Surg* 2003;29:407-409.

15. Colin J. European clinical evaluation: Use of Intacs for the treatment of keratoconus. *J Cataract Refract Surg* 2006;32:747-755.
16. Alió JL, Shabayek MH, Belda JI, Correas P, Feijoo ED. Analysis of results related to good and bad outcomes of Intacs implantation for keratoconus correction. *J Cataract Refract Surg* 2006;32:756-761.
17. Rabinowits YS. Intacs for keratoconus. *Int Ophthalmol Clin* 2013;50:63-76.
18. Shetty R, Kurian M, Anand D, Mhaske P, Narayana KM, Shetty BK. Intacs in advanced keratoconus. *Cornea* 2008;27:1022-1029.

How to cite this article: Hashemian MN, Zare MA, Mohammadpour M, Rahimi F, Fallah MR, Panah FK. Outcomes of Single Segment Implantation of Conventional Intacs versus Intacs SK for Keratoconus. *J Ophthalmic Vis Res* 2014;9:305-9.

Source of Support: Nil. **Conflict of Interest:** None declared.

Author Help: Online submission of the manuscripts

Articles can be submitted online from <http://www.journalonweb.com>. For online submission, the articles should be prepared in two files (first page file and article file). Images should be submitted separately.

- 1) **First Page File:**
Prepare the title page, covering letter, acknowledgement etc. using a word processor program. All information related to your identity should be included here. Use text/rtf/doc/pdf files. Do not zip the files.
- 2) **Article File:**
The main text of the article, beginning with the Abstract to References (including tables) should be in this file. Do not include any information (such as acknowledgement, your names in page headers etc.) in this file. Use text/rtf/doc/pdf files. Do not zip the files. Limit the file size to 1 MB. Do not incorporate images in the file. If file size is large, graphs can be submitted separately as images, without their being incorporated in the article file. This will reduce the size of the file.
- 3) **Images:**
Submit good quality color images. Each image should be less than 4096 kb (4 MB) in size. The size of the image can be reduced by decreasing the actual height and width of the images (keep up to about 6 inches and up to about 1800 x 1200 pixels). JPEG is the most suitable file format. The image quality should be good enough to judge the scientific value of the image. For the purpose of printing, always retain a good quality, high resolution image. This high resolution image should be sent to the editorial office at the time of sending a revised article.
- 4) **Legends:**
Legends for the figures/images should be included at the end of the article file.