

Available online at www.sciencedirect.com

ScienceDirect

journal homepage: www.elsevier.com/locate/radcr

Case Report

CT findings of severe burn injuries after a motor vehicle collision: a case report

En-Haw Wu, MD^{a,*}, Daniel Shouldice, MD^b, Jeffrey Robinson, MD, MBA^c

^aDepartment of Radiology, University of Washington, 1959 NE Pacific St, Seattle, WA 98195, USA

^bDepartment of Emergency Medicine, University of Washington, 325 9th Ave, Seattle, WA 98104, USA

^cDepartment of Radiology, University of Washington, Box 359728, 325 9th Ave, Seattle, WA 98104, USA

ARTICLE INFO

Article history:

Received 15 March 2019

Revised 22 May 2019

Accepted 22 May 2019

Available online 14 June 2019

Keywords:

Computer tomography

Burn

Motor vehicle collision

ABSTRACT

Severe burn injuries can complicate management of polytrauma. While CT is the primary imaging modality for evaluation of trauma injuries, CT findings of severe burn are rarely reported. A 31-year-old female was brought to the emergency department after motor vehicle collision in which she sustained a burn injury from contact with the vehicle muffler. Her initial trauma workup was notable for full-thickness burns to her left abdominal wall among other injuries. CT scan showed skin thickening and extensive stranding involving the whole layer of subcutaneous soft tissue. The deep fascia and underlying muscle layer were free from burn injuries. Identification of this finding on the CT scan helps establish appropriate care.

Published by Elsevier Inc. on behalf of University of Washington.

This is an open access article under the CC BY-NC-ND license.

(<http://creativecommons.org/licenses/by-nc-nd/4.0/>)

Introduction

Motor vehicle collisions (MVC) result in a wide range of injuries to patients due to the frequent high speeds and complex mechanisms involved. An extensive burn from MVC may complicate a patient's management [1]. Most burn injuries are diagnosed and classified based on the clinical examination. CT scan is the primary imaging modality for patients after sustaining acute injuries [2]. CT imaging findings of severe acute burns are rarely reported. We report a case of an extensive burn injury to the abdominal wall in a patient after MVC. We present the CT findings of burn injury and review the literature.

Case report

A 31-year-old female who was brought to the Emergency Department after a MVC in which she was ejected from the car and subsequently found trapped underneath the car itself. She sustained an extensive burn injury to her abdominal wall from contact with the vehicle muffler. Her examination was notable for nonblanching pink/pale and painless areas to her left anterior abdomen. Findings were consistent with full-thickness burns to the area. As she had presented a trauma activation, she underwent standard total body trauma CT.

CT of abdomen showed skin thickening and extensive subcutaneous tissue stranding involving the left anterior

* Corresponding author.

E-mail address: ehw5@uw.edu (E.-H. Wu).

<https://doi.org/10.1016/j.radcr.2019.05.027>

1930-0433/Published by Elsevier Inc. on behalf of University of Washington. This is an open access article under the CC BY-NC-ND license. (<http://creativecommons.org/licenses/by-nc-nd/4.0/>)

abdominal wall (Fig. 1) and left breast (not shown) correlating to the physical findings. CT densities of the stranding areas measured from -20 to 20 Hounsfield unit. The stranding was confined above the deep fascia. Soft tissue underneath the deep fascia and the underlying rectus abdominis muscle were intact (Fig. 2).

In addition to the burn to the abdominal wall, she also sustained burn injuries to her left wrist and thigh, and right ankle. The total body surface area (TBSA %) of the burn injury was 6%. CT scan also revealed an American Association for the Surgery of Trauma (AAST) grade 2 renal laceration and fractures of the T2-T5 spinous processes (not shown). The patient was treated with surgical debridement and subsequent skin grafting in the burn unit. She was discharged uneventfully in 2 weeks.

Discussion

Burn injury represents a complex clinical entity with significant morbidity [3]. Coexisting extensive burn injuries complicate diagnosis and management of the patients sustaining polytrauma. Many of such trauma-related burn injuries were found in motor vehicle accidents [1]. Awareness of burn injuries in these patients are the crucial for an appropriate care.

Burn injuries are resulted from exposure to heat and chemicals. Thermal insult results in coagulative necrosis of the skin and underlying soft tissue. A cascade of vasoactive mediators is released, and these inflammatory mediators alter the capillary permeability of the skin and underlying soft tissue [4,5]. The degree of injury is classified based on the skin and soft tissue layers being involved [6]. These overall can attribute to the diffuse changes on skin and soft tissue findings on imaging studies.

Radiography generally constitutes the initial examination for patients with polytrauma and soft-tissue injury. Findings of burn injuries on radiographs include soft tissue swelling, effacement of fat planes, and possibly skin discontinuity in severe burn injuries [7]. Identification of the degree and extent of burns can be difficult and limited on radiographs. Ultrasonography can be performed at the bedside and offers real time evaluation of the soft tissue pathology or injury [8]. However, performance of the ultrasonography can be limited by the patient's skin condition, such as reverberation artifact from air between skin or soft tissue defects [9]. Magnetic resonance imaging is a highly sensitive examination for soft tissue by offering anatomical definition and pathophysiologic evaluation [10]. In most cases, magnetic resonance imaging serves as a secondary tool of imaging if there is a need for further characterization and sometimes not widely available in the emergency setting.

Multislice computed tomography (CT) is the standard imaging for patients sustaining polytrauma and MVCs [11]. While CT offers evaluation of the injuries of the visceral organs, it also provides an analysis of compartmental anatomy and evaluation of the overlying skin and soft tissue pathology due to the high spatial resolution and capability of multiplanar reformatting [12]. CT imaging of the extensive burn injuries is rarely reported. However, it is important to recognize such a finding in patients with polytrauma. The skin consists

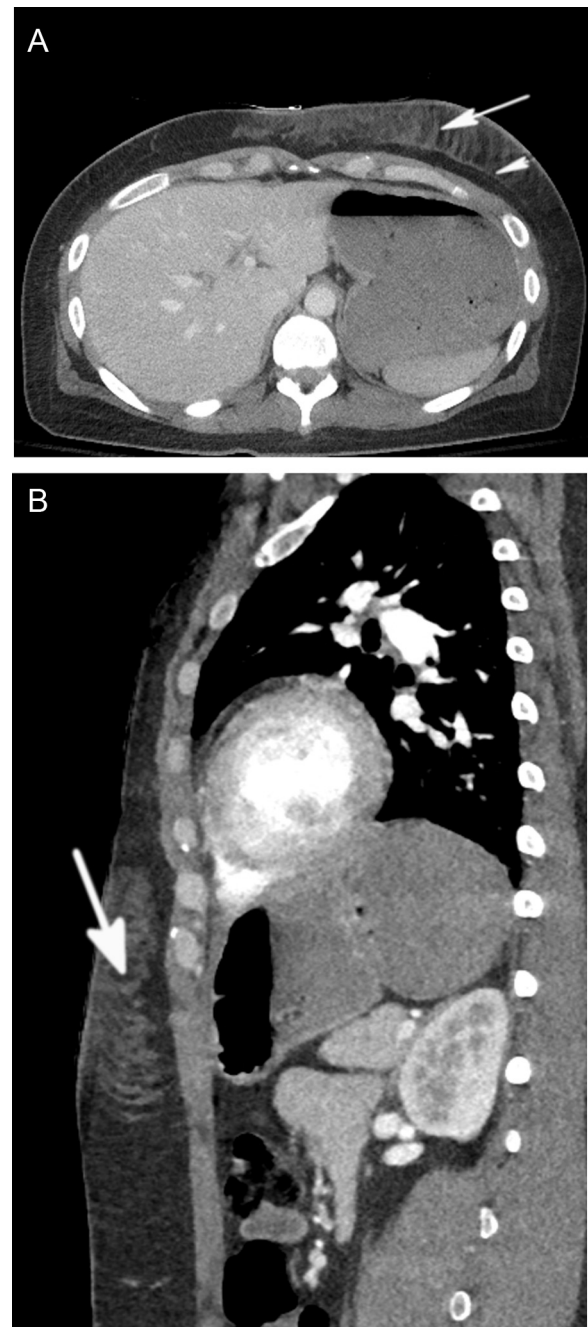


Fig. 1 – CT scan of full thickness burn injury. A 31-year-old female after motor vehicle collision. (A) Axial image of CT of abdomen with IV contrast shows subcutaneous stranding extensively involves left anterior abdominal wall. Some of the stranding involves the subcutaneous fat lobules and forms thick bank-like or polygonal densities (arrow) above the deep fascia (arrowhead). Soft tissue beneath the deep fascia layer and the underlying rectus abdominis muscle are intact without evidence of injury. (B) Sagittal CT image shows subcutaneous stranding extensively involving the subcutaneous layer of abdominal wall.

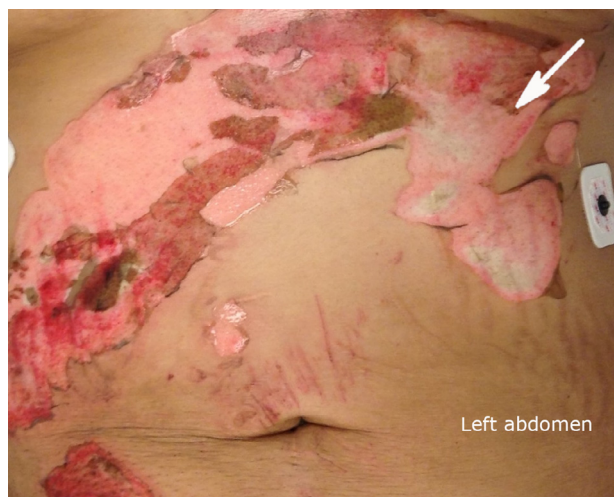

Fig. 2 – Clinical photograph of the same patient’s full thickness burn. Photograph of anterior abdominal wall at the bedside shows pink/pale areas in the anterior abdomen secondary to the full thickness burn injury (arrow).

of 3 layers which include epidermis, dermis, and hypodermis. The 2 first layers are typically 1-4 mm in thickness [13]. On the CT imaging, these 2 layers cannot be resolved and represent the relatively hyperdense layer of the skin [7,12]. The hypodermis layer or subcutaneous soft tissue is comprised of fatty tissue with interspersed neurovascular nerve structures. The average subcutaneous fat thickness in the abdominal wall is 2-4 mm [13,14]. This layer generally demonstrates hypodensity on CT imaging because of fatty components. Below the hypodermis are a firm collagenous deep fascia. Further below lies the deep fat layer and investing fascia of the musculature [15,16].

In our case, CT images showed burn injuries that involved the superficial and hypodermis layers of skin. The burn-related stranding diffusely involved the hypodermis fat lobules. Those injuries were confined above the underlying deep fascia. These findings correlated well with the clinically classified full thickness burn injury. There is lack of literature regarding use of IV contrast enhancement in evaluation of the burn injuries. Increased densities of hypodermis fat in our case are possibly attributed to extravasation of contrast material due to increased capillary permeability, a result of inflammatory process or necrosis of soft tissue [7,17]. CT is unable to further define the zones of burn injuries, which is widely accepted theory for pathophysiologic changes of burn injury [4]. Although there is rarity of reports, those burn-related stranding in the soft tissue is supposed to regress in approximately 2 weeks as the acute inflammatory factors and cytokines start to decline in 1 week and gradually return to baseline level in 2-3 weeks [5,18].

CT finding of the diffuse stranding and increased densities from burn injuries can be similar to the other pathologies, such as, contusion, hematoma, soft tissue edema, and infection [7]. However, subcutaneous contusion or hematoma usually results in disruption of the connective tissue in the hypo-

dermis, resulting in a bulkier hyperdensity on CT images [19]. Image findings of noninflammatory soft-tissue edema, such as congestive heart failure, are usually more extensive and diffuse. Diffuse cellulitis can also demonstrate focal skin thickening, septation of the subcutaneous fat, and thickening of the underlying superficial fascia [12]. In most cases, clinical history helps differentiate cellulitis or infection from traumatic injuries.

Severe burns can complicate the management of injuries from MVCs. CT scan helps evaluate the extent and depth of the burn injury while serving as a primary imaging tool for patients with polytrauma. CT findings of full thickness burn injuries include skin thickening and diffuse stranding of subcutaneous soft tissue. Familiarity with these findings can aid the emergency radiologist to provide accurate diagnosis.

Conflict of interest

None.

Supplementary material

Supplementary material associated with this article can be found, in the online version, at doi:10.1016/j.radcr.2019.05.027.

REFERENCES

- [1] Purdue GF, Hunt JL. Multiple trauma and the burn patient. *Am J Surg* 1989;158(6):536–9.
- [2] Soto JA, Anderson SW. Multidetector CT of blunt abdominal trauma. *Radiology* 2012;265(3):678–93.
- [3] Webb AR. *Oxford textbook of critical care*. Oxford; New York: Oxford University Press; 1999. xxxvi, 1384, 37 p. p.
- [4] Hettiaratchy S, Dziewulski P. ABC of burns: pathophysiology and types of burns. *BMJ* 2004;328(7453):1427–9.
- [5] Rose LF, Chan RK. The burn wound microenvironment. *Adv Wound Care (New Rochelle)* 2016;5(3):106–18.
- [6] DeSanti L. Pathophysiology and current management of burn injury. *Adv Skin Wound Care* 2005;18(6):323–32 quiz 32-4.
- [7] Hayeri MR, Ziai P, Shehata ML, Teytelboym OM, Huang BK. Soft-tissue infections and their imaging mimics: from cellulitis to necrotizing fasciitis. *Radiographics* 2016;36(6):1888–910.
- [8] Bureau NJ, Chhem RK, Cardinal E. Musculoskeletal infections: US manifestations. *Radiographics* 1999;19(6):1585–92.
- [9] Feldman MK, Katyal S, Blackwood MS. US artifacts. *Radiographics* 2009;29(4):1179–89.
- [10] Soldatos T, Durand DJ, Subhawong TK, Carrino JA, Chhabra A. Magnetic resonance imaging of musculoskeletal infections: systematic diagnostic assessment and key points. *Acad Radiol* 2012;19(11):1434–43.
- [11] Anderson SW, Lucey BC, Rhea JT, Soto JA. 64 MDCT in multiple trauma patients: imaging manifestations and clinical implications of active extravasation. *Emerg Radiol* 2007;14(3):151–9.

-
- [12] Fayad LM, Carrino JA, Fishman EK. Musculoskeletal infection: role of CT in the emergency department. *Radiographics* 2007;27(6):1723–36.
- [13] Gawkrödger DJ, Ardern-Jones MR. *Dermatology: an illustrated colour text [still image]*. Edinburgh; New York: Churchill Livingstone/Elsevier; 2016.
- [14] Yano K, Hosokawa K, Nakai K, Kubo T, Matsuo Y. Regional differences in ultrasonic assessment of subcutaneous fat thickness in the abdomen: effects on the TRAM flap. *Ann Plast Surg* 2003;51(2):130–5.
- [15] Lancerotto L, Stecco C, Macchi V, Porzionato A, Stecco A, De Caro R. Layers of the abdominal wall: anatomical investigation of subcutaneous tissue and superficial fascia. *Surg Radiol Anat* 2011;33(10):835–42.
- [16] Stecco C, Macchi V, Porzionato A, Duparc F, De Caro R. The fascia: the forgotten structure. *Ital J Anat Embryol* 2011;116(3):127–38.
- [17] Schmid MR, Kossmann T, Diewell S. Differentiation of necrotizing fasciitis and cellulitis using MR imaging. *AJR Am J Roentgenol* 1998;170(3):615–20.
- [18] Rowan MP, Cancio LC, Elster EA, Burmeister DM, Rose LF, Natesan S, et al. Burn wound healing and treatment: review and advancements. *Crit Care* 2015;19:243.
- [19] Matalon SA, Askari R, Gates JD, Patel K, Sodickson AD, Khurana B. Don't forget the abdominal wall: imaging spectrum of abdominal wall injuries after nonpenetrating trauma. *Radiographics* 2017;37(4):1218–35.