

Inflammation and infection

Purple urine bag syndrome, a disturbing urine discoloration

Omar Karray^{a,d,*}, Rym Batti^{b,d}, Emna Talbi^{c,d}, Haroun Ayed^{a,d}, Marouene Chakroun^{a,d},
Mouna Ayadi Ouarda^{b,d}, Abderrazek Bouzouita^{a,d}, Mohamed Cherif^{a,d},
Mohamed Riadh Ben Slama^{a,d}, Mezlini Amel^{b,d}, Jouida Abdelmoula^{c,d}, Amine Derouiche^{a,d},
Mohamed Chebil^{a,d}

^a Urology Department, Charles Nicolle Hospital, Tunis, Tunisia

^b Oncology Department, Salah Azaiez Institute, Tunis, Tunisia

^c Biochemistry Department, Charles Nicolle Hospital, Tunis, Tunisia

^d Faculty of Medicine, Tunis El Manar University, Tunis, Tunisia



Introduction

Purple urine bag syndrome (PUBS) is a rare and disturbing situation for patient's relative and the care team. It's mainly observed in long term bedridden with an indwelling urinary catheter use patients. PUBS is usually harmless and asymptomatic, but it may lead to severe conditions with a considerable morbidity and mortality.

Authors report a case occurring in a 78 years old male patient, describing clinical and evolutive features, and discussing physiopathology and management of PUBS.

Case report

A 78 years old north african patient, with an history of hypertension, diabetes mellitus and a prostatic adenocarcinoma with vertebral metastasis, treated by triptorelin, consulted for a right back pain associated to a recent purple discoloration of the indwelling urine bag (Fig. 1). The patient was bedridden few weeks before hospitalization for a reduction of autonomy, with a permanent indwelling catheter. Temperature was at 38,5° Celsius. Conscience and hemodynamic state were stable. Acute pyelonephritis signs were concomittant to a purple discoloration of urine bag, three days before the emergency consult. Withe blood cells count was at 13500 elements/ml and platelet count at 220000 elements/ml. C-reactive protein was at 35 mg/l, and procalcitonin at 4 ng/ml. Abdominal ultrasound concluded to a densification of the peri-renal and pelviureteric fat. There weren't obstructive signs on the upper urinary tract or peri-renal collection in ultrasound. The patient got a probabilist antibiotherapy after bacteriological sampling of urine: cefotaxim 2 g, three times a day, and gentamycin 240 mg once a day. The indwelling catheter was changed, and the purple coloration disappeared. The urine were turbid in the bag. The indwelling Urine culture concluded to an *Escherichia Coli*, the count was at 15 5 elements/ml, the sensitivity to β -lactam and aminoglycoside antibiotics was confirmed in the antibiogram. A sediment appeared in the urine

tube few minutes after bacteriological sampling. A semi-quantitative spectrophotometric analysis of the sediment was performed. Ammonium urate acide and struvite were detected (Fig. 2).

Evolution was favourable during hospitalization. Back pain and fever disappeared in two days. Urine culture, after three days on treatment, was negative. The patient was discharged in the fifth day, he had cefixim for two weeks. Physical examination in the outpatient clinic was normal. Ultrasonographic abnormalities disappeared a month later.

Discussion

PUBS is a rarely reported situation, that's mostly seen in long term nursing institutions.

The oldest historical description of PUBS dates back to 1812. The first medical description of PUBS was 1978, by Barlow and Dickson.¹

The prevalence of PUBS is variable, depending on patients population and bacterial epidemiology. It has been evaluated around 10–15% of patients with long term indwelling catheter. It's important to mention that the urine itself isn't discolored. Urine bacteriological sampling is usually dark brown and turbid. The purple aspect concern urine contained in the catheter and its collecting bag.²

This discoloration is related to the combination of two pigments, indigo and indirubine, providing from the metabolism of tryptophan. Production of the pigments arises from the action of an enzyme, the indoxyl sulphatase, produced by a spectrum of bacteria like *Escherichia Coli* and *Klebsiella Pneumoniae*, upon the indoxyl sulphate. Pigments adhere to the catheter and the bag, and urine is discolored from red to blue to become purple. Urine may be differently discolored between the catheter and the urine bag.³

PUBS itself is not a severity sign, but it reflects bacteriuria. In some cases, PUBS may be associated to severe and life-threatening conditions related to comorbidities and long-term bed rest.

The same phenomenon may be observed in infants, known as Drummond Syndrome, or the blue diaper syndrome. It's secondary to a

* Corresponding author. Charles Nicolle Hospital, Boulevard 9 Avril 1938, Bab Saadoun, 1007 Tunis, Tunisia.
E-mail address: omar.karray.88@gmail.com (O. Karray).



Fig. 1. Purple discoloration of urine bag.

disorder in tryptophan intestinal absorption, which is eliminated and metabolised in urine, causing its discoloration.³

Risk factors are female gender, dementia, chronic constipation, chronic renal disease, alkaline urine, increased urine bacterial load and the use of polyvinyl chloride urine bags. PUBS is observed in permanent urinary catheterization, either urethral or supra-pubic.²

Dementia is the most related to recurrence of PUBS. Female gender exposes to PUBS as the urethra is shorter, closer to the anus and more exposed to bacterial infections than in men. Intestinal hypo-motility in chronic constipated patients leads to bacterial overgrowth with an increase in tryptophan metabolism. PUBS is more reported in chronic kidney disease, as indoxyl sulphate is bound to albumin with a limited removal during dialysis and an increase of its serum concentration. Alkaline urine facilitates pigment precipitation in the synthetic materials of the urine catheter and bag, even though some reports described PUBS in acidic urines.²

Spectrophotometry was performed only in the case reported by Ficher et al. They found indigo pigment in the urine sediment.⁴ Antibiotherapy is not systematic once PUBS is observed, it depends on the presence of septic signs. PUBS may disappear once the indwelling catheter is changed. Intensive antibiotherapy is necessary once PUBS is associated to a severe urinary infection. In some reports, PUBS was associated to a scrotal gangrene and to a septic shock, justifying a thorough follow-up once PUBS is diagnosed.^{4,5}

There aren't consensual guidelines about PUBS. It's managed on a case-by-case basis. An early diagnosis and management avoids invasive explorations without particular findings, such as cystoscopy. Prevention includes appropriate indications of urine drainage, and avoidance of unnecessary ones, the catheter care, the use of silver impregnated Foley catheter, that reduce bacterial culture and growth, and therefore PUBS. Constipation treatment may also reduce the incidence and the recurrence of PUBS in risk population.

Conclusion

Despite its benign appearance and physiopathologie, PUBS is still a disturbing little-known condition for health-care team and patient's relatives. A knowledge of risk factors and metabolic mechanisms is required by geriatricians, urologists and emergency doctors in order to plan an adequate management. Association to comorbidities may lead PUBS to a life-threatening septic condition, justifying a watchful surveillance. Once prevented and correctly managed, PUBS is usually resolutive uneventfully.

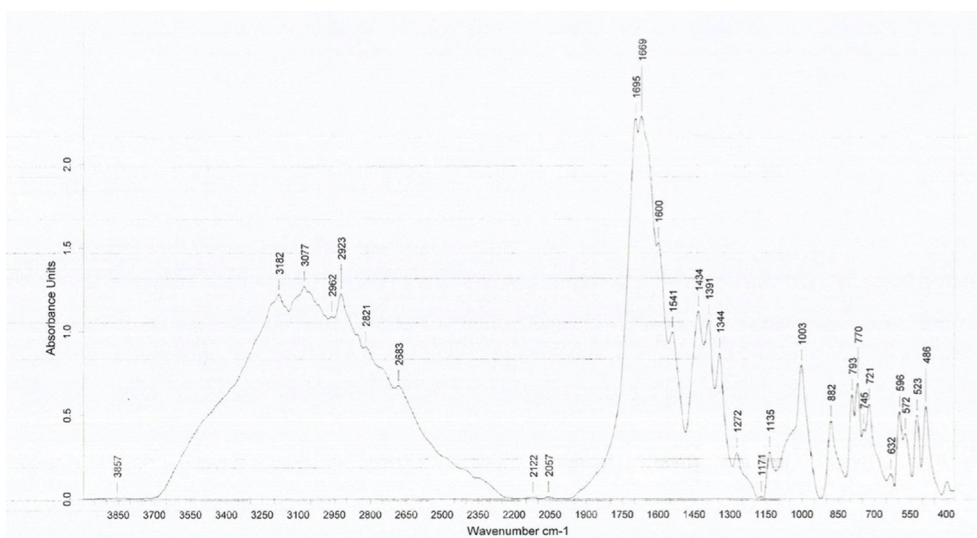


Fig. 2. Spectrophotometry: presence of ammonium urate acid and struvite.

References

1. Barlow G, Dickson J. Purple urine bags. *Lancet*. 1978;28:220–221.
2. Peters P, Merlo J, Beech N, et al. The purple urine bag syndrome: a visually striking side effect of highly alkaline urinary tract infection. *Can Urol Assoc J*. 2011;5:233.
3. Gautam G, Kothari A, Kumar R, Dogra PN. Purple urine bag syndrome: a rare clinical entity in patients with long term ind- welling catheters. *Int Urol Nephrol*. 2007;39:155–156.
4. Ficher K, Araújo A, Houly S, Lins P, Silva Jr M, Góis A. Purple urine bag syndrome: case report for *Streptococcus agalactiae* and literature review. *J. Bras. Nefrol*. 2016;38(4).
5. Tasi YM, Huang MS, Yang CJ, Yeh SM, Liu CC. Purple urine bag syndrome, not always a benign process. *Am J Emerg Med*. 2009;27(7):895–897.