

Received: 2020.09.14

Accepted: 2020.12.15

Available online: 2020.12.27

Published: 2021.02.08

Rib Osteoblastoma as a Cause of Neurogenic Thoracic Outlet Syndrome: A Case Report

Authors' Contribution:

Study Design A
Data Collection B
Statistical Analysis C
Data Interpretation D
Manuscript Preparation E
Literature Search F
Funds Collection G

ABDEF 1 **Shadi Hamouri**
ADF 2 **Mohammad AlQudah**
ADF 1 **Nabil Al-zoubi**
EF 3 **Wisam Al Gargaz**
BF 1 **Hamza Jarboa'**
EF 4 **Erich Hecker**

1 Department of General Surgery and Urology, Jordan University of Science and Technology, Irbid, Jordan
2 Department of Pathology and Microbiology, Jordan University of Science and Technology, Irbid, Jordan
3 Department of Special Surgery, Jordan University of Science and Technology, Irbid, Jordan
4 Department of Thoracic Surgery, Ruhr District Thoracic Center in Herne, University of Duisburg-Essen Academic Teaching Hospital, Herne, Germany

Corresponding Author: Shadi Hamouri, e-mail: smhamouri@just.edu.jo**Conflict of interest:** None declared

Patient: Female, 23-year-old
Final Diagnosis: Thoracic outlet syndrome
Symptoms: Cervical mass • pain • paresthesia
Medication: —
Clinical Procedure: CT scan • incisional biopsy • MRI • nerve conduction study • supraclavicular approach to the TOS
Specialty: Surgery

Objective: Rare disease**Background:** Osteoblastoma is a very rare bone tumor accounting for 1% of all bone tumors. Most of the time it involves the spine and long bones and it involves the ribs very rarely. While osteoblastoma occurrence in the first rib has been reported, causing neurogenic thoracic outlet syndrome (TOS) has never been reported.**Case Report:** A 23-year-old woman presented with a left cervical mass associated with pain and paresthesia in the medial aspect of the left upper extremity and 4th and 5th fingers for the previous 3 months. The patient denied any previous illness or trauma in her history. Physical examination revealed a hard mass in the posterior triangle of the left neck with altered sensation in the left 4th and 5th fingers. The patient was investigated by a chest roentgenogram, nerve conduction study, computer tomography (CT) of the chest, and magnetic resonance image (MRI), as well as incisional biopsy. Although all radiological investigations were suggesting osteochondroma with a differential diagnosis of chondrosarcoma, the incisional biopsy showed osteoblastoma. Radical surgical excision of the lesion followed through a left supraclavicular approach. The patient's preoperative symptoms were relieved completely and there was no recurrence of the tumor at 2 years.**Conclusions:** Osteoblastoma of the first rib is very rare tumor and to present with TOS is extremely rare. The nonspecific radiological characteristics of the tumor, especially on CT, makes the preoperative certainty of the diagnosis unlikely.**Keywords:** Osteoblastoma • Ribs • Thoracic Outlet Syndrome**Full-text PDF:** <https://www.amjcaserep.com/abstract/index/idArt/928548>

1253



—



3



8



Background

Osteoblastoma is a very rare bone tumor accounting for 1% of all bone tumors [1]. Most of the time it involves the spine and long bones [2] and it involves the ribs very rarely [1]. They were initially reported by Lichtenstein in the 1950s as “osteogenic fibromas of bone” [3] and after that this type of tumors was reported in the literature. Here, we describe a left first rib osteoblastoma that presented as neurogenic thoracic outlet syndrome. While osteoblastoma occurrence in the first rib has been reported, causing neurogenic thoracic outlet syndrome (TOS) has never been reported.

Case Report

A 23-year-old female patient presented with left cervical mass associated with pain and paresthesia in the medial aspect of the left upper extremity and 4th and 5th fingers for the previous 3 months. The patient reported previous attacks of intermittent, dull, achy pain and numbness in the left 4th and 5th fingers during the last 5 years. These were treated with non-steroidal anti-inflammatory analgesics, with partial response, but the symptoms increased in severity and became persistent during the previous 3 months. The patient denied any previous illness or trauma in her history.

Physical examination revealed a hard mass in the posterior triangle of the left neck with altered sensation in the left 4th and 5th fingers. The patient’s symptoms could be imitated by an abduction and external rotation of the left arm. There was no difference in the measured blood pressure in both upper limbs or in the palpated radial and brachial pulses. All the studied hematologic and biochemical laboratory investigations, including alkaline phosphatase, were within the normal limits. A chest roentgenogram showed a radiopaque mass in the upper left hemithorax. Moreover, a nerve conduction study was performed and showed a nerve conduction velocity below 60 m/s in the lower brachial plexus trunk (normally >85 m/s).

A computer tomography (CT) scan of the chest revealed a well-defined exophytic bony lesion with osseous matrix seen arising from the left first rib, measuring about 3.8×3.2×4.9 cm associated with a surrounding soft tissue component. This mass lesion was extending up toward the lower neck and mildly compressing the left subclavian artery (Figure 1A, 1B). The provisional diagnosis included osteochondroma (exostosis), with a differential diagnosis of chondrosarcoma. For further assessment, magnetic resonance imaging was performed and revealed findings that suggestive of osteochondroma (Figure 2). Due to the uncertainty of the diagnosis, an incisional biopsy was performed, showing osteoblastoma. Radical surgical excision of the lesion followed through a left supraclavicular approach. The early postoperative

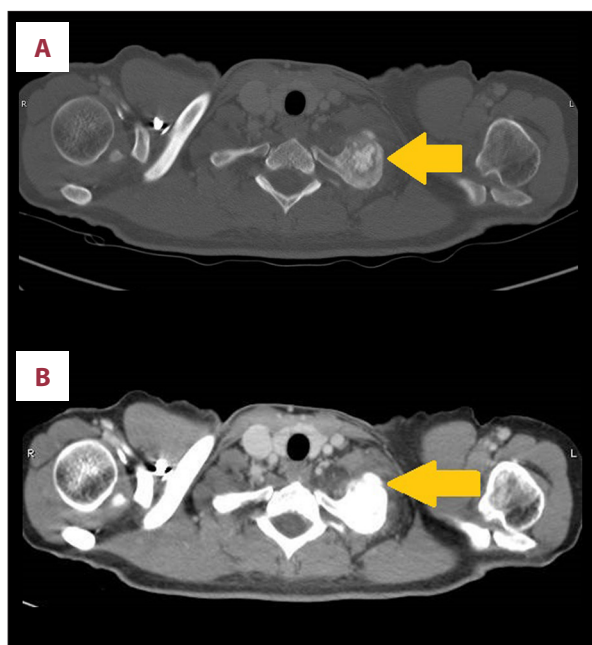


Figure 1. (A, B) CT scan of the chest showing a well-defined exophytic bony lesion with osseous matrix arising from the left first rib (arrows).

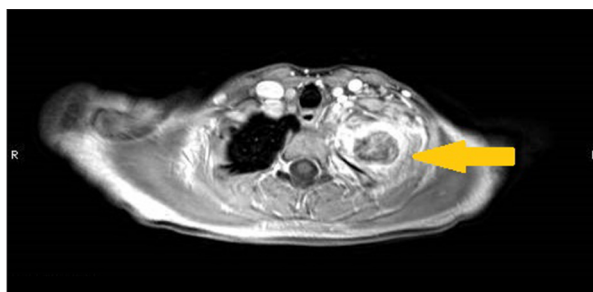


Figure 2. MRI of the chest showing a heterogeneously enhancing lesion with areas of sclerosis involving and expanding the first left rib and associated with a large enhancing soft tissue component (arrow).

course was uneventful, and the patient was discharged home after drain removal on the third postoperative day. Three weeks later, the patient presented with a discharging sinus at the edge of the surgical incision surrounded by minimal redness of the surrounding skin. The neck ultrasound showed around 2×3 cm deep collection at the surgical site. Due to absence of pain, fever, or leukocytosis, watchful waiting treatment was elected. After 1 week, a small piece of the bone wax used in the procedure extruded and the above-mentioned collection drained spontaneously through the sinus. The wound and the sinus had healed completely by 6 weeks postoperatively.

The histological examination grossly revealed a white-grayish hard lesion with rounded contour. The microscopic examination showed a well-circumscribed benign-looking bone forming

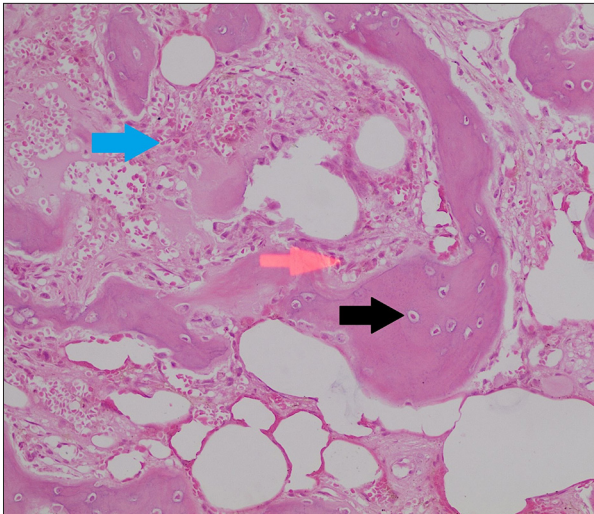


Figure 3. Microscopic examination (H&E stain with 20× magnification) shows bone forming lesion composed of anastomosing irregular trabeculae (black arrow) with multiple foci of sclerotic nidus. The trabeculae are lined by a single layer of osteoblasts (red arrow) with intervening loose fibrovascular stroma (blue arrow). No evidence for cellular atypia, abnormal mitotic figures, or necrosis.

a lesion composed of anastomosing irregular trabeculae with multiple foci of sclerotic nidus. The trabeculae were lined by a single layer of osteoblasts with intervening loose fibrovascular stroma (Figure 3). There was no evidence of mitosis or necrosis. The margins of the excised part of the first rib showed benign mature trabecular bone.

The patient's preoperative symptoms were relieved completely and there was no recurrence of the tumor at 2 years. We are planning to follow her up clinically and radiographically.

Discussion

Osteoblastoma is a rare osteoblastic benign bone tumor that most frequently affects the vertebral column, long bones, and sacrum, but it can involve virtually any bone in the body. It accounts for 1% of all bone tumors and 3% of all benign bone tumors [1,2]. The peak incidence of osteoblastoma is in the second decade of life. There are no data about the sex distribution of rib osteoblastoma, but other sites of occurrence such as the vertebral column have a male predominance [2].

TOS is a disorder that arises from the compression of 1 or more of the neurovascular structures that traverse the superior aperture of the chest. Neurogenic TOS accounts for most cases, occurring in around 90% of patients presenting for an evaluation. There are multiple potential causes of TOS, including but not

limited to anatomical, congenital, adventitious fibrous bands, trauma, and atherosclerosis [4]. Osteoid osteoma has been reported as a cause of TOS [5] and a recurring osteoblastoma has been reported in the first rib tumor without TOS [6]. Our case is the first reported case of osteoblastoma as a cause of TOS.

Osteoblastoma of the rib typically presents with progressive dull pain, limited to the tumor site. Sometimes it gets worse at night and is not relieved with salicylates, as occurs with osteoid osteomas. The affected bone might be grown and appear as a palpable tender swelling. Infrequently it can be asymptomatic [7].

Radiographic features of osteoblastoma of the rib have not been well reported owing to the rarity of the disease. It can occur in an intramedullary, intracortical, or periosteal location, so the radiological appearance is not specific [8]. The variability in the radiological findings expands the differential diagnosis of the lesion to include benign as well as malignant bone tumors. As a result of the nonspecific radiological findings in our case, osteochondroma and chondrosarcoma were the main differential diagnoses.

Ye et al [8] described 3 patterns of the lesions that can be illustrated in the CT or the MRI:

- Tumors >2 cm in diameter with extra remarkable periosteal reaction.
- Tumors with extremely expansile behavior, like an aneurysmal bone cyst, and multiple central small calcifications, and a thin shell of peripheral periosteal bone, along with a well-defined margin.
- A more aggressive type with bone expansion and destruction, adjacent soft tissue permeation, and intermingled matrix calcification.

Moreover, the CT and MRI can illustrate the exact size, shape, and relation to adjacent structures and provide a road map for surgical therapy.

Pathologically, the average size of an osteoblastoma is 3-4 cm; they tend to be expansive lesions, and have a central, richly vascular, friable nidus. The peripheral region of this nidus contains reactive bone, and usually varies from sclerotic to thin. Components of aneurysmal bone cysts are reported to be present in approximately 10-15% of cases of osteoblastomas [2]. Figure 3 illustrates the histological features of our case.

The recurrence rate of osteoblastoma of the ribs is difficult to determine due to the rarity of cases. Although the overall recurrence rate of osteoblastoma in general has been reported to be around 10% after resection of the conventional cases, the recurrence in the aggressive form of the disease is around 50% of the cases. The usual time of appearance of the recurrent disease is 5-10 years after resection [2]. Accordingly, long-term follow-up is advisable, even after complete surgical resection.

Conclusions

Osteoblastoma of the first rib is very rare tumor and to present with TOS is extremely rare. The nonspecific radiological characteristics of the tumor, especially on the CT, makes the pre-operative certainty of the diagnosis unlikely. Radical surgical treatment of the lesion is the standard treatment of choice to prevent local destruction and to decrease the risk of recurrence.

References:

1. Arkader A, Dormans JP. Osteoblastoma in the skeletally immature. *J Pediatr Orthop*, 2008;28:555-60
2. Galgano MA, Goulart CR, Iwenofu H, et al. Osteoblastomas of the spine: A comprehensive review. *Neurosurg Focus*, 2016;41:E4
3. Lichtenstein L. Benign osteoblastoma; A category of osteoid-and bone-forming tumors other than classical osteoid osteoma, which may be mistaken for giant-cell tumor or osteogenic sarcoma. *Cancer*, 1956;9:1044-52
4. Donahue DM, Osho A. Thoracic outlet syndrome. In: LoCicero J, Feins RH, Colson YL et al (eds.), *Shields' general thoracic surgery*. 8th ed. Philadelphia, Wolters Kluwer, 2019;619-28
5. Kargar S, Arefanian S, Ghasemi A, et al. Osteoid osteoma of the rib presenting as thoracic outlet syndrome. *Ann Thorac Surg*, 2013;96:2221-23
6. Taghipour Zahir S, Sefidrokh Sharahjin N, Kargar S. A rare case of rib osteoblastoma: Imaging features and review of literature. *Iran J Radiol*, 2013;10:152-55
7. Katsenos S, Archondakis S, Sakellaridis T. Osteoblastoma of the rib: A rare benign tumor with an unusual location. *Int J Surg Case Rep*, 2013;4:146-48
8. Ye J, Liu L, Wu J, Wang S. Osteoblastoma of the rib with CT and MR imaging: A case report and literature review. *World J Surg Oncol*, 2012;10:49

Conflict of Interest

None.