

A case of probable esomeprazole-induced transient liver injury in a pregnant woman with hyperemesis

Binny Thomas¹⁻³
Mahmoud Mohamed^{1,3,4}
Moza Al Hail¹⁻³
Fatma Alzahra Y Awwad¹
Ramy M Wahba¹
Sabir B Hassan¹
Khalid Omar¹
Wessam El Kassem¹
Palivalappila Abdul Rouf¹

¹Hamad Medical Corporation, Doha, Qatar; ²Robert Gordon University, Aberdeen, Scotland, UK; ³Qatar University, Doha, ⁴Weill Cornell Medical College, Ar-Rayyan, Qatar

Abstract: We report a case of 22-year-old primigravida presented to Women's Hospital – Hamad Medical Corporation emergency with severe epigastric pain, nausea, and vomiting. On admission, she was dehydrated with remarkably worsening symptoms. Laboratory findings revealed significantly elevated liver enzymes with unknown etiology. Her past medical history showed an admission for nausea and vomiting 3 weeks previously and she was discharged on antiemetics, and esomeprazole for the first time. Due to the predominantly elevated liver enzymes, the clinical pharmacist discussed the possibility of esomeprazole-induced adverse effects and suggested to suspend esomeprazole based on the evidence from literature review. The liver enzymes showed a substantial improvement within days after the discontinuation of the drug; however, a rechallenge was not done since it could have adversely affected the mother or the fetus. Using the Naranjo Adverse Drug Reaction Probability scales, the adverse reaction due to esomeprazole was classified as “probably”.

Keywords: hyperemesis, drug-induced liver injury, esomeprazole, adverse drug reaction, ADR, proton pump inhibitor

Introduction

Drug-induced hepatic toxicity is one of the most common causes of liver injury, accounting for almost one-half of all the liver failure and mimics all forms of liver disease. Approximately >1000 medications have been reported to cause liver disease at least one time. However, majority of these liver diseases subside after suspension of the drug, while very few of them have been reported to cause a permanent harm. The majority of drug-induced hepatic adverse events are unpredictable and are either immune-mediated hypersensitivity reactions or idiosyncratic.^{1,2}

Esomeprazole is an S-isomer of omeprazole and is generally considered safe and effective to treat acid suppression during pregnancy.³⁻⁵ However, US Food and Drug Administration classified it as Category C, which explains that animal reproduction studies have shown an adverse effect on the fetus and there are no adequate and well-controlled studies on humans, but potential benefits may warrant use of the drug in pregnant women despite potential risks.⁶

We report a case of probable esomeprazole-induced transient liver injury (elevated liver transaminases, i.e., alanine transaminase [ALT] and aspartate transaminase [AST]) in a pregnant woman which resolved after discontinuation of the suspected drug. A literature search of standard databases (MEDLINE, Embase, and Cumulative Index to Nursing and Allied Health Literature) conducted in September 2015 did not identify any similar reports in pregnant population.

Correspondence: Binny Thomas
Department of Pharmacy Women's
Hospital – Hamad Medical Corporation,
PO Box 3050, Doha, Qatar
Tel +974 66 010 620
Email binnyinhmc@gmail.com

Impact on practice

Health professionals treating hyperemesis gravidarum or gastric refluxes should be aware of potential esomeprazole-induced liver toxicities.

Liver enzyme levels should be carefully monitored while prescribing esomeprazole to a pregnant woman.

Case presentation

No informed consent was required from the patient to publish this report due to its anonymous nature. This waiver of informed consent and all approvals to publish and present this case was obtained from the Medical Research Centre at Hamad Medical Corporation (HMC).

A 22-year-old primigravida in her first trimester presented to Women’s Hospital – HMC emergency with acute epigastric pain, nausea, and nonbilious vomiting more than four times in last 24 hours. Her past medical history revealed that 3 weeks previously (considered as Day 0 in Figure 1), she was admitted to the hospital and was diagnosed as hyperemesis gravidarum and was later discharged on pyridoxine, metoclopramide, and esomeprazole. The patient had no known diagnosis of liver injury/disease prior to the onset of this illness and denied history of any recreational drug use,

nonprescription, or use of herbal supplements. Prior to current admission (Day 1), she was taking esomeprazole 40 mg twice daily, metoclopramide suppositories 20 mg twice daily, and pyridoxine 40 mg orally once daily and had no history of drug allergies or other adverse drug reactions.

At this time, the patient continued to complain of significant nausea, vomiting, poor appetite, significant weight loss, and darkish yellow urine. On examination, she was dehydrated, no signs of ascites or edema, impalpable spleen; however, severe tenderness was observed in the epigastric area. Laboratory investigation revealed significantly elevated ALT (267 Units/L) and AST (137 Units/L; Figure 1). HIV testing was negative. A deferential diagnosis was made as Mallory–Weiss tear (diagnosed clinically) and hyperemesis gravidarum versus viral/autoimmune liver disease or drug-induced liver injury (DILI). Viral hepatitis screening test and other tests including anti-smooth muscle antibody, antimitochondria antibody, antinuclear antibody, and antiliver kidney microsomal antibodies were done.

This reaction (elevated liver enzymes) was identified by the clinical pharmacist who discussed the possibility of an esomeprazole-induced adverse effect. The outcome of the discussion resulted in discontinuing esomeprazole (Day 5) and replacing it with oral pantoprazole 40 mg twice daily.

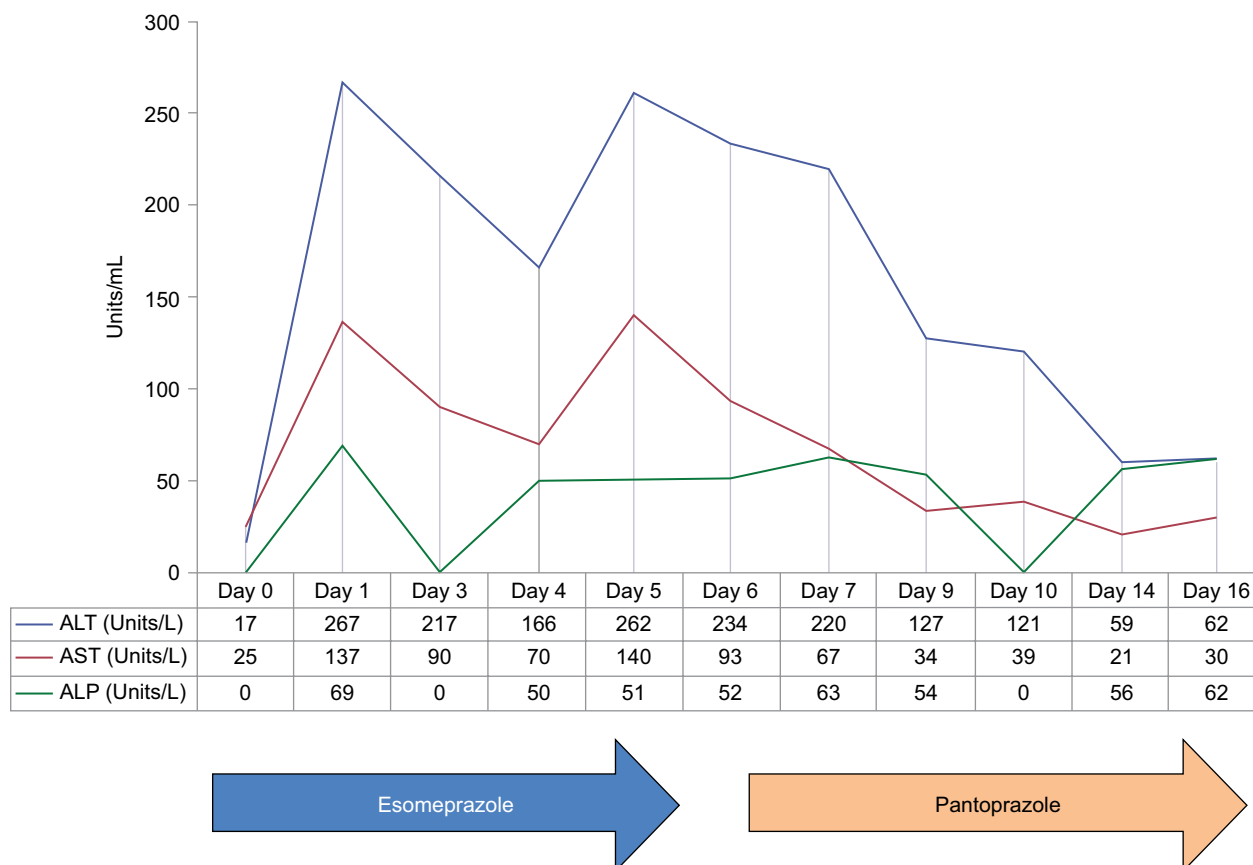


Figure 1 Elevated liver enzymes with esomeprazole.

Abbreviations: ALT, alanine transaminase; AST, aspartate transaminase; ALP, alkaline phosphatase.

This change in therapy had almost immediate impact, with liver enzymes having dropped predominantly in successive days, without any other intervention. Approximately 3 days (Day 7) after stopping esomeprazole, subsequent laboratory reports demonstrated that patient's AST, ALT, and alkaline phosphatase were significantly reduced. The patient reported a substantial improvement in her activity levels with resolution of nausea and vomiting and epigastric pain, and she was discharged on Day 10. On discharge, she was prescribed with pantoprazole 40 mg and metoclopramide suppositories 20 mg and was asked to follow-up after a week. During her subsequent follow-up visit on Day 16, the liver functions were found to be normal.

Using the Naranjo Adverse Drug Reaction Probability scales, a score of 6 was obtained indicating a "probable" adverse reaction due to esomeprazole. The patient was instructed never to rechallenge herself with esomeprazole and instructed to report it as a medication adverse reaction in the future.

Discussion

To our knowledge, this is the first published report of oral esomeprazole-induced liver injury in a pregnant patient. While the pathophysiology of DILI is poorly understood, some of the possible mechanisms for drug-induced hepatotoxicity include 1) impaired intracellular calcium hemostasis, leading to disassembly of actin fibrils and resulting in bulging of cell membrane to cause rupture and cell lysis; 2) Drug-induced hepatotoxicity is also caused due to loss of villous processes and the disruption of transport pumps, for example, MRP3 that prevents the excretion of bilirubin and other organic compounds; 3) Sometimes due to stimulation of apoptotic pathways by tumor necrosis factor alpha (TNF- α), receptor or Fas may trigger the cascade of intercellular caspases. Certain drugs are known to cause mitochondrial dysfunction by reducing the ATP production and disturbing the respiratory chain enzyme and hence causing hepatic toxicity. DILI is known as the most common cause of liver injury and main cause of drug withdrawal. It is known that >50% of all acute liver failures and ~10% of all acute hepatitis cases are due to drugs.^{2,7,8} There are two main types of hepatic toxicity, one is the immune response to the drug trigger and the other is direct action of the drug itself. Esomeprazole induces drug injury and is more of a direct toxicity because when the drug is withdrawn, the pathologic findings were resolved. Authors have also assumed the role of immune system in the current case because of the delayed nature of the reaction and resolution. Although, direct destruction of liver epithelium by drugs has been reported previously with

acetaminophen, it might also occur in other medications. This type of injury may result in altered salt homeostasis, mitochondrial dysfunction, and cell death. Rechallenge here is not recommended since a recurrent injury may be more severe than the first episode and might adversely affect the fetus too.

A search on UK MHRA and MedEffect Canada and a literature review of standard databases (MEDLINE, Embase, and Cumulative Index to Nursing and Allied Health Literature) conducted in September 2015 did not identify any similar reports in pregnant women. Rare but previously reported esomeprazole-induced liver injury has occurred in male population or with other underlining conditions; however, no such reports were reported in pregnant population till date.

Capitain et al⁹ reported liver toxicity in a patient receiving chemotherapy, for breast cancer, after single administration of esomeprazole. Upon withdrawal of esomeprazole, liver enzymes returned to normal even after the continuation of the chemotherapy. In another two studies, omeprazole was the main cause of DILI reported.^{10,11} A similar case of transient hepatic injury that resolved soon after esomeprazole was discontinued following a negative work up against viral infection or autoimmune disease, the dose-dependent elevation of ALT and AST, and return of liver enzymes to normal after switching to another proton pump inhibitor (PPI) (omeprazole) was also reported.

Esomeprazole is the S-isomer of omeprazole. Both esomeprazole and pantoprazole are metabolized through CYP 450 enzymes, and they are known enzyme inhibitors for their own metabolism. Therefore, higher areas under the curve (AUC) are attained with continuous use. Once metabolized, hydroxy, 5-O-desmethyl, and sulfone metabolites are formed. However, the formation of hydroxy metabolite is slower, and the formation of the other two metabolites is more rapid in esomeprazole compared to pantoprazole.¹² Hence, the formation of metabolites might explain the toxic effect on the liver and support the direct liver injury over immune reaction. Pantoprazole has not shown a similar metabolism and does not inhibit its metabolism. The diversity in metabolic pathways may explain in part the different consequence on liver functions between PPIs.^{12,13}

Conclusion

A case of probable esomeprazole-induced transient liver injury in pregnant women was reported. It is important for health care professionals to be aware of this rare but significantly harm producing event in pregnancy. This case has been reported to Medication Safety Office and Drug Information services – Women's Hospital Medication safety office and

Drug Information services. Authors recommend that future cases of suspected esomeprazole-induced hepatotoxicity should be reported and efforts to delineate the mechanism of injury should be undertaken.

Acknowledgments

Authors would like to acknowledge GI team, Hamad Medical Corporation for their valuable clinical decisions and Dr Thaslim Abdul Rahman, Robert Gordon University, UK, for his assistance in the case report. Authors would further like to thank Dr Doua Al Saad for her contribution to the case report.

Author contributions

All authors contributed toward data analysis, drafting and critically revising the paper and agree to be accountable for all aspects of the work. BT is a Doctoral (PhD) Researcher from RGU, UK, and Clinical Pharmacy Specialist at HMC and was involved in manuscript writing and literature review. MGM is a senior researcher at Weil Cornell Medical College, Qatar, and Clinical Pharmacist at HMC, he intervened in the case and was involved in manuscript writing. WEK is the medication safety officer at HMC and was involved in the Naranjo Scale Evaluation, data analysis and revision of manuscript. MAH and PAR are senior administrators at HMC and were involved in writing the initial proposal, rewriting and editing manuscript. RMW, SBH, and KO are obstetric physicians whose contributions were vital in the clinical interventions made, and writing up for the discussion and reviewing the histological and other laboratory interpretation.

Disclosure

The authors report no conflicts of interest in this work.

References

- Zimmerman HJ. *Hepatotoxicity: The Adverse Effects of Drugs and Other Chemicals on the Liver*. Philadelphia: Lippincott Williams & Wilkins; 1999.
- Kaplowitz N. Drug-induced liver disorders. *Drug Safety*. 2001;24(7):483–490.
- Spencer CM, Faulds D. Esomeprazole. *Drugs*. 2000;60(2):321–329; discussion 330–1.
- Davies M, Wilton LV, Shakir SA. Safety profile of esomeprazole. *Drug Safety*. 2008;31(4):313–323.
- Majithia R, Johnson DA. Are proton pump inhibitors safe during pregnancy and lactation? *Drugs*. 2012;72(2):171–179.
- The U.S. Food and Drug Administration [homepage on the Internet]. *Nexium (Esomeprazole Magnesium)*. 2015. Available from: <http://www.fda.gov/NewsEvents/Newsroom/PressAnnouncements/ucm431648.htm>. Accessed September 28, 2015.
- Fontana RJ, Hayashi PH, Gu J, et al. Idiosyncratic drug-induced liver injury is associated with substantial morbidity and mortality within 6 months from onset. *Gastroenterology*. 2014;147(1):96.e–108.e.
- Lee WM. Drug-induced hepatotoxicity. *N Engl J Med*. 2003;349(5):474–485.
- Capitain O, Lortholary A, Abadie-Lacourtois S. Cytolytic hepatitis and esomeprazole during chemotherapy. *Presse Med*. 2005;34(17):1235–1236.
- Koury S, Stone C, La Charite D. Omeprazole and the development of acute hepatitis. *Eur J Emerg Med*. 1998;5(4):467–470.
- Sugano K, Kinoshita Y, Miwa H, Takeuchi T, Esomeprazole NSAID Preventive Study Group. Safety and efficacy of long-term esomeprazole 20 mg in Japanese patients with a history of peptic ulcer receiving daily non-steroidal anti-inflammatory drugs. *BMC Gastroenterol*. 2013;13:54.
- Andersson T, Hassan-Alin M, Hasselgren G, Röhs K, Weidolf L. Pharmacokinetic studies with esomeprazole, the (S)-isomer of omeprazole. *Clin Pharmacokinet*. 2001;40(6):411–426.
- Romero-Gomez M, Otero M, Suarez-Garcia E, Diaz EG, Fobelo M, Castro-Fernandez M. Acute hepatitis related to omeprazole. *Am J Gastroenterol*. 1999;94(4):1119–1120.

Clinical Pharmacology: Advances and Applications

Publish your work in this journal

Clinical Pharmacology: Advances and Applications is an international, peer-reviewed, open access journal publishing original research, reports, reviews and commentaries on all areas of drug experience in humans. The manuscript management system is completely online and includes a very quick and fair peer-review system, which is all easy to use.

Submit your manuscript here: <https://www.dovepress.com/clinical-pharmacology-advances-and-applications-journal>

Dovepress

Visit <http://www.dovepress.com/testimonials.php> to read real quotes from published authors.