

## Oncology

## Development of CNS-type Primitive Neuroectodermal Tumor in Metastatic Testicular Mixed Germ Cell Tumor

Anobel Y. Odisho<sup>a,b</sup>, Joseph T. Rabban<sup>c</sup>, Maxwell V. Meng<sup>a,\*</sup><sup>a</sup> Department of Urology, Helen Diller Family Comprehensive Cancer Center, University of California, San Francisco, USA<sup>b</sup> Department of Urology, University of Washington, USA<sup>c</sup> Department of Pathology, University of California, San Francisco, USA

## ARTICLE INFO

## Article history:

Received 11 January 2016

Accepted 20 January 2016

## Keywords:

Testicular cancer

Retroperitoneal lymph node dissection

Germ cell tumor

Teratoma

## ABSTRACT

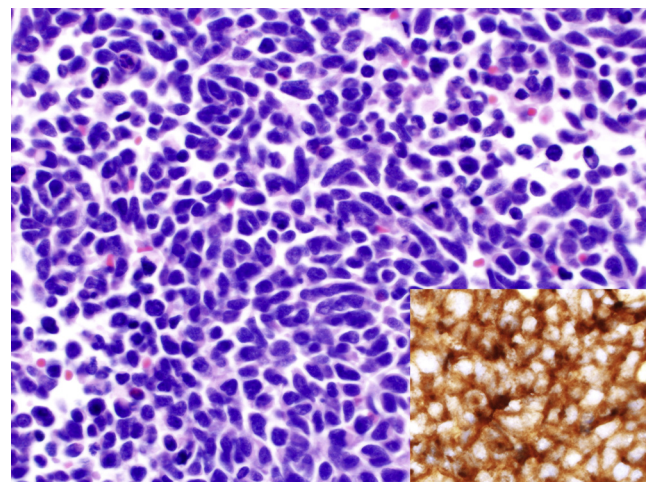
A 29-year-old man presenting with a retroperitoneal mass was found to have a testis lesion consistent with mixed germ cell tumor and the RPLND specimen showed teratoma with an area of central nervous system-type primitive neuroectodermal tumor (PNET) not present in the testis. Whether such primitive tumor components represent a de novo tumor component or represent progression from existing neuroepithelial teratomatous elements is unclear. Given the high likelihood of residual tumor and possibility of malignant transformation, post-chemotherapy RPLND remains vital in treating patients with testis cancer. PNET is chemo-resistant and lesions should be resected, without clear evidence for adjuvant chemotherapy.

© 2016 The Authors. Published by Elsevier Inc. This is an open access article under the CC BY-NC-ND license (<http://creativecommons.org/licenses/by-nc-nd/4.0/>).

## Case presentation

A previously healthy 29-year-old man presented with intermittent right lower quadrant and flank pain. On computed tomography (CT) he was found to have a right-sided retroperitoneal mass measuring  $13 \times 11 \times 7$  cm, encasing the aorta, compressing the inferior vena cava and right ureter, and causing moderate hydronephrosis (Fig. 1). Testis tumor markers were significant for  $\alpha$ -fetoprotein (AFP) of 1960 ug/l, lactate dehydrogenase (LDH) of 863 U/l, and  $\beta$ -human chorionic gonadotropin (hCG) of less than 0.5 IU/l. Scrotal ultrasound revealed two small discrete adjacent right intratesticular lesions,  $12 \times 9 \times 11$  mm and  $9 \times 6 \times 6$  mm with a normal contralateral testis. Pathologic examination of the orchiectomy revealed a 2 cm mixed germ cell tumor (50% seminoma, classic type and 50% teratoma without immature elements) that was partially necrotic and surrounded by organizing granulation tissue and scar. The tumor did not extend beyond the testicular parenchyma and did not involve lymphovascular spaces or the cord margin. Post-operative markers remained elevated (AFP 2433, LDH 656, hCG <0.5). As IGCCCG intermediate-risk (T1N3M0S2) he underwent 3 cycles of bleomycin, etoposide, and cisplatin and after

developing a dry cough, his fourth cycle was limited to etoposide and cisplatin. His tumor markers normalized and he underwent a retroperitoneal lymph node dissection (RPLND). Pathology revealed an 8 cm metastasis composed of teratoma and seminoma plus a

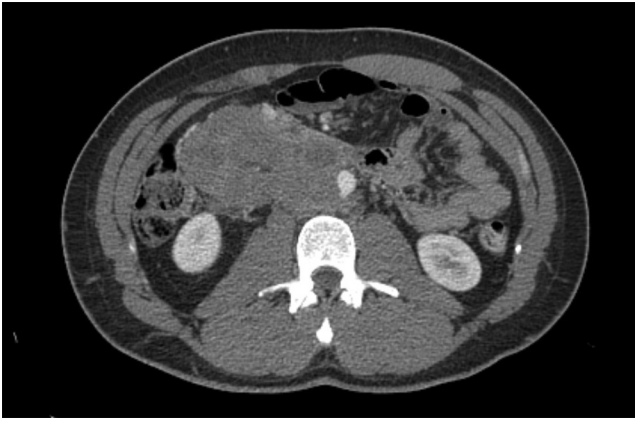

**Figure 1.** Primitive neuroectodermal tumor cells formed a 2 cm mass within the 8 cm retroperitoneal metastasis composed of seminoma and teratoma (not shown); inset shows diffuse immunohistochemical expression of synaptophysin whereas all germ cell immunostains were negative (not shown).

Source of funding: None.

\* Corresponding author. University of California, San Francisco, Department of Urology, Mailcode 1695, 550 16th Street, 6th Floor San Francisco, CA 94143, USA. Tel.: +1 415 353 7096; fax: +1 415 476 5366.

E-mail address: [mmeng@urology.ucsf.edu](mailto:mmeng@urology.ucsf.edu) (M.V. Meng).



**Figure 2.** Computed Tomography demonstrating large right-sided retroperitoneal mass, measuring  $13 \times 11 \times 7$  cm, encasing the aorta and compressing the inferior vena cava and right ureter.

2 cm focus of poorly-differentiated high grade small round blue cells resembling malignant primitive neural elements. The primitive tumor cells showed immunohistochemical expression of synaptophysin but not of CD99 (Fig. 2). Embryonal carcinoma and rhabdomyosarcoma were excluded by immunohistochemistry (negative SALL4, OCT4, desmin and myogenin). The morphology and immunophenotype of the cells in question was classified as a form of central nervous system-type primitive neuroectodermal tumor (CNS-type PNET). Re-examination of the slides of the primary testicular tumor did not reveal any similar tumor component but it was not possible to determine the tumor type that originally occupied the areas of necrosis and scar adjacent to viable seminoma and teratoma.

## Discussion

Teratomas represent approximately 4% of testicular germ cell tumors, but display complex histology and a heterogeneous clinical progression.<sup>1</sup> Although some may be inert or only locally aggressive, 3–8% of testicular teratomas have the potential for transformation of the epithelial elements to carcinoma or mesenchymal elements to sarcoma. Rarely, primary or metastatic testicular germ cell tumors may contain tumor components that morphologically resemble central nervous system medulloblastoma or medullopithelioma (so-called CNS-type PNET) or Ewing sarcoma

(previously referred to as peripheral-type PNET).<sup>2</sup> Although the CNS-type PNETs may morphologically resemble Ewing sarcoma, the latter harbor a pathognomonic translocation of the *EWSR1* gene on chromosome 22 and are CD99 positive, whereas the former are not. A recent study demonstrated that *EWSR1* translocations are not present in testicular tumors that contain PNET-like tumors.<sup>3</sup> Therefore these tumor components are not Ewing sarcoma but a form of CNS-type PNET. Whether such primitive tumor components represent a de novo tumor component or represent progression from existing neuroepithelial teratomatous elements is unclear. The current case is best classified as CNS-type PNET as the CD99 stain was negative and synaptophysin was positive.

Post-chemotherapy RPLND remains an important component of treatment for patients with residual masses. Approximately half of patients have only residual scar, 40% have teratoma, and 10% have viable tumor. Recent work showed that even in patients with residual masses  $\leq 20$  mm after contemporary chemotherapy regimens, 7% and 26% had viable tumor and teratoma, respectively.<sup>4</sup>

## Conclusion

Given the high likelihood of residual tumor and possibility of malignant transformation of teratoma into aggressive histology, post-chemotherapy RPLND remains vital in treating patients with testis cancer. In addition, PNET is chemo-resistant and recurrent lesions should be resected, without clear evidence for adjuvant chemotherapy in this setting.

## Conflicts of interest

The authors have no conflicts of interest.

## References

1. Ulbright TM. Germ cell tumors of the gonads: a selective review emphasizing problems in differential diagnosis, newly appreciated, and controversial issues. *Mod Pathol.* 2005;18:S61–S79. <http://dx.doi.org/10.1038/modpathol.3800310>.
2. Fletcher CDM, Bridge AJ, Hogendoorn P, Mertens F, eds. *WHO Classification of Tumours of Soft Tissue and Bone*. 4. International Agency for Research on Cancer; 2013.
3. Ulbright TM, Hattab EM, Zhang S, et al. Primitive neuroectodermal tumors in patients with testicular germ cell tumors usually resemble pediatric-type central nervous system embryonal neoplasms and lack chromosome 22 rearrangements. *Mod Pathol.* 2010;23(7):972–980. <http://dx.doi.org/10.1038/modpathol.2010.70>.
4. Oldenburg J. Postchemotherapy retroperitoneal surgery remains necessary in patients with nonseminomatous testicular cancer and minimal residual tumor masses. *J Clin Oncol.* 2003;21(17):3310–3317. <http://dx.doi.org/10.1200/JCO.2003.03.184>.