

# Left circumflex artery injury postmitral valve surgery, single center experience



Aysha Husain<sup>a</sup>, Aly Alsanei<sup>a</sup>, Mohammed Tahir<sup>a</sup>, Ziad Dahdouh<sup>a</sup>, Zohair AlHalees<sup>a</sup>, Ali AlMasood<sup>a,\*</sup>

<sup>a</sup> Heart Center, King Faisal Hospital and Research Center, Riyadh

<sup>a</sup> Saudi Arabia

The left circumflex (LCX) artery is located close to the mitral valve (MV), making it susceptible to injury during MV surgery. We are reporting our experience in the diagnosis and management of this complication. We retrospectively reviewed our surgical and coronary angiography databases for patients with documented LCX artery injury during MV surgery between January 2000 and December 2016. The complication was associated with MV replacement (9/1313, 0.7%) but not MV repair (0/393, 0.0%). Eight patients (88.9%) were female and the mean age was 40.4 ± 14.2 years. There was roughly similar distribution of left and right dominant coronary circulations (5 and 4 patients, respectively). Eight patients (88.9%) had ischemic changes on electrocardiogram and ventricular arrhythmias were documented on six patients (66.7%). Three patients (33.3%) were treated with percutaneous coronary intervention while six patients (66.7%) required redo surgery to graft the LCX artery. The 30-day mortality was high (33.3%). A high index of suspicion is required to diagnose this injury. At the moment, no consensus is available on the optimal treatment strategy. We propose percutaneous approach as the first option to spare the patients from undergoing open-heart surgery for the second time.

© 2018 The Authors. Production and hosting by Elsevier B.V. on behalf of King Saud University. This is an open access article under the CC BY-NC-ND license (<http://creativecommons.org/licenses/by-nc-nd/4.0/>).

**Keywords:** valvular surgery, percutaneous coronary intervention, coronary artery disease, coronary bypass grafts, mitral valve disease

## 1. Introduction

The left circumflex (LCX) artery curves around the posterior mitral valve (MV) annulus, and this close proximity makes it susceptible to injury during MV surgery [1]. Injury to the LCX artery can jeopardize the myocardium and expose patients to a considerable risk of mortality. LCX

artery injury can transform low risk single valve surgery into higher double open-heart surgeries or emergency need for percutaneous coronary intervention (PCI) after cardiac surgery [2–24]. Sporadic cases of this complication have been reported in the literature [2–32]. Anatomical studies on the LCX artery proposed the left-dominant coronary circulation to be a risk factor due to the shortest distance recorded between the LCX

**Disclosure:** Authors have nothing to disclose with regard to commercial support.

Received 9 August 2018; revised 21 December 2018; accepted 26 December 2018.

Available online 31 December 2018

\* Corresponding author. King Faisal Specialist Hospital and Research Center, Heart Center, Riyadh11211 MBC:16, 3354, Saudi Arabia.  
E-mail address: [aalmasood@kfshrc.edu.sa](mailto:aalmasood@kfshrc.edu.sa) (A. AlMasood).



P.O. Box 2925 Riyadh – 11461KSA  
Tel: +966 1 2520088 ext 40151  
Fax: +966 1 2520718  
Email: [sha@sha.org.sa](mailto:sha@sha.org.sa)  
URL: [www.sha.org.sa](http://www.sha.org.sa)



1016-7315 © 2018 The Authors. Production and hosting by Elsevier B.V. on behalf of King Saud University. This is an open access article under the CC BY-NC-ND license (<http://creativecommons.org/licenses/by-nc-nd/4.0/>).

Peer review under responsibility of King Saud University.

URL: [www.ksu.edu.sa](http://www.ksu.edu.sa)

<https://doi.org/10.1016/j.jsha.2018.12.003>



Production and hosting by Elsevier

artery and MV [26,33–35]. In this article, we describe our experience with this complication and compare it to the previously reported cases in the literature.

## 2. Materials and methods

We retrospectively analyzed all patients who underwent MV surgery in King Faisal Specialist Hospital (Riyadh, Saudi Arabia) between January 2000 and December 2016. Patients with postoperative complicated course who required coronary angiography (CAG) were identified. CAG reports and angiographic views were reviewed to identify patients with LCX injury or LCX occlusion. Electronic medical records and medical charts were used to extract variables into predesigned data sheets.

The variables extracted included: demographic data, cause of MV surgery, left ventricle ejection fraction (LVEF) at the baseline, postoperatively, and at the 6-months follow-up, coronary dominance pattern, electrocardiography (ECG) findings, treatment method, time between ischemia identification and treatment, and mortality rate at 30-days, 6-months, and 1-year follow-up. The data were analyzed using descriptive statistics and compared with the previous case reports. Data were expressed as mean  $\pm$  standard deviation for continuous variables and as frequencies and percentages for categorical variables. The study was approved by the ethical committee at our institution.

## 3. Results

Out of 1706 patients who underwent MV surgery during the assigned period, 95 (5.6%) underwent CAG shortly post-MV surgery, for suspicion of postoperative myocardial injury. Out of 1706 patients reviewed, nine (0.5%) were found to have LCX artery injury. The complication was associated with MV replacement (0.7%, 9/1313) but not MV repair (0.0%, 0/393). With the exception of one patient, the injured patients were females (88.9%). The mean age of the patients was  $40.4 \pm 14.2$  years, ranging between 9 years and 56 years. The youngest patient was a female child with congenital heart disease (Shone complex). The etiology of MV disease was rheumatic heart disease in eight patients (88.9%).

As shown in Table 1, three patients (33.3%) underwent CAG prior to surgery as a routine procedure before open heart surgery for those who are at risk of coronary artery disease. The average

### Abbreviations

LCX	left circumflex
MV	mitral valve
CAG	coronary angiography
PCI	percutaneous coronary intervention
LVEF	left ventricle ejection fraction
ECG	Electrocardiography

preoperative LVEF was  $48.8 \pm 6.9\%$ . The surgery done was redo MV replacement in four patients (44.4%) and primary MV replacement in the remaining patients. The time from LCX artery injury confirmation using CAG to revascularization either via PCI or bypass surgery varied between 2 hours and 72 hours. Postoperative CAG revealed evidence of total LCX artery occlusion in all patients. There was roughly similar distribution of left and right dominant coronary circulations (5 and 4 patients, respectively).

As shown in Tables 1 and 2, the findings suggestive of myocardial ischemia due to LCX artery injury were documented on echocardiography as wall-motion abnormalities on echocardiography (100.0%), ST segment deviation (88.9%), electrical instability with ventricular tachycardia or ventricular fibrillation (66.7%). In three patients (33.3%), the complication manifested as cardiac arrest requiring resuscitation and in one patient (11.1%), extracorporeal membrane oxygenation (ECMO) was required. The injury was discovered intraoperatively in only one patient (11.1%), in whom transesophageal echocardiography showed hypokinesia of the lateral and inferior walls.

For management, six patients (66.7%) had a second open-heart surgery performed to graft the vessel with saphenous vein graft and three patients (33.3%) had a PCI successfully restored antegrade blood flow to the occluded LCX artery (Table 1). Patient 5, the youngest patient in our registry, underwent PCI at the age of 9 years. Patient 6 underwent PCI after a failed CABG, in which the LCX graft could not be placed due to extensive adhesions. Patient 8 successfully underwent PCI in which a drug-eluting stent was deployed into the LCX artery after multiple predilatation attempts with noncompliant balloons (Fig. 1). The 30-day mortality was high (33.3%). Patients who survived the initial insult were alive at 6 months and 1 year later (Table 1).

## 4. Discussion

We are reporting a total of nine patients with LCX injury post-MV surgery, the largest series up to date. Two cases were reported previously

Table 1. Overview of patients reported with left circumflex artery injury during mitral valve surgery, KFSH, 2000–2016 (n = 9).

Case No.	Sex	Age	Pre-op CAG	Pre-op EF	Type of surgery	Time till reperfusion (h)	ECG	Echocardiography changes	Coronary dominance Post-op CAG	Treatment	30-d mortality	6-mo mortality	EF at 6 mo
1	F	55	Yes	50	MVR (Conform × valve 33/35)	2.5	NA	Akinesia of inferiolateral wall	Right	CABG	Yes	Yes	-
2	F	44	No	55	MVR (Mosaic #29) TVR mosaic #33	7	Anterior ST depression	Hypokinesia of lateral wall	Left	CABG	No	No	35
3	F	42	No	50	MVR (ST Jude #27) ring TV repair 3D #32	2.5	Inferior ST depression	Hypokinesia of inferioposterior wall	Right	CABG	Yes	Yes	-
4	F	32	No	35	MVR (Onyx 25/33)	6	Anterior ST depression	Hypokinesia of inferioposterior wall	Right	CABG	No	No	25
5	F	9	No	55	SAM resection and MVR (CM # 23)	72	Inferior ST depression	Hypokinesia of inferior wall	Left	PCI	No	No	35
6	M	36	No	45	Redo MVR (CM#29)	72	Inferior ST elevation	Global hypokinesia	Left	Failed CABG then PCI	Yes	Yes	-
7	F	49	Yes	55	Redo MVR (ATS # 27) TV repair Duran ring#29	4	Inferior ST elevation	Hypokinesia of inferioposterior wall	Right	CABG	No	No	40
8	F	56	Yes	45	Redo MVR (Apex #31)	8	Anterior ST depression	Global hypokinesia	Left	PCI	No	No	45
9	F	41	No	55	Redo MVR (CM#29) TV repair MC3 ring	2	NA	Hypokinesia of inferiolateral wall	Left	CABG	No	No	35

CABG = coronary artery bypass grafting; CAG = coronary angiography; ECG = electrocardiography; EF = ejection fraction; F = female; KFSH = King Faisal Specialist Hospital; M = male; MVR = mitral valve replacement; PCI, percutaneous coronary intervention; TV = tricuspid valve; TVR, tricuspid valve replacement; SAM, Sub-Aortic membrane; ATS, bileaflet prosthetic valve developed by ATS Medical; Inc., CM, Carbomedics valve; MC, Edwards MC annuloplasty ring (Edwards LifeScience, Irvine, CA, USA); NA, not available.

Table 2. Frequency of findings on patients with LCX artery injury post-MV surgery, KFSH, 2000–2016 (n = 9).

Presentation findings suggestive of LCX artery injury post-MV surgery	N	%
ECG changes with ST segment deviation	8	88.9
Electrical instability (ventricular fibrillation or ventricular tachycardia)	6	66.7
Regional wall motion abnormalities (postoperative echocardiography)	9	100.0
Regional wall motion abnormalities (intraoperative transesophageal echocardiography)	1	11.1
Cardiac arrest	3	33.3

ECG = electrocardiography; KFSH = King Faisal Specialist Hospital; LCX = left circumflex artery; MV = mitral valve.

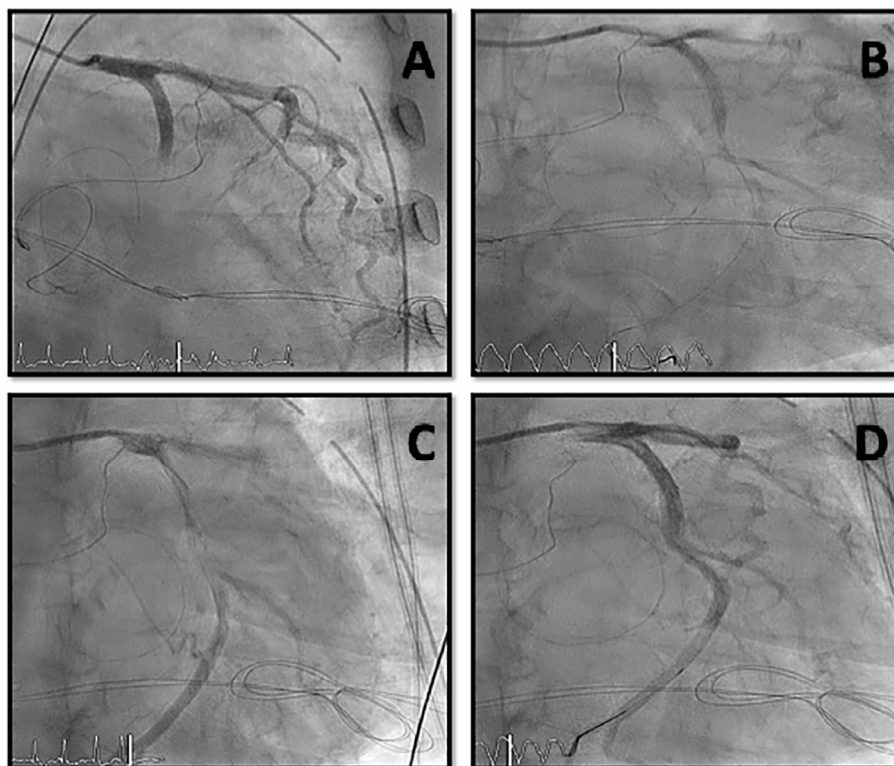


Figure 1. Successful percutaneous coronary stenting for patient with LCX injury post-MV surgery after multiple predilatation inflation attempts. LCX = left circumflex; MV = mitral valve. A; diagnostic angiogram, B; PTCA wire crossing the occlusion, C; angiogram post balloon dilation, D; angiogram post stent deployment.

[30,31]. LCX injury post-MV surgery is considered a rare complication, and only 42 cases reported in literature [26]. Similarly, the overall incidence in this study was 0.5%.

The demography of our database is different from that of the cases reported in the literature, and this reflects the underlying etiology [26]. Unlike Western countries, rheumatic etiology represents most valve diseases that require surgical treatment in Saudi Arabia [36]. Of nine patients, eight were female, as rheumatic heart disease with mitral stenosis is more prevalent in females. The mean age of the patients was  $40.4 \pm 14.2$  years, which is younger than the mean age reported in the literature and reflects a population with no ischemic heart disease risk factors [26].

A major difference between our data and previously reported cases is the pattern of coronary dominance. Our patients showed roughly similar distribution of left and right dominant coronary circulations. This was generally inconsistent with the findings from anatomical studies and reported cases in the literature [23,26,33–35]. In these cases, left-dominant circulation was more prevalent and tended to be a risk factor for LCX artery injury during MV surgery [26]. The LCX artery curves in close proximity to posterior MV annulus and the distance was measured in several anatomical studies. Three of these studies confirmed a pattern of a short distance (average, 3.99 mm) between the LCX artery and the posterior mitral annulus in hearts with left-dominant coronary cir-

culations [23,34,35]. However, an anatomical study performed by Pessa et al. [33] found this small distance can be recorded in right-dominant circulation negating the findings observed in other studies and supporting our results. Occlusion of nondominant LCX artery might not cause major hemodynamic compromise and it can be underreported in literature. This might account for the difference in the pattern of coronary dominance noted in our patients than the ones reported earlier.

Therefore, the performance of CAG to determine the pattern of coronary dominance prior to every MV surgery does not necessarily preclude the possibility of LCX artery injury. With advancements in cardiac imaging and improved spatial resolution of cardiac computed tomography (CT), the distance between the MV and the LCX artery can be accurately measured prior to surgery [13,37]. However, this raises the question of whether cardiac CT prior to every MV surgery is cost effective given the low incidence of this complication. The mechanism of injury could be related to suture going around or through the artery, tissue retraction, artery laceration, or external compression from the valve implanted [23].

If the prevention of this complication is not feasible, then early diagnosis is crucial. The main presenting feature of this complication was ST changes on routine postoperative ECG. However, a high index of suspicion is required to initiate further investigations and therapy since these patients can rapidly deteriorate. Three patients in this series rapidly progressed to cardiac arrest. In one patient, regional wall-motion abnormalities were observed on intraoperative transesophageal echocardiography. Ender et al. [38] studied the patency of the LCX artery on transesophageal echocardiography during minimally invasive MV surgery. This is an interesting aspect as early changes might be noted during surgery, and therapy can be initiated during the same setting. The time from ischemia detection to therapy varied in our patients. In general, this time should be as short as possible to prevent myocardial damage. Therefore, performing the surgery in a hybrid room might be beneficial to reduce the reperfusion time and allow CAG to be done in the same setting.

In our study, the 30-day mortality was high (33.3%). Patients who survived the acute insult remained alive at 6 months and 1 year, however some of them developed reduced left-ventricular function on echocardiography (Table 1). The average deterioration was 14.2%, ranging between 0% and 20%.

Our therapeutic approach was to try to establish the coronary flow to the injured LCX artery surgically or percutaneously as soon as possible. The decision which option to follow was according to interventionist and cardiac surgeon judgment. There is a lack of consensus about what is the best approach to treat this situation. The traditional concept is to shorten ischemia time to avoid mortality and morbidity. We propose the percutaneous approach as the first option to spare the patients from undergoing open-heart surgery for a second time, and it is faster to establish coronary blood flow. In our patients, PCI was associated with slightly lower deterioration of LVEF at 6 months (10.0%) compared with open-heart surgery (16.3%) but similar mortality (33.3% in both).

#### 4.1. Limitations

The main limitation of our study is the small number of patients studied, which is related to the low incidence of this complication during MV surgery. This should be considered when interpreting our findings. Worldwide registries are needed to assemble all such cases and to find better strategies to predict and treat this complication.

## 5. Conclusion

The LCX artery curves around the posterior mitral annulus, which makes it susceptible to injury during MV surgery. In our study, the overall incidence was very low (0.5%) with roughly similar distribution of left and right dominant coronary circulations. A high index of suspicion is required to diagnose this injury. ECG monitoring of ischemic changes and intraoperative transesophageal echocardiography to detect regional wall-motions abnormalities can allow for early detection and timely therapy.

#### 5.1. Impact on daily practice

Increasing awareness of the possibility of LCX artery injury during MV surgery is mandatory for the early detection and prompt treatment of this complication, which carries a high risk of mortality. Percutaneous therapy can provide early and successful restoration of blood flow.

## References

- [1] Aybek T, Risteski P, Miskovic A, Simon A, Dogan S, Abdel-Rahman U, et al. Seven years' experience with suture annuloplasty for mitral valve repair. *J Thorac Cardiovasc Surg* 2006;131:99–106.
- [2] Mantilla R, Legarra JJ, Pradas G, Bravo M, Sanmartin M, Goicolea J. Percutaneous coronary intervention for

- iatrogenic occlusion of the circumflex artery after mitral anuloplasty. *Rev Esp Cardiol* 2004;57:702–4.
- [3] Sangha R, Hui P. Intravascular ultrasound imaging and percutaneous intervention in a patient with postmitral valve replacement circumflex coronary artery occlusion. *J Invasive Cardiol* 2004;16:351–2.
  - [4] Nakajima H, Ikari Y, Kigawa I, Kitamura T, Hatori M, Tooda E, et al. Rapid diagnosis and management of intraoperative myocardial infarction during valvular surgery: using intraoperative transesophageal echocardiography followed by emergency coronary artery bypass grafting without coronary angiography. *Echocardiography* 2005;22:834–8.
  - [5] Meursing DF, Boonswang NA, Dobrilovic N, Wait MA. Perioperative myocardial infarction secondary to dynamic circumflex coronary artery occlusion after mitral valve repair. *Tex Heart Inst J* 2006;33:85–7.
  - [6] Wykrzykowska J, Cohen D, Zimetabum P. Mitral anuloplasty causing left circumflex injury and infarction: Novel use of intravascular ultrasound to diagnose suture injury. *J Invasive Cardiol* 2006;18:505–8.
  - [7] Raza JA, Rodriguez E, Miller MJ. Successful percutaneous revascularization of circumflex artery injury after minimally invasive mitral valve repair and left atrial cryo-MAZE. *J Invasive Cardiol* 2006;18:E285–7.
  - [8] Zegdi R, Jouan J, Fabiani JN, Deloche A. Injury to the circumflex coronary artery following mitral valve repair. *Eur J Cardiothorac Surg* 2007;31:740.
  - [9] Aubert S, Barthelemy O, Landi M, Acar C. Circumflex coronary artery injury following mitral anuloplasty treated by emergency angioplasty. *Eur J Cardiothorac Surg* 2008;34:922–4.
  - [10] Ender J, Gummert J, Fassl J, Krohmer E, Bossert T, Mohr FW. Ligation or distortion of the right circumflex artery during minimal invasive mitral valve repair detected by transesophageal echocardiography. *J Am Soc Echocardiogr* 2008;21(408):e4–5.
  - [11] Grande AM, Fiore A, Massetti M, Vigano M. Iatrogenic circumflex coronary lesion in mitral valve surgery: Case report and review of the literature. *Tex Heart Inst J* 2008;35:179–83.
  - [12] Gomes WJ. Injury to the circumflex coronary artery following mitral valve repair: A rather opposite strategy. *Eur J Cardiothorac Surg* 2008;33:948–9.
  - [13] Vivas D, Alfonso F, Silva J. Anomalous circumflex coronary artery injury caused by mitral anuloplasty: role of 64-multislice computed tomography. *J Invasive Cardiol* 2009;21:E204–5.
  - [14] Calafiore AM, Iaco AL, Varone E, Bosco P, Di Mauro M. Distortion of the proximal circumflex artery during mitral valve repair. *J Card Surg* 2010;25:163–5.
  - [15] Vaishnava P, Pyo R, Filsoofi F, Sharma S. Compression of an anomalous left circumflex artery after aortic and mitral valve replacement. *Ann Thorac Surg* 2011;92:1887–9.
  - [16] Varela NL, Pulido JN, Lynch JJ, Mauermann WJ, Rehfeldt KH. Acute coronary syndrome after mitral valve surgery: a rare complication secondary to mechanical occlusion of the circumflex artery. *Int Anesthesiol Clin* 2011;49:32–41.
  - [17] Sheth H, Swamy RS, Shah AP. Acute myocardial infarction and cardiac arrest due to coronary artery perforation after mitral valve surgery: successful treatment with a covered stent. *Cardiovasc Revasc Med* 2012;13:62–5.
  - [18] Postorino S, Buja P, Grassi G, Millosevich P, Barbierato M, Venturini A, et al. Mitral valve repair complicated by iatrogenic coronary artery lesion treated with percutaneous coronary intervention. *J Cardiovasc Med (Hagerstown)* 2011;12:180–1.
  - [19] Somekh NN, Haider A, Makaryus AN, Katz S, Bello S, Hartman A. Left circumflex coronary artery occlusion after mitral valve anuloplasty: “A stitch in time”. *Tex Heart Inst J* 2012;39:104–7.
  - [20] Schyma C, Kernbach-Wighton G, Madea B. Kinking of a coronary artery as a rare complication in mitral valve replacement. *Forensic Sci Int* 2012;221:e30–3.
  - [21] Banayan J, Dhawan R, Vernick WJ, McCarthy PM. CASE 3–2012: iatrogenic circumflex artery injury during minimally invasive mitral valve surgery. *J Cardiothorac Vasc Anesth* 2012;26:512–9.
  - [22] Folkmann S, Mohr FW, Garbade J. Emergency PCI after occlusion of the circumflex artery due to minimally invasive mitral valve replacement in redo operation. *Acta Cardiol* 2014;64:451–3.
  - [23] Hiltrop N, Bennett J, Desmet W. Circumflex coronary artery injury after mitral valve surgery: a report of four cases and comprehensive review of the literature. *Catheter Cardiovasc Interv* 2017;89(1):78–92.
  - [24] Danielson GK, Cooper E, Ifuku M. Severance of mitral prosthesis fixation sutures by annulus calcification. *J Thorac Cardiovasc Surg* 1967;53:858–63.
  - [25] Virmani R, Chun PK, Parker J, McAllister HAJ. Suture obliteration of the circumflex coronary artery in three patients undergoing mitral valve operation. Role of left dominant or codominant coronary artery. *J Thorac Cardiovasc Surg* 1982;84:773–8.
  - [26] Morin D, Fischer AP, Sohl BE, Sadeghi H. Iatrogenic myocardial infarction. A possible complication of mitral valve surgery related to anatomical variation of the circumflex coronary artery. *Thorac Cardiovasc Surg* 1982;30:176–9.
  - [27] Tavilla G, Pacini D. Damage to the circumflex coronary artery during mitral valve repair with sliding leaflet technique. *Ann Thorac Surg* 1998;66:2091–3.
  - [28] Speziale G, Fattouch K, Ruvolo G, Fiorenza G, Papalia U, Marino B. Myocardial infarction caused by compression of anomalous circumflex coronary artery after mitral valve replacement. *Minerva Cardioangiol* 1998;46:455–6.
  - [29] Mulpur AK, Kotidis KN, Nair UR. Partial circumflex artery injury during mitral valve replacement: Late presentation. *J Cardiovasc Surg (Torino)* 2000;41:333–4.
  - [30] Hassan W, ElShaer F, Hegazy H, Al Fadley F, Kharabsheh S. Successful bailout percutaneous coronary intervention for immediate surgical complication. *J Invasive Cardiol* 2004;16:516–7.
  - [31] Assaqqat MA, Hassan W, Siblini G. Coronary arterial compression treated by stenting after replacement of the mitral valve in a child. *Cardiol Young* 2003;13:475–8.
  - [32] Coutinho GF, Leite F, Antunes MJ. Circumflex artery injury during mitral valve repair: Not well known, perhaps not so infrequent—lessons learned from a 6-case experience. *J Thorac Cardiovasc Surg* 2017;154(5):1613–20.
  - [33] Pessa CJ, Gomes WJ, Catani R, Prates JC, Buffolo E. Anatomical relationship between the posterior mitral valve annulus and the coronary arteries. Implications to operative treatment. *Braz J Cardiovasc Surg* 2004;19:372–7.
  - [34] Cornu E, Lacroix PH, Christides C, Laskar M. Coronary artery damage during mitral valve replacement. *J Cardiovasc Surg (Torino)* 1995;36:261–4.
  - [35] Kaklikkaya I, Yeginoglu G. Damage to coronary arteries during mitral valve surgery. *Heart Surg Forum* 2003;6: E138–42.
  - [36] Duran CM, Gometza B, Saad E, Al-Halees Z, Khouqeer F, Al-Sanei A. Heart valve surgery in a young predominantly rheumatic population. *Ann Saudi Med*. 1993;13:501–7.
  - [37] Castillo JG, Sanz J, Fischer GW, Bowman K, Filsoofi F. Management of anomalous left circumflex artery encircling the aortic annulus in a patient undergoing multivalvular surgery. *J Card Surg* 2009;24:667–9.
  - [38] Ender J, Selbach M, Borger MA, Krohmer E, Falk V, Kaisers UX, et al. Echocardiographic identification of iatrogenic injury of the circumflex artery during minimally invasive mitral valve repair. *Ann Thorac Surg* 2010;89:1866–72.