

Cone-beam Computed Tomographic Evaluation of the Quality of Obturation Using Different Pediatric Rotary File Systems in Primary Teeth

D Vaishali Naidu¹, J Sharada Reddy², Tarasingh Patloth³, K Suhasini⁴, Hema Chandrika I⁵, Hasanuddin Shaik⁶

ABSTRACT

Aim and objective: To compare and evaluate the efficacy of three different pediatric rotary file systems in primary molars using cone-beam computed tomography (CBCT).

Materials and methods: Thirty extracted mandibular primary molars were selected and divided into three groups with ten teeth each, instrumented with Kedo SG Blue rotary files, Pro AF Baby gold rotary files, and Pedo Flex rotary files, respectively. Root canal obturation was done with zinc-oxide eugenol cement and the quality of obturation was assessed using CBCT based on the extent of filling as underfilled or optimally filled and the presence or absence of voids within the filling. The data were statistically analyzed using the Chi-square test.

Results: Among the three groups, the Kedo SG Blue group showed more number of optimally filled teeth with minimal voids ($p < 0.05$) followed by the Pro AF Baby gold group and Pedo Flex group.

Conclusion: Within the study limitations, the Kedo SG Blue group showed ideal endodontic obturation when compared with Pro AF baby gold and Pedo Flex rotary file systems.

Clinical significance: The present study will guide the pedodontists regarding the efficacy of pediatric rotary file systems and their usage protocols.

Keywords: Cone-beam computed tomography, Kedo SG blue rotary files, Pediatric rotary files, Pedo flex rotary files, Primary molars, Prime Pedo rotary files, Quality of obturation.

International Journal of Clinical Pediatric Dentistry (2021): 10.5005/jp-journals-10005-2000

INTRODUCTION

Pediatric endodontics is a fundamental aspect of dentistry that preserves the primary teeth in its functional form. Effective debridement and restoration of the pulpally involved primary teeth should be considered as the treatment of choice for space maintenance, function, and esthetics.¹ The complex, ribbon-shaped root canal morphology of the primary molars challenges the success of pulpectomy in achieving a three-dimensional seal. Mechanical preparation with conventional hand instruments is time-consuming and may lead to iatrogenic errors (canal transportation, apical blockage, ledging, zipping, etc.) when compared with rotary instrumentation, which can efficiently prepare the root canals.

Barr et al. in 1999 pioneered rotary biomechanical preparation with Profile 0.04 taper files in primary teeth.² Studies on rotary instrumentation outlined the uniform root canal preparation and predictable obturation with a significant reduction in the working time.^{2,3} The modified protocol of the Pro Taper, Heroshaper, and K3 rotary files was used in primary molars.⁴⁻⁶ But, these conventional rotary files designed for permanent teeth, are longer (21 or 25 mm) with a constant taper (6 or 8%) are inconvenient to be used in the oral cavities of children. Pediatric endodontics has evolved with the introduction of exclusive pedodontic rotary file systems with modified length and taper. Kedo-S is the first pedodontic rotary file system introduced by Reeganz Dental care Pvt. Ltd., India followed by Prime Pedo (Sky International Enterprises, India), Pro AF Baby Gold (Dentobizz, India), DXL-Pro Pedo (Kraft Dental, India), Pedo Flex (Orikam Health care, India), Denco Kids files (Shenzhen Denco medical Ltd., China), and Sani Kid rotary files (Chengdu Sani medical equipment Co. Ltd., China).⁷

¹⁻⁶Department of Pedodontics and Preventive Dentistry, Government Dental College and Hospital, Hyderabad, Telangana, India

Corresponding Author: J Sharada Reddy, Department of Pedodontics and Preventive Dentistry, Government Dental College and Hospital, Hyderabad, Telangana, India, Phone: +91 9290970400, e-mail: sharadagdchyd@gmail.com

How to cite this article: Vaishali Naidu D, Sharada Reddy J, Patloth T, et al. Cone-beam Computed Tomographic Evaluation of the Quality of Obturation Using Different Pediatric Rotary File Systems in Primary Teeth. *Int J Clin Pediatr Dent* 2021;14(4):542-547.

Source of support: Nil

Conflict of interest: None

To date, no study has reported the comparative evaluation of different pediatric rotary file systems using cone-beam computed tomography (CBCT). Hence, a study was planned to compare and evaluate the efficacy of three different pediatric rotary file systems viz., Kedo SG Blue, Pro AF Baby gold, and Pedo Flex rotary files using CBCT.

MATERIALS AND METHODS

- Thirty mandibular primary molars extracted either due to gross caries, loss of bone support, or over retention with at least two-thirds of root length (7-12 mm) were included in the study. The teeth were rinsed and stored in normal saline for 1 week. Ethical clearance for the study was obtained from Institutional Ethical Committee. The teeth were divided into

three groups based on the pediatric rotary files used for the root canal preparation.

- Group I ($n = 10$): Kedo SG Blue rotary files (Reeganz Dental Care Pvt. Ltd., India).
- Group II ($n = 10$): Pro AF Baby gold rotary files (Dentobizz, India).
- Group III ($n = 10$): Pedo Flex rotary files (Orikam Health Care, India).

Access cavity preparation was done using No. 8 round bur (Mani Inc., Japan) followed by working length determination using Radiovisiograph (RVG, Carestream Health, Inc., USA) with the endodontic file placed 1 mm short of the apical foramen. Rotary instrumentation was done after the canals were enlarged up to #20 hand K-files.

Group I

Root canal preparation was done using Kedo SG blue rotary file system. It consists of three files D1 (#25, for narrow canals), E1 (#30, for wider canals), and U1(#40, for anteriors). Using an endodontic motor set at 300 RPM and 2.2 N cm torque, the mesiobuccal and mesiolingual canals were prepared with D1 file, while the distal and palatal canals with the E1 file.

Group II

Root canal preparation was done using a Pro AF Baby gold rotary file system. It consists of five files B1 (#20–04%), B2 (#25–04%), B3 (#25–06%), B4 (#30–04%), and B5 (#40–04%). Using an endodontic motor set at 300 RPM and 3 N cm torque, the narrow canals (mesiobuccal/mesiolingual) were prepared with B1 and B2 while the wider canals (distal/palatal) with B2 and B4.

Group III

Root canal preparation was done using Pedo Flex rotary file system consisting of three files #20 (yellow), #25 (red), and #30 (blue) which were used sequentially in all the canals with an endodontic motor set at 350 RPM and 1.5 N cm torque.

According to the manufacturer's protocol, Kedo-S rotary files are recommended to be used 1–2 times till the entire working length and not >3 to 4 seconds to avoid instrument deformation and separation. This protocol was standardized for all the file systems.

Irrigation was done with 10 mL of 1% sodium hypochlorite solution (Prime dental products Pvt. Ltd., India) followed by normal saline in all the teeth after each file is used during the entire cleaning and shaping procedure. Also, the files were lubricated with 15% EDTA gel (RC Help; Prime Dental Products Pvt. Ltd., India) during the biomechanical preparation and the whole procedure was carried out by a single operator.

After the canal preparation, obturation was done with zinc oxide eugenol (ZOE) cement using the reamer technique in all the groups. The postendodontic assessment and comparative evaluation were done using CBCT (New Tom-NNT software, Italy) (Fig. 1) with respect to the quality of obturation and the voids within the root canal filling. Scoring was based on Modified Coll and Sadrian⁸ criteria as:

- Score 1 (under-filling): All the canals were filled >2 mm short of the apex.
- Score 2 (optimal filling): One or more of the canals having obturating material ending at the radiographic apex or up to 2 mm short of the apex.

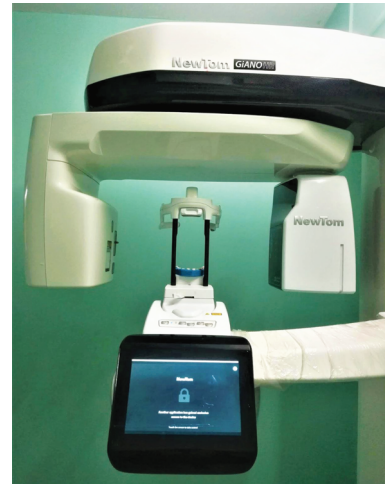


Fig. 1: CBCT machine

- Score 3 (overfilling): Any canal showing obturating material extending beyond the radiographic apex.
- Presence or absence of voids.

In the present study, score 3 is not included as the peri-apical region of the teeth could not be simulated. Data were analyzed and a Chi-square test was done using SPSS. version 25 software (International business machines corporation, New York) to determine the association between the categorical variables and the results were tabulated.

RESULTS

When the quality of obturation was compared among the three groups, Kedo SG Blue showed the highest number of optimal fillings (Fig. 2A) in nine teeth (42.9%) followed by Pro AF Baby gold group in eight teeth (38.1%) and the least was found in Pedo Flex group in four teeth (19%). Only one tooth (11.1%) was underfilled in the Kedo SG Blue group, whereas two teeth (22.2%) and six teeth (66.7%) were underfilled in Pro AF Baby gold and Pedo Flex groups, respectively (Fig. 2B). There was a statistically significant difference with $p = 0.036$ (Table 1). In specific to the mesial and distal canals, the highest number of optimally filled canals were found in the Kedo SG Blue group (11 mesial and 9 distal canals) followed by Pro AF Baby gold (10 mesial and 9 distal canals) and Pedo Flex (6 mesial and 6 distal canals), although there was no statistical significance (Table 2).

When analyzed for the presence or absence of voids, 7 teeth (26.9%) of the Kedo SG Blue group had voids, while 9 teeth (34.6%) and 10 teeth (38.5%) of Pro AF Baby gold and Pedo Flex groups had voids, respectively (Table 3). In specific to the canals, the Kedo SG Blue group showed minimal voids (5 mesial and 8 distal canals), followed by Pro AF Baby gold (9 mesial and 8 distal canals) and Pedo Flex (11 mesial and 7 distal canals) (Table 4).

The intergroup comparison of quality of obturation showed a statistical significance between Kedo SG Blue and Pedo Flex groups ($p = 0.019$) (Table 5). For the presence or absence of voids, a statistically significant difference was observed between Kedo SG Blue and Pedo Flex group with respect to the mesial canals ($p = 0.025$) (Table 6).

DISCUSSION

The complex endodontic configuration of the primary teeth and the possible limitations of the conventional NiTi rotary files like file separation,⁹ discomfort for the children in mouth opening due to the length (21–25 mm) of the files, having no specific protocol for the

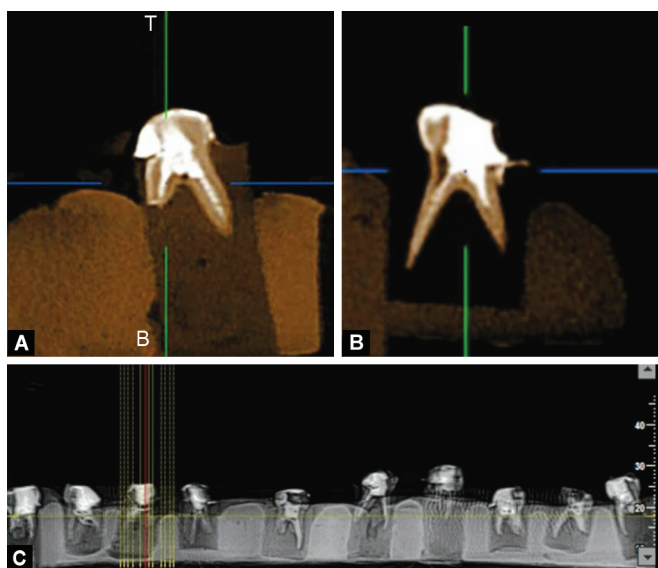
rotary instrumentation in primary teeth, etc.,¹⁰ made it mandatory for the introduction of exclusive pediatric rotary file systems with specific protocols. Application of the protocols recommended for the permanent teeth may lead to lateral perforation of the primary root canal system.^{4,9}

The present study holds its uniqueness in comparing the exclusive pediatric rotary file systems viz., Kedo SG Blue, Pro AF Baby gold, and Pedo Flex rotary file systems in primary teeth. Each file system has their own file design, speed, and torque specifications and instrumentation protocol. These files are readily available and cost-effective.

The obturation quality is one of the major factors that determine the favorable outcome of pulpectomy.¹¹ This can be evaluated using radiographs, digital radiography like radiovisiography or CBCT, dye penetration, radioisotopes, fluid filtration, bacterial leakage, microscopic analysis, etc.¹² Among all, CBCT provides a faster and an accurate three-dimensional view of the root canal system. During imaging, a cone-shaped X-ray beam is directed through the area of interest at 180 to 360° around the patient's head in a single sweep within 10 to 40 seconds.¹³

Once the image is digitalized, it can be manipulated and displayed in three orthogonal planes [axial, sagittal, and coronal (Fig. 2C)] simultaneously. So to procure in detail information regarding the volumetric filling, CBCT was used as the diagnostic tool in the study.

Using CBCT, evaluation of the canal morphology and adaptation of the obturating material was done in permanent teeth.^{14–16} Studies were done to evaluate the cleaning efficacy of hand and conventional NiTi rotary files^{10,17,18} in primary teeth. Volumetric



Figs 2A to C: (A) Optimally filled root canals with voids; (B) Under-filled root canals with voids; (C) CBCT image shows the coronal view of the samples

Table 1: Comparison of quality of obturation among the groups

Group		QS			χ^2 , df	p value
		Under-filled	Optimally filled	Total		
Group I (n = 10)	Count	1	9	10	6.667, 2	0.036 ^a
	% within group	10.0	90.0	100.0		
	% within QS	11.1	42.9	33.3		
Group II (n = 10)	Count	2	8	10		
	% within group	20.0	80.0	100.0		
	% within QS	22.2	38.1	33.3		
Group III (n = 10)	Count	6	4	10		
	% within group	60.0	40.0	100.0		
	% within QS	66.7	19.0	33.3		

χ^2 = Chi-square; df = Degree of freedom; p = probability; a = significant

Table 2: Comparison of quality of obturation in mesial and distal canals

Groups		Mesial canals		Distal canals	
		Under-filled	Optimally filled	Under-filled	Optimally filled
Group I	Count	4	11	6	9
	% within canals	22.3	40.7	28.5	37.5
Group II	Count	5	10	6	9
	% within canals	27.7	37.1	28.5	37.5
Group III	Count	9	6	9	6
	% within canals	50.0	22.2	42.8	25.0
χ^2 , df		3.732, 2		1.071, 2	
p value		0.155		0.585	

χ^2 = Chi-square; df = degree of freedom; p = probability

Table 3: Comparison of presence or absence of voids among the groups

Group		Void		Total	χ^2 , df	p value
		Absent	Present			
Group I (n = 10)	Count	3	7	10	4.038, 2	0.133
	% within group	30.0	70.0	100.0		
	% within void	75.0	26.9	33.3		
Group II (n = 10)	Count	1	9	10		
	% within group	10.0	90.0	100.0		
	% within void	25.0	34.6	33.3		
Group III (n = 10)	Count	0	10	10		
	% within group	0.0	100.0	100.0		
	% within void	0.0	38.5	33.3		

χ^2 = Chi-square; df = degree of freedom; p = probability

Table 4: Comparison of presence or absence of voids in mesial and distal canals

Groups		Mesial voids		Distal voids	
		Absent	Present	Absent	Present
Group I	Count	10	5	7	8
	% within voids	50.0	20.0	31.8	34.7
Group II	Count	6	9	7	8
	% within voids	30.0	36.0	31.8	34.7
Group III	Count	4	11	8	7
	% within voids	20.0	44.0	36.3	30.4
χ^2 , df		5.833, 2		2.386, 2	
p value		0.050		0.303	

χ^2 = Chi-square; df = Degree of freedom; p = Probability

Table 5: Intergroup comparison of quality of obturation and presence or absence of voids in teeth

Groups	Groups	p value for quality of obturation	p value for voids
Group I (n = 10)	Group I	0.531	0.264
	Group II	0.019 ^a	0.060
Group II (n = 10)	Group I	0.531	0.264
	Group III	0.068	0.305
Group III (n = 10)	Group I	0.019 ^a	0.060
	Group II	0.068	0.305

p = probability; a = significant

Table 6: Intergroup comparison of quality of obturation and voids in mesial and distal canals

Groups	Groups	p value for quality of obturation		p value for voids	
		Mesial	Distal	Mesial	Distal
Group I	Group II	0.606	1.000	0.070	0.639
	Group III	0.068	0.371	0.025 ^a	0.121
Group II	Group I	0.606	1.000	0.070	0.639
	Group III	0.178	0.371	0.606	0.264
Group III	Group I	0.068	0.371	0.025 ^a	0.121
	Group II	0.178	0.371	0.606	0.264

p = probability; a = significant

evaluation of various obturation techniques was done in primary teeth.^{12,13,19} However, in the literature, there are no studies that have evaluated the cleaning efficacy and volumetric filling of root canals using different pedodontic rotary files in primary teeth.

According to the results obtained in the present study, the Kedo SG Blue group showed a maximum number of optimally-filled teeth with minimal voids. When compared with the distal canals, more mesial canals were optimally filled.

Considerable research was done by Jeevanandan and Govindaraju,²⁰ Govindaraju et al.,²¹ and Panchal et al.²² proving Kedo S rotary files' efficacy on comparison with hand K-files. The attributing factors for the better obturation quality with Kedo S rotary files can be anticipated to the NiTi nature, shorter length of the files (17 mm), varying tip diameter, and variably variable (VV) taper. With this taper, higher cervical enlargement and restricted apical preparation are seen which facilitates optimal obturation. The superior performance of the Kedo SG Blue files is due to the additional titanium coat and higher flexibility to negotiate the narrow canals, which lead to a better flow of the obturating material. Similar results were obtained by Priyadarshini et al.²³ where clinical comparison was done using hand K-files, Kedo S files, Kedo SH-files, and Kedo SG Blue files. They found Kedo SG Blue files to be better than others. Its unique features prevent inadvertent file separation thereby increasing its efficacy over its predecessor Kedo S files.²³

When the Kedo SG Blue group was compared with the Pro AF Baby gold group, no much difference was found. Pro AF Baby gold files are heat-treated NiTi controlled memory (CM) wire flexible files. They are 17 mm in length with a constant taper of 4% (B1, B2, B4, B5 files) and 6% (B3 file). The deformities while preparing the root canals and file separation are reduced due to their CM wire technology. The files have a sharp edge with super-high cutting efficiency, a well-polished surface by advanced potent polishing technology, and a non-cutting tip with an accurate tip grinding.²⁴ Because of these features, Pro AF baby gold files showed efficiency comparable to Kedo SG blue files.

A striking difference in the obturation quality was noticed between the Kedo SG Blue group and the Pado Flex group. Neo Endo flex files are one of the recently introduced rotary endodontic files. These files were manufactured to overcome the limitations of conventional NiTi files. Modifying the length of Neo Endo flex files to 16 mm with a constant taper of 4%, Pado Flex files were introduced to be conveniently used in pediatric patients. These files are heat-treated exclusively to give them superior flexibility characteristics. It has a triangular cross-section with sharp cutting edges. It has a non-cutting safety tip, which prevents accidental apical transportation. Generally, due to the heat treatment, an alloy may be prone to plastic deformation which reduces its cutting ability and disruption of the cutting edges during its use. Proprietary heat treatment reduces the restoring forces, thus centering the instrument within the canal. This might have led to the incomplete removal of the dentin, compromising the obturation quality.²⁵

The outcome of an endodontically treated primary tooth is affected not only with the chemomechanical preparation but also the obturating material used and the technique of obturation. The ideal root canal filling technique must provide optimal filling of the canal with minimal or no voids.²⁶ In the present study, the void was a constant finding in all the groups but the Kedo SG group showed minimal voids. Factors that influence the presence or absence of voids include not only the instrumentation technique but also the type, viscosity, and consistency of the paste, obturation technique, and operator skills. Materials that have been reported to be successful in obturating the primary root canals are ZOE, iodoform, calcium hydroxide, endoflas, and vitapex. Zinc oxide eugenol paste was the material of choice as it is one of the most conventional, cost-effective, and widely used materials for primary teeth pulpectomy. As the reamer technique of obturation was used, the irregularities in the root canal configuration could not be obliterated completely, which entrapped tiny air bubbles creating voids. Root canal

obturation with voids may provide potential pathways for leakage which increases the risk of endodontic failure.²⁷

Clinically, Kedo SG blue files were very feasible as they negotiated the canals easily on gentle insertion through the canal orifice. Only a single file was used per canal according to the manufacturer's instructions. Though Pro AF Baby gold files were convenient enough, two files per canal should be used depending upon the working width. As per the protocol of Pado Flex, three files should be used sequentially. The sequential instrumentation indirectly determines the working time, ability, and quality of obturation. As it is an *in vitro* study with a small sample size, it might limit the acceptance of the results.

CONCLUSION

Within the study limitations, the Kedo SG Blue file system proved its efficacy along with Pro AF Baby gold files in achieving an ideal root canal filling. Cone-beam computed tomography serves perfectly in the three-dimensional evaluation of the quality of root canal filling. Clinically, pediatric rotary instrumentation will provide a comfortable and faster endodontic treatment in children. As new rotary endodontic systems are continually updated, further clinical studies should be planned to evaluate their efficacy.

CLINICAL SIGNIFICANCE

The present study will guide the pedodontists regarding the efficacy of pediatric rotary file systems and their usage protocols.

REFERENCES

- McDonald RE, Avery DR, Dean JA. Dentistry for the child and adolescent. 7th ed., St. Louis: CV Mosby Co; 2000.
- Barr ES, Kleier DJ, Barr NV. Use of nickel-titanium rotary files for root canal preparation in primary teeth. *Pediatr Dent* 1999;21(7):453-454.
- Silva LA, Leonardo MR, Nelson-Filho P, et al. Comparison of rotary and manual instrumentation techniques on cleaning capacity and instrumentation time in deciduous molars. *J Dent Child* 2004;71(1):45-47.
- Kuo CI, Wang YL, Chang HH. Application of Ni-Ti rotary files for pulpectomy in primary molars. *J Dent Sci* 2006;1:10-15.
- Kummer TR, Calvo MC, Cordeiro MM, et al. Ex vivo study of manual and rotary instrumentation techniques in human primary teeth. *Oral Surg Oral Med Oral Pathol Oral Radiol Endod* 2008;105(4):e84-e92. DOI: 10.1016/j.tripleo.2007.12.008.
- Ochoa-Romero T, Mendez-Gonzalez V, Flores-Reyes H, et al. Comparison between rotary and manual techniques on duration of instrumentation and obturation times in primary teeth. *J Clin Pediatr Dent* 2011;35(4):359-364. DOI: 10.17796/jcpd.35.4.8k013k21t39245n8.
- Katge F, Ghadge S, Poojari M, et al. Comparative evaluation of cleaning efficacy of Prime pado and DXL-Pro Pado rotary files with conventional H files in root canals of primary teeth: an *in vitro* study. *J Clin Diagn Res* 2019;13(7):ZC06-ZC09.
- Coll JA, Sadrian R. Predicting pulpectomy success and its relationship to exfoliation and succedaneous dentition. *Pediatr Dent* 1996;18(1):57-63.
- Nagaratna PJ, Shashikiran ND, Subbareddy VV. In-vitro comparison of NiTi rotary instruments and stainless steel hand instruments in root canal preparations of primary and permanent molar. *J Indian Soc Pedod Prev Dent* 2006;24(4):186-189. DOI: 10.4103/0970-4388.28075.
- Musale PK, Mujawar SA. Evaluation of the efficacy of rotary vs hand files in root canal preparation of primary teeth *in vitro* using CBCT. *Eur Arch Paediatr Dent* 2014;15(2):113-120. DOI: 10.1007/s40368-013-0072-1.

11. Ranly DM, Garcia-Godoy F. Current and potential pulp therapies for primary and young permanent teeth. *J Dent* 2000;28(3):153–161. DOI: 10.1016/s0300-5712(99)00065-2.
12. Akhil JEJ, Prashant B, Shashibushan KK. Comparative evaluation of three obturation techniques in primary incisors using digital intra-oral receptor and CBCT - an invitro study. *Clin Oral Investigat* 2019;23(2):689–696.
13. Singh R, Chaudhary S, Manuja N, et al. Evaluation of different root canal obturation methods in primary teeth using cone beam computerized tomography. *J Clin Pediatr Dent* 2005;39(5):462–469. DOI: 10.17796/1053-4628-39.5.462.
14. de Alencar AH, Dummer PM, Oliveira HC, et al. Procedural errors during root canal preparation using rotary NiTi instruments detected by periapical radiography and cone beam computed tomography. *Braz Dent J* 2010;21(6):543–549. DOI: 10.1590/s0103-64402010000600011.
15. Tetradis S, Anstey P, Graff-Radford S. Cone beam computed tomography in the diagnosis of dental diseases. *J Calif Dent Assoc* 2010;38(1):27–32.
16. Ahluwalia Y, Sharma U, Kumar N, et al. Adaptation of single cone-cone gutta-percha in curved canals prepared and obturated with protaper and heroshaper systems by using cone beam computed tomography. *J Int Soc Prevent Communit Dent* 2019;9:185–193.
17. Radhika E, Reddy ER, Rani TS, et al. Cone beam computed tomography evaluation of hand Nickel-Titanium K-files and rotary system in primary teeth. *Pediatr Dent* 2017;39(4):319–323.
18. Shaikh SM, Goswami M. Evaluation of the effect of different root canal preparaion techniques in primary teeth using CBCT. *J Clin Pediat Dentis* 2018;42(4):250–255. DOI: 10.17796/1053-4628-42.4.2.
19. Nagaveni NB, Yadav S, Poornima P, et al. Volumetric evaluation of different obturation techniques in primary teeth using spiral computed tomography. *J Clin Pediatr Dent* 2017;41(1):27–31. DOI: 10.17796/1053-4628-41.1.27.
20. Jeevanandan G, Govindaraju L. Clinical comparison of Kedo-S paediatric rotary files vs manual instrumentation for root canal preparation in primary molars: a double blinded randomized clinical trial. *Eur Arch Paediatr Dent* 2018;19(4):273–278. DOI: 10.1007/s40368-018-0356-6.
21. Govindaraju L, Jeevanandan G, Subramanian EM. Comparison of quality of obturation and instrumentation time using hand files and two rotary file systems in primary molars: a single-blinded randomized controlled trial. *Eur J Dent* 2017;11(3):376–379. DOI: 10.4103/ejd.ejd_345_16.
22. Panchal V, Jeevanandan G, Subramanian EM. Comparison of instrumentation time and obturation quality between hand K-file, H-files, and rotary Kedo-S in root canal treatment of primary teeth: a randomized controlled trial. *J Indian Soc Pedod Prev Dent* 2019;37(1):75–79. DOI: 10.4103/JISPPD.JISPPD_72_18.
23. Priyadarshini P, Jeevanandan G, Govindaraju L, et al. Clinical evaluation of instrumentation time and quality of obturation using paediatric hand and rotary file systems with conventional hand K-files for pulpectomy in primary mandibular molars: a double-blinded randomized controlled trial. *Eur Arch Paediatr Dent* 2020;21(6):693–701. DOI: 10.1007/s40368-020-00518-w.
24. Thakkar TK, Naik S, Ghule K. Advances in rotary endodontics in pediatric dentistry. *EC dental Science* 2019;18(6):1320–1330.
25. Tomer AK, Gupta R, Behera A, et al. An in-vitro evaluation of remaining dentine thickness through CBCT using different files. *Int J Appl Dent Sci* 2018;4(3):9–13.
26. Grover R, Mehra M, Pandit IK, et al. Clinical efficacy of various root canal obturating methods in primary teeth: a comparative study. *Eur J Paediatr Dent* 2013;14(2):104–108.
27. Khubchandani M, Baliga MS, Rawlani SS, et al. Comparative evaluation of different obturation techniques in primary molars: an in vivo study. *Eur J Gen Dent* 2017;6(1):42–47. DOI: 10.4103/2278-9626.198611.