

# Oral Fibrolipoma-A Rare Histological Entity: Report of 3 Cases and Review of Literature

B.S. Manjunatha<sup>1</sup>✉, G.S. Deepak Pateel<sup>2</sup>, V. Shah<sup>3</sup>

<sup>1</sup>Associate Professor, Department of Oral Pathology and Microbiology, Sumandeep Vidyapeeth, K M Shah Dental College and Hospital, Pipariya, Vadodara, Gujarat State, India.

<sup>2</sup>Senior lecturer, Department of Oral Pathology and Microbiology, Sumandeep Vidyapeeth, K M Shah Dental College and Hospital, Pipariya, Vadodara, Gujarat State, India.

<sup>3</sup>Professor, Department of Oral Pathology and Microbiology, Sumandeep Vidyapeeth, K M Shah Dental College and Hospital, Pipariya, Vadodara, Gujarat State, India.

✉ Corresponding author:  
B.S. Manjunatha, Associate Professor, Dept of Oral Pathology, KM Shah Dental College Sumandeep Vidyapeeth Pipariya--391760 Waghodia Vadodara, Gujarat, India. drmanju26@hotmail.com

Received: 15 April 2010  
Accepted: 20 October 2010

## Abstract:

Lipomas are rare benign soft tissue mesenchymal neoplasms in the oral cavity, representing 1% of all benign oral tumors. Fibrolipoma (FL), an uncommon, histological variant of the classic lipoma, mostly affects the buccal mucosa. Very few cases of FL have been reported in the English literature. To the best of our knowledge a review of the English literature showed 33 cases of FL affecting the oral cavity.

The diagnosis and differentiation of FL with clinically similar lesions such as fibroma, mucocele and pleomorphic adenoma are very essential for a correct treatment plan and complete follow-up. Due to the rarity of oral cavity fibrolipoma reports, three cases and a review of literature is presented here.

**Key Words:** Lipoma; Buccal Mucosa; Adipose Tissue Neoplasms; Adipocytes

*Journal of Dentistry, Tehran University of Medical Sciences, Tehran, Iran (2010; Vol.7, No.4)*

## INTRODUCTION

Lipoma is a benign mesenchymal soft tissue neoplasm of mature adipocytes of which of about 20% occurs in the head and neck region. However, oral lipomas comprise of only 1% to 4% of cases and these usually present as painless, well-circumscribed, slow-growing submucosal mass or superficial lesions, mainly in the buccal mucosa.

These are usually composed of mature adipocytes, surrounded by a thin fibrous capsule [2]. Oral lipoma is usually slow growing and rarely recurs after surgical treatment. Hence, the prognosis of these benign tumors is considered good [3, 4]

Histologically, lipomas are classified as simple lipoma or variants such as fibrolipoma, spindle

cell lipoma, intramuscular or infiltrating lipoma, angioliipoma, salivary gland lipoma (sialoliipoma), pleomorphic lipoma, myxoid and atypical lipomas [5,6].

FL of the oral cavity has been infrequently reported. To the best of our knowledge, the review of the English literature till early 2009 revealed a total of 33 cases of intraoral FL (Table 1).

As oral lipomas are relatively rare, few large case series have been published in the English literature [1,7-9].

A review by Fregnani et al. [1] revealed the buccal mucosa as the most common site of occurrence and the tongue as the second most common site.

One case of FL has been reported in the lower

lip area. A male predilection was noted from the data available in the literature (Table 1). However, in contrast some have also shown a female predilection [9].

The time of development of the tumor to diagnosis is often unknown but has been reported to vary from two months to 21 years [10].

The mean age of occurrence of FL is 34 years with a range from 3 to 56 years. In this present case report we analyze three cases of fibrolipoma and discuss the clinico-pathological features.

### CASE REPORT

Two male patients (cases 1 & 2) came to KM Shah Dental College and Hospital, Vadodara from September 2008 to March 2009 and presented with chief complain of growth in the right cheek of at least 6 months duration. One male patient in May 2009 reported to the out patient department for a set of complete denture for his upper edentulous jaw and was unaware of such a lesion on the palate.

The detailed clinical features of all three cases of oral fibrolipoma comprising age and gender of the patient, size, appearance and duration of the lesion are summarized in Table 2. All three patients were male, with the mean age of 66.6 years (range, 55 to 75 years).

The chief complaint was a solitary painless nodule in all three cases of which two were seen on the buccal mucosa (case 1 and 2) and one was on the palate (case 3) (Fig 1). The size of the tumor varied from 1 cm to 3.0 cm with a mean dimension of 1.8 cm. Clinically, all cases presented as painless, well-circumscribed, sub-mucosal nodules, soft to semi-firm in consistency and pale pinkish in color similar to the adjacent normal mucosa.

The lesion was sessile in two cases (Fig 2) and pedunculated in one case.

The duration of this lesion ranged from 6 years to 10 years. It is interesting to note that clinically all cases were diagnosed as 'fibroma'. Histopathologically, all cases revealed admix-

ture of round to oval, variably sized typical adipocytes interspersed with dense collagen fibers in a connective tissue stroma (Figs 3 & 4). Stratified squamous epithelium covering the surface was also seen in these cases.

The microscopic diagnosis of 'fibrolipoma' was given for all three cases.

A follow-up of 6 months in all three cases found no evidence of disease.

### DISCUSSION

Lipomas are benign soft tissue neoplasms of adipose tissue origin and are relatively uncommon in the oral cavity, representing about 1% to 5% of all benign oral lesions [1]. The first description of oral lipoma was provided in 1848 by Roux in a review of alveolar masses which he referred it as a 'yellow epulis' [11]. Lipomas can occur in various anatomic sites including the major salivary glands and various parts of the mouth.

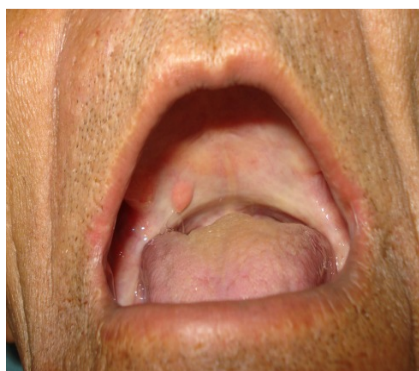The English literature review showed a variable distribution of these intraoral lipomas but approximately half were related to the cheek and the remaining were found in the tongue, floor of the mouth, lips, palate and gingiva [12-16] Generally, oral lipomas have been reported to occur in all ages but are frequently seen after 40 years of age [13].

Hatziotis, in a review of the literature, reported that 80% of the patients were over 40 years of age, 64% were over 50 years and 40% over 60 years with an age range of 2-87 years [17].

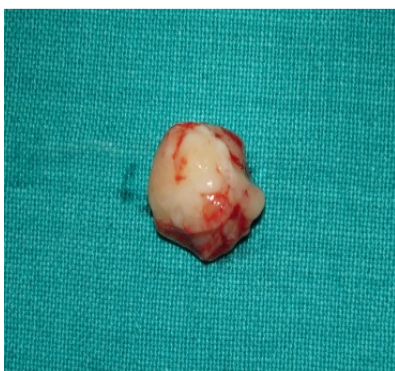Fibrolipoma is a benign soft tissue tumor that rarely occurs in the oral and maxillofacial regions, and is classified as a variant of conventional lipoma by the WHO [18,19].

FL is a histological variant of simple lipoma and differs from the classic variant, posed of mature adipose tissue interspersed by bands of connective tissue.

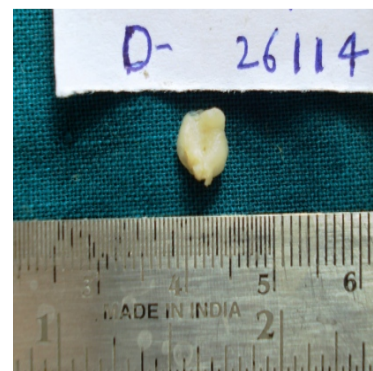FL of the oral cavity has been infrequently reported. To the best of our knowledge, the review of the English Fibrolipoma usually literature till early 2009 revealed a total of 33 cases



**Fig 1.** Photograph showing lesion in the palate in case-3.



**Fig 2.** Macroscopic appearance of the lesion in case-2.



**Fig 3.** Microphotograph showing round to oval shaped adipocytes admixed with fibrous connective tissue stroma (H & E Stain, 100X magnification).

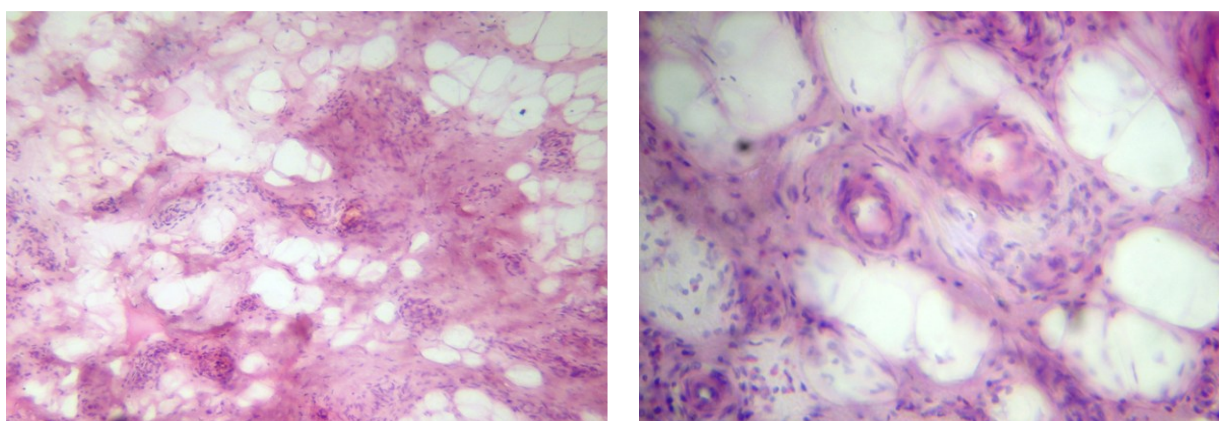
manifests as long-lasting sessile of intraoral FL. A very recent study showed that 27% of 41 cases of oral lipomas were FL [9]. Fibrolipomas have been reported in the esophagus, pharynx, colon, trachea, larynx and

other locations [20,21]. round to ovoid sub-mucosal nodules affecting the buccal mucosa, tongue, labial mucosa, parotid region and palate, as shown by our literature review (Table 1).

**Table 1.** Summary of previous reported cases of oral fibrolipoma

<i>Author</i>	<i>Age /Sex*</i>	<i>Site</i>	<i>Duration</i>	<i>No. of Cases</i>	<i>Recurrence</i>
Saitoh et al 1995 <sup>16</sup>	3/F	Parotid	NA	1	NED 3 years
Dattilo et al 1996 <sup>14</sup>	45/M	Tongue	10 years	1	NA
Epivatianos et al 2000 <sup>13</sup>	NA	Tongue	NA	2	NA
Fregnani et al 2003 <sup>1</sup>	NA	Buccal Mucosa	NA	18	NED 26.5 months
Furlong MA et al 2004 <sup>7</sup>	NA	Parotid Buccal mucosa	NA	2	NA
Bandéca MC 2007 <sup>23</sup>	42/M	Lower lip	NA	1	NED 60 months
Capodiferro S et al 2008 <sup>15</sup>	43/M	Labial mucosa	8 months	1	NED 10 months
Freitas et al 2009 <sup>9</sup>	56/F	Buccal mucosa	NA	7	NA

\*Age→in years, M→ Male, F→Female, NED--no evidence of disease; NA--not available



**Fig 4.** Microphotograph showing round to oval shaped adipocytes admixed with dense collagenous fibers and fibroblasts (H & E Stain, 400X magnification).

According to the literature, it is difficult to value the real incidence of this neoplasm because it appears as painless and slow-growing clinical appearance. In reality, the patient refers to the clinician only when it becomes symptomatic and for aesthetic or functional problems. In a large series of studies on lipoma by Fregnani et al and de Feitas et al, 39% and 27% were reported microscopically as fibrolipoma, respectively [1,9]. Whereas other similar case series have reported a very low incidence of fibrolipoma cases [2,13,17]. These differences could be explained by real racial and geographic characteristics or simply by different diagnostic criteria.

The size of the tumor depends on the location of the lesion, but rarely exceeds 25 mm in diameter [22].

Lipomas are freely mobile in relation to the surrounding tissues and may clinically have a semi-lucent yellow color because of the thin overlying epithelium.

In some cases it is possible to observe the superficial blood vessels as well.

The consistency of this lesion varies from soft to firm, depending on the quantity and distribution of fibrous tissue and the depth of the tumor [23].

In some cases, a sensation of fluctuation may be recognized in these tumors [24].

**Table 2.** Clinical details of our cases

<i>Case</i>	<i>Age/ Gender*</i>	<i>Site*</i>	<i>Size</i>	<i>Appearance</i>	<i>Symptoms</i>	<i>Duration</i>	<i>Consistency</i>
Case 1	75 /M	Right BM	3 cm	Pedunculated	None	10 years	Soft
Case 2	55 /M	Right BM	1 cm	Sessile	None	6 months	Firm
Case 3	70 /M	Soft Palate	1.5 cm	Sessile	None	6months	Soft

\*Age→in years, M→ Male, F→Female, BM→ Buccal mucosa

nor salivary gland tumors either benign or malignant. We diagnosed fibrolipoma based on the presence of mature adipose tissue interspersed by bands of broad or fascicles of dense connective tissue fibers with the capsule.

Lipoma and fibrolipoma both are usually well circumscribed and have a thin capsule. Fibrolipoma differs from the classic variant because the mature adipose tissue is interspersed by bands of connective tissue.

The proliferative activity of FL revealed a greater proliferative rate than other simple variants which indicates the need for accurate diagnosis of such variants with high proliferative activity and further encourages similar studies [1].

Furthermore liposarcoma of the oral cavity is exceedingly rare, but this entity cannot be distinguished from its benign counterpart at clinical examination [15]. Therefore, accurate histological examination is mandatory, and the differential diagnosis is based on the detection of a lack of lobular architecture, areas of prominent fibrosis and, most importantly, on the presence of multivacuolated adipose cells with indented nuclei (lipoblasts), which are typically present in liposarcoma in variable proportions. The lesion in all three patient was surgically excise without any complications. Post-operative follow-up of six months showed no recurrence in any of the cases. The data from the literature review showed no evidence of recurrence in any reports and the duration of follow-up ranged from minimum 10 months to maximum 5 years. The average follow-up period in the literature review was approximately 3 years.

However, two cases of giant FL [25,26] have not been considered in the present report. These contradictory findings authenticate the need for a meticulous analysis of intra-oral FL cases.

## **CONCLUSION**

Microscopic/histological findings provided by

Oral Pathologists should be combined with clinical features for accurate diagnosis. FL represents a distinct clinico-pathologic and biologic entity with an increased growth potential compared with the classic lipoma and not associated with any syndrome and with a low recurrence rate.

The case presented here adds to the existing few cases of FL reported in English literature. Lesions appearing alike clinically often present diverse and overlapping histopathological features and in such cases, they pose a diagnostic dilemma for general dentists. So, the authors recommend that histopathological examination of excised tissue is a gold standard investigative procedure along with consultation with an Oral Pathologist for correct diagnosis has a very significant role in providing successful treatment and preventing any malignant transformation, as recommended earlier. It is very much essential for new cases to be documented and followed carefully so that more accurate, better treatment modalities could be drawn to prevent further damages.

## **ACKNOWLEDGMENTS**

The authors wish to thank Chancellor and Pro-Chancellor, Sumandeep Vidyapeeth, Pipariya, Vadodara, India, for all the encouragement and support given during the study.

## **REFERENCES**

- 1-Fregnani ER, Pires FR, Falzoni R, Lopes MA, Vargas PA. Lipomas of the oral cavity: clinical findings, histological classification and proliferative activity of 46 cases. *Int J Oral Maxillofac Surg.* 2003 Feb; 32(1):49-53.
- 2-deVisscher JG. Lipomas and fibrolipomas of the oral cavity. *J Maxillofac Surg.* 1982 Aug; 10(3):177-81.
- 3-Papanayotou PH, Kayavis IG, Trigonidis G. Lipomas of the oral cavity. Report of three cases. *J Oral Med.* 1983 Jan-Mar; 38(1):37-9.
- 4-Perri de Carvalho AC, Martinelli C, Sanches MG. Congenital lipoma in the oral cavity. *A*

- case report. *Quintessence Int.* 1987 Nov; 18(11):799-802.
- 5-Gnepp DR, Editor. *Diagnostic surgical pathology of the head and neck*. Philadelphia: WB Saunders; 2001:191-4.
- 6-Weiss SW, Goldblum JR, Editors. *Benign lipomatous tumors*. In: *Enzinger and Weiss's soft tissue tumors*. 4th ed. St. Louis: Mosby; 2001. p. 571-639.
- 7-Furlong MA, Fanburg-Smith JC, Childers EL. Lipoma of the oral and maxillofacial region: site and subclassification of 125 cases. *Oral Surg Oral Med Oral Pathol Oral Radiol Endod.* 2004 Oct; 98(4):441-50.
- 8-Seldin HM, Seldin SD, Rakower W, Jarrett WJ. Lipomas of the oral cavity: report of 26 cases. *J Oral Surg.* 1967 May; 25(3):270-4
- 9-deFreitas MA, Freitas VS, de Lima AA, Pereira FB Jr, dos Santos JN. Intraoral lipomas: a study of 26 cases in a Brazilian population. *Quintessence Int.* 2009 Jan; 40(1):79-85.
- 10-MacGregor AJ, Dyson DP. Oral Lipoma. *Oral Surg Oral Med Oral Pathol.* 1966 Jun; 21(6):770-7.
- 11-Roux M. On exostoses: their character. *Am J Dent Sci.* 1848; 9:133-4.
- 12-Vindenes H. Lipomas of the oral cavity. *Int J Oral Maxillofac Surg.* 1978 Jun; 7(3):162-6.
- 13-Epivatianos A, Markopoulos AK, Papanayotou P. Benign tumors of adipose tissues of the oral cavity: A clinicopathologic study of 13 cases. *J Oral Maxillofac Surg.* 2000 Oct; 58(10): 1113-8.
- 14-Dattilo DJ, Ige JT, Nwana EJ. Intraoral lipoma of the tongue and submandibular space: report of a case. *J Oral Maxillofac Surg.* 1996 Jul; 54(7):915-7.
- 15-Saverio Capodiferro, Eugenio Maiorano, Francesco Scarpelli and Gianfranco Favia. Fibrolipoma of the lip treated by diode laser surgery: A case report. *J Med Case Reports.* 2008 Sep 12; 2:301.
- 16-Saitoh Y, Hama T, Ishizaka S, Kawaguchi M, Terazono T, Hyuga M, et al. Fibrolipoma of the parotid in a child. *Am J Otolaryngol.* 1995 Nov-Dec; 16(6):433-5
- 17-Hatziotis JC. Lipoma of the oral cavity. *Oral Surg Oral Med Oral Pathol.* 1971 Apr; 31(4): 511-24.
- 18-Fletcher CDM, Mertens F, Unni KK: Adipocytic tumors. In *Pathology and Genetics: Tumors of Soft Tissue and Bone*. World Health Organization Classification of Tumors, Lyon, France: IARC Press; 2002:9-46.
- 19-Rosai J. *Ackerman's Surgical Pathology*. Volume 2, St Louis Missionary: Mosby; 1996: p2053-4.
- 20-Pérez B, Campos ME, Rivero J, López-Aguado D. Giant esophageal fibrolipoma. *Otolaryngol Head Neck Surg.* 1999 Mar; 120(3):445-6.
- 21-Nicoli F, Balli C, Pezza V. A case of giant fibrolipoma of the esophagus. Diagnosis using computerized tomography and double-contrast esophagography. [Article in Italian]. *Radiol Med.* 1990 Jul-Aug; 80(1-2):99-102.
- 22-Rapidis AD. Lipoma of the oral cavity. *Int J Oral Maxillofac Surg.* 1982 Feb; 11(1):30-5.
- 23-Bandéca MC, de Pádua JM, Nadalin MR, Ozório JE, Silva-Sousa YT, da Cruz Perez DE. Oral soft tissue lipomas: a case series. *J Can Dent Assoc.* 2007 Jun; 73(5):431-4.
- 24-Tan MS, Singh B. Difficulties in diagnosing lesions in the floor of the mouth—report of two rare cases. *Ann Acad Med Singapore* 2004 Jul; 33(4 Suppl):72-6.
- 25-Kiehl RL. Oral fibrolipoma beneath complete denture. *J Am Dent Assoc.* 1984 Apr; 100(4):561-2.
- 26-Oliveros-Chaparro C, Bogarin-Rodriguez J, Sanchez-Mendez M. Giant fibrolipoma of the floor of mouth. Presentation of a clinical case. [Article in Spanish]. *Invest Clin.* 2001 Jun; 42(2):147-52.