

Historical analysis of the diagnosis and management of femoroacetabular impingement prior to the year 2000: a systematic review

Tushar Tejpal¹, Ajaykumar Shanmugaraj², Jeffery Kay², Nicole Simunovic^{2*} and Olufemi R. Ayeni^{2,3}

¹Faculty of Health Sciences, McMaster University,

²Division of Orthopaedic Surgery, Department of Surgery and

³Department of Health Research Methods, Evidence, and Impact, McMaster University Medical Centre, 1200 Main Street West, 4E15, Hamilton, ON L8N 3Z5, Canada.

*Correspondence to: O. R. Ayeni. E-mail: ayenif@mcmaster.ca

Submitted 5 June 2020; Revised 31 August 2020; revised version accepted 27 October 2020

ABSTRACT

This systematic review aims to assess the diagnosis, indications and treatment of femoroacetabular impingement (FAI) prior to the year 2000 and to determine if historical concepts remain applicable today. PUBMED, MEDLINE and EMBASE were searched for literature evaluating the diagnosis/treatment of FAI prior to 2000. Cadaver/non-human, non-English and review studies were excluded. Quality assessment was performed using the Methodological Index for Non-Randomized Studies. Nine studies comprising 307 patients [315 hips; mean age of 32.6 ± 2.4 years (range, 12–58)] were included. Patients reported groin pain. Magnetic resonance arthrography (MRA; $n = 76$) and the anterior impingement test (AIT) ($n = 88$) were used to diagnose impingement. Surgical dislocation with a trochanteric flip osteotomy ($n = 237$) and Bernese periacetabular osteotomy ($n = 40$) were common treatments. Pain and range of motion improved for patients. Overall complication rate was 35% ($n = 99$), with heterotopic ossification ($n = 79$) most commonly reported. Prior to 2000, there was low quantity and quality of research on the diagnosis/management of FAI. Diagnostic evaluation was primarily through clinical examination (i.e. groin pain and AIT). MRA was occasionally used to detect labral degeneration; however, utilization of computed tomography (CT) and diagnostic injections were not reported. Surgical dislocation and osteotomies of the acetabulum yielded desirable short-term clinical outcomes with a moderate complication rate. No study reported using arthroscopy for FAI management prior to 2000. Clinicians today can learn from historical principles (i.e. clinical diagnosis of FAI, management with surgical correction of femoral head–neck offset) while applying novel techniques (i.e. CT, injections, arthroscopic surgical techniques and rehabilitation) to improve patient outcomes.

Level of Evidence: IV (systematic review of III and IV evidence).

INTRODUCTION

Femoroacetabular impingement (FAI) is a clinical syndrome in which there are abnormalities in the anatomical structure of the femoral head and/or the acetabulum [1]. Described by Ganz *et al.* [1] in 2003, there are three patterns of abnormality that can occur in FAI: cam, pincer and mixed. Abnormal/aspherical morphology of the

proximal femur is characteristic of cam deformity, while pincer deformity is a result of over-coverage of the femoral head by the acetabulum [1]. Mixed FAI is a combination of both cam and pincer deformity [1]. These morphological abnormalities result in non-typical contact between the femur and the acetabulum during hip motion [1]. This syndrome can lead to cartilage and labral damage, along

with hip pain [1]. Over time, such damage can progress to degenerative disease, with increasing evidence suggesting FAI in the development of hip osteoarthritis (OA) [2].

Pediatric hip disorders, high-impact athletic activities and genetic factors have all been proposed as possible mechanisms for the development of FAI [2, 3]. The prevalence of FAI is roughly 10–15% in the general adult population, with children that participate in high-intensity sports being ten times more likely to develop cam deformity than age-matched counterparts [4]. The prevalence of symptomatic athletes is 55%, much greater than the general adult population [4].

Physical examination and assessment of range of motion (ROM) is typically conducted to assess for FAI [5, 6]. The flexion, adduction and internal rotation (FADIR) test is most commonly used by surgeons [5]. Additionally, magnetic resonance arthrography (MRA) is recommended to evaluate the labrum to verify the presence of FAI [7]. Non-operative and surgical options exist for treatment of FAI [4]. Non-operative management includes activity modification, physical therapy and pain medication [4]. If non-operative techniques fail, a number of hip preservation techniques exist to relieve symptoms of pain, improve function and decrease risk/progression of hip OA [4]. These include open surgical hip dislocation, reverse periacetabular osteotomy, mini-open direct anterior approach and hip arthroscopy [4].

Prior to 2003, little has been reported regarding the diagnosis and treatment of FAI [8]. The idea that impingement causes hip pain and reduces ROM was initially reported by Smith-Pedersen in 1936 [9]. Smith-Pedersen performed acetabular rim trimming and femoral neck osteoplasty in patients that presented with acetabular protrusion and chronic slipped femoral capital epiphysis (SCFE) [9]. In 1965, the first description of femoral morphology leading to hip OA, was confirmed by Murray [10]. Murray described tilt deformities of the proximal femur, deformities of SCFE and Perthes deformity as causes of hip OA [10]. Femoral deformity gained more attention, in the 1980s, with Harris' description of pistol grip deformity [10]. An understanding of FAI culminated once the surgical hip dislocation technique was established [10].

As FAI has gained more attention, there has been a rapid rise in publications corresponding to FAI-related research [11]. A review, published by Ayeni *et al.* [12] in 2011, reported that between the years 2005 and 2010 there were a total of 298 relevant studies and a 5-fold increase in the number of publications related to FAI. More recently, a systematic review published in 2016, which used the same search criteria as Ayeni *et al.* found a total of 1066 studies related to FAI that were published between 2011

and 2015, 3.5 times more articles in comparison to 2005–10 [13]. As FAI is a relatively new clinical syndrome described in the field of orthopedics, there has been rapid increase in research related to this syndrome; however, to date, there has not been any systematic review that has critically analyzed the diagnosis, management and treatment of FAI prior to the year 2000. Hence, the purpose of this study was to systematically assess methods by which clinicians diagnosed and treated FAI prior to 2000 and to determine if historical treatment concepts remain applicable to current practices. We hypothesize that there will be a low quantity and quality of research available on FAI prior to the year 2000. Furthermore, we predict that clinical diagnosis of FAI would be similar to current practices, however, advanced diagnosis and treatment techniques would differ.

MATERIALS AND METHODS

Search strategy

Three online databases (PUBMED, EMBASE and MEDLINE) were searched for studies examining FAI from database inception to 31 December 2005. The search terms included 'impingement', 'femur', 'acetabulum', 'surgical' and other similar terms (Supplementary Appendix Table SAI). The search terms were also entered into Google Scholar and a hand search was performed to ensure that the articles were not missed. The research question and inclusion/exclusion criteria were established *a priori*. Inclusion criteria included: (i) all levels of evidence; (ii) studies assessing the diagnosis of FAI; (iii) studies assessing the treatment of FAI; (iv) those that included only patients treated prior to the year 2000 and (v) human subjects. The exclusion criteria included: (i) cadaver/non-human studies; (ii) review articles; and (iii) non-English studies. The search was extended to 2005 to ensure that studies that treated patients prior to the year 2000 were included despite being published after 2000. Studies had to explicitly state the year the patients were treated to determine eligibility.

Study screening

A systematic screening approach in accordance with the Preferred Reporting Items for Systematic Reviews and Meta-analyses (PRISMA) and Revised Assessment of Multiple Systematic Reviews guidelines were employed from title/abstract to full text screening stages in duplicate by two independent reviewers [14]. Title and abstract screening was conducted concurrently. Discrepancies were discussed and resolved with input by a third reviewer. The references of included studies were also screened using the

same systematic approach to capture any additional relevant articles.

Quality assessment

Using the *Journal of Bone & Joint Surgery (JBJS)* classification system for literature in the field of orthopedics, the level of evidence (I–IV) for each study was determined by the two reviewers independently and in duplicate [15]. The methodological quality of non-randomized comparative studies was evaluated using the Methodological Index for Non-randomized Studies (MINORS) [16]. A score of 0, 1 or 2 is given for each of the 12 items on the MINORS checklist with a maximum score of 16 for non-comparative studies and 24 for comparative studies. Methodological quality was categorized *a priori* as follows: a score of 0–8 or 0–12 was considered poor quality, 9–12 or 13–18 was considered fair quality, and 13–16 or 19–24 was considered excellent quality, for non-comparative and comparative studies, respectively.

Data abstraction

Two reviewers independently abstracted relevant data from included articles and recorded the data onto a Google Spreadsheet designed *a priori*. Demographic data included author, year of publication, sample size, study design, level of evidence and patient demographics (e.g. gender, age, etc.). Information regarding indications for surgery, rehabilitation protocols and post-operative outcomes (surgical and radiographic), including complications was documented.

Statistical analysis

Due to statistical and methodological heterogeneity, a meta-analysis could not be performed, and the results were summarized descriptively. Descriptive statistics such as mean, range and measures of variance (e.g. standard deviations, 95% confidence intervals, CI) are presented where applicable. The intra-class correlation coefficient (ICC) was used to evaluate inter-reviewer agreement for the MINORS score. A kappa (κ) statistic was used to evaluate inter-reviewer agreement at all screening stages. Agreement was categorized *a priori* as follows: ICC/ κ of 0.81–0.99 was considered as almost perfect agreement; ICC/ κ of 0.61–0.80 was substantial agreement; ICC/ κ of 0.41–0.60 was moderate agreement; 0.21–0.40 fair agreement and an ICC/ κ value of 0.20 or less was considered slight agreement.

RESULTS

Study characteristics

The initial search from all databases yielded a total of 8698 articles. After excluding 912 duplicates, a systematic screening process yielded a total of nine articles for inclusion (Fig. 1). The nine studies included two retrospective cohorts and seven case series. The included studies were conducted in Switzerland ($n=8$) and the United States ($n=1$).

Patient characteristics

Of the included studies, a total of 307 patients (315 hips) were included. Among the included patients 65.1% ($n=82/126$) were male. The mean age of the patients was 32.6 ± 2.4 years (range, 12–58) with a mean follow up time of 17.0 ± 3.7 (SD) months. Of the four studies ($n=37$) that reported information pertaining to lost to follow up, only one (2.7%) patient was lost to follow up (Table 1) [17–20]. All patients had signs and symptoms of anterior impingement. Of the included patients, 31 (10.0%) patients had been treated for other conditions including: SCFE ($n=13$, 41.9%), femoral neck fractures ($n=9$, 29%), Legg–Calve–Perthes disease ($n=5$, 16%) and hip dysplasia ($n=4$, 13%).

Study quality

There was substantial agreement amongst reviewers at the title/abstract ($\kappa=0.742$; 95% CI, 0.687–0.796) and full-text ($\kappa=0.754$; 95% CI, 0.694–0.814) screening stages. The mean MINORS score across all non-comparative studies was 10 ± 1.2 (SD) indicating fair quality of evidence. The comparative study had a score of 15, also indicating fair quality of evidence. All studies provided a clearly stated aim for their study; however, no study provided blind evaluation of endpoints or reasons for not blinding. There was almost perfect agreement amongst the reviewers for the quality assessment using the MINORS criteria (ICC = 0.964; 95% CI 0.942–0.985; Table 1).

Indications

None of the included studies explicitly stated indications for surgical management of FAI. One study used clinical symptoms of groin pain, the anterior impingement test (AIT), pre-operative radiographs and MRA to determine the presence of FAI [21]. Two studies assessed for impingement using complaints of groin pain, AIT and MRA [20, 24]. One study used groin pain, the AIT and pre-operative radiographs for assessment of impingement [26]. One study used symptoms of groin pain and pre-operative radiographs as indications for FAI [19]. Two studies only

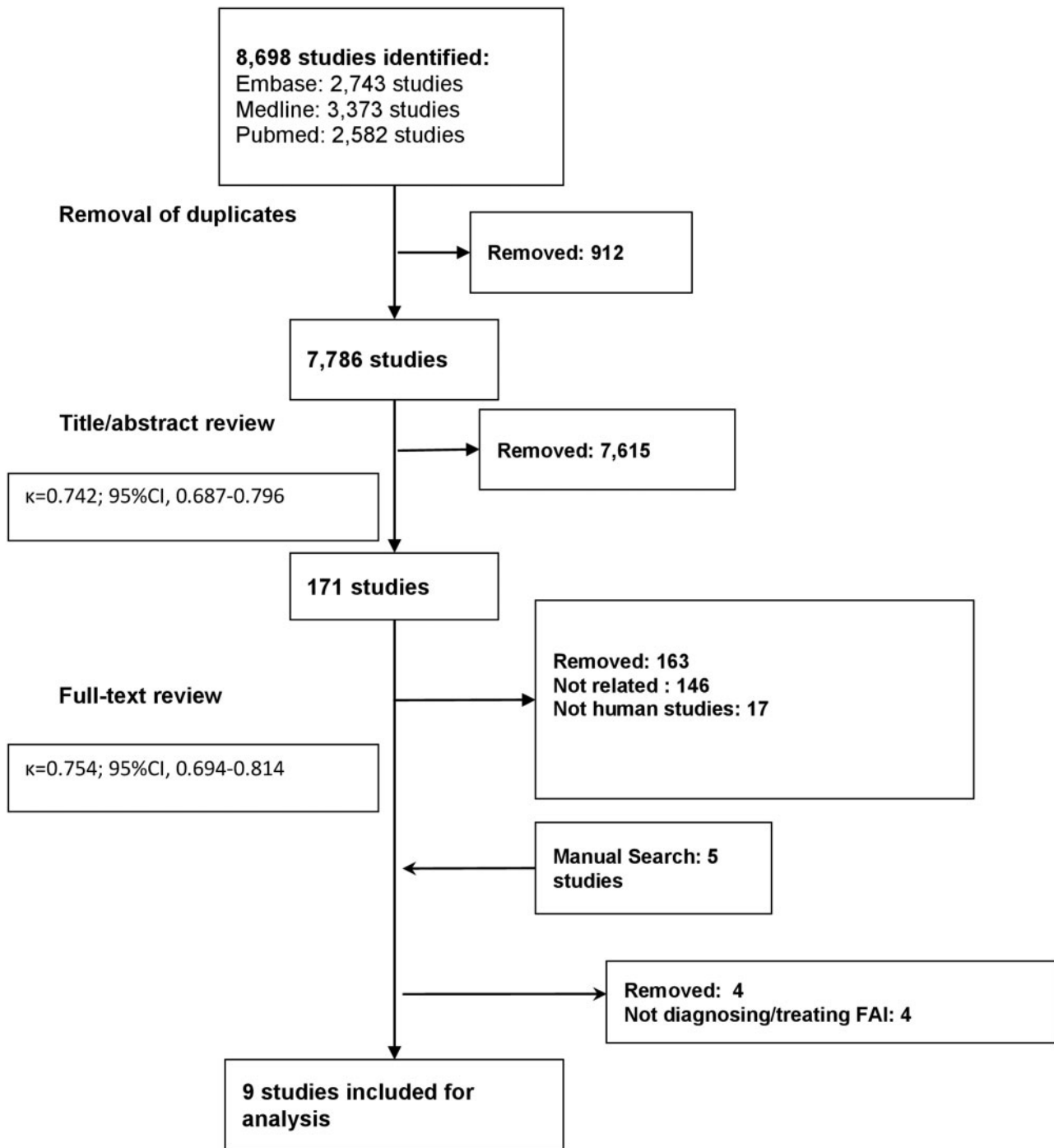


Fig. 1. PRISMA flow diagram.

used symptoms of groin pain [17, 25] while one study only used MRA [18] to confirm presence of FAI.

Diagnostic techniques

All studies except for one (88.9%) reported symptoms of pain [17, 19–21, 24–26]. Within these studies, all patients

reported groin pain ($n = 119$, 100%; Table II). Additionally, nine patients (7.6%) also complained of trochanteric pain, and three (2.5%) had pain in the gluteal region. Symptoms of pain were not explicitly reported in 188 patients [22].

Impingement was assessed using the impingement test in four studies ($n = 88$, 28.7%) [20, 21, 24, 26]. The test

Table I. Study characteristics

Primary author, year	Study design (level of evidence)	Study sample size	Mean age (years)	Mean follow-up (months)	Study quality (MINORS score)
Eijer [17], 2000	Retrospective study (III)	9	33.3 (12–64)	16.4 (range 11–25)	10
Myers [18], 1999	Case series (IV)	5	30.2	NR	7
Snow [19], 1993	Case series (IV)	4	17.6 (13–19 years)	34 (8–81)	12
Beck [20], 2004	Retrospective study (III)	19	36 (21–52)	56.4 (50.4–62.4)	14
Siebenrock [21], 2003	Case series (IV)	22	23 (14–41)	23 (24–49)	12
Ganz [22], 2001	Case series (IV)	188	33.5 (16–58)	NR	9
Ganz [23], 1997	Case series (IV)	24	40.3 ± 8	NR	15
Leunig [24], 1997	Case series (IV)	23	40 ± 2	NR	9
Leunig [25], 2000	Case series (IV)	13	13 ± 2	NR	7

NR, not reported.

was described as evoking acute pain during physical examination by flexion, adduction and internal rotation in 70–90°, forcing the anterior neck area against the acetabular rim [21]. All patients, except for one, tested positive on the AIT (Table II).

Additionally, pre-operative radiographs were used for the diagnosis of impingement by three (33.3%) studies to examine the morphological features of the anterior head to neck junction [19, 21, 26]. These studies found a non-spherical head and a short/small head–neck ratio as morphological features favoring anterior impingement [19, 21, 26]. Each study reported using anteroposterior and lateral radiographic views [19, 21, 26]. In one study, mean femoral anteversion ($9.68 \pm 3.7^\circ$) and mean impingement depth ($17.5 \pm 4.2^\circ$) were reported (Table II) [26].

Four studies (44.4%) used MRA to determine signs of impingement in the form of degenerative or torn labrum and associated cartilage damage [18, 20, 21, 24]. One study (11.1%) used magnetic resonance imaging (MRI) to detect labral lesions [17]. Four studies (44.4) did not report such information [19, 22, 25, 26]. Labral degeneration/tears were reported in 84 patients (84.5%) with additional cartilage alterations reported in 26 patients (26.3%; Table II).

Surgical techniques

In the majority of studies (five studies, $n = 237$), authors surgically dislocated the hip and created an improved femoral head–neck offset by resection osteotomy of the cam lesion [17, 18, 20, 22, 25]. The resection osteotomy was

performed after dislocation of the femoral head using a Kocher–Langenbeck approach with a trochanteric flip and an anterior arthrotomy [17, 18, 20, 22, 25]. In one of these studies, prior to resection osteotomy, an anterior joint decompression by soft tissue resection only was initially used to treat impingement, however this was not deemed to be effective [18]. In two studies ($n = 40$), acetabular reorientation was performed with a Bernese periacetabular osteotomy [21, 24]. The procedure was conducted through a modified Smith–Peterson approach [21, 24]. Two orthogonal Schanz screws were placed in the superior portion of the acetabular fragment to allow for rotation of the fragment [21, 24]. The fragment was fixed temporarily with Kirschner wires [21, 24]. An intraoperative T-shaped arthrotomy was performed to evaluate labral and cartilaginous lesions [21, 24]. In one study ($n = 4$) individuals underwent arthroscopic debridement and proximal femoral osteotomy [19]. One study ($n = 24$) did not provide surgical treatment for impingement.[26] Four studies reported using capsulotomy techniques, [20, 22, 24, 25] with two specifying that use of a z-shaped capsulotomy to expose the hip for examination of impingement (Table III) [20, 25].

Rehabilitation protocol

One study ($n = 9$) reported rehabilitation protocol following surgical treatment of impingement. Partial weight bearing was allowed post-operatively for a minimum of 8 weeks [17]. Low-molecular weight heparin was prescribed

Table II. Clinical and radiographic diagnosis of FAI

<i>Primary author, year</i>	<i>Clinical diagnosis</i>	<i>Radiographic diagnosis</i>
Eijer [17], 2000	Pain: patients complained of groin pain on flexion of hip	MRI for detection of labral lesions
Myers [18], 1999	Pain: patients complained of groin pain on flexion of hip	MRA for detection of labral lesions
Snow [19], 1993	Pain: patients complained of groin pain on internal rotation of hip	Pre-operative radiographs to examine morphological features of the anterior head to neck junction
Beck [20], 2004	Pain: patients complained of groin pain AIT: positive	MRA for detection of labral lesions
Siebenrock [21], 2003	Pain: patients complained of groin pain following physical activity AIT: Positive	MRA for detection of labral lesions Pre-operative radiographs to examine morphological features of the anterior head to neck junction
Ganz [22], 2001	NR	NR
Ito [26], 2001	Pain: patients complained of groin pain AIT: positive	Pre-operative radiographs to examine morphological features of the anterior head to neck junction
Leunig [24], 1997	Pain: patients complained of groin pain AIT: positive (except for one patient)	MRA for detection of labral lesions
Leunig [25], 2000	Pain: patients complained of groin pain, exacerbated by vigorous activity	NR

until full weight bearing [17]. Flexion >than 70°, active abduction and adduction were not allowed until final follow-up [17]. The remaining eight studies did not report rehabilitation protocols.

Clinical and radiographic outcomes

All studies reported improvement in ROM and pain from pre-operative values (Table III). Two studies reported quantitative results regarding ROM [17, 21]. In one study, wherein patients underwent a Bernese periacetabular osteotomy, mean flexion improved from 99° (90–110°) to 106° (90–120°; $P=0.014$), internal rotation improved from 11° (0–30°) to 21° (0–40°; $P=0.006$) and adduction improved from 22° (10–40°) to 30° (30–40°; $P=0.0117$) post-operatively [21]. No statistical significance was found in extension, external rotation and abduction as pre- and post-operative values remained the same at 1° (0–10°), 33° (20–70°) and 35° (20–50°), respectively [21]. In another study, wherein surgical dislocation and

resection was performed, mean flexion improved from 92° (80–120°) to 103°, internal rotation improved by from 7° (–10 to 20°) to 16°, abduction improved from 30° (20–50°) to 36° [17]. External rotation and adduction remained the same at 0° (0–0°) and 17° (20–50°), respectively [17]. Post-operative ranges and values for statistical significance were not provided (Table III) [17].

Two studies reported functional outcomes using the Merle d'Aubigne score [20, 21]. After treatment of impingement through surgical dislocation and resection osteotomy, one study reported significant improvements ($P=0.015$) in the Merle d'Aubigne score from a pre-operative score of 14.1 to a post-operative score of 16.5 (measures of variance were not provided) [20]. In another study, in which patients underwent a Bernese periacetabular osteotomy, the average Merle d'Aubigne score increased from 14.0 (range, 12–16 points) to 16.9 (range, 15–18 points) post-operatively (Table III) [21].

Table III. Surgical techniques, outcomes and complications

Primary author, year	Surgical techniques	Outcomes	Complications
Eijer [17], 2000	Surgical dislocation of hip and created an improved femoral head–neck offset by resection osteotomy of the CAM lesion Resection osteotomy was performed using a Kocher–Langenbeck approach with a trochanteric flip and an anterior arthrotomy	Pain: improved for all patients ROM: mean flexion improved by 11° (<i>P</i> -value NR) Internal rotation improved by 9° (<i>P</i> -value NR) Abduction improved by 6° (<i>P</i> -value NR) External rotation and adduction remained the same (<i>P</i> -value NR)	Pain persisted in one patient
Myers [18], 1999	Surgical dislocation of hip and created an improved femoral head–neck offset by resection osteotomy of the CAM lesion Resection osteotomy was performed using a Kocher–Langenbeck approach with a trochanteric flip and an anterior arthrotomy	Pain: Improved for all patients ROM: Improved for all patients	No complications
Snow [19], 1993	Arthroscopic debridement and proximal femoral osteotomy	Pain: Improved for all patients ROM: Improved for all patients	Pain persisted in two patients
Beck [20], 2004	Surgical dislocation of hip and created an improved femoral head–neck offset by resection osteotomy of the CAM lesion Resection osteotomy was performed using a Kocher–Langenbeck approach with a trochanteric flip and an anterior arthrotomy Z-shaped capsulotomy used to expose the hip for examination of impingement	Pain: Improved for all patients Merle d'Aubigne hip score: pre-operative score: 14.1 and post-operative score: 16.5 (<i>P</i> = 0.015) At final follow-up, six patients had Grade 0 OA, eight patients had Grade 1 OA and two had Grade 2	Four patients had hip deterioration
Siebenrock [21], 2003	A Bernese periacetabular osteotomy was conducted through a modified Smith–Peterson approach	Pain: Improved for all patients Merle d'Aubigne hip score: Pre-operative score: 14.0 (range, 12 to 16 points) and post-operative score: 16.9 (range, 15–18 points; <i>p</i> -value NR)	No complications

(Continued)

Table III. (Continued)

Primary author, year	Surgical techniques	Outcomes	Complications
Ganz [22], 2001	An intra-operative T-shaped arthroscopy was performed to evaluate labral and cartilaginous lesions	ROM: mean flexion improved by 7° ($P = 0.014$) Internal rotation improved by 10° ($P = 0.006$) Adduction improved by 8° ($P = 0.0117$) Extension, external rotation and abduction remained the same (NS)	Two patients had partial neurapraxia of the sciatic nerve
Ito [26], 2001	Surgical dislocation of hip and created an improved femoral head-neck offset by resection osteotomy of the CAM lesion Resection osteotomy was performed using a Kocher-Langenbeck approach with a trochanteric flip and an anterior arthroscopy Capsulotomy used to expose the hip for examination of impingement	NR Pain: Improved for all patients ROM: Improved for all patients Mean femoral anteversion: $9.68 \pm 3.7^\circ$ Mean impingement depth: $17.5 \pm 4.2^\circ$	79 hips had HOs Seven patients had saddleback deformity Three patients had trochanteric non-union NR
Leunig [24], 1997	A Bernese periacetabular osteotomy was conducted through a modified Smith-Peterson approach An intraoperative T-shaped arthroscopy was performed to evaluate labral and cartilaginous lesions	Pain: improved for all patients ROM: improved for all patients	NR
Leunig [25], 2000	Capsulotomy used to expose the hip for examination of impingement	Pain: Improved for all patients	NR

(Continued)

Table III. (Continued)

Primary author, year	Surgical techniques	Outcomes	Complications
	Surgical dislocation of hip and created an improved femoral head-neck offset by resection osteotomy of the CAM lesion	ROM: Improved for all patients	
	Resection osteotomy was performed using a Kocher-Langenbeck approach with a trochanteric flip and an anterior arthrotomy		
	Z-shaped capsulotomy used to expose the hip for examination of impingement		

NR, not reported; NS, not significant.

At final follow-up, one study reported radiographic degeneration as remaining stable or improved after undergoing surgical dislocation [20]. For each patient, an orthograde radiograph of the pelvis and a lateral cross table radiograph were taken and the hips were classified using Tönnis classification of OA [20]. OA was initially rated as Grade 0 in seven hips, Grade 1 in 10 hips and Grade 2 in two hips [20]. At final follow-up, 14 hips remained the same and three had improved (two had Grade 1 OA and one had Grade 2 OA; Table III) [20].

Complications

The current review found an overall complication rate of 35.0% ($n=99$). The majority of these complications (91.9%) stemmed from a single study [22]. The rate of major complications was 3.8% ($n=11$). Major complications included trochanteric non-union ($n=3$, 37.3%) Grade III heterotopic ossification (HO; $n=2$, 18.2%) and partial sciatic neurapraxia ($n=2$, 18.2%). Avascular necrosis was not reported in any study. The rate of minor complications was 31.1% ($n=88$). Complications included Grades I and II HO ($n=77$, 87.5%), saddle back deformity ($n=7$, 7.9%) and persistent pain following treatment ($n=3$, 3.4%; Table III).

DISCUSSION

The most notable finding of this review is the paucity of literature available that described the diagnosis and management of FAI prior to the year 2000. Prior to 2000, diagnosis of FAI was predominately through assessment of groin pain, the AIT and, in some instances, MRA. There were no studies describing the use of hip arthroscopy in the management of FAI prior to the year 2000. Surgical dislocation with improved deepened femoral head-neck offset by resection osteotomy was the most commonly used procedure to treat FAI. All procedures provided pain relief and increased ROM as can be seen through improvements in Merle d'Aubigne hip scores in patients undergoing surgical dislocation with resection osteotomy; however, a moderate complication rate was reported, most commonly HO.

In this systematic review, all patients reported symptoms of groin pain as part of the clinical diagnosis of FAI. In a survey conducted by Ayeni *et al.* [27], 81.7% of respondents reported diagnosing FAI based on the individual's history of groin pain. Sensation of groin pain results from labral abnormalities [24]. In this review, such abnormalities were confirmed using MRA with 90% sensitivity [24]. Recently, usage of other imaging modalities such as MRI and computed tomography (CT) has increased [28]. A 2017 study noted that sensitivity for detecting labral

tears from conventional MRI was 70% compared with 95% for MRA, showing that MRA appears to be superior to MRI when assessing labral tears [28]. Unlike MRI, CT provides improvements in detailing bony features of hip disorders [29]. CT can also accurately control for patient positions when assessing femoral and acetabular version [29]. Although CT allows for a dynamic assessment of FAI, MRA and MRI techniques are typically used to avoid exposing patients to radiation, especially in younger populations [28]. Additionally, intra-articular hip injection is another technique used to diagnose FAI [30]. One study found that fluoroscopically guided intra-articular hip injections can diagnose intra-articular hip pathologies, including labral tears, with 90% accuracy [30]. Intra-articular injections can additionally provide pain relief, for up to 12 months, for FAI patients [30]. In this review, it was observed that prior to 2000, CT and intra-articular hip injections were not used in pre-operative assessment of FAI and that the focus was primarily on the usage of MRA for detection of labral lesions.

A number of clinical tests have been developed to assess FAI [31]. In the current review, FAI was confirmed in patients (28.3%) through testing positive on the AIT. In the same survey, Ayeni *et al.* [27], reported that 70% of surgeons used the FADIR test to clinically diagnose FAI. FADIR assessment has remained relatively constant throughout the years [32]. The test is typically conducted through flexing the hip to either 90° (64.5%), 110° (4.7%) or full flexion (17.7%), followed with internal rotation and adduction of tested hips [33]. Patients in this review were assessed similarly through 70–90° of hip flexion. The FADIR, the foot progression angle walking test (FPAW), and the maximal squat test are reported to show the best sensitivities for assessing FAI [31]. The FPAW test and maximal squat test were not reported in this review, highlighting that there was a limited number of clinical tests available to clinicians prior to the year 2000.

Five studies within the present systematic review treated FAI through surgical dislocation of the hip. One study reported significant improvements ($P=0.015$) in the Merle d'Aubigne score suggesting that surgical dislocation provides improved patient ROM [20]. Recently, Domb *et al.* [34] found comparable radiographic and clinical results between surgical dislocation and arthroscopy groups, highlighting that past techniques continue to yield desirable outcomes in patients. Due to rapid technological development there has been more widespread use of arthroscopy for FAI treatment [34, 35]. A 2014 systematic review found that between 2004 and 2013, in North America, roughly 73% ($n=2648$) of patients underwent an arthroscopic intervention while 11% ($n=407$) of patients

underwent surgical dislocation for treatment of FAI [36]. Similar trends in treatment were also noted in Europe [36]. It is evident that prior to the year 2000, a large majority of surgeons elected to use a surgical dislocation approach to treat FAI, with a majority of cases now being treated with arthroscopic techniques. The present systematic review found that no study reported the use of hip arthroscopy in the management of FAI prior to the year 2000.

Another surgical technique, the Bernese periacetabular osteotomy, was used in cases wherein acetabular retroversion was associated with FAI [21]. This technique reported statistically significant increases in range of internal rotation, flexion and adduction along with improvements in average Merle d'Aubigne score [21]. In 2016, Parry *et al.* [37] found that the same technique offered significant clinical improvement, specifically in the Harris Hip Score, for patients with FAI secondary to acetabular retroversion. Additionally, both studies reported a positive posterior wall sign, suggesting that Bernese periacetabular osteotomy continues to be useful for hips with decreased acetabulum size and instability due to a deficient posterior acetabular wall [21].

The most common complication reported, found exclusively following surgical dislocation, was HO (79.8%). It has been reported that surgical dislocation using the Kocher–Langenbeck approach and concurrent trochanteric osteotomy increases the risk of the development of ectopic bone [38]; hence, a possible explanation of increased rates of HO observed in this review. With more surgical experience and increased prophylaxis usage, the incidence of HO has decreased as seen in a 2019 multicenter analysis which reported 18 (5.4%) Grades I and II HOs compared with 77 (27.2%) in our study [39]. Despite downward trends, the rate of complications following surgical dislocation is still higher than currently used FAI techniques such as arthroscopy [40]. Botser *et al.* [40] reported that the complication rate in patients in their arthroscopic group was 1.7% ($n=15$) compared with 9.2% ($n=28$) for patients in the open surgical dislocation group. Despite providing relatively similar clinical and radiographic results, arthroscopic procedures may be preferred over surgical procedures due to lower complication rates.

Strengths

The strengths of this systematic review stem from the rigorous methodology employed which includes a broad search strategy conducted on multiple databases, and a duplicate systematic approach to reviewing the literature. The systematic screening approach was employed in duplicate, thus minimizing reviewer bias. There was excellent

agreement at all screening stages and for the quality assessment. The novelty of this topic as it addresses how the field of hip preservation is advancing is another strength of this systematic review.

Limitations

The most significant limitation of the current review is that there was a lack of high-quality studies with large sample sizes and long-term follow-up. The limited documentation of data, including mean follow-up time, standardized radiographic and clinical outcomes limits the strength of the conclusions. Given that FAI syndrome had not been established at the time these studies were published, the lack of standardization between studies is expected. The majority of studies (88.8%) included in this review were conducted in Switzerland; therefore, there may be a lack of generalizability of this review. Furthermore, this finding may highlight the apparent differences in diagnosis and treatment of FAI across continents prior to 2000.

CONCLUSIONS

Prior to 2000, there was low quantity and quality of research on the diagnosis/management of FAI. Diagnostic evaluation was primarily through clinical examination (including groin pain and AIT). MRA was occasionally used to detect labral degeneration however, utilization of CT and diagnostic injections were not reported. Surgical dislocation and osteotomies of the acetabulum yielded desirable short-term clinical outcomes with a moderate complication rate. No study reported using arthroscopy for FAI management prior to 2000. Clinicians today can learn from historical principles (including clinical diagnosis of FAI, management with surgical correction of femoral head–neck offset) while applying novel techniques (including CT, injections, arthroscopic surgical techniques and rehabilitation) to improve patient outcomes.

SUPPLEMENTARY DATA

Supplementary data are available at *Journal of Hip Preservation Surgery* online.

CONFLICT OF INTEREST STATEMENT

None declared.

REFERENCES

- Ganz R, Parvizi J, Beck M *et al.* Femoroacetabular impingement: a cause for osteoarthritis of the hip. *Clin Orthop Relat Res* 2003; **417**:112–20.
- Pun S, Kumar D, Lane NE. Review: femoroacetabular impingement. *Arthritis Rheumatol* 2015; **67**:17–27.
- Sim Y, Horner NS, de SA D *et al.* Reporting of non-hip score outcomes following femoroacetabular impingement surgery: a systematic review. *J Hip Preserv Surg* 2015; **2**:224–41.
- Lee W-Y, Kang C, Hwang D-S *et al.* Descriptive epidemiology of symptomatic femoroacetabular impingement in young athlete: single center study. *Hip Pelvis* 2016; **28**:29.
- Martin RL, Sekiya JK. The interrater reliability of 4 clinical tests used to assess individuals with musculoskeletal hip pain. *J Orthop Sports Phys Ther* 2008; **38**:71–7.
- Atzmon R, Sharfman ZT, Haviv B *et al.* Does capsular closure influence patient-reported outcomes in hip arthroscopy for femoroacetabular impingement and labral tear? *J Hip Preserv Surg* 2019; **6**:199–206.
- Toomayan GA, Holman WR, Major NM *et al.* Sensitivity of MR arthrography in the evaluation of acetabular labral tears. *AJR Am J Roentgenol* 2006; **186**:449–53.
- Kuhns BD, Weber AE, Levy DM *et al.* The natural history of femoroacetabular impingement. *Front Surg* 2015; **2**:58.
- Öhlin A, Coughlin RP, Ahldén M *et al.* The evolution of femoroacetabular impingement surgical management as a model for introducing new surgical techniques. *Knee Surgery Sport Traumatol Arthrosc* 2020; **28**:1333–40.
- Wylie JD, Kim Y-J. The natural history of femoroacetabular impingement. *J Pediatr Orthop* 2019; **39**:S28–32.
- Khan M, Bedi A, Fu F *et al.* New perspectives on femoroacetabular impingement syndrome. *Nat Rev Rheumatol* 2016; **12**:303–10.
- Ayeni OR, Chan K, Al-Asiri J *et al.* Sources and quality of literature addressing femoroacetabular impingement. *Knee Surg Sports Traumatol Arthrosc* 2013; **21**:415–9.
- Khan M, Oduwole KO, Razdan P *et al.* Sources and quality of literature addressing femoroacetabular impingement: a scoping review 2011–2015. *Curr Rev Musculoskelet Med* 2016; **9**:396–401.
- Moher D, Liberati A, Tetzlaff J *et al.*; The PRISMA Group. Preferred reporting items for systematic reviews and meta-analyses: the PRISMA statement. *PLoS Med* 2009; **6**:e1000097.
- Wright JG, Swiontkowski MF, Heckman JD. Introducing levels of evidence to the journal. *J Bone Joint Surg Am* 2003; **85**:1–3.
- Slim K, Nini E, Forestier D *et al.* Methodological index for non-randomized studies (minors): development and validation of a new instrument. *ANZ J Surg* 2003; **73**:712–6.
- Eijer H, Myers SR, Ganz R. Anterior femoroacetabular impingement after femoral neck fractures. *J Orthop Trauma* 2001; **15**:475–81.
- Myers SR, Eijer H, Ganz R. Anterior femoroacetabular impingement after periacetabular osteotomy. *Clin Orthop Relat Res* 1999; **363**:93–9.
- Snow SW, Keret D, Scarangella S *et al.* Anterior impingement of the femoral head: a late phenomenon of Legg-Clave-Perthes's disease. *Pediatr Orthop* 1993; **13**:286–9.
- Beck M, Leunig M, Parvizi J. Anterior femoroacetabular impingement part II. Midterm results of surgical treatment. *Clin Orthop Relat Res* 2004; **418**:67–73.
- Siebenrock KA, Schoeniger R, Ganz R. Anterior femoroacetabular impingement due to acetabular retroversion treatment with periacetabular osteotomy. *J Bone Joint Surg Am* 2003; **85**:278–86.

22. Ganz R, Gill TJ, Gautier E *et al.* Surgical dislocation of the adult hip a technique with full access to the femoral head and acetabulum without the risk of avascular necrosis. *J Bone Joint Surg Br* 2001; **83**:1119–24.
23. Ganz R, Ito K, Leunig M *et al.* Resident in orthopaedic surgery evaluation of the acetabular labrum by MR arthrography. 1997.
24. Leunig M, Werlen S, Ungersböck A *et al.* Evaluation of the acetabular labrum by MR arthrography. *J Bone Joint Surg Br* 1997; **79-B**: 230–4.
25. Leunig M, Casillas MM, Hamlet M *et al.* Slipped capital femoral epiphysis: early mechanical damage to the acetabular cartilage by a prominent femoral metaphysis. *Acta Orthop Scand* 2000; **71**: 370–5.
26. Ito K, Minka MA, Leunig M *et al.* Femoroacetabular impingement and the cam-effect. A MRI-based quantitative anatomical study of the femoral head-neck offset. *J Bone Joint Surg Br* 2001; **83-B**: 171–6.
27. Ayeni OR, Belzile EL, Musahl V *et al.* Results of the Perception of femoroacetabular impingement by Surgeons Survey (PROCESS). *Knee Surg Sports Traumatol Arthrosc* 2014; **22**: 906–10.
28. Kaddah RO, Khalil ME. MR Arthrography versus conventional MRI in evaluation of labral and chondral lesions in different types of femoroacetabular impingement. *Egypt J Radiol Nucl Med* 2017; **48**:169–78.
29. Heyworth BE, Dolan MM, Nguyen JT *et al.* Preoperative three-dimensional CT predicts intraoperative findings in hip arthroscopy. *Clin Orthop Relat Res* 2012; **470**:1950–7.
30. Khan W, Khan M, Alradwan H *et al.* Utility of intra-articular hip injections for femoroacetabular impingement: a systematic review. *Orthop J Sport Med* 2015; **3**:1–8.
31. Caliesch R, Sattelmayer M, Reichenbach S *et al.* Diagnostic accuracy of clinical tests for cam or pincer morphology in individuals with suspected FAI syndrome: a systematic review. *BMJ Open Sport Exerc Med* 2020; **6**:e000772.
32. Haldane CE, Ekhtiari S, de SA D *et al.* Preoperative physical examination and imaging of femoroacetabular impingement prior to hip arthroscopy—a systematic review. *J Hip Preserv Surg* 2017; **4**:201–13.
33. Shanmugaraj A, Shell JR, Horner NS *et al.* How useful is the flexion-adduction-internal rotation test for diagnosing femoroacetabular impingement: a systematic review. *Clin J Sport Med* 2018; **30**:76–82.
34. Domb BG, Stake CE, Botser IB *et al.* Surgical dislocation of the hip versus arthroscopic treatment of femoroacetabular impingement: a prospective matched-pair study with average 2-year follow-up. *Arthrosc J Arthrosc Relat Surg* 2013; **29**:1506–13.
35. Ishoi L, Thorborg K, Kraemer O *et al.* The association between specific sports activities and sport performance following hip arthroscopy for femoroacetabular impingement syndrome: a secondary analysis of a cross-sectional cohort study including 184 athletes. *J Hip Preserv Surg* 2019; **6**:124–33.
36. Yeung M, Khan M, Schreiber VM *et al.* Global discrepancies in the diagnosis, surgical management, and investigation of femoroacetabular impingement. *Arthrosc J Arthrosc Relat Surg* 2014; **30**: 1625–33.
37. Parry JA, Swann RP, Erickson JA *et al.* Midterm outcomes of reverse (anteverting) periacetabular osteotomy in patients with hip impingement secondary to acetabular retroversion. *Am J Sports Med* 2016; **44**:672–6.
38. Firoozabadi R, O'Mara TJ, Swenson A *et al.* Risk factors for the development of heterotopic ossification after acetabular fracture fixation. *Clin Orthop Relat Res* 2014; **472**:3383–8.
39. Gao GY, Zhang X, Dai LH *et al.* Heterotopic ossification after arthroscopy for hip impingement syndrome. *Chin Med J (Engl)* 2019; **132**:827–33.
40. Botser IB, Smith TW, Nasser R *et al.* Open surgical dislocation versus arthroscopy for femoroacetabular impingement: A comparison of clinical outcomes. *Arthroscopy* 2011; **27**:270–8.