



Anti-CASPR2 myeloencephalitis with active replication of hepatitis B virus in the central nervous system: a case report

Xu Liu¹ · Lu Wang² · Di Zhong¹ · Bo Yan^{1,3} · Xiaoting Hao¹

Received: 25 February 2022 / Accepted: 27 March 2022 / Published online: 12 April 2022
© The Author(s) under exclusive licence to Belgian Neurological Society 2022

Introduction

Autoimmune encephalitis (AE) involves inflammation of the central nervous system, and its most common forms involve auto-antibodies against the N-methyl-D-aspartate receptor, leucine-rich glioma-inactivated protein 1, or contactin-associated protein-like 2 (CASPR2) [1].

CASPR2 forms part of the voltage-gated potassium channel complex in both the central and peripheral nervous systems [1], so anti-caspr2 disease usually involves extensive damage to both systems, leading to limbic encephalitis, Morvan syndrome, cerebellar syndrome, peripheral nerve hyperexcitability, and autonomic dysfunction [2].

AE can be triggered by neurotropic viruses, and this has been well documented for encephalitis involving auto-antibodies against the N-methyl-D-aspartate receptor [3]. Chronic infection with hepatitis B virus (HBV) has been linked to neurological complications such as myelitis and Guillain-Barré syndrome [4, 5], but it has never been clearly linked to AE.

Here we report what appears to be the first case of anti-CASPR2 encephalitis linked to chronic HBV infection.

Case presentation

A 20 year-old Han Chinese woman presented at our hospital because of headache and fever, followed one week later by bilateral lower limb weakness, urinary retention, abnormal delirium, and rapid onset of somnolence. She reported that her body weight had decreased by 7 kg over the preceding three weeks. Physical examination at admission showed gross vertical nystagmus in both eyes, weakened bilateral pharyngeal reflex, poor muscle strength in the upper limbs (grade 2 on the left side, 3 on the right side). Bilateral muscle tone was reduced and tendon reflexes were reduced in both upper limbs and absent in both lower limbs. The patient was positive for meningeal irritation and negative for Babinski's sign. She was normal in other neurological and physical examinations. 21 days after onset, patient presented with positive Babinski sign, increased tendon reflex and muscle tone.

Magnetic resonance imaging revealed multiple lesions in the hippocampus, bilateral basal ganglia, brainstem, cerebellar hemisphere, as well as cervical and thoracic spinal cord (Fig. 1). Lumbar puncture showed normal cerebrospinal fluid pressure of 250 mmH₂O, normal cell count (134 × 10⁶/L) and elevated protein (1.22 g/L; normal range, 0.15–0.45 g/L). A cell-based assay revealed an anti-CASPR2 antibody titer of 1:32 in serum, but no such antibody was detected in cerebrospinal fluid. The patient was negative for auto-antibodies against the N-methyl-D-aspartate receptor, glutamate receptors 1 or 2-aminobutyric acid B receptor, α-amino-3-hydroxy-5-methyl-4-isoxazol-propionic acid (AMPA) receptors, leucine-rich glioma-inactivated protein 1, dipeptidyl-peptidase-like protein 6, Iglon5, myelin oligodendrocyte glycoprotein, glial fibrillary acidic protein, aquaporin 4, myelin basic protein, and flotillins 1 or 2. The patient was also negative for oligoclonal bands. Metagenomic next-generation sequencing (mNGS) of cerebrospinal fluid detected 28 copies of HBV-DNA, and HBV load in

Xu Liu and Lu Wang contributed equally to this manuscript.

✉ Bo Yan
yanbo96@163.com

✉ Xiaoting Hao
sherryhao@whscu.cn

¹ Department of Neurology, West China Hospital, Sichuan University, Chengdu 610000, Sichuan, China

² Department of Neurology, The Affiliated Hospital of Southwest Jiaotong University and The Third People's Hospital of Chengdu, Chengdu 610031, Sichuan, China

³ Department of Neurology, Chengdu Shangjin Nanfu Hospital, Chengdu 611730, Sichuan, China

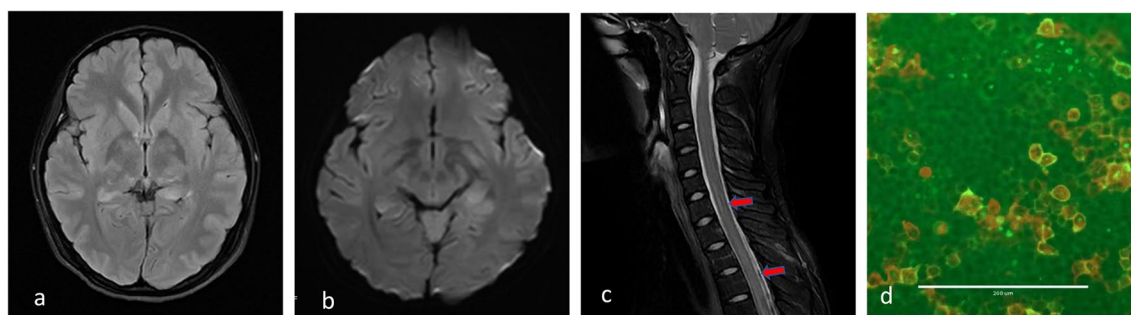


Fig. 1 **a–b** Magnetic resonance imaging of the patient, showing multiple lesions in the hippocampus, bilateral basal ganglia, brainstem, and cerebellar hemisphere. **c** T2-weighted magnetic resonance imag-

ing revealing lesions in the thoracic spinal cord. **d** Cell-based assay of anti-CASPR2 antibodies in serum

serum was 2.91×10^7 IU/ml. Chest computed tomography did not reveal HBV-associated occupancy.

Based on these findings, the patient was diagnosed with anti-CASPR2 myeloencephalitis and chronic HBV infection. She was given multiple courses of immunoglobulin therapy and entecavir, and her condition gradually improved by the time of discharge. The patient complained only of mild sleep disorder, which had resolved by follow-up at 4 months after discharge. However, at this time, we tested autoimmune antibody again using cell-based assay, which revealed an anti-CASPR2 antibody titer of 1:100 in serum and 1:10 in cerebrospinal fluid.

Discussion

To our knowledge, this appears to be the first case of anti-caspr2 myeloencephalitis apparently linked to chronic HBV infection. Interestingly, we found that the titer of anti-CASPR2 antibody in serum and cerebrospinal fluid increased despite improvement in the patient's condition. Previous studies suggested that there was no definite linear relationship between severity of disease and antibody titer [1].

How AE begins remains unclear. Some AE patients present tumors, such as ovarian teratoma in a patient with encephalitis involving antibodies against the N-methyl-D-aspartate receptor [6], and a thymoma in a patient with anti-caspr2 encephalitis [2]. Viral infection also appears capable of triggering AE: cases of encephalitis involving antibodies against the N-methyl-D-aspartate receptor have been linked to infection by herpes simplex virus, H1N1 influenza virus, influenza B virus, and severe acute respiratory syndrome coronavirus 2 [3, 7]. Some patients have been reported to have chronic HBV infection as well as neurological disorders including acute disseminated encephalomyelitis, neuromyelitis optica spectrum disorders, and Guillain-Barré syndrome [4].

When the body begins to generate antibodies against the invading virus, some of those antibodies may recognize auto-antigens on the surface of cells. For example, epitopes on HBV appear to resemble areas on myelin basic protein, such that the body's anti-HBV antibodies may bind to the myelin sheath on axons, leading to demyelination and inflammation [8]. This model may explain how viral infection can lead to AE. Consistent with this idea, anti-CASPR2 antibodies in patients with AE recognize extracellular epitopes of CASPR2 [1]. Indeed, chronic HBV infection in patients with neurotic myotonia (Isaacs syndrome) can elicit production of auto-antibodies against the voltage-gated potassium channel complex in which CASPR2 functions [9]. Therefore we speculate that HBV infection of the nervous system may trigger production of auto-antibodies against CASPR2, inducing AE.

Conclusion

HBV may trigger anti-CASPR2 myeloencephalitis. Our case suggests that patients with chronic infections such as HBV who are suspected of having encephalitis should be screened by mNGS and assay of AE-related antibodies in the cerebrospinal fluid.

Author contributions XL (Department of Neurology, West China Hospital, Sichuan University): acquired clinical data, reviewed the literature, created the figure, and drafted the manuscript. LW (The Affiliated Hospital of Southwest Jiaotong University & The Third People's Hospital of Chengdu): participated in drafting and reviewing the manuscript. DZ (Department of Neurology, West China Hospital, Sichuan University): acquired clinical data. BY (Department of Neurology, West China Hospital, Sichuan University): performed neuroradiological assessment, and revised the manuscript. XH (Department of Neurology, West China Hospital, Sichuan University): collected and analyzed immunohistology data, conceived the figure, and revised the manuscript.

Funding This work was supported by the National Key R&D Program of China (2018YFC1311400).

Declarations

Conflict of interest The authors declare no competing interests.

Ethical approval The study was approved by the institutional review board.

Consent to participate Informed consent was obtained from all participants included in the study.

References

- van Sonderen A, Petit-Pedrol M, Dalmau J et al (2017) The value of LGI1, Caspr2 and voltage-gated potassium channel antibodies in encephalitis. *Nat Rev Neurol* 13:290–301. <https://doi.org/10.1038/nrneurol.2017.43>
- van Sonderen A, Ariño H, Petit-Pedrol M et al (2016) The clinical spectrum of Caspr2 antibody-associated disease. *Neurology* 87:521–528. <https://doi.org/10.1212/WNL.0000000000002917>
- Schwenkenbecher P, Skripuletz T, Lange P et al (2021) Intrathecal antibody production against epstein-barr, herpes simplex, and other neurotropic viruses in autoimmune encephalitis. *Neurol Neuroimmunol Neuroinflamm*. <https://doi.org/10.1212/NXI.0000000000001062>
- Inoue J, Ueno Y, Kogure T et al (2008) Analysis of the full-length genome of hepatitis B virus in the serum and cerebrospinal fluid of a patient with acute hepatitis B and transverse myelitis. *J Clin Virol* 41:301–304. <https://doi.org/10.1016/j.jcv.2008.01.002>
- Pettersson J, Piorkowski G, Mayxay M et al (2019) Meta-transcriptomic identification of hepatitis B virus in cerebrospinal fluid in patients with central nervous system disease. *Diagn Microbiol Infect Dis* 95:114878. <https://doi.org/10.1016/j.diagmicrobio.2019.114878>
- Dalmau J, Tüzün E, Wu H et al (2007) Paraneoplastic anti-N-methyl-D-aspartate receptor encephalitis associated with ovarian teratoma. *Ann Neurol* 61:25–36. <https://doi.org/10.1002/ana.21050>
- Phillips O, Tubre T, Lorenzo H et al (2021) Limbic encephalitis in a child with ovarian teratoma and influenza B. Case report and critical review of the history of autoimmune anti-N-methyl-D-aspartate receptor encephalitis. *J Neuroimmunol* 360:577716. <https://doi.org/10.1016/j.jneuroim.2021.577716>
- Fujinami R, Oldstone M (1985) Amino acid homology between the encephalitogenic site of myelin basic protein and virus: mechanism for autoimmunity. *Science* 230:1043–1045. <https://doi.org/10.1126/science.2414848>
- Basiri K, Fatehi F (2009) Isaacs syndrome associated with chronic hepatitis B infection: a case report. *Neurol Neurochir Pol* 43:388–390

Publisher's Note Springer Nature remains neutral with regard to jurisdictional claims in published maps and institutional affiliations.