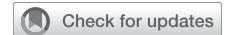

# Early results of geometric ring annuloplasty for bicuspid aortic valve repair during aortic aneurysm surgery



Marc W. Gerdisch, MD,<sup>a</sup> T. Brett Reece, MD,<sup>b</sup> Dominic Emerson, MD,<sup>c</sup> Richard S. Downey, MD,<sup>d</sup> Geoffrey B. Blossom, MD,<sup>e</sup> Arun Singhal, MD,<sup>f</sup> Joshua N. Baker, MD,<sup>g</sup> Theodor J. M. Fischlein, MD, MD,<sup>h</sup> Vinay Badhwar, MD,<sup>i</sup> and the BAVr Working Group\*

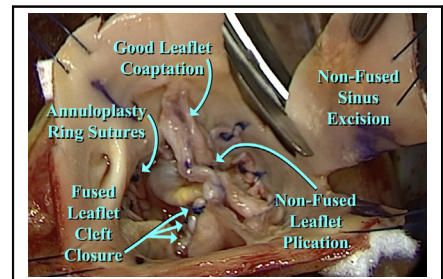
## ABSTRACT

**Objectives:** Geometric ring annuloplasty has shown promise during bicuspid aortic valve repair for aortic insufficiency. This study examined early outcomes of bicuspid aortic valve repair associated with proximal aortic aneurysm replacement.

**Methods:** From September 2017 to November, 2021, 127 patients underwent bicuspid aortic valve repair with concomitant proximal aneurysm reconstruction. Patient age was  $50.6 \pm 12.7$  years (mean  $\pm$  standard deviation), male gender was 83%, New York Heart Association Class was 2 (1-2) (median [interquartile range]), and preoperative aortic insufficiency grade was 3 (2-4). Ascending aortic diameter was 50 (46-54) mm, and all patients had ascending aortic replacement. Forty patients had sinus diameters greater than 45 mm, prompting remodeling root procedures. A total of 105 patients had Sievers type 1 valves, 3 patients had type 0, and 7 patients had type 2. A total of 118 patients had primarily right/left fusion, 8 patients had right/nonfusion, and 1 patient had left/nonfusion. Leaflet reconstruction used central leaflet plication and cleft closure, with limited ultrasonic decalcification in 31 patients.

**Results:** Ring size was 23 (21-23) mm, and 26 of 40 root procedures were selective nonfused sinus replacements. Aortic clamp time was 139 (112-170) minutes, and bypass time was 178 (138-217) minutes. Postrepair aortic insufficiency grade was 0 (0-0) ( $P < .0001$ ), and mean valve gradient was 10 (7-14) mm Hg. No early and 1 late mortality occurred. Four patients required reoperation for bleeding, and 4 patients required pacemakers. At a mean follow-up of 20 months (maximal 93), there were no valve-related complications, 5 late repair failures prompting valve replacement, and 1 death due to Coronavirus Disease 2019.

**Conclusions:** Geometric ring annuloplasty for bicuspid aortic valve repair with proximal aortic aneurysm reconstruction is safe and associated with good early outcomes. Further experience and follow-up will help inform long-term durability. (JTCVS Techniques 2022;14:55-65)



BAV repair with hemi-root replacement. Bicuspid repair using geometric ring annuloplasty and root remodeling with single sinus resection followed by aneurysm repair.

## CENTRAL MESSAGE

By using bicuspid ring annuloplasty, leaflet reconstruction, and aortic root remodeling, most types of bicuspid valve defects associated with proximal aortic aneurysms can be repaired with good early results.

## PERSPECTIVE

Routine bicuspid valve repair during aortic aneurysm surgery has been difficult for a variety of reasons. Bicuspid ring annuloplasty produces major annular remodeling and equalizes fused and nonfused segmental annular circumferences, facilitating leaflet reconstruction. Together with ascending aortic and selective sinus replacement, bicuspid valve repair can become routine with good early results.

From the <sup>a</sup>Department of Cardiac Surgery, Franciscan Health Indianapolis, Indianapolis, Ind; <sup>b</sup>Department of Cardiac Surgery, University of Colorado, Aurora, Colo; <sup>c</sup>Department of Cardiac Surgery, Cedars Sinai Medical Center, Los Angeles, Calif; <sup>d</sup>Department of Cardiac Surgery, University of Michigan, Muskegon, Mich; <sup>e</sup>Department of Cardiac Surgery, Ohio Health Riverside Methodist Hospital, Columbus, Ohio; <sup>f</sup>Department of Cardiac Surgery, University of Iowa, Iowa City, Iowa; <sup>g</sup>Department of Cardiac Surgery, Missouri Baptist Hospital, St Louis, Mo; <sup>h</sup>Department of Cardiac Surgery, Klinikum Nürnberg, Paracelsus Medical University, Nürnberg, Germany; and <sup>i</sup>Department of Cardiac Surgery, West Virginia University, Morgantown, WVa.

This was an investigator-initiated study of the first significant application of geometric ring annuloplasty to repair of BAVs during proximal aortic aneurysm resection.


No commercial funding was used for generation of this article. Institutional Review Board or Ethics Committee approval was obtained at each institution, as well as an overall waiver of informed consent for retrospective analysis of de-identified clinical data from the WCG Institutional Review Board (Puyallup, Wash). After Institutional Review Board approval, the data were recorded by the surgeons and independent research personnel at each center, and the de-identified data were collated for descriptive analysis.

**Read at the 101st Annual Meeting of The American Association for Thoracic Surgery: A Virtual Learning Experience, April 30-May 2, 2021.**

\*The BAVr Working Group Members: Alfredo Trento, MD,<sup>a</sup> Joanna Chikwe, MD,<sup>a</sup> Lawrence M. Wei, MD,<sup>b</sup> Jason P. Glotzbach, MD,<sup>c</sup> Timothy W. James, MD,<sup>d</sup> Reed

**Abbreviations and Acronyms**

AI = aortic insufficiency  
 BAV = bicuspid aortic valve

 Video clip is available online.

To view the AATS Annual Meeting Webcast, see the URL next to the webcast thumbnail.

It now can be argued that autologous repair of the bicuspid aortic valve (BAV) for aortic insufficiency (AI) is the surgical procedure of choice when clinical indications exist.<sup>1</sup> Operative mortalities are low,<sup>2</sup> early success rates are high,<sup>3</sup> and repair failure (previously a drawback) is decreasing progressively with technical development.<sup>4</sup> Valve-related complications are lower than with prosthetic valve replacement,<sup>5,6</sup> and as a result, survival with aortic valve repair is likely augmented.<sup>7</sup> Aortic valve repair procedures are now highly developed,<sup>8-11</sup> but still require selective application, allowing only a minority of valves to be repaired.<sup>12</sup> Two barriers to repair of BAV with associated ascending aortic aneurysm persist, namely, difficulty in repairing some anatomies such as valves with 3 equal sinuses or unicuspid defects<sup>13,14</sup> and lower repair rates in patients with BAV and proximal aortic aneurysms using traditional reimplantation procedures.<sup>15</sup> The major annular remodeling associated with BAV ring annuloplasty specifically addresses the first problem by equalizing the fused and nonfused annuli, while establishing 180° commissural orientation.<sup>16</sup> Internal geometric ring annuloplasty also facilitates aneurysm replacement, and when coupled with remodeling aortic root replacement<sup>17</sup> eliminates the need for deep external root dissection in the sometimes difficult right coronary sinus area.<sup>4</sup> The purpose of this study was to assess the early results of BAV ring annuloplasty combined with proximal aortic replacement, including root remodeling when appropriate, for management of BAV defects

associated with aortic aneurysms during initial application in the United States and Europe.

**MATERIALS AND METHODS**

From February 2014 to November 2021, 127 consecutive patients underwent BAV repair supported by internal ring annuloplasty with concomitant ascending aortic or root aneurysm replacement in 25 US and 2 European centers (Table 1). The first 6 patients were part of the European regulatory trial,<sup>18</sup> and the rest were postmarket after Food and Drug Administration and CE approval. A waiver of informed consent was obtained from the Institutional Review Board or Ethics Committee of each institution for retrospective analysis of de-identified clinical data. Additionally, an overall waiver was obtained from the WCG Institutional Review Board. This series represents the initial application of internal BAV annuloplasty ring technology in the 27 participating centers. Patient age was 50.6 ± 12.7 years (mean ± standard deviation), male gender was 83%, New York Heart Association Class was 2 (1-2) (median [interquartile range]), and preoperative AI grade was 3 (2-4). Twenty-eight patients (22%) had grade 0-1 AI preoperatively, and the valves were repaired during aneurysm surgery because of low coaptation height or dilated annulus, factors predicting future valve deterioration. The majority (82/127 or 65%) had grade 3 or 4 AI. Average ascending aortic diameter was 50 (46-54) mm, and all patients had graft replacement of the ascending aorta. Forty patients had sinus diameters greater than 45 mm prompting additional remodeling root procedures (Table 1), and 26 of these had selective nonfused sinus replacement. A total of 118 patients had Sievers type 1 valves, 4 patients had type 0, and 5 patients had type 2 defects. A total of 118 patients had primarily right/left fusion, 8 patients had right/nonfusion, and 1 patient had left/nonfusion.

As described previously,<sup>18</sup> the rings were machined from titanium blocks producing circular base geometry incorporating two 180° sub-commissural posts that flared outward by 10°. The rings were covered with a thin layer of polyester fabric to promote endothelialization while maintaining a low profile (Figure 1, A). By using specially designed ball sizers placed in the coronary sinus (Figure 1, B), ring size was determined as nonfused leaflet free-edge length/1.5, which was correlated with maintaining unchanged intercommissural distance (Video 1). Pathologic annular diameter was measured in 88 patients using a Hegar dilator. Mild to moderate calcification was removed using the ultrasonic aspirator in 31 patients (24%) if localized to the commissures, raphe, or cleft tissue. Severe transmural leaflet calcification, active endocarditis cases, or leaflet defects requiring large pericardial patches were not selected for repair. Rings were sutured sub-annularly into the inflow portion of the valve with 7-13 transannular horizontal mattress sutures of 3-0 or 4-0 coated braided polyester (Tevdek, Teleflex Medical EOM) supported by fine polyester pledgets. A 20-mm half-circle taper needle was ideal for suture placement. Early in the series, polypropylene (Prolene, Ethicon Inc) suture was used, but proved inadequate because of late suture fracture (see "Results"). However, using a high lubricity suture is important to pull the ring tightly up under the annulus, and the annular suture line should be complete, with no gaps, and with bites 2 mm deep to the leaflet-aortic junction above and

D. Quinn, MD,<sup>a</sup> J. Alan Wolfe, MD,<sup>f</sup> Kentaro Yamane, MD,<sup>g</sup> Jeffrey T. Cope, MD,<sup>h</sup> Behzad Solemani, MD,<sup>h</sup> Hiroo Takayama, MD,<sup>h</sup> Victor M. Rodriguez, MD,<sup>i</sup> Takashi Murashita, MD,<sup>j</sup> Rochus K. Voeller, MD,<sup>k</sup> Ming-Sing Si, MD,<sup>l</sup> Melissa Levack, MD,<sup>m</sup> Chris R. Burke, MD,<sup>n</sup> Marc R. Moon, MD,<sup>o</sup> Alexander Kraev, MD,<sup>p</sup> Marek J. Jasinski, MD,<sup>q</sup> Georgios Stavridis, MD,<sup>r</sup> and J. Scott Rankin, MD<sup>b</sup>

<sup>a</sup>Cedars Sinai Medical Center, Los Angeles, Calif, <sup>b</sup>West Virginia University, Morgantown, WVa, <sup>c</sup>University of Utah, Salt Lake City, Utah, <sup>d</sup>St Joseph's Medical Center, Tacoma, Wash, <sup>e</sup>Maine Medical Center, Portland, Me, <sup>f</sup>Northeast Georgia Medical Center, Gainesville, Ga, <sup>g</sup>Pennsylvania State University, Hershey, Pa, <sup>h</sup>Columbia Presbyterian Medical Center, New York, NY, <sup>i</sup>University of California Davis, Sacramento, Calif, <sup>j</sup>University of Missouri, Columbia, Mo, <sup>k</sup>University of Minnesota, Minneapolis, Minn, <sup>l</sup>University of Michigan, Ann Arbor, Mich, <sup>m</sup>Vanderbilt University Medical Center, Nashville, Tenn, <sup>n</sup>University of Washington,

Seattle, Wash, <sup>o</sup>Washington University Medical Center, St Louis, Mo, <sup>p</sup>Billings Clinic, Billings, Mont, <sup>q</sup>Wroclaw Medical University, Wroclaw, Poland, <sup>r</sup>Onassis Heart Center, Athens, Greece.

Received for publication March 2, 2022; revisions received March 2, 2022; accepted for publication March 30, 2022; available ahead of print June 9, 2022.

Address for reprints: Marc W. Gerdisch, MD, Department of Cardiac Surgery, Franciscan Health Indianapolis, Indianapolis, IN 46237 (E-mail: [mgerdisch@openheart.net](mailto:mgerdisch@openheart.net)).

2666-2507

Copyright © 2022 The Authors. Published by Elsevier Inc. on behalf of The American Association for Thoracic Surgery. This is an open access article under the CC BY-NC-ND license (<http://creativecommons.org/licenses/by-nc-nd/4.0/>).

<https://doi.org/10.1016/j.xjtc.2022.03.023>

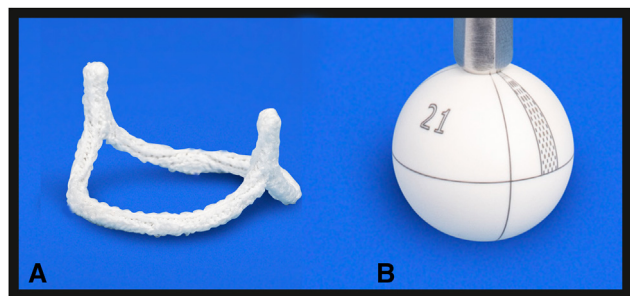
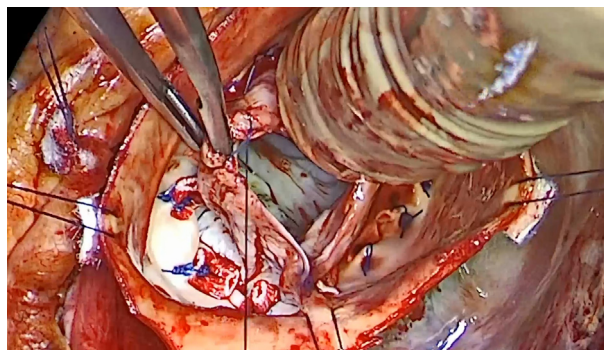
**TABLE 1. Clinical characteristics for patients with bicuspid aortic valve aneurysm**

| Clinical characteristics<br>Descriptive statistics | Total N = 127    |               |
|--|------------------|---------------|
|  | Mean $\pm$ SD    | Median (IQR)  |
| Age (y)  | 50.6 $\pm$ 12.7* | 51 (40-59)    |
| Male, N (%)  | 106/127 (83%)    | –             |
| NYHA Class   | –                | 2 (1-2)       |
| Ascending aortic diameter (mm)                     | –                | 50 (46-54)    |
| Ascending aortic replacement only, N (%)           | 87 (69%)         | –             |
| Root procedures for diameter >45 mm, N (%)         | 40 (31%)         | –             |
| Hemi-root replacements, N (%)                      | 26 (20%)         | –             |
| Aortic clamp time (min)                            | –                | 139 (112-170) |
| Bypass time (min)                                  | –                | 178 (138-217) |
| Preoperative annular diameter (mm)                 | 27.2 $\pm$ 3.7*  | –             |
| Average ring size (mm)                             | –                | 23 (21-23)    |
| Preoperative AI grade                              | –                | 3 (2-4)       |
| Postrepair AI grade                                | –                | 0 (0-0)       |
| Postrepair mean systolic valve gradient (mm Hg)    | –                | 10 (7-14)     |
| Hospital days to discharge                         | –                | 6 (4-8)       |

Clinical descriptive characteristics of the 127 patients undergoing BAV repair and concomitant proximal aortic procedures. *SD*, Standard deviation; *IQR*, interquartile range; *NYHA*, New York Heart Association; *AI*, aortic insufficiency. \*Represents data with normal distribution by D'Agostino and Pearson test. The change in AI grade after repair was statistically significant,  $P < .0001$ .

below the valve. Leaflet reconstruction usually used Schäfers' methods of central leaflet plication and cleft closure (Figure 2). Video 1 shows a technical BAV repair, and a complete description has been published.<sup>4</sup>

After completing the valve repair, decisions were made about which aortic segments to replace using established criteria.<sup>19</sup> In all cases, ascending aortic or root diameter exceeded 45 mm, and ascending aortic replacement was performed with a Dacron graft 5 to 7 mm larger than the ring used in the valve repair, duplicating normal anatomy.<sup>20,21</sup> If the transverse maximal sinus diameter approached or exceeded 45 mm, a remodeling root procedure was performed using a Valsalva graft, again 5 to 7 mm larger than the annuloplasty ring. If the root enlargement was asymmetrically involving only the nonfused sinus (Figure 3), that sinus was excised, and a slightly less than 180° tongue of the graft was sutured to the sinus, usually starting at the nadir and progressing upward toward

**FIGURE 1. A, BAV annuloplasty ring. B, Leaflet ball sizer used in this series.****VIDEO 1. Annuloplasty ring sizing and leaflet reconstructive techniques for BAV repair. Video available at: [https://www.jtcvs.org/article/S2666-2507\(22\)00352-2/fulltext](https://www.jtcvs.org/article/S2666-2507(22)00352-2/fulltext).**

the commissures. The graft anastomosis was continued across the top of the fused sinus, often with a single running suture as an aortic “hemi-root” replacement.<sup>18,22</sup> Video 2 shows BAV repair with hemi-root replacement. If the aortic root was greater than 45 mm in diameter and both sinuses were dilated, the Valsalva graft was fashioned with 2 approximately equal 180° tongues, and the fused sinus was excised. Usually, each tongue was sutured from its respective sinus base with running sutures completed to the tops of the 2 commissures and tied. The vertical graft incisions were extended as necessary to exactly accommodate commissural heights. Finally, coronary buttons were reimplemented into the side of the graft, using standard techniques. The distal anastomoses were completed to the distal ascending aorta or the aortic arch in a hemi-arch fashion. BAV repair with full aortic root replacement is shown in Video 3. If coronary ostia were anomalous or arose close to a commissure, the coronaries could be left in continuity with the commissures and sinus replacement modified accordingly (Video 4). The technique evolved during the study, and the current recommended approach can be viewed in Video 5.


The standard readings of clinical transesophageal Doppler echocardiograms were used to assess AI grade before and after repair using 5 grades: 0 = none or trivial, 1 = mild, 2 = moderate, 3 = moderately severe, and 4 = severe.<sup>23</sup> Prerepair AI grades were compared with those obtained after repair with a 2-tailed paired *t* test. This was not an echocardiographic longitudinal follow-up study, but the “last available” echocardiography data were documented, along with times since the index surgery. Five repair failures occurred during follow-up, and the worse AI grade observed before reoperation was permanently assigned as the last echocardiography in those patients, specifically penalizing reoperation. Mean systolic aortic valve gradients also were measured for the same time points from Doppler velocity data using standard algorithms. Normally distributed data were presented as mean  $\pm$  standard deviation, and non-normal data as median (interquartile range). Categorical data were described as percentages. Pre-repair pathologic annular diameter was compared with “ideal” annular diameter, measured as nonfused leaflet free-edge length/1.5,<sup>4</sup> using a 2-tailed paired *t* test and linear regression analysis. Freedom from the composite of all-cause death, reoperation, and valve-related complications was analyzed as the most conservative assessment of outcomes, minimizing competing risks. By using the composite outcome variable, time-to-event analysis was performed with Kaplan–Meier techniques and the statistical package of Prism 9.0 (GraphPad Software, Inc). Ninety-five percent confidence limits were calculated by the exponential Greenwood formula. For this descriptive presentation, all survival data were displayed, but the last 10% were differentiated from the other 90% by lighter shading.

## RESULTS

All BAV repairs were completed successfully, with no intraoperative conversions from repair to prosthetic valve



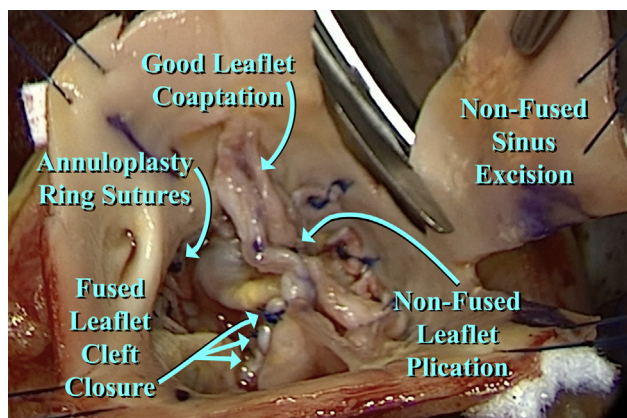
## Bicuspid Leaflet Reconstruction (Modified from Schäfers)



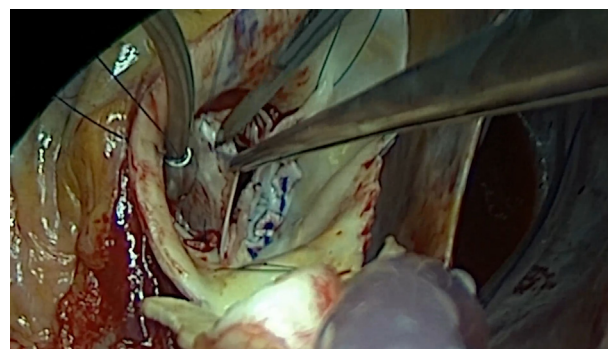
**FIGURE 2.** A, Typical type 1 BAV is shown with the right-left commissure comprising a complete fusion (fused leaflet raphe) and a thickened fused cusp cleft. B, The leaflet reconstruction is begun by plicating the nonfused cusp to an 8- to 10-mm effective height. C, Spacing sutures are placed from the center of the nonfused cusp across to the fused cusp, equidistant from the commissure, on both sides of the cleft. This sets up the cleft for closure, producing a 2-leaflet valve with similar effective height, geometric height, and free-edge length. Illustration adopted from Schäfers<sup>35</sup> with permission. *eH*, Effective height; *gH*, geometric height; *FEL*, free-edge length.

replacement. Ring size was 23 (21-23) mm (Table 1), aortic clamp time was 139 (112-170) minutes, and bypass time was 178 (138-217) minutes. Twenty-six of the 40 root procedures were selective nonfused sinus or hemi-root

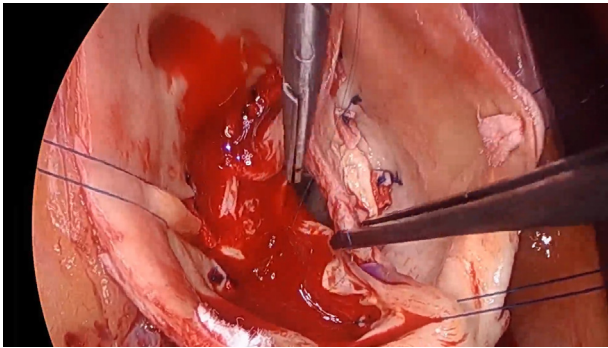
replacements. Mild to moderately calcified valves were de-calcified with the ultrasonic aspirator in 31 patients (24%). Five patients had repair of unicuspid defects.<sup>16</sup> Intraoperative postrepair AI grade was 0 (0-0) ( $P < .0001$  vs preresult), and mean valve gradient was 10 (7-14) mm Hg. No 30-day, in-hospital operative mortalities occurred. Four patients required reoperation for bleeding, and 5 patients required



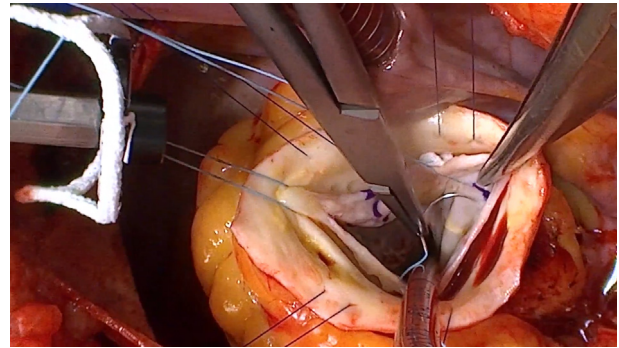
**FIGURE 3.** After BAV repair, the ring annular sutures are evident, as well as the linear cleft closure and nonfused leaflet plication. An asymmetrically enlarged noncoronary sinus is being excised in preparation for an ascending aortic and hemi-root replacement. Leaflet coaptation is good with similar effective height, geometric height, and free-edge length.



**VIDEO 2.** Techniques of BAV repair and associated hemi-root remodeling. Video available at: [https://www.jtcvs.org/article/S2666-2507\(22\)00352-2/fulltext](https://www.jtcvs.org/article/S2666-2507(22)00352-2/fulltext).



**VIDEO 3.** BAV repair with full remodeling root replacement. Video available at: [https://www.jtcvs.org/article/S2666-2507\(22\)00352-2/fulltext](https://www.jtcvs.org/article/S2666-2507(22)00352-2/fulltext).

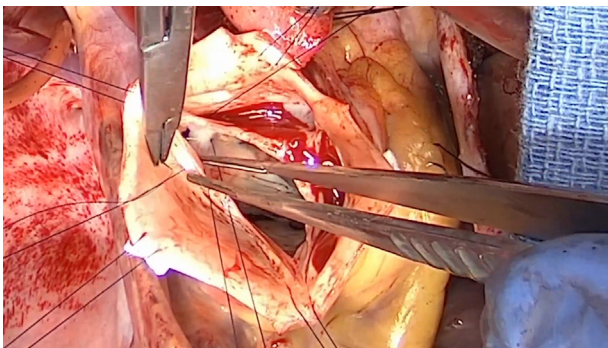


**VIDEO 5.** Current techniques of BAV repair to optimize late success rates. Video available at: [https://www.jtcvs.org/article/S2666-2507\(22\)00352-2/fulltext](https://www.jtcvs.org/article/S2666-2507(22)00352-2/fulltext).

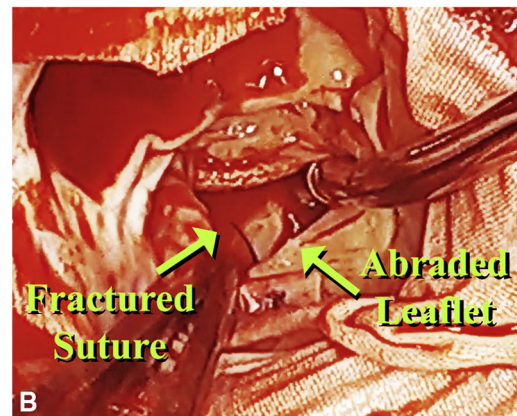
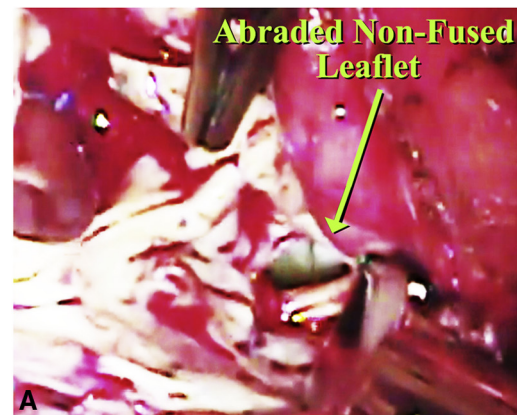
pacemakers (4%). Follow-up closing date was November 30, 2021. With a mean follow-up of 20-months (maximal 93 months; maximal in 90% of patients 43 months), 5 patients required aortic valve replacement for interval repair failure.

The first patient with repair failure experienced rupture of the commissural aspect of a leaflet, thought by the surgeon to reflect placement of the ring post too high in the sub-commissural triangle. Contact between the polyester covering of the ring post and the commissural leaflet tissue seemed to have abraded and ruptured the leaflet. A mechanical valve was placed. This sort of leaflet abrasion has been observed if the ring was sutured to the base of a leaflet (rather than 2 mm back into the annulus), as shown in a non-aneurysmal BAV repair reported previously<sup>24</sup> (Figure 4, A). No contact between ring polyester and leaflet tissue should be permitted. Two repair failures in the present series were due to fracture of polypropylene ring looping sutures, with release of the rings into the center of the valve and abrasion of the adjacent leaflets (Figure 4, B). These valves were replaced with mechanical prostheses. The fourth repair failure was thought to be due to a gap in the annular suture line that allowed the ring to move out under the leaflet and abrade it. A mechanical valve was placed. A fifth patient developed breakdown of a raphe closure 2 months after surgery,

perhaps due to overzealous fused leaflet thinning, and required a mechanical valve. All 5 reoperated patients recovered uneventfully, and no further annular suture failures have occurred since switching to braided polyester suture in the spring of 2021. Throughout the study period, no



**VIDEO 4.** Repair of BAV with root aneurysm and associate coronary artery anomalies. Video available at: [https://www.jtcvs.org/article/S2666-2507\(22\)00352-2/fulltext](https://www.jtcvs.org/article/S2666-2507(22)00352-2/fulltext).

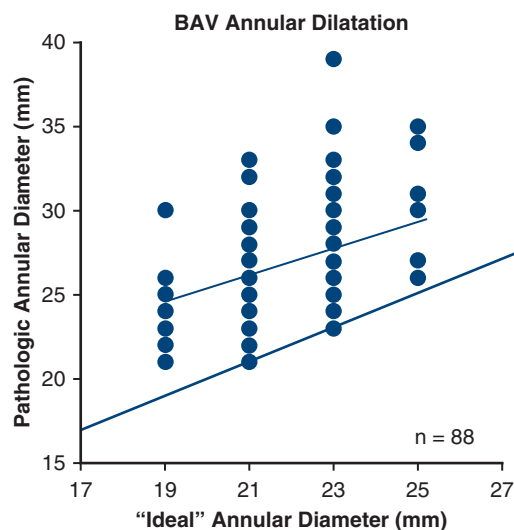


**FIGURE 4.** A, BAV repair failure due to suturing ring into the base of the nonfused cusp with subsequent leaflet abrasion from ring Dacron. This was a nonaneurysmal BAV repair, reported previously.<sup>24</sup> B, Video frame from the third repair failure, showing a fractured polypropylene suture, release of the ring toward the valve center, and abrasion of the leaflet.



valve-related complications occurred. One unvaccinated patient died of Coronavirus Disease 2019 infection 4 months after surgery. At that hospitalization, AI grade was 0, mean valve gradient was 17 mm Hg, and ejection fraction was 0.55.

A graph from 88 patients illustrating pathologic annular diameter observed before repair versus the “ideal” annular diameter predicted from leaflet free-edge length is shown in Figure 5. A few patients exhibited little annular dilatation, but in most, the pathologic diameter was significantly above the line of identity. On average, pathologic diameter was approximately 5 mm larger than “ideal” (Table 1) ( $P < .0001$ ), similar to analyses for trileaflet AI. In defining echocardiographic variables at “latest follow-up,” the 5 repair failures cases had the last value before reoperation recorded; 17 patients had not had a follow-up echocardiogram yet or it was obtained elsewhere; in those cases, the operative data were used; 75 were recorded in the first postoperative year; 15 were obtained in the second postoperative year; 5 were obtained in the third postoperative year; 3 were obtained in the fourth postoperative year; and 7 were obtained between 4 and 8 years. Including the 5 repair failures receiving reoperation for grade 3 to 4 AI, the follow-up AI grade was 0 (0-1) ( $P < .0001$  vs preoperative). At the last echocardiography, only 3 patients had stable grade 2 AI, and 119 patients had insignificant grade 0-1 AI. The corresponding mean valve gradient was 12 (8-16). A Kaplan-Meier time to event curve of composite freedom from



**FIGURE 5.** Comparison of pathologic annular diameter (measured with a Hegar dilator before repair) to the “ideal” annular diameter predicted from leaflet free-edge length/1.5 in the 88 patients with prerepair Hegar annular diameter measurements. The line of identity is the heavy thick line, and the linear regression is the thinner line. The regression equation was  $Y = 0.7886 \times X + 9.627$  ( $P < .0001$ ). Mean  $\pm$  standard deviation for pathologic diameter was  $27.3 \pm 3.7$  mm and for “ideal” diameter was  $22.7 \pm 1.9$  mm ( $P < .0001$ ). BAV, Bicuspid aortic valve.

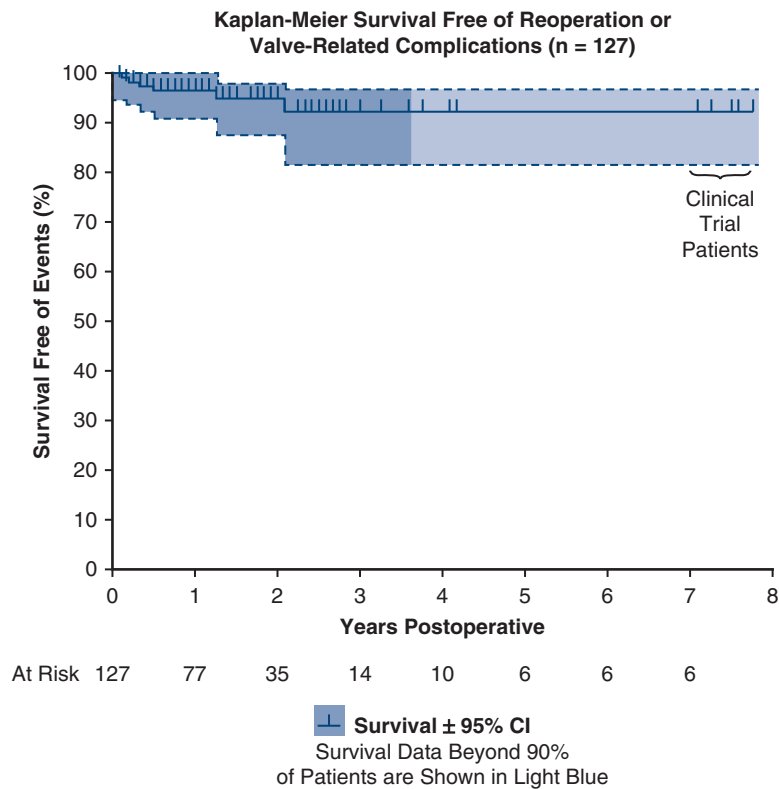
all-cause death, reoperation, and valve-related complications over time is shown in Figure 6. A Graphical Abstract is included as Figure 7.

## DISCUSSION

Organized efforts to repair insufficient BAVs were initiated by Cosgrove and colleagues<sup>25</sup> in the late 1980s. However, techniques were rudimentary, usually using sub-commissural mattress sutures for annuloplasty<sup>26</sup> and leaflet wedge resections for prolapse correction.<sup>25</sup> Subsequent follow-up in the 1990s revealed unacceptable AI recurrence rates using these techniques,<sup>27</sup> and efforts to develop practical BAV repair abated. In the late 1990s, Schäfers and co-workers<sup>28</sup> published a series of patients and illustrations of central leaflet plication for management of leaflet prolapse. Because prolapse is such a prominent feature of bicuspid AI, this innovation was a major enabler for readdressing BAV repair, and the Homburg group<sup>1</sup> recently published their subsequent 20-year experience with excellent long-term results. For replacement of associated proximal aortic aneurysms, these surgeons modified remodeling techniques to their current mature state.<sup>29</sup> The approach to BAV repair used in the current article largely uses Schäfers’ methods, only with ring annuloplasty added to the repair.<sup>18</sup> Our interest in ring annuloplasty was derived from Carpentier’s work,<sup>30</sup> anticipating that an annuloplasty ring, designed specifically for aortic valve geometry, could improve success and reproducibility of BAV repair.<sup>18,22</sup>

Annuloplasty is a fundamental component of cardiac valve repair, and full annuloplasty is accepted as a predictor of durability in BAV repair.<sup>31</sup> As with mitral and tricuspid valve insufficiency, most aortic valves with chronic AI exhibit annular dilatation.<sup>32</sup> Reduction in annular dimension to a value appropriate for leaflet size is an objective method of ring sizing and a significant advantage of this approach.<sup>4,18</sup> Moreover, remodeling BAV annular geometry to 180° commissures allows routine repair of valves with a variety of commissural orientations, such as intermediate-type BAV with 3 equal sinuses and unicuspid valves.<sup>16</sup> In so doing, BAV ring annuloplasty provides substantial advantages over other methods of BAV repair.<sup>4</sup> The major ring remodeling that equalizes the fused and nonfused annular segments (no matter the baseline anatomy) allows repair of virtually all BAV defects in the absence of severe calcification. Mild to moderate degrees of calcification also can be managed with the ultrasonic aspirator,<sup>4</sup> converting most insufficient bicuspid valves to repair candidates.

BAV ring annuloplasty also is advantageous when performed concomitant to remodeling aortic replacement. The procedure can be tailored to specific sinus and coronary anatomy (Video 3). Only the nonfused sinus needs to be replaced when asymmetric sinus enlargement is present (Video 2). This approach comprised approximately two-thirds of our patients with root enlargement and



**FIGURE 6.** Kaplan–Meier analysis of time-varying events after BAV and proximal aneurysm repair in 127 patients. The composite outcome of interest was survival free of reoperation or valve-related complications. Patients from the early device clinical trials are on the upper right. Blue shading indicates  $\pm 95\%$  confidence limits. Lighter blue shading denotes data from the last 10% of the population. *CI*, Confidence interval.

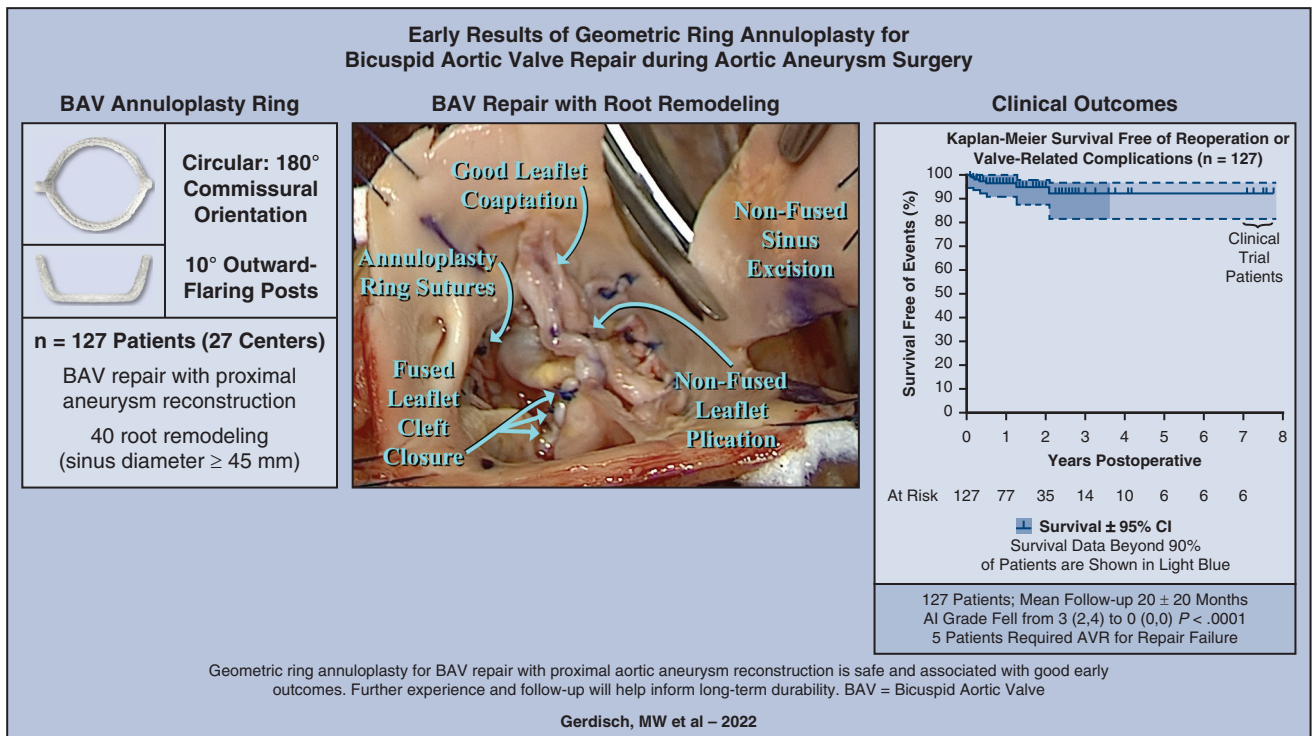
significantly simplified the procedures. Anomalous coronary arteries arising close to a commissure could be left intact, with the sinus suture line coursing outside of the coronary/commissural complex (Video 4). In most cases, remodeling is simpler and more expeditious than reimplantation. The permanent pacemaker rate in this study was 4%, which may be higher than for other techniques. This rate could be reduced in future cases by limiting suture depth into the septal muscle beneath the right/noncoronary commissure, although understanding of conduction system anatomy in BAV defects currently is lacking.

Separating the valve repair from aneurysm management also has advantages. As discussed, initially creating and maintaining favorable annular geometry allow assessment of reparability as the first step and provide opportunity to address the entire valve pathology before replacing any portion of the aorta. As such, identification of an inadequate repair is not delayed until after the entire aortic procedure, and this aspect may assist the surgeon in the decision to treat more complex valve anatomies. Moreover, external deep aortic root dissection is not required, as with both reimplantation and external bands. In some BAV cases, a right sinus muscle bar can make external annuloplasty difficult, and with internal rings, this problem and the variable of aortic thickness are avoided. With both external bands and circular

annuloplasty sutures, the bands can cut through the aorta, disrupting the entire root.

Aortic ring annuloplasty can also have technical problems. In the first clinical trials 10 years ago, the 2-year repair failure rate was 11%,<sup>33</sup> mostly from annular suture untying and leaflet injuries due to long annular suture tails. The development of lateral suture fixation<sup>22</sup> largely eliminated these complications, and in the current series, the early repair failure rate decreased by two-thirds, although these were the first ring BAV repairs performed by most of the surgeons. Even with early failures, events in the present series were low and similar to most contemporary repair series.<sup>1,34</sup> Given the technical nature of all 5 repair failures, it is possible that results could improve further with more experience. Moreover, suture failure with fracture of Prolene annular sutures was found to occur, and together with refined ring sizing strategies (Video 1), the change to braided polyester annular sutures seems to have reduced failure rates to very low levels (Video 5). Thus, compared with other techniques, aortic ring annuloplasty seems to achieve similar outcomes, but has the possible advantage of better reproducibility and greater applicability to more difficult pathologies.

One repair failure in this series was a technical issue of suturing the ring post too high in the sub-commissural space



**FIGURE 7.** Graphical summary of the study showing the geometry of the BAV annuloplasty ring on the left, an operative photograph of the leaflet repair technique in the center, and the outcomes observed on the right. BAV, Bicuspid aortic valve; CI, confidence interval; AI, aortic insufficiency; AVR, aortic valve replacement.

with abrasion of the commissural leaflet. This type of problem emphasizes the importance of detailed initial surgeon training and continued video proctoring until the learning curve is traversed.<sup>34</sup> Similar leaflet abrasion can be produced by suturing rings directly into leaflets (Figure 4, A),<sup>24</sup> loosely tied sutures, or suture line gaps, emphasizing the importance of tight juxtaposition of each ring under the entire annulus, 2 mm deep to the leaflet-aortic junction. Three repair failures occurred because of fracture of polypropylene annular sutures and annular suture line gaps. In both situations, the rings were released into the center of the valves with subsequent leaflet abrasion (Figure 4, B). Polypropylene initially was used for annular sutures because of its ability to slide and oppose the ring tightly beneath the annulus. Although the incidence of polypropylene suture fracture has been low, it now seems reasonable to use braided polyester sutures instead, which seem to have less tendency toward fracture than the more brittle polypropylene (Video 5).

Unlike trileaflet aortic rings where liberal downsizing can be useful (and transvalvular gradients are low),<sup>4,33</sup> bicuspid ring true-sizing (or even upsizing if there is any question) is important to minimize higher mean valve gradients (Video 1). Emphasizing the maintenance of inter-commissural dimension, while reducing sinus-to-sinus diameter, optimizes ring size, reduces leaflet plication, and minimizes consequent gradients. Larger sized rings also may reduce suture line stress and

suture failure. Shaving of dysplastic leaflets or commissural decalcification is important, along with avoiding overplication<sup>35</sup> by maintaining leaflet free-edge length greater than half of the ring circumference (Videos 1, 2, and 5). In special circumstances, however, more plication may be required for reasons of valve competence, and initial mean systolic gradients of 20 to 30 mm Hg have been tolerated well. Over weeks to months postoperatively, such gradients usually fall below 20 mm Hg, possibly because the living leaflet tissue adapts to the hemodynamic milieu.<sup>18</sup> With proper BAV ring sizing, postrepair gradients should be low in the majority of patients (Video 1).

**Study Limitations**

This descriptive study is limited by its observational nature, short follow-up, and small sample size. The echocardiographic follow-up uses only routine clinical data and must be considered as only a first glimpse to rule out large issues, with a future need for proper longitudinal echocardiography analysis. With the exception of the 5 technical repair failures, however, deterioration over time was not detected, and it is important to observe 6 original clinical trial patients doing well almost 8 years after surgery. In this regard, the analysis was not intended as a definitive statement of the propriety of BAV plus aortic aneurysm repair, but rather a first significant description of an approach developed by the authors in the initial phases of US and European




clinical application. Since the first regulatory trials of geometric ring annuloplasty, many small problems have been identified and corrected, and technique development now may be asymptotically approaching 100% efficacy. Still, only future case assessment will tell, and more experience and follow-up will be necessary to validate these strategies. Hopefully, the broader anatomic application possible with ring annuloplasty, together with the emerging superiority of BAV repair,<sup>1</sup> will allow autologous BAV reconstruction to be the dominant surgical procedure in the future.

## CONCLUSIONS

Geometric ring annuloplasty for BAV repair combined with proximal aortic reconstruction, including root remodeling, is safe and associated with good early outcomes. The composite of postrepair events is low, and results are consistent with other types of aortic valve repair, but with perhaps greater applicability. The methods are still evolving and could improve further in coming years. Internal geometric rings could form the basis of standardizing BAV repair, as well as extending repair into anatomies that were previously challenging. Further experience and follow-up will be necessary to validate long-term durability.

## Webcast

You can watch a Webcast of this AATS meeting presentation by going to: [https://aats.blob.core.windows.net/media/21%20AM/AM21\\_A20/AM21\\_A20\\_02\\_REVISED.mp4](https://aats.blob.core.windows.net/media/21%20AM/AM21_A20/AM21_A20_02_REVISED.mp4).



## Conflict of Interest Statement

The aortic annuloplasty ring was developed by BioStable Science and Engineering ([www.biostable-s-e.com](http://www.biostable-s-e.com)) and is Food and Drug Administration approved in the United States (21 CFR 870.3800) and CE Marked in Europe (G7 103732 0008). Drs Gerdisch, Baker, and Rankin are consultants for this company. All other authors reported no conflicts of interest.

The *Journal* policy requires editors and reviewers to disclose conflicts of interest and to decline handling or reviewing manuscripts for which they may have a conflict of interest. The editors and reviewers of this article have no conflicts of interest.

## References

- Miyahara S, Schneider U, Margenthaler L, Schaefer HJ. (Almost) all nonstenotic bicuspid aortic valves should be preserved or repaired. *Semin Thoracic Surg.* 2019;31:656-60.

- Caceres M, Ma Y, Rankin JS, Saha-Chaudhuri P, Englum BR, Gammie JS, et al. Mortality characteristics of aortic root surgery in North America. *Eur J Cardiothorac Surg.* 2014;46:887-93.
- Rankin JS, Mazzitelli D, Fischlein TJM, Choi YH, Pirk J, Pfeiffer S, et al. Geometric ring annuloplasty for aortic valve repair during aortic aneurysm surgery: two-year clinical trial results. *Innovations.* 2018;13:248-53.
- Rankin JS, Wei LM, Downey RS, Si MS, Gerdisch MW, Kupferschmid JP, et al. Aortic valve repair using geometric ring annuloplasty. *Oper Tech Thorac Cardiovasc Surg.* 2021;26:173-83.
- Aicher D, Fries R, Rodionycheva S, Schmidt K, Langer F, Schafers HJ. Aortic valve repair leads to a low incidence of valve-related complications. *Eur J Cardiothorac Surg.* 2010;37:127-32.
- Price J, De Kerchove L, Glineur D, Vanoverschelde JL, Noirhomme P, El Khoury G. Risk of valve-related events after aortic valve repair. *Ann Thorac Surg.* 2013;95:606-13.
- de Meester C, Pasquet A, Gerber BL, Vancraeynest D, Noirhomme P, El Khoury G, et al. Valve repair improves the outcome of surgery for chronic severe aortic regurgitation: a propensity score analysis. *J Thorac Cardiovasc Surg.* 2014;148:1913-20.
- Price J, Magruder JT, Young A, Grimm JC, Patel ND, Alejo D, et al. Long-term outcomes of aortic root operations for Marfan syndrome: a comparison of Bentall versus aortic valve-sparing procedures. *J Thorac Cardiovasc Surg.* 2016;151:330-6.
- David TE, David CM, Ouzounian M, Feindel CM, Lafreniere-Roula M. A progress report on reimplantation of the aortic valve. *J Thorac Cardiovasc Surg.* 2021;161:890-9.e1.
- de Kerchove L, Boodhwani M, Glineur D, Vandyck M, Vanoverschelde JL, Noirhomme P, et al. Valve sparing-root replacement with the reimplantation technique to increase the durability of bicuspid aortic valve repair. *J Thorac Cardiovasc Surg.* 2011;142:1430-8.
- Patlolla SH, Schaff HV, Stulak JM, Michelena HI, Saran N, King KS, et al. Bicuspid aortic valve repair: causes of valve failure and long-term outcomes. *Ann Thorac Surg.* 2021;111:1225-32.
- Alashi A, Khullar T, Mentias A, Gillinov AM, Roselli EE, Svensson LG, et al. Long-term outcomes after aortic valve surgery in patients with asymptomatic chronic aortic regurgitation and preserved LVEF: impact of baseline and follow-up global longitudinal strain. *JACC Cardiovasc Imaging.* 2020;13:12-21.
- Aicher D, Kunihara T, Abou Issa O, Brittner B, Graber S, Schafers HJ. Valve configuration determines long-term results after repair of the bicuspid aortic valve. *Circulation.* 2011;123:178-85.
- Igarashi T, Matsushima S, Shimizu A, Ehrlich T, Karliova I, Schafers HJ. Bicuspidization and annuloplasty provide a functioning configuration to the unicuspid aortic valve. *Ann Thorac Surg.* 2020;110:1111-9.
- Leontyev S, Schamberger L, Davierwala PM, Von Aspern K, Etz C, Lehmann S, et al. Early and late results after David vs Bentall procedure: a propensity matched analysis. *Ann Thorac Surg.* 2020;110:120-6.
- Si M-S, Conte JV, Romano JC, Romano MA, Andersen ND, Gerdisch MW, et al. Unicuspid aortic valve repair using geometric ring annuloplasty. *Ann Thorac Surg.* 2021;111:1359-66.
- Schäfers HJ, Kunihara T, Fries P, Brittner B, Aicher D. Valve-preserving root replacement in bicuspid aortic valves. *J Thorac Cardiovasc Surg.* 2010;140:S36-40; discussion S5-51.
- Rankin JS, Mazzitelli D, Fischlein TJM, Choi Y-H, Aicher D, Wei LM, et al. Bicuspid aortic valve repair using geometric ring annuloplasty: a first-in-humans pilot trial. *JTCVS Tech.* 2020;1:18-25.
- Svensson LG, Adams DH, Bonow RO, Kouchockos NT, Miller DC, O'Gara PT, et al. Aortic valve and ascending aorta guidelines for management and quality measures. *Ann Thorac Surg.* 2013;95:S1-66.
- Rankin JS, Bone MC, Fries PM, Aicher D, Schafers HJ, Crooke PS. A refined hemispheric model of normal human aortic valve and root geometry. *J Thorac Cardiovasc Surg.* 2013;146:103-9.
- Crooke PS, Beavan LA, Griffin CD, Mazzitelli D, Rankin JS. A geometric model of the normal human aortic root and design of a fully anatomic aortic root graft. *Innovations (Phila).* 2015;15:57-62.
- Mazzitelli D, Pfeiffer S, Rankin JS, Fischlein T, Choi YH, Wahlers T, et al. A regulated trial of bicuspid aortic valve repair supported by geometric ring annuloplasty. *Ann Thorac Surg.* 2015;99:2010-6.
- Zoghbi WA, Enriquez-Sarano M, Foster E, Grayburn PA, Kraft CD, Levine RA, et al. Recommendations for evaluation of the severity of native valvular regurgitation with two-dimensional and Doppler echocardiography. *J Am Soc Echocardiogr.* 2003;16:777-802.

24. Baker JN, Klokocovnik T, Miceli A, Glauber M, Wei LM, Badhwar V, et al. Minimally invasive aortic valve repair using geometric ring annuloplasty. *J Card Surg.* 2022;37:70-5.
25. Cosgrove DM, Rosenkranz ER, Henderson WG, Barlett JC, Stewart WJ. Valvuloplasty for aortic insufficiency. *J Thorac Cardiovasc Surg.* 1991;102:571-7.
26. Cabrol A, Guiraudon G, Bertrand M. Le traitement de l'insuffisance aortique par l'annuloplastie aortique. *Arch des Mal du Coeur.* 1966;59:1305-12.
27. Casselman FP, Gillinov AM, Akhrass R, Kasirajan V, Blackstone EH, Cosgrove DM. Intermediate-term durability of bicuspid aortic valve repair for prolapsing leaflet. *Eur J Cardiothorac Surg.* 1999;15:302-8.
28. Schäfers HJ, Aicher D, Langer F. Correction of leaflet prolapse in valve-preserving aortic replacement: pushing the limits? *Ann Thorac Surg.* 2002;74:1762-4.
29. Schäfers HJ, Aicher D. Root remodeling for aortic root dilatation. *Ann Cardiothorac Surg.* 2013;2:113-6.
30. Carpentier A. Cardiac valve surgery - the "French correction". *J Thorac Cardiovasc Surg.* 1983;86:323-37.
31. Jasinski MJ, Kosiorowska K, Gocol R, Jasinski J, Nowicki R, Bielicki G, et al. Bicuspid aortic valve repair, outcomes after 17 years of experience. *Eur J Cardiothorac Surg.* 2021;60:1053-61.
32. Jasinski MJ, Rankin JS, Mazzitelli D, Fischlein T, Choi Y-H, Wei LM, et al. Leaflet dimensions as a guide to geometric annuloplasty during aortic valve repair. *Innovations.* 2021;16:267-72.
33. Mazzitelli D, Fischlein T, Rankin JS, Choi YH, Stamm C, Pfeiffer S, et al. Geometric ring annuloplasty as an adjunct to aortic valve repair: clinical investigation of the HAART 300 device. *Eur J Cardiothorac Surg.* 2016;49:987-93.
34. Malas T, Saczkowski R, Sohmer B, Ruel M, Mesana T, de Kerchove L, et al. Is aortic valve repair reproducible? Analysis of the learning curve for aortic valve repair. *Can J Cardiol.* 2015;31:1497.e15-22.
35. Schäfers HJ. Reconstruction of the bicuspid aortic valve. *Oper Tech Thorac Cardiovasc Surg.* 2007;12:2-13.

**Key Words:** aortic aneurysm repair, aortic insufficiency, bicuspid valve repair

## Discussion

**Presenter: Dr Marc W. Gerdisch**

**Moderator: Dr Tirone E. David**



**Dr Hans-Joachim Schäfers** (*Saar, Germany*). First, my congratulations for this presentation and the excellent clinical results. Also, my thanks for giving me the chance to review the manuscript in advance. As background, we need to keep in mind that, in isolated bicuspid repair for aortic regurgitation, the presence of annular dilatation is important, and the use of an annuloplasty, as well as creation of a symmetric postoperative valve configurations, are important prerequisites for durable valve function.

In interpreting your results, we need to keep in mind that these were predominantly or primarily aortic patients, because all 70 underwent aortic surgery, and you have a multicenter study. The common denominator really is the annuloplasty device. Let's keep in mind mean crossclamp time was 145 minutes and pacemaker rate was 4%, which is, in my mind, a bit on the high side. The 3 reoperations

that you mentioned were apparently related to abrasion of cusp tissue in 1 patient and ring dehiscence in the other 2, and this needs to be kept in mind when judging the effect of the annuloplasty result. The interpretation is not facilitated by the heterogeneity of valves. You use the Sievers classification to describe it, which I don't find very helpful. Maybe the de Kerchove classification from symmetric to very asymmetric would be helpful.

Three of your patients were classified with type 2 Sievers, which is a unicuspid valve. Mean aortic regurgitation (AR) was only 2.4. The majority of patients apparently had lesser degrees of AR preoperatively, and the heterogeneous operations as you described.

In trying to bring a little more clarity in judging the effect of the annuloplasty and the operation, in how many instances was symptomatic AR the indication for surgery? And could you state preoperative annular diameters? Another interesting question with these annuloplasty devices, which tend to be a little on the small side, but gradients are apparently good, have these gradients remained stable over time? I would like to thank the Society for the privilege of discussing the papers, and also my compliments and thanks to you for this honest report. In my mind, further experience, more follow-up, and a more homogeneous cohort will be needed to judge the risk-benefit ratio of this annuloplasty. Maybe you can clarify a few of these aspects.

**Dr Marc W. Gerdisch** (*Indianapolis, Ind*). Thank you, Dr Schäfers, for taking the time to review the paper and asking these very important questions, which, to be honest, I had considered myself and lead up to this thought, in part, because in your own literature you reflect on some of these issues. I'll try to be as brief as possible. I do think classification with respect to asymmetry would be more accurate for assessing efficacy of the repair. Our data collection up to that point wasn't quite as robust as perhaps it should've been, although now it is. We have a much more detailed methodology for collecting data, which we need to prepare going forward. The intention of the paper was to show the robust response amongst surgeons, talented surgeons admittedly, adopting the technology and then performing repairs. With respect to the severity of congestive heart failure symptoms, I can't give you a breakdown. I would just offer that the mean value shows an improvement in the overall incidence of congestive heart failure. With respect to asymmetry, it's important to notice, and you did mention that we had some Sievers 2, and that we treated intermediate type 1 as well. We have an aggressive approach to repair in this cohort, meaning asymmetry was considered a factor, but in general all valves were approached with a plan to repair, and in fact, they were repaired.

When we look for example at your experience, 15 years, 150 patients with remodeling and superb outcomes, you also point out that most of those patients approximate a

180 configuration. There are not many of patients with diverse anatomy. So, the driving thought was first, could we take surgeons that do valve repair in general and expand their capability? Could they repair more valves, and more complex anatomy? In centers of excellence like yours or perhaps Dr David's—and Dr David has a recent commentary saying that the reimplantation model has been incredibly successful but largely in normal leaflets and is now just being expanded to more complex leaflet morphology. Still, when we think about the overall experience as Dr David showed earlier today, 465 patients over 30 years in the busiest reimplantation center, perhaps in the world, there's something missing for most surgeons, right? There are many surgeons who are encountering anatomy that either they've never addressed before or perhaps they're not comfortable even with simple anatomy. So, the goals here were twofold: to expand applicability for surgeons who are already comfortable with aortic valve repair to do more complex repairs and then to also expand opportunity for surgeons and patients who are in the operating room with simple anatomy that might otherwise not be repaired. This experience provides insight that the early outcomes are

like those seen in centers of excellence, including with diverse anatomy.

We know, for example, a large root, a lot of leaflet work, and bicuspid anatomy, all contributed to earlier failures in the David operation. Chen showed that nicely. We can debate whether it is true for everybody, but the question is whether there is a way for us to standardize the experience for the surgeon, drive the anatomy more toward a 180 configuration safely, and then address the leaflets with the techniques that you've established, to achieve repair in most cases. Could it be the same kind of process we went through over several decades with mitral valve repair? We've perhaps accelerated it little bit for aortic valve repair. Now, time will tell as you mentioned, and we do have to delineate in detail symmetrical versus asymmetrical. With respect to complex anatomies, some patients we have converted for intermediates to tricuspid or bicuspid, and all of it will be published over time. But, again, the goal here was not to say this is the only way to repair a valve. It was to demonstrate this is a way to repair a valve that can be standardized, that can be performed in 15 different centers with results that are acceptable, and appropriate for aortic valve repair.