



RESEARCH PAPER

The role of serial physical examinations in the management of angioedema involving the head and neck: A prospective observational study[☆]



Gary Linkov^a, Jennifer R. Cracchiolo^a, Norman J. Chan^a, Megan Healy^b, Nausheen Jamal^a, Ahmed M.S. Soliman^{a,*}

^a Department of Otolaryngology-Head & Neck Surgery, Temple University School of Medicine, Philadelphia, PA 19140, USA

^b Department of Emergency Medicine, Temple University School of Medicine, Philadelphia, PA 19140, USA

Received 27 November 2015; received in revised form 31 December 2015; accepted 5 January 2016
Available online 9 February 2016

KEYWORDS

Angioedema;
Physical examination;
Fiberoptic
laryngoscopy

Abstract *Objective:* To elucidate the progression of angioedema of the head and neck with routine management and to assess the utility of serial physical exams and fiberoptic laryngoscopy in its management.

Methods: This study was a prospective observational research. From 2013 to 2014, a prospective observational study was conducted at a tertiary referral center. Forty patient were approached, 7 refused, 33 (18–90 years old) were enrolled. Patients presented with angioedema involving the head and neck over a 12 month period were asked to participate in the study. Physical examination and fiberoptic laryngoscopy were performed at presentation and then repeated at least 1 h later.

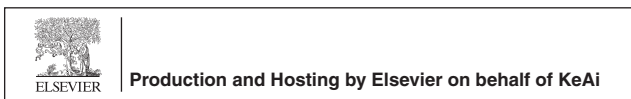Results: Thirty-three patients with head and neck angioedema from any cause were enrolled (mean age 58, range 23–89 years). The upper lip was the most commonly involved site (58%). On reevaluation, 82% of patients reported subjective improvement in symptoms. The

[☆] Presentation: Poster presented at the American Laryngological Association 2015 meeting, Boston, MA.

* Corresponding author. Department of Otolaryngology-Head & Neck Surgery, Temple University School of Medicine, 3400 North Broad Street, Kresge West 312, Philadelphia, PA 19140, USA. Tel.: +1 215 707 3665; fax: +1 215 707 7523.

E-mail address: asoliman@temple.edu (A.M.S. Soliman).

Peer review under responsibility of Chinese Medical Association.



association between subjective improvement and the physical exam, including fiberoptic laryngoscopy findings, was statistically significant ($P < 0.001$).

Conclusion: In stable patients with angioedema of any head and neck subsite, self-reported symptoms are associated with clinical stability or improvement as assessed by physical signs and fiberoptic laryngoscopy. Patients' symptoms may be an appropriate surrogate to monitor clinical status without the need for routine serial physical examinations or fiberoptic laryngoscopy, though further study is needed.

Copyright © 2016 Chinese Medical Association. Production and hosting by Elsevier B.V. on behalf of KeAi Communications Co., Ltd. This is an open access article under the CC BY-NC-ND license (<http://creativecommons.org/licenses/by-nc-nd/4.0/>).

Introduction

Angioedema (AE) is defined as a self-limited, localized swelling that often occurs in the head and neck. It most commonly affects the face, lips, palate, and tongue, with laryngeal involvement occurring less frequently. It results from increased permeability of the vasculature supplying the subcutaneous, submucosal, and deep dermal tissues. AE can occur in both sporadic and hereditary forms. AE of the head and neck is potentially life-threatening, as it may lead to airway compromise.

Airway management is the single most important aspect of acute therapy, regardless of the etiology of AE.^{1,2} The otolaryngologist is frequently consulted to evaluate the patient and to determine the need for acute airway intervention. Though serial physical examinations, including fiberoptic laryngoscopy, are routinely performed to determine the progression of disease, the utility of this approach has not been adequately studied.

To date, there have been few studies investigating the appropriate management of patients with AE.^{3–10} Most are retrospective reviews that report the authors' clinical experience with AE and subsequently make recommendations regarding best practices. Only one study has prospectively examined angioedema triggered by angiotensin-converting enzyme inhibitors (ACEi), however, the authors did not correlate symptomatology with findings on serial physical examinations.⁴

The goal of this study was to elucidate the progression of angioedema of the head and neck with routine medical management and to assess the utility of serial physical exams, including the use of fiberoptic laryngoscopy.

Materials and methods

After institutional review board approval was obtained, all patients presenting to the Emergency Department (ED) with angioedema involving the head and/or neck between December 2013 and December 2014 were asked to participate in this prospective, observational study. Informed consent was obtained on the day of discharge for all patients in this study, including those discharged from the ED on the day of presentation. Patients who were medically unstable or required emergent intubation were excluded. Patients received standard and similar medical management for angioedema with the use of systemic intravenous H1 and H2 blockers and steroids.

All patients underwent complete head and neck examination and fiberoptic laryngoscopy at presentation by the ED physicians and/or the Otolaryngology physicians. When the Otolaryngology service was consulted, their findings were used for the study. Patients who were admitted for observation and did not require airway intervention underwent a repeat head and neck examination by the Otolaryngology service, including fiberoptic laryngoscopy in most cases, at least 1 h later. On reexamination, patients were asked to report subjective improvement by answering yes or no to the question: "do you feel better?" Also on reexamination, evaluating physicians determined a global clinical assessment as improved, worse, or same.

The patients' demographics, past medical, social and family histories, symptoms and signs at presentation, and at reevaluation, were recorded by ED physicians and/or Otolaryngology physicians on standardized forms specifically made for this study. The following anatomic sites were specifically assessed for involvement on examination: the face, neck, upper lip, lower lip, anterior tongue, floor of mouth, soft palate, base of tongue, supraglottis, and glottis. Each site was recorded as being involved or not involved and then an overall subjective assessment of degree of involvement was recorded as mild, moderate, or severe.

Only 'water bag' edema, typically associated with acute angioedema of the head and neck, was considered positive for site involvement. The criteria for intubation were based on an overall clinical state. Endoscopic findings that were deemed concerning and likely to warrant airway protection were an inability to see the glottic opening secondary to edema or a documented worsening of edema on repeat examination despite medical management.

A univariate analysis of involved anatomic site and the need for intubation, as well as self-reported symptom improvement (feeling better versus not feeling better) and physical examination (improved/same versus worsened) was carried out using Fisher's exact test. Significance was defined a priori as $P < 0.05$. All statistical analysis was performed using SPSS version 19.0 (SPSS, Chicago, IL).

Results

Thirty-three patients with head and neck angioedema (AE) were enrolled. The mean age was 58 years (range 23–89 years). Seventy three percent of patients were female. Ninety one percent were African American. Hypertension was present in 85% of patients. An angiotensin-converting enzyme inhibitor (ACEi) was identified as the etiology of the

Table 1 Patient characteristics.

Variable	n (%)
# Of patients	33
Age	58 yrs (23–89)
Sex	
Female	24 (73)
Male	9 (27)
Ethnicity	
AA	30 (91)
Hispanic	1 (3)
Caucasian	2 (6)
DM	8 (24)
HTN	28 (85)
CAD	6 (18)
Asthma	6 (18)
Facial trauma	0
Seasonal allergy	3 (9)
Food allergy	5 (15)
Drug rash	1 (3)
Atopic dermatitis	0
Family history of AE	3 (9)
Tobacco	10 (30)
Alcohol	9 (27)
Prior episodes of AE	16 (49)

AA: African American; DM: Diabetes mellitus; HTN: Hypertension; CAD: Coronary artery disease; AE: Angioedema.

angioedema in 76% of cases; the majority of these patients had been on the medication for more than one year. Sixteen patients (48%) had a prior episode of AE. Additional patient characteristics are summarized in [Table 1](#).

At presentation, the mean time since onset of symptoms was 583 min (range 20–2880 min). The most common symptom was dysphagia in 21% of patients. Four patients presented with hoarseness (12%); none had stridor or respiratory distress. Additional patient symptoms at presentation are summarized in [Table 2](#).

The upper lip was the most commonly involved site (58%) on examination, followed by the lower lip (45%), anterior tongue (30%), face (21%), soft palate (18%), supraglottis (18%), floor of mouth (15%), base of tongue (12%), and neck (9%). No glottic edema was observed. More than one site was involved in 76% of patients. The overall edema severity on initial presentation was mild in 55% of patients (scale of mild, moderate, or severe). An example of a patient, from this series, with supraglottic edema can be seen in [Fig. 1](#).

All patients received intravenous dexamethasone or methylprednisolone, diphenhydramine, and famotidine in the ED and during their hospitalization. The Otolaryngology service was asked by the ED to evaluate 88% of patients. The remainder of the patients were evaluated only by the ED and discharged home on the same day. The initial fiberoptic laryngoscopy was performed by an Emergency Department physician in 51% of all patients in the study (including all of the patients who were discharged without Otolaryngology consultation), and was routinely performed on all patients seen by the Otolaryngology service. Repeat fiberoptic laryngoscopy was performed on 26 patients (79%) of all patients in the study. Seven patients underwent only

Table 2 Initial presentation: symptoms.

Variable	n (%)
Otolaryngology consult	29 (88)
Time since symptoms started (min)	583 (20–2880)
Etiology	
ACEi	25 (76)
Allergy	5 (15)
Other	3 (9)
When ACEi initiated	
<1 yr	6 (18)
1–5 yr	8 (24)
>5 yr	8 (24)
Dyspnea	3 (9)
Hoarseness	4 (12)
Odynophagia	3 (9)
Dysphagia	7 (21)
Globus sensation	5 (15)
Cough	2 (6)
Abdominal pain	1 (3)
FOL by ER	17 (51)

ACEi: Angiotensin-converting enzyme inhibitor; FOL: Fiberoptic laryngoscopy.

one laryngoscopy: six were discharged home from the ED and one was intubated due to worsening symptoms.

Four patients (12%) were intubated. One patient had only anterior tongue edema. Another patient had anterior tongue, neck, and supraglottic edema. A third patient had

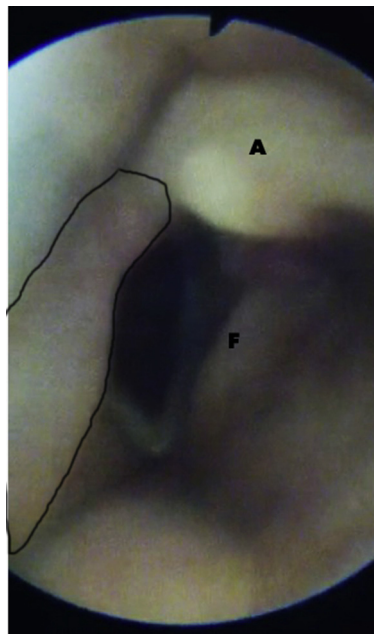


Fig. 1 Still frame image of a fiberoptic laryngoscopy examination of a patient with right-sided supraglottic edema (area encircled in black). The right true vocal fold is partially obscured by the supraglottic edema. The left arytenoid (A) and left false vocal fold (F) are marked. Of note, this patient improved clinically and on repeat examination and did not require intubation.

Table 3 Initial presentation: exam.

Variable	n (%)	P-value (for requiring intubation)
Stridor	0	
Hoarseness	3 (9)	
Respiratory distress	0	
Face	7 (21)	0.555
Neck	3 (9)	0.330
Upper lip	19 (58)	0.288
Lower lip	15 (45)	0.607
Anterior tongue	10 (30)	0.073
FOM	5 (15)	0.500
Soft palate	6 (18)	0.142
BOT	4 (12)	0.420
Supraglottis	6 (18)	0.142
Glottis	0	N/A
Severity		
Mild	18 (55)	
Moderate	11 (33)	
Severe	4 (12)	
CAT initiated	1 (3)	
Total intubated in study	4 (12)	

FOM: Floor of mouth; BOT: Base of tongue; CAT: Critical airway team; N/A: Not available.

upper lip, lower lip, soft palate, base of tongue, and supraglottic edema. A fourth patient had soft palate and supraglottic edema. No anatomic site had a statistical association with intubation (Table 3).

A repeat evaluation was performed (with or without laryngoscopy) at a mean time of 307 min (range 60–1200 min) after the initial examination. On reevaluation, 82% of patients reported subjective improvement in symptoms (answered “yes” to the question “do you feel better?”) The association between symptom improvement and physical examination findings, including fiberoptic laryngoscopy, was statistically significant ($P < 0.001$). A reduction in the number of patients with edema at all involved sites was observed; edema was now present in: upper lip (33%), lower lip (21%), supraglottis (15%), anterior tongue (12%), soft palate (12%), base of tongue (12%), floor of mouth (6%), face (6%), and neck (3%). Seventy-nine percent of patients were admitted to the hospital for further medical management, 18% were discharged from the ED, and one patient left against medical advice. For those patients who were admitted, the average length of stay was 3 days (range 2–6 days). No deaths occurred in the study population. Reevaluation data is summarized in Table 4.

Discussion

Angioedema involving the head and neck remains a common reason for emergent Otolaryngology consultation by the Emergency Department. The task assigned is to determine which patients require immediate airway control and to predict which patients may progress to require airway intervention at a later point. We aimed to determine the progression of AE with medical treatment in the ED and the

Table 4 Reevaluation.

Variable	n (%)	P-value (for clinical status)
Time since first evaluation (min)	307 (60–1200)	
“Do you feel better?”		
Yes	27 (82)	$P < 0.001$
No	6 (18)	
Dyspnea	1 (3)	
Hoarseness	1 (3)	
Odynophagia	1 (3)	
Dysphagia	2 (6)	
Globus sensation	4 (12)	
Stridor	0	
Respiratory distress	0	
Sites still involved		
Face	2 (6)	
Neck	1 (3)	
Upper lip	11 (33)	
Lower lip	7 (21)	
Anterior tongue	4 (12)	
FOM	2 (6)	
Soft palate	4 (12)	
BOT	4 (12)	
Supraglottis	5 (15)	
Glottis	0	
Clinical status		
Same/Improved	28 (85)	
Worse	5 (15)	
Intubated	4 (12)	
Disposition		
Admit	26 (79)	
Discharge	6 (18)	
Left AMA	1 (3)	
Days in hospital if admitted	3 (2–6)	

FOM: Floor of mouth; BOT: Base of tongue; AMA: Against medical advice.

predictive roles of patients’ symptoms, physical examination and fiberoptic laryngoscopy in answering these questions in a prospective fashion.

Angiotensin-converting enzyme inhibitors remain the main cause of angioedema of the head and neck. Our study found a higher percentage of ACEi-induced AE (76%) compared to others, where it was as low as 30% of all AE cases.⁹ This may be related to their use as renal protective agents in diabetic patients, which are ubiquitous in our study population.¹⁰ It is concerning that such a high percentage of patients (49%) continued to be on an ACEi despite having had prior episodes of angioedema related to it. An editorial in 2008 highlighted the hope that physical decision support systems in electronic medical records may help prevent this exact type of scenario.¹¹

The most commonly affected sites are the lips and tongue. In a large retrospective chart review which assessed 228 patients with ACEi-induced AE, the lips were affected in 54% of cases and the tongue in 40% of cases.⁵ In our series, we had similar findings with the upper lip specifically being the most commonly affected site in 58% of

cases. Of note, there were no patients with glottic edema in our series. This is likely related to the exclusion of patients who required immediate intubation.

In our study, the anterior tongue was the only anatomic site to show a trend toward a statistically significant relationship with intubation ($P = 0.073$). Similarly, McCormick et al.⁸ in a retrospective review found an airway intervention rate of 16%, which was significantly increased with involvement of the anterior tongue, base of tongue, and larynx. Only one prospective observational study exists on the topic of head and/or neck angioedema as it relates to airway management.¹² Forty patients with ACEi-induced AE were included, of which 6 (15%) required intubation. The only physical exam finding to be statistically correlated with requiring intubation was massive tongue edema. The patients' symptom progression as it related to objective findings, however, was not evaluated.

Although several authors have previously investigated airway management in patients with angioedema, the role of serial physical examinations in this patient group is not well elucidated. Ishoo et al.⁴ sought to predict the risk of airway compromise in AE by retrospectively reviewing 93 episodes in 80 patients over a 10-year period. Intubation or tracheotomy was necessary in 9 cases (9.7%), all involving the tongue and/or larynx, which were subsequently defined as the high-risk groups. No correlation between symptoms and findings on serial physical examinations was performed.

Bentsianov et al.³ correlated symptoms and fiberoptic laryngoscopy findings on initial examination with the need for urgent airway intervention. In this retrospective review of 74 patients, 14 patients (20%) required immediate airway intervention. No patient with a normal fiberoptic exam required immediate or delayed airway intervention. However, only 32 patients (43%) underwent fiberoptic laryngoscopy. Again, no comment is made on the progression of symptoms and its association with serial physical examinations.

Finally, a recent retrospective review of ACEi related AE from our institution found that 6 patients (6.8%) were intubated after serial fiberoptic laryngoscopy revealed progression of angioedema; 5 of these patients were intubated after their second laryngoscopy and 1 was intubated after the third laryngoscopy.¹⁰ No association of symptoms and physical findings on serial examinations was made given the retrospective nature.

In the present study, only 4 patients (12%) required intubation, 2 had severe anterior tongue edema (one without laryngeal edema and one with resolved laryngeal edema), 1 progressed to involve the larynx, soft palate, and base of tongue, and 1 presented initially with significant laryngeal edema. Of note, the patient who had progressive involvement on physical examination reported worsening of symptoms on reevaluation. There was a statistically significant association between patient symptoms and physical examination findings, including fiberoptic laryngoscopy, for the entire group.

Our results suggest that patients' symptoms can guide clinical management and are well associated with findings on serial physical examinations. Patients' self-reported impression of how they feel during the course of angioedema treatment may be as effective as routinely performing serial physical examinations, including fiberoptic laryngoscopy, in guiding clinical management.

One limitation of our study is the small sample size. Additionally, our patient cohort was of relatively lower clinical severity, as we excluded medically unstable patients who required emergent airway intervention prior to a structured airway assessment. This may explain the lower incidence of laryngeal findings at presentation in our patients. Finally, the timing of the repeat examination was variable between 60 and 1200 min, which could serve as a potential confounder.

Summary

1. Angioedema of the anterior tongue should raise concern for potentially requiring airway intervention.
2. Angioedema not initially involving the larynx rarely progresses to involve it.
3. Angioedema involving the larynx did not worsen with treatment.
4. In stable patients with angioedema of any head and neck subsite, self-reported symptoms are associated with clinical stability or improvement as assessed by physical signs and fiberoptic laryngoscopy.
5. Patients' symptoms may be an appropriate surrogate to monitor clinical status without the need for routine serial physical examinations or fiberoptic laryngoscopy, though further study is needed.

Funding

None.

Financial disclosures

None.

Conflicts of interest

None.

Contributions by author

Gary Linkov, MD: Analysis and Interpretation, Manuscript drafting, Review.

Jennifer R. Cracchiolo, MD: Conception and Design, Manuscript drafting, Review.

Norman J. Chan, MD: Conception and Design, Manuscript drafting, Review.

Megan Healy, MD: Analysis and Interpretation, Manuscript drafting, Review.

Nausheen Jamal, MD: Analysis and Interpretation, Manuscript drafting, Review.

Ahmed M.S. Soliman, MD: Conception and Design, Manuscript drafting, Review.

References

1. Temino VM, Peebles RS. The spectrum and treatment of angioedema. *Am J Med.* 2008;121:282–286.

2. Lewis LM. Angioedema: etiology, pathophysiology, current and emerging therapies. *J Emerg Med.* 2013;45:789–796.
3. Bentsianov BL, Parhiscar A, Azer M, Har-El G. The role of fiberoptic nasopharyngoscopy in the management of the acute airway in angioneurotic edema. *Laryngoscope.* 2000;110:2016–2019.
4. Ishoo E, Shah UK, Grillon GA, Stram JR, Fuleihan NS. Predicting airway risk in angioedema: staging system based on presentation. *Otolaryngol Head Neck Surg.* 1999;121:263–268.
5. Winters ME, Rosenbaum S, Vilke GM, Almazroua FY. Emergency department management of patients with ACE-inhibitor angioedema. *J Emerg Med.* 2013;45:775–780.
6. Grant NN, Deeb ZE, Chia SH. Clinical experience with angiotensin-converting enzyme inhibitor-induced angioedema. *Otolaryngol Head Neck Surg.* 2007;137:931–935.
7. Tai S, Mascaro M, Goldstein NA. Angioedema: a review of 367 episodes presenting to three tertiary care hospitals. *Ann Otol Rhinol Laryngol.* 2010;119:836–841.
8. McCormick M, Folbe AJ, Lin HS, Hooten J, Yoo GH, Krouse JH. Site involvement as a predictor of airway intervention in angioedema. *Laryngoscope.* 2011;121:262–266.
9. Banerji A, Clark S, Blanda M, LoVecchio F, Snyder B, Camargo Jr CA. Multicenter study of patients with angiotensin-converting enzyme inhibitor-induced angioedema who present to the emergency department. *Ann Allergy Asthma Immunol.* 2008;100:327–332.
10. Eibling D. Making us smart: why the design of clinical decision support systems is so critical. *Laryngoscope.* 2008;118:2121–2124.
11. Chan NJ, Soliman AM. Angiotensin converting enzyme inhibitor-related angioedema: onset, presentation, and management. *Ann Otol Rhinol Laryngol.* 2015;124:89–96.
12. Al-Khudari S, Loochtan MJ, Peterson E, Yaremchuk KL. Management of angiotensin-converting enzyme inhibitor-induced angioedema. *Laryngoscope.* 2011;121:2327–2334.

Edited by Jing Li