

Functional medicine

A peripelvic renal cyst resulting in clinically symptomatic ureteropelvic junction obstruction

William S. Coggins^a, Hogan K. Hudgins^a, Christopher D. Kosarek^b, Robyn L. Roberts^{b,*}

^a School of Medicine, University of Texas Medical Branch, 301 University Boulevard, Galveston, TX 77555, USA

^b Division of Urology, Department of Surgery, University of Texas Medical Branch, 301 University Boulevard, Galveston, TX 77555, USA



ARTICLE INFO

Article history:

Received 25 July 2017

Received in revised form

6 October 2017

Accepted 12 November 2017

Available online 21 November 2017

Keywords:

Ureteropelvic junction obstruction

Peripelvic renal cyst

Case presentation

A 57-year-old female presented to the emergency room with left flank pain and no other associated signs or symptoms. She denied hematuria, fever, or urinary tract infection. A computed tomography (CT) scan without contrast indicated obstruction of the left UPJ accompanied by moderate hydronephrosis (Fig. 1). No nephrolithiasis was found, and a renal scan was scheduled at a later date. The patient's pain was alleviated after an intramuscular Ketorolac injection. She was discharged from the emergency room with Tamsulosin and oral analgesia.

On follow-up with her treating urologist, a renal scan was ordered and demonstrated a differential function of 48% on the left and 52% on the right. After the administration of 40 mg of intravenous furosemide, the right kidney demonstrated no evidence of obstruction while the left kidney had delayed emptying with a $T_{1/2}$ beyond of 30 minutes (Fig. 2A). The patient also reported Dietl's crisis, an intense flank pain, upon the administration of furosemide. The results of this test supported the diagnosis of right UPJO and the patient was scheduled for robotic-assisted laparoscopic pyeloplasty.³

Cystoscopy and retrograde pyelogram were performed prior to docking the robot due to microhematuria on urine analysis. No masses or lesions were observed in the bladder, and no filling defects were seen in the ureters. Left UPJO was confirmed.

After dissection and visualization of the left UPJ, a large peripelvic cyst (greater than 5 cm) was noted in the area of interest, as seen in Fig. 3. Otherwise, the UPJ appeared normal and without evidence of crossing vessel, area of stricture, or low insertion of ureter on the renal pelvis.

Marsupialization of the cyst was performed to alleviate the obstruction. Post-operatively, the patient recovered well and was discharged on post-operative day 1. Pathology results described benign fibroadipose tissue with vascular congestion, consistent with a cyst. Two weeks post-procedure, the patient underwent a repeat renal Lasix scan demonstrating stable differential function and improved emptying of the left renal unit prior to Lasix administration measured at 16 minutes (Fig. 2B). On three-month follow-up, patient denied further symptoms of Dietl's crisis or

Introduction

Simple renal cysts are commonly observed and asymptomatic in the majority of patients. These cysts are usually located peripherally and are unnoticed unless they grow large enough to cause pain by impinging on the kidney.¹ In contrast to the simple cyst, the peripelvic renal cyst is contiguous to the renal pelvis and infrequently observed.¹ Often peripelvic cysts either stem from an embryologic vestige or result from a lymphatic obstruction.² Rarely do peripelvic cysts cause ureteropelvic junction obstruction (UPJO). UPJO most commonly occurs in childhood and adolescence. Most common causes include intrinsic stenosis, an abnormal insertion point of the ureter, or compression of the ureter by a crossing vessel.³ In the case presented, a peripelvic cyst was found to be compressing the UPJ, causing an obstruction. Due to the unusual nature of the peripelvic cyst and the resultant obstruction, we chose to report this case.

* Corresponding author. Division of Urology, University of Texas Medical Branch, 301 University Boulevard, Galveston, TX 77555-0540, USA.

E-mail address: rolrober@utmb.edu (R.L. Roberts).

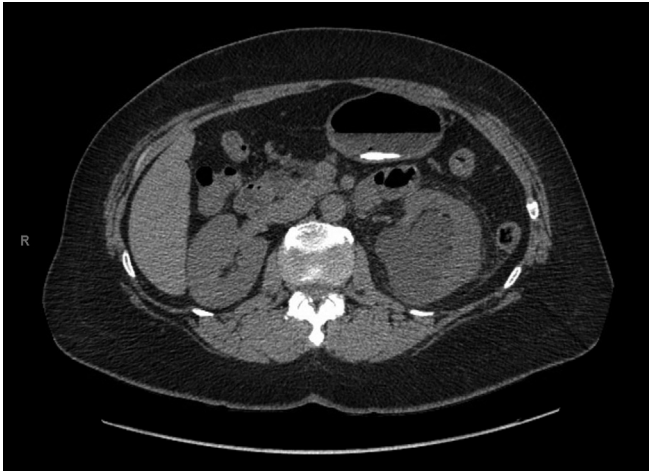


Fig. 1. CT without contrast demonstrating a UPJO and hydronephrosis of left kidney.

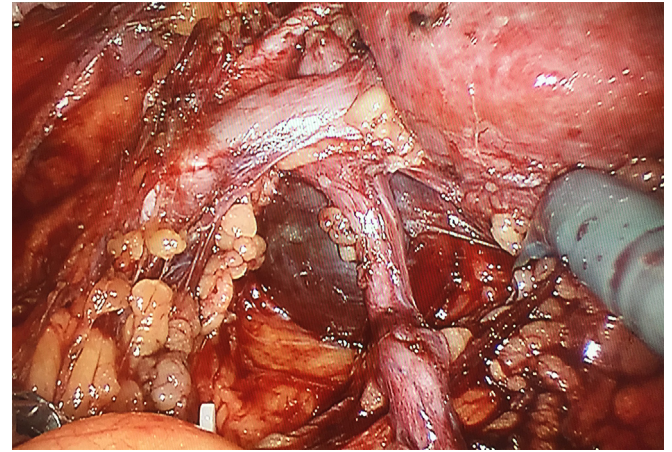


Fig. 3. Intra-operative photo exhibiting peripelvic renal cyst obstructing ureter.

flank pain. Due to financial issues, repeat imaging could not be performed.

Discussion

Multiple papers have described treatment options for symptomatic renal cysts, including percutaneous drainage with sclerotherapy, laparoscopic decortication or marsupialization, and laparoscopic ablation.^{1–5} Per our literature review, only one case report in the past 26 years has been published regarding the treatment of a peripelvic cyst with symptomatic obstruction.⁴

In the previously reported case, the patient presented in a similar fashion. Both patients were middle-aged women presenting with flank pain, and both were diagnosed via CT with hydronephrosis due to a UPJO. Both cysts were marsupialized and post-

operative imaging and tests showed marked improvement in the affected kidney with a full recovery.

Conclusion

In this instance, marsupialization was an effective technique for relieving the UPJO. By relieving the extrinsic compression caused by the peripelvic cyst, the patency of the ureter was restored without the need for reconstruction.

This case illustrates the importance of preoperative contrast-enhanced CT scans and their interpretation. In order to avoid unanticipated findings in the operating room, preoperative scans must be attentively reviewed and discussed. Although rarely prevalent, peripelvic renal cysts should be considered when reviewing a CT scan of a UPJO.

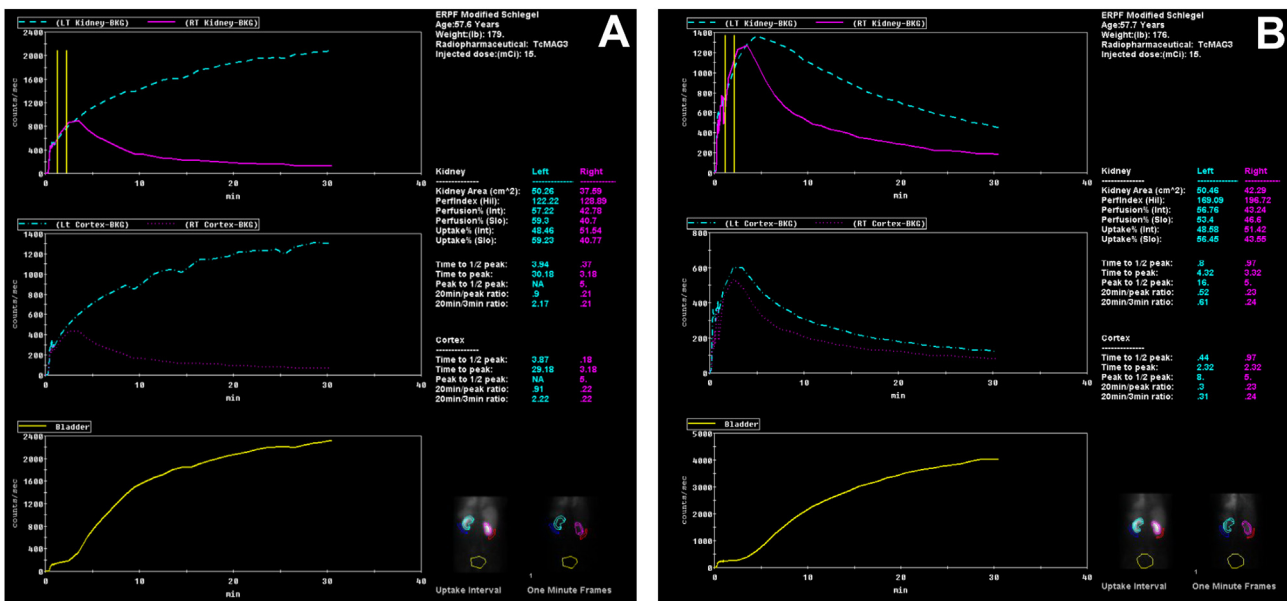


Fig. 2. Pre-operative renal Lasix scan demonstrating marked left renal clearance dysfunction (2A) and post-operative renal Lasix scan demonstrating significant improvement in left renal clearance (2B).

Funding sources

This research did not receive any specific grant from funding agencies in the public, commercial, or not-for-profit sectors.

Conflict of interest

None.

References

1. Camargo AH, Cooperberg MR, Ershoff BD, et al. Laparoscopic management of

- peripelvic renal cysts: University of California, San Francisco, experience and review of literature. *Urology*. 2005;65(5):882–887. <https://doi.org/10.1016/j.urology.2004.11.012>.
2. Lee J, Darcy M. Renal cysts and urinomas. *Semin Interv Radiol*. 2011;28(4):380–391. <https://doi.org/10.1055/s-0031-1296080>.
3. Hoening DM, McDougall EM, Shalhav AL, et al. Laparoscopic ablation of peripelvic renal cysts. *J Urol*. 1997;158(4):1345–1348.
4. Kavoussi LR, Clayman RV, Mikkelsen DJ, et al. Ureteronephroscopic marsupialization of obstructing peripelvic renal cyst. *J Urol*. 1991;146(2):411–414.
5. Yoder BM, Wolf Jr JS. Long-term outcome of laparoscopic decortication of peripheral and peripelvic renal and adrenal cysts. *J Urol*. 2004;171(2 Pt 1):583–587. <https://doi.org/10.1097/01.ju.0000103642.29044.71>.