



# Lymphaticovenular Anastomosis: Superficial Venous Anatomical Approach

Kengkart Winaikosol, MD<sup>1</sup> Palakorn Surakunprapha, MD<sup>1</sup>

<sup>1</sup>Plastic and Reconstructive Unit, Department of Surgery, Faculty of Medicine, Khon Kaen University, Khon Kaen, Thailand

Address for correspondence Kengkart Winaikosol, MD, Department of Surgery, Faculty of Medicine, Khon Kaen University, 123 Mittraphap Highway, Muang District, Khon Kaen 40002, Thailand (e-mail: kengkawi@kku.ac.th).

Arch Plast Surg 2022;49:689–695.

## Abstract

**Background** Lymphaticovenular anastomosis (LVA) is an effective, functional treatment for limb lymphedema. This study reports an alternative surgical approach to lymphedema treatment without the use of indocyanine green mapping.

**Methods** A retrospective analysis was performed on 29 consecutive lymphedema patients who underwent LVAs from January 2015 to December 2020, whereby incisions were made along the anatomy of the superficial venous systems in both upper and lower extremities around the joint areas. The evaluation included qualitative assessments and quantitative volumetric analyses.

**Result** The mean number of anastomoses was 3.07, and the operative time was 159.55 minutes. Symptom improvement was recorded in 86.21% of the patients, with a mean volume reduction of 32.39%. The lymphangitis episodes decreased from 55.17% before surgery to 13.79% after surgery, and the median number of lymphangitis episodes per year decreased from 1 before surgery to 0 after surgery.

**Conclusions** The superficial venous anatomical approach is an easy way to start a lymphedema practice using LVA without other advanced surgical equipment. With this reliable technique, microsurgeons can perform LVA procedures and achieve good results.

## Keywords

- ▶ microsurgery
- ▶ vein
- ▶ lymphedema
- ▶ lymphaticovenular anastomosis
- ▶ anastomosis

## Introduction

Lymphedema is a chronic disease caused by lymphatic transport capacity impairment, resulting in edema, high protein accumulation in the interstitium, inflammation, and irreversible changes in late stages.<sup>1,2</sup> Lymphedema is classified as either primary or secondary. Primary lymphedema is lymphedema other than secondary and includes genetic disorders, such as the Milroy disease.<sup>3,4</sup> Secondary lymphedema is the most common type of lymphedema and may be caused by trauma, infection, or, most commonly, oncological treatment.<sup>5,6</sup>

Lymphedema treatment is challenging. Therapeutic approaches consist of operative and nonoperative methods, such as complex decongestive therapy (CDT), which combine manual lymphatic drainage, bandaging, physical exercises, skincare, and compression stockings. The goal of CDT is to reduce capillary filtration, improve interstitial fluid drainage, reduce swelling, inflammation, infection, and improve quality of life.<sup>5,7,8</sup>

In the late 90s, Koshima et al introduced supermicrosurgical techniques, such as lymphaticovenular anastomosis (LVA), used with satisfactory results.<sup>9,10</sup> LVA is the artificial

received

October 1, 2021

accepted after revision

July 26, 2022

DOI <https://doi.org/>

10.1055/s-0042-1756348.

ISSN 2234-6163.

© 2022. The Korean Society of Plastic and Reconstructive Surgeons. All rights reserved.

This is an open access article published by Thieme under the terms of the Creative Commons Attribution-NonDerivative-NonCommercial-License, permitting copying and reproduction so long as the original work is given appropriate credit. Contents may not be used for commercial purposes, or adapted, remixed, transformed or built upon. (<https://creativecommons.org/licenses/by-nc-nd/4.0/>)

Thieme Medical Publishers, Inc., 333 Seventh Avenue, 18th Floor, New York, NY 10001, USA

connection between a patent lymphatic collector and an adjacent vein in the lymphoedematous limb.<sup>11,12</sup> LVA reconstructs the physiologic lymphatic flow with minimal invasiveness and contributes to improving patient lives. Indocyanine green (ICG) fluorescence lymphography can be used for real-time lymphatic flow visualization.<sup>4,13,14</sup> ICG lymphography is a recent advanced technology for preoperative lymphatic flow evaluation. After intradermal or subcutaneous ICG injection, near-infrared fluorescent images are obtained, and the findings are classified into linear, reticular, splash, stardust, and diffused patterns.<sup>13,15</sup> At this point, ICG technology is expensive and generally inaccessible. We propose our LVA techniques which follow the superficial venous anatomical approach as an alternative to ICG fluorescence lymphography.

## Methods

The current study was conducted in the Plastic & Reconstructive Unit of Srinagarind Hospital, Khon Kaen University, Khon Kaen, Thailand. It consisted of 29 lymphedema patients diagnosed and confirmed with lymphoscintigraphy and who underwent LVA in our unit between January 2015 to December 2020. The clinical stages were based on those of Campisi's classification (► **Table 1**).<sup>16</sup>

### Operative Technique

All LVA procedures were performed under general anesthesia. For upper extremity limbs (along the anatomy of the cephalic and basilica veins), skin incisions were made approximately 3 to 5 cm at the dorsum of the distal forearm (2–3 cm proximal to wrist joint), volar side of the proximal forearm (3–5 cm distal to elbow), or volar side of distal of the arm (3–5 cm proximal to elbow). For lower extremity limbs, the incisions were made approximately 3 to 5 cm above the malleolus, approximately 5-cm medial side below the knee, or the Superior-Edge-of-the-Knee Incision (SEKI) point (along the anatomy of the great saphenous vein).<sup>17</sup> No pneumatic tourniquet was used for the exsanguination. The superficial veins were identified and marked with a vein finder device. The surgical incision was designed over the area of the superficial vein. Intradermal injection of isosulfan blue dye was applied into each finger web space, toe web space, 2- to 3-cm distal to each incision line, or a combination of those areas to outline the lymphatic system. All operative procedures were performed by two senior surgeons (K.W. and P.S.) using an operating microscope.

After each skin incision, dissection was carefully executed to identify small-sized branches of cephalic and basilic veins and collecting lymphatics. The collecting lymphatics and small veins were mobilized and skeletonized. The end-to-end or side-to-end anastomoses were made using 11–0 microsutures, after which hemostasis was checked, and the skin was closed using 5–0 absorbable sutures with interrupted dermal stitches (► **Video 1**).

### Video 1

Lymphaticovenular anastomosis: superficial venous anatomical approach Online content including video sequences viewable at: <https://www.thieme-connect.com/products/ejournals/html/10.1055/s-0042-1756348>.

### Outcomes

The circumferential tape measurement method is based on the approximation of several perimeter measurements to a total volume. Each segment volume was calculated using the following formula:

$$V_s = \frac{1}{12\pi} \sum_{i=1}^n L(Ct_x C_t + C_t x C_b + C_b x C_b)$$

where  $V_s$  is the volume of a segment,  $L$  = length of each segment, and  $C_t$  and  $C_b$  represent the circumference at the top and the base of the segment, respectively.<sup>18–21</sup> Volume reduction was defined as a relative decrease in the volume difference between the healthy and affected extremity.

The upper extremity lymphedema (UEL) index and lower extremity lymphedema (LEL) index were introduced by Yamamoto et al and used for measurements in this study.<sup>22,23</sup> Each index has three concepts as follows: (1) area evaluation using a high-dimensional, cross-sectional area based on a circular extremities model; (2) body mass index (BMI) body type correction; and (3) allowing mutual evaluation between different cases and bilateral cases by the absolute values.

### Statistical Analysis

Continuous variables are presented as a mean with standard deviation (SD) or median with the interquartile range (IQR), as appropriate. Categorical variables are presented as absolute numbers and percentages. Preoperative and postoperative parameters were compared. Continuous variables were

**Table 1** Campisi's lymphedema clinical staging system

Stage 1A	No edema with the presence of lymphatic dysfunction
Stage 1B	Mild edema, reversible with a declivous position and night rest
Stage 2	Persistent edema that progresses only partially with a declivous position and night rest
Stage 3	Persistent edema that continually becomes more severe (recurrent acute erysipeloid lymphangitis)
Stage 4	Fibrotic lymphedema (with initial lymphostatic warts) and column-shaped limb
Stage 5	Elephantiasis with severe limb deformation, scleroindurative pachydermitis, and widespread lymphostatic warts

compared between groups with the paired *t*-test or Wilcoxon's signed-rank test, and categorical variables were tested with the Chi-squared test or Fisher's exact test. A value of  $p < 0.05$  was considered statistically significant. All analyses were performed with Stata version 10.1 (StataCorp. LP, College Station, TX).

## Results

A total of 29 lymphedema patients were treated with LVA surgery, and the patient demographics are illustrated below (► **Table 2**). The mean age was  $51.17 \pm 15.21$  years, and the majority of cases were female (25 cases, 86.21%). The etiology distribution was

**Table 2** Demographics of the 29 lymphedema patients evaluated

	<i>n</i> (%) / mean $\pm$ SD / median (IQR)
Age (y)	51.17 $\pm$ 15.21
Sex	
Female	25 (86.21)
Male	4 (13.79)
Etiology	
Primary	6 (20.69)
Secondary	23 (79.31)
Comorbidity	16 (55.17)
Hypertension	7 (24.14)
Dyslipidemia	5 (17.24)
Diabetic mellitus	4 (13.79)
BMI (kg/m <sup>2</sup> )	25.01 $\pm$ 4.61
Affected limb	
Upper extremity	18 (62.07)
Lower extremity	11 (37.93)
Side	
Left	14 (48.28)
Right	15 (51.72)
Lymphedema duration (y)	3.0 (1.17–5.0)
Patients experiencing lymphangitis	16 (55.17)
No. of lymphangitis episodes	1 (0–3)
Campisi's staging	
2	2 (6.90)
3	17 (58.62)
4	10 (34.48)
UEL/LEL staging	
1	3 (10.34)
2	5 (17.24)
3	9 (31.03)
4	12 (41.38)

Abbreviations: BMI, body mass index; IQR, interquartile range; LEL, lower extremity lymphedema; SD, standard deviation; UEL, upper extremity lymphedema.

79.31% secondary lymphedema after radical cancer surgery and 20.69% primary lymphedema. Sixteen cases had notable comorbidities: hypertension (24.14%), dyslipidemia (17.24%), and diabetes mellitus (13.79%). The mean BMI was  $25.01 \pm 4.61$ , kg/m<sup>2</sup> and about two-thirds of all cases were affected in the upper extremities (18 cases, 62.07%). Fifteen cases were affected on the right side, and 14 cases were on the left side. The median time of the symptoms presented before surgery was 3 years, and 55.15% of patients had experienced lymphangitis. The majority of preoperative cases were categorized as Campisi's stage 3 (58.62%) and stage 4 (34.48%) and UEL/LEL stage 3 (31.03%) and stage 4 (41.38%).

LVA was performed on all patients, and the mean operative time was  $159.55 \pm 56.37$  minutes. Single surgical site incision was performed in 62.07% of the patients, and multiple incision was done in 37.93%. The majority of anastomoses were of the end-to-end fashion (65.52%), and the mean number of anastomoses was  $3.07 \pm 1.03$ . The mean diameter of the biggest anastomosis was  $0.95 \pm 0.47$  mm (► **Table 3**).

A pressure garment was applied 2 weeks after surgery. The median follow-up time of this study was 12.01 months (IQR: 8.07–26.33 months). Compared with the preoperative parameters, 25 cases (86.21%) showed a 32.39% mean volume improvement (33.63% in upper extremity cases and 30.36% in lower extremity cases). The number of postoperative lymphangitis patients decreased to 4 (13.79%), and 14 cases (48.28%) showed UEL/LEL staging improvement (► **Table 4**).

Comparing the pre- and postsurgery parameters revealed a significant improvement in lymphangitis incidences, the number of lymphangitis episodes, UEL/LEL index, UEL/LEL staging, and the mean volume difference (► **Table 5**).

## Discussion

Lymphaticovenular anastomosis (LVA) is a practical surgical method for lymphedema treatment with good results. In LVA, surgeons use a supermicrosurgical technique to anastomose

**Table 3** Intraoperative outcomes

	<i>n</i> (%) / mean $\pm$ SD
Operative time (min)	159.55 $\pm$ 56.37
Surgical incision:	
Single incision	18 (62.07)
Multiple incisions	11 (37.93)
No. of anastomosis	3.07 $\pm$ 1.03
Type of anastomosis:	
End-to-end fashion	19 (65.52)
Side-to-end fashion	10 (34.48)
Diameter of biggest anastomosis (mm)	0.95 $\pm$ 0.47
Diameter of the second anastomosis	0.81 $\pm$ 0.52
Diameter of the third anastomosis	0.63 $\pm$ 0.23
Diameter of the fourth anastomosis	0.56 $\pm$ 0.20
Diameter of the fifth anastomosis	0.50 $\pm$ 0.14

Abbreviation: SD, standard deviation.

**Table 4** Postoperative outcomes

	<i>n</i> (%) / mean $\pm$ SD / median (IQR)
Follow-up time (mo)	12.01 (8.07–26.33)
No. patients of improvement	
Improved	25 (86.21)
Unchanged or worse	4 (13.79)
Patients experiencing postoperative lymphangitis	4 (13.79)
Postoperative UEL/LEL staging	
1	9 (31.03)
2	8 (27.59)
3	4 (13.79)
4	8 (27.59)
UEL/LEL staging improvement	
Improved	14 (48.28)
Unchanged or worse	15 (51.72)
Percentage of mean volume improvement (%)	32.39 $\pm$ 28.89
Upper extremity	33.63 $\pm$ 23.02
Lower extremity	30.36 $\pm$ 37.80

Abbreviations: IQR, interquartile range; LEL, lower extremity lymphedema; SD, standard deviation; UEL, upper extremity lymphedema.

lymphatic vessels and adjacent venules, creating new channels through which excess fluid trapped in lymphedematous areas can effectively drain into the venous circulation, increasing the region's lymphatic transport capacity.<sup>10,24,25</sup>

Many studies showed a preoperative approach that assessed the lymphedema classification based on indocyanine green (ICG) lymphangiographic findings.<sup>25–30</sup> Narushima et al categorized lymphedema severity into six stages. Briefly, in stage 0, no dermal backflow pattern is seen. In stage I, a splash pattern is seen around the axilla or in the groin area. In stages II to IV, progressive stardust patterns are observed, and stage V represents a diffuse pattern in the whole limb.<sup>31</sup>

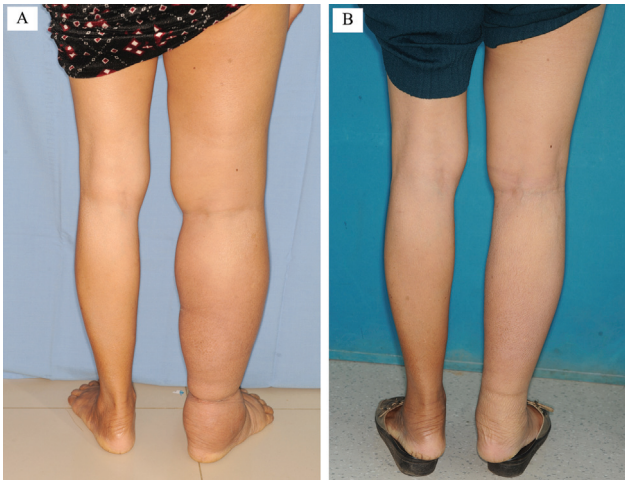
As ICG lymphangiography and near-infrared cameras are not widely available, we wanted to demonstrate an alternative approach to lymphedema treatment. We performed the LVA while following the superficial vein identified with the vein finder device. We made incisions along the anatomy of the superficial venous systems in both upper and lower extremities around the joint areas because the patency rate was significantly higher than at the nonjoint areas.<sup>32</sup> Intraoperative lymphatic mapping was identified with isosulfan blue dye. In this approach, we performed an average of 3.07  $\pm$  1.03 anastomoses in approximately 160 minutes of operative time.

O'Brien et al. reported that in their experience with performing LVA alone in 52 patients, 42% of those patients improved, with an average of 44% in volume reduction.<sup>33</sup> In the 1960s, Koshima et al published lymphedema treatment options for the modern era, consisting of microvascular LVA in upper and lower extremities. The results showed that arm circumference decreased an average of 5.3 cm (range: 2–9 cm), while half of the legs also improved.<sup>24</sup> Chang et al found in a prospective study of 100 consecutive patients after a 12-month follow-up that LVA can effectively reduce lymphedema with an average of 42% volume reduction.<sup>25</sup> In a study in Korea, Pereira studied 33 patients with upper and lower

**Table 5** Comparative preoperative and postoperative parameters

	Preoperative <i>n</i> (%) / median (IQR)	Postoperative <i>n</i> (%) / median (IQR)	<i>p</i> -Value
Lymphangitis	16 (55.17)	4 (13.79)	0.0005
No. of lymphangitis episodes	1 (0–3)	0 (0–0)	0.0008
UEL/LEL index	202.19 (152.22–335.07)	190.69 (124.38–297.32)	0.0001
UEL index	157.43 (136.06–187.73)	140.97 (118.25–162.87)	0.0004
LEL index	340.39 (308.98–392.09)	328.36 (262.29–380.74)	0.0409
UEL/LEL staging			0.007
1	3 (10.34)	9 (31.03)	
2	5 (17.24)	8 (27.59)	
3	9 (31.03)	4 (13.79)	
4	12 (41.38)	8 (27.59)	
Index difference	77.68 (54.36–131.68)	23.88 (10.48–35.75)	<0.0001
UEL index difference	65.17 (42.96–90.96)	23.61 (10.48–33.77)	0.0002
LEL index difference	131.68 (62.88–168.69)	23.88 (3.11–72.78)	0.0033
Volume difference (mL)	1,455.95 (962.69–2,450.11)	401.80 (205.65–701.48)	<0.0001
Upper extremity	1,389.93 (811.96–1,804.42)	378.61 (205.65–637.95)	0.0002
Lower extremity	2,450.11 (1,328.15–3,359.10)	566.59 (–35.36–950.42)	0.0033

Abbreviations: IQR, interquartile range; LEL, lower extremity lymphedema; UEL, upper extremity lymphedema.



**Fig. 1** Preoperative photo (A) and 3-year follow-up postoperative photo (B) of a 60-year-old female with right unilateral lower extremity lymphedema secondary to postcervical cancer treatment. After three lymphaticovenular anastomoses, there was an excess volume reduction of 73.5%.

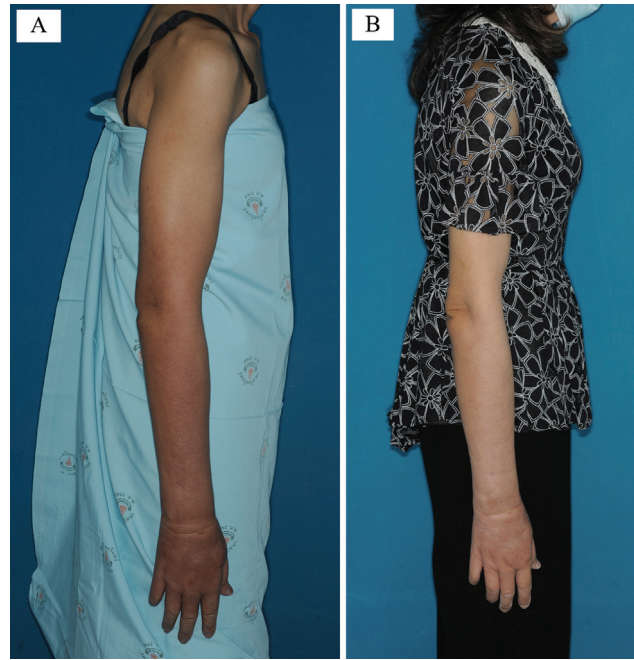
extremity lymphedema and who underwent LVA. Those patients averaged 3.75 anastomoses in upper limb cases and 2.3 anastomoses in lower limb cases. The results showed a 64.97 and 39.81% excess volume reduction in upper and lower extremity lymphedema, respectively.<sup>34</sup>

In this present study, 86.21% of patients affected by upper or lower limb lymphedema improved significantly. Treated limbs showed a mean volume reduction of 32.39% (33.63 and 30.36% in upper and lower limbs, respectively), decreased lymphangitis episodes, improved UEL/LEL index, and improved UEL/LEL staging (48.28%). Examples of such patient improvements are illustrated in ►Figs. 1 and 2.

The appropriate number of LVAs is debatable. Mihara et al reported that more LVA sites created during surgery correlated to a better volume reduction.<sup>35</sup> At the same time, Seki et al documented various ways that one functional LVA could be enough to obtain satisfactory outcomes.<sup>17</sup> Our study did not show a correlation between the number of LVA anastomoses and volume reduction. This point will be further investigated in the future.

Yamamoto et al proposed the UEL<sup>22</sup> and LEL indexes and staging<sup>23</sup> for classifying the severity of upper and lower extremity lymphedema. These indexes allow for comparing preoperative and postoperative outcomes, the mutual evaluation between different cases, and the cases with bilateral lymphedema by the absolute values. This study showed a postoperative volume reduction improvement in 86.21% of patients and a UEL/LEL index improvement. The UEL/LEL staging classification can compare preoperative and postoperative improvement, and our study reported a 48.28% UEL/LEL staging improvement.

Additional benefits of LVA treatment are decreased postoperative lymphangitis episodes in patients experiencing lymphangitis (55.17% in presurgery to 13.79% in postsurgery) and decreased lymphangitis episodes per year (a median of 1 [IQR: 1–3] in presurgery to a median of 0 [IQR: 0–0] in postsurgery).



**Fig. 2** Preoperative photo (A) and 1-year follow-up postoperative photo (B) of a 43-year-old female patient with right upper extremity lymphedema secondary to breast cancer treatment. After LVA, lymphangitis episodes decreased dramatically from 3 to 4 episodes per year to 0 episodes per year, and volume reduction reached 50%. LVA, lymphaticovenular anastomosis.

Our lymphedema treatment approach is an easy way to start a lymphedema practice using LVA without other advanced surgical equipment. With this reliable technique, microsurgeons can use standard routine equipment to perform LVAs and achieve good results.

A limitation of this study is that we demonstrated good results at the median follow-up term of only 12 months. In the future, a follow-up investigation will be conducted which will help determine the long-term outcome.

Lymphaticovenular anastomosis is an effective treatment option for reducing limb lymphedema volume and improving involved symptoms, including reducing the number of lymphangitis episodes. The superficial venous anatomical approach is an easy way to achieve good surgical outcomes.

#### Authors' Contributions

Conceptualization: K.W., P.S. Data curation: K.W. Methodology: K.W., P.S. Project administration: K.W. Writing original draft: K.W. Writing - review & editing: K.W., P.S. All authors read and approved the final manuscript.

#### Ethical Approval

The study was approved by the Khon Kaen University Ethics Committee for Human Research (IRB No. HE641259) and performed in accordance with the principles of the Declaration of Helsinki. The informed consent was waived because this study design is a retrospective chart review.

**Patient Consent**

Patients provided written consent for the use of their images.

**Conflict of Interest**

None declared.

**Acknowledgment**

The authors thank Mr. Kevin McCracken for assistance with the English language presentation under the aegis of the Khon Kaen University Publication Clinic, Thailand.

**References**

- 1 Brorson H, Ohlin K, Olsson G, Nilsson M. Adipose tissue dominates chronic arm lymphedema following breast cancer: an analysis using volume rendered CT images. *Lymphat Res Biol* 2006;4(04):199–210
- 2 Executive Committee. The diagnosis and treatment of peripheral lymphedema: 2009 Consensus Document of the International Society of Lymphology. *Lymphology* 2016;49(04):170–184 PubMed
- 3 Schook CC, Mulliken JB, Fishman SJ, Grant FD, Zurakowski D, Greene AK. Primary lymphedema: clinical features and management in 138 pediatric patients. *Plast Reconstr Surg* 2011;127(06):2419–2431
- 4 Yamamoto T, Yoshimatsu H, Narushima M, Yamamoto N, Hayashi A, Koshima I. Indocyanine green lymphography findings in primary leg lymphedema. *Eur J Vasc Endovasc Surg* 2015;49(01):95–102
- 5 Chang DW, Masia J, Garza R III, Skoracki R, Neligan PC. Lymphedema: Surgical and medical therapy. *Plast Reconstr Surg* 2016;138(3, suppl)209S–218S
- 6 Yamamoto T, Yamamoto N, Kageyama T, et al. Technical pearls in lymphatic supermicrosurgery. *Glob Health Med* 2020;2(01):29–32
- 7 Damstra RJ, Voesten HGJ, van Schelven WD, van der Lei B. Lymphatic venous anastomosis (LVA) for treatment of secondary arm lymphedema. A prospective study of 11 LVA procedures in 10 patients with breast cancer related lymphedema and a critical review of the literature. *Breast Cancer Res Treat* 2009;113(02):199–206
- 8 Mortimer P. Investigation and management of lymphoedema. *Vascular Medicine Review* 1990;1:1–20
- 9 Koshima I, Inagawa K, Etoh K, Moriguchi T. Supramicrosurgical lymphaticovenular anastomosis for the treatment of lymphedema in the extremities [in Japanese]. *Nippon Geka Gakkai Zasshi* 1999;100(09):551–556
- 10 Koshima I, Inagawa K, Urushibara K, Moriguchi T. Supermicrosurgical lymphaticovenular anastomosis for the treatment of lymphedema in the upper extremities. *J Reconstr Microsurg* 2000;16(06):437–442
- 11 Retik AB, Perlmutter AD, Harrison JH. Communications between lymphatics and veins involving the portal circulation. *Am J Surg* 1965;109:201–205 PubMed
- 12 Pressman JL, Burtz MV, Shafer L. Further observations related to direct communications between lymph nodes and veins. *Surg Gynecol Obstet*. 1964;119:984–990 PubMed
- 13 Yamamoto T, Narushima M, Doi K, et al. Characteristic indocyanine green lymphography findings in lower extremity lymphedema: the generation of a novel lymphedema severity staging system using dermal backflow patterns. *Plast Reconstr Surg* 2011;127(05):1979–1986
- 14 Yamamoto T, Yamamoto N, Yoshimatsu H, Hayami S, Narushima M, Koshima I. Indocyanine green lymphography for evaluation of genital lymphedema in secondary lower extremity lymphedema patients. *J Vasc Surg Venous Lymphat Disord* 2013;1(04):400–405.e1
- 15 Yamamoto T, Narushima M, Yoshimatsu H, et al. Dynamic Indocyanine Green (ICG) lymphography for breast cancer-related arm lymphedema. *Ann Plast Surg* 2014;73(06):706–709
- 16 Campisi C, Boccardo F. Microsurgical techniques for lymphedema treatment: derivative lymphatic-venous microsurgery. *World J Surg* 2004;28(06):609–613
- 17 Seki Y, Yamamoto T, Yoshimatsu H, et al. The superior-edge-of-the-knee incision method in lymphaticovenular anastomosis for lower extremity lymphedema. *Plast Reconstr Surg* 2015;136(05):665e–675e
- 18 Sander AP, Hajer NM, Hemenway K, Miller AC. Upper-extremity volume measurements in women with lymphedema: a comparison of measurements obtained via water displacement with geometrically determined volume. *Phys Ther* 2002;82(12):1201–1212
- 19 Drobot A, Bez M, Abu Shakra I, et al. Microsurgery for management of primary and secondary lymphedema. *J Vasc Surg Venous Lymphat Disord* 2021;9(01):226–233.e1
- 20 Tidhar D, Armer JM, Deutscher D, Shyu CR, Azuri J, Madsen R. Measurement issues in anthropometric measures of limb volume change in persons at risk for and living with lymphedema: a reliability study. *J Pers Med* 2015;5(04):341–353
- 21 Karges JR, Mark BE, Stikeleather SJ, Worrell TW. Concurrent validity of upper-extremity volume estimates: comparison of calculated volume derived from girth measurements and water displacement volume. *Phys Ther* 2003;83(02):134–145
- 22 Yamamoto T, Yamamoto N, Hara H, Mihara M, Narushima M, Koshima I. Upper extremity lymphedema index: a simple method for severity evaluation of upper extremity lymphedema. *Ann Plast Surg* 2013;70(01):47–49
- 23 Yamamoto T, Matsuda N, Todokoro T, et al. Lower extremity lymphedema index: a simple method for severity evaluation of lower extremity lymphedema. *Ann Plast Surg* 2011;67(06):637–640
- 24 Koshima I, Kawada S, Moriguchi T, Kajiwara Y. Ultrastructural observations of lymphatic vessels in lymphedema in human extremities. *Plast Reconstr Surg* 1996;97(02):397–405, discussion 406–407
- 25 Chang DW, Suami H, Skoracki R. A prospective analysis of 100 consecutive lymphovenous bypass cases for treatment of extremity lymphedema. *Plast Reconstr Surg* 2013;132(05):1305–1314
- 26 Suami H, Chang DW, Yamada K, Kimata Y. Use of indocyanine green fluorescent lymphography for evaluating dynamic lymphatic status. *Plast Reconstr Surg* 2011;127(03):74e–76e
- 27 Kitai T, Inomoto T, Miwa M, Shikayama T. Fluorescence navigation with indocyanine green for detecting sentinel lymph nodes in breast cancer. *Breast Cancer* 2005;12(03):211–215
- 28 Unno N, Inuzuka K, Suzuki M, et al. Preliminary experience with a novel fluorescence lymphography using indocyanine green in patients with secondary lymphedema. *J Vasc Surg* 2007;45(05):1016–1021
- 29 Ogata F, Narushima M, Mihara M, Azuma R, Morimoto Y, Koshima I. Intraoperative lymphography using indocyanine green dye for near-infrared fluorescence labeling in lymphedema. *Ann Plast Surg* 2007;59(02):180–184
- 30 Yamamoto T, Matsuda N, Doi K, et al. The earliest finding of indocyanine green lymphography in asymptomatic limbs of lower extremity lymphedema patients secondary to cancer treatment: the modified dermal backflow stage and concept of sub-clinical lymphedema. *Plast Reconstr Surg* 2011;128(04):314e–321e
- 31 Narushima M, Yamamoto T, Ogata F, Yoshimatsu H, Mihara M, Koshima I. Indocyanine green lymphography findings in limb lymphedema. *J Reconstr Microsurg* 2016;32(01):72–79

- 32 Suzuki Y, Sakuma H, Yamazaki S. Comparison of patency rates of lymphaticovenous anastomoses at different sites for lower extremity lymphedema. *J Vasc Surg Venous Lymphat Disord* 2019;7(02):222–227
- 33 O'Brien BMC, Mellow CG, Khazanchi RK, Dvir E, Kumar V, Pederson WC. Long-term results after microlymphaticovenous anastomoses for the treatment of obstructive lymphedema. *Plast Reconstr Surg* 1990;85(04):562–572
- 34 Pereira N, Lee YH, Suh Y, et al. Cumulative experience in lymphovenous anastomosis for lymphedema treatment: the learning curve effect on the overall outcome. *J Reconstr Microsurg* 2018;34(09):735–741
- 35 Mihara M, Hara H, Tange S, et al. Multisite lymphaticovenular bypass using supermicrosurgery technique for lymphedema management in lower lymphedema cases. *Plast Reconstr Surg* 2016;138(01):262–272