

# Successful treatment of primary headache associated with sexual activity using erenumab: Case report

Cephalalgia  
2022, Vol. 42(7) 680–683  
© International Headache Society 2022



Article reuse guidelines:  
sagepub.com/journals-permissions  
DOI: 10.1177/03331024221075074  
journals.sagepub.com/home/cep



Gytis Makarevičius<sup>1</sup> and Kristina Ryliškiene<sup>2,3</sup>

## Abstract

**Background:** Primary headache associated with sexual activity is a rare benign headache disorder that is provoked by sexual excitement. It is a diagnosis of exclusion after the underlying secondary causes have been ruled out. The cause of this headache disorder is still unknown. Cerebral vasospasm, pericranial muscular contraction, hemodynamic and respiratory changes during sexual activity are most commonly listed as possible pathophysiological mechanisms. Several acute and prophylactic options with good clinical response have been described in the case series.

**Case report:** We present a case of a 30-year-old woman with primary headache associated with sexual activity and comorbid with frequent episodic migraine without aura. Both headache disorders were successfully managed with monoclonal antibody against calcitonin gene-related peptide (CGRP) receptor erenumab 70 mg.

**Conclusion:** The efficacy of erenumab in our case presumes that CGRP might also be an important mediator in facilitating primary headache associated with sexual activity.

## Keywords

Primary headache associated with sexual activity, migraine, calcitonin gene-related peptide, erenumab, case report

Date received: 24 October 2021; revised: 23 December 2021; accepted: 3 January 2022

## Introduction

Primary headache associated with sexual activity (HSA) is a benign type of headache that is provoked by sexual excitement. HSA is a diagnosis of exclusion after the underlying secondary causes have been ruled out (1). According to current estimates, the disease prevalence is 1–1.6% among sexually active men and women (ratios between 1.2:1 and 3:1) (1,2). However, it is possible that this headache disorder is underdiagnosed due to patients' unwillingness to express sexual activity-related complaints (3). There is a high comorbidity of HSA with migraine (25%), benign exercise headache (29%), and tension-type headache (45%) (3). To date, no randomized controlled trials to compare the efficacy of different treatment options for HSA have been conducted. Yet, several treatment options for HSA with good clinical response have been described in literature. Parenteral administration of triptans was shown to be effective in shortening orgasmic headache attacks (4). The most commonly reported preventive treatments are indomethacin and

triptans 30–60 minutes prior to sexual activity and beta-blockers (such as propranolol, metoprolol, nadolol) (1). Some treatment options also described being effective include: diltiazem, nimodipine and topiramate (5). Monoclonal antibodies (MAbs) targeting calcitonin gene-related peptide (CGRP) or its receptors have not been previously described as a treatment option for HSA. We present a patient with HSA, whose headaches, although resistant to other treatment options of HSA, responded well to treatment with erenumab, suggesting that MAbs against CGRP or its receptors might be effective in preventing HSA. Data on the headache severity and frequency was obtained from

<sup>1</sup>Faculty of Medicine, Vilnius University, Vilnius, Lithuania

<sup>2</sup>Centre of Neurology, Vilnius University, Vilnius, Lithuania

<sup>3</sup>Centre of Neurology, Kardiolitos klinikos, Vilnius, Lithuania

## Corresponding author:

Gytis Makarevičius, Vilnius University, Faculty of Medicine, M. K. Ciurlionio St. 21, LT-03101 Vilnius.

Email: gytis.makarevicius@mf.stud.vu.lt

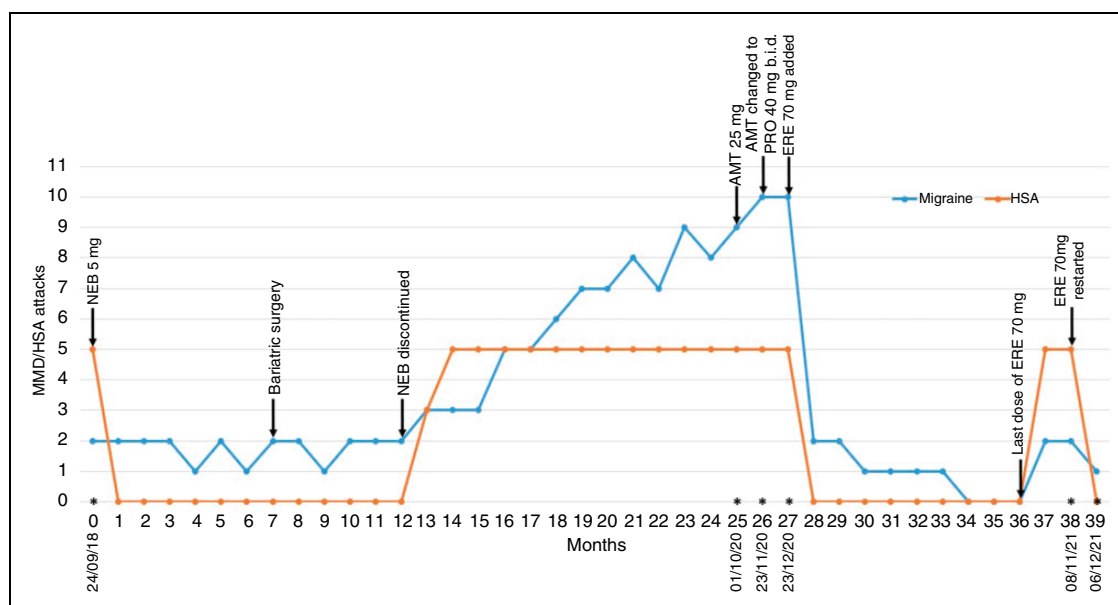
the patient's headache diary that she started documenting after her first outpatient visit. The patient provided written informed consent for the writing and publication of this case report. No ethical approval was required for this study.

## Clinical case

A 30-year-old woman attended an outpatient clinic in September 2018 with a one-month history of 5 attacks of orgasmic headaches. The headaches commenced right at the point of every orgasm, gradually building up in severity over several minutes. In its peak, the intensity of the pain was 5–6 out of 10 as described on a numerical rating scale, subsequently diminishing over about 30 minutes. The pain was located in the right parietal area, dull in quality with occasional throbbing component and, was unrelated to any other accompanying symptoms. Higher level of sexual excitement correlated with higher pain intensity. Orgasmic headaches resulted in decreased satisfaction with her sexual relationship. She began to avoid sexual activity in fear of subsequent headaches. Since the age of 20, the patient suffered from episodic headache (1–2 attacks per month, 2–4 monthly headache days) in the right parietal area. Since the age of 29 after her third delivery, the severity of pain increased to 7–8 out of 10, and accompanying symptoms (photo/phonophobia, osmophobia, nausea, and vomiting) became very intense. These attacks were unsuccessfully managed

by ibuprofen 400 mg. The patient's history indicated obesity since the age of 23 (Body mass index (BMI) 37). Physical examination revealed elevated blood pressure (142/98 mmHg). Neurological examination, fundoscopy, magnetic resonance imaging (MRI) with angiography, and ultrasound of extracranial arteries were unremarkable. Primary HSA and migraine without aura was diagnosed. Oral sumatriptan 50 mg for migraine attacks and nebivolol 5 mg o.d. for prophylaxis of HSA were prescribed. She was also recommended to continue her diet and exercise regime for weight reduction. After 1 month of follow-up HSA remitted and the good control of migraine attacks was achieved. The clinical course of disease is shown in Figure 1.

In October 2020, the patient visited the outpatient clinic complaining of headache worsening – orgasmic headache relapsed, monthly migraine days (MMD) increased from 1–2 to 7–10, migraine attacks became uncontrolled. In April 2019, the patient underwent bariatric surgery that resulted in losing a substantial amount of weight (BMI decreased from 37 to 21) and developing intolerable hypotension with nebivolol, which was discontinued in September 2019. Due to COVID-19 pandemic restrictions from March 2020, the patient stopped her regular exercises. In addition, chronic stressors at home and work caused almost constant anxiety. These major changes in patient's life together with the discontinuation of prophylaxis resulted in gradual worsening of migraine and relapse



**Figure 1.** Preventive treatment of headache associated with sexual activity and migraine.

MMD – monthly migraine days, HSA – headache associated with sexual activity, NEB – nebivolol, AMT – amitriptyline, PRO – propanolol, b.i.d. – two times per day, ERE – erenumab, \* – outpatient visits and their dates. parenthetical n dash after \*

of HSA. MRI was performed again, but the results were unremarkable. The patient was prescribed amitriptyline 25 mg, and due to tachycardia worsening, symptomatic hypotension, and no efficacy after almost 2 months of treatment, it was changed to propranolol 40 mg b.i.d. One month treatment with propranolol managed tachycardia but was inefficient for the prophylaxis of migraine and orgasmic headache. The propranolol dose was not increased due to hypotension, and in December 2020 erenumab 70 mg was added. In 2 weeks, patient reported significant improvement of migraine frequency and severity, and disappearance of HSA. The sustained efficacy of continuous erenumab treatment on both headache disorders was observed at the 3- and 9-months follow-up visits: 0–1 MMD, no HSA (Figure 1). There were no side effects associated with erenumab.

In October 2021, due to technical prescription errors at the pharmacy erenumab was unintentionally discontinued. Despite the use of propranolol 40 mg b.i.d. recurrence of severe uncontrolled migraine attacks and HSA started in 6 weeks after the last dose of erenumab. On the 8 of November 2021, erenumab therapy was restarted. In 2 weeks after erenumab resumption the patient documented discontinuation of HSA, as well as migraine improvement (Figure 1).

## Discussion

We presented a female case with HSA and migraine without aura. Both headache disorders were diagnosed according to the criteria of the third edition of the International Classification of Headache Disorders (ICHD-3) after secondary causes of HSA were excluded by fundoscopy, neuroimaging, and ultrasound (2). Given that HSA is frequently comorbid with migraine, it can be considered that HSA is underreported and underdiagnosed in female population (1,2). This headache disorder impacts a person's sexual relationship and life quality, it was also emphasized by our patient. Asking direct questions about headache with sexual activity in females with migraine might improve the diagnostic accuracy of HSA.

To our knowledge, no reports have been published demonstrating the successful response of HSA to erenumab. However, HSA can have an episodic and chronic course (4). Moreover, spontaneous remission of episodic HSA is not uncommon (4). Thus, after the first episodes of HSA it is not possible to accurately determine whether remission is caused by prophylactic medication or is spontaneous and merely coincidental. In our case the first episode of HSA was managed with nebivolol as beta-blockers are considered the first-line preventive treatment. Quick response was not

unexpected considering the fact that the patient was hypertensive and that a quick and good response has been previously described in literature (4,6). For the second episode of HSA, which lasted more than a year, considering significant migraine worsening, anxiety, and arterial hypotension administration of amitriptyline was selected, later it was changed to low dose of propranolol. However, the treatment was either poorly tolerated or ineffective. Therefore, primarily for the prevention of frequent and severe migraine attacks erenumab was added to propranolol. This resulted not only in migraine improvement but also in HSA remission. Although it is not possible to exclude synergistic effect of propranolol and erenumab, it is worth noting that during the third HSA episode propranolol alone was not effective in preventing HSA. Quick response of HSA to erenumab and subsequent quick relapse after withdrawal coincided with the clinical course of migraine, these instant changes in migraine frequency are described in real-life studies (7,8).

The mechanisms of HSA are still largely unknown. A number of factors have been suggested as contributing to HSA, including cerebral vasospasm, pericranial muscular contraction, hemodynamic and respiratory changes during sexual activity (9). HSA and migraine comorbidity suggests the role of the trigeminovascular system in HSA pathogenesis. As a key pain mediator of the trigeminovascular pathway, CGRP plays a crucial role in the pathophysiology of migraine (10). The connection of HSA with migraine is also seen in our clinical case. Although CGRP role in migraine is extensively studied, its role in other headache disorders is yet to be determined. Nevertheless, CGRP has recently been suggested to be a nonspecific mediator causing headache in other types of headache disorders. For example, Ashina et al demonstrated that after traumatic brain injury people who were infused with CGRP developed headache similar to migraine when healthy people do not (11). Similarly, in a recent case series of patients with idiopathic intracranial hypertension, erenumab was shown to be effective in managing headache and possible connection of CGRP in the development of the disease was hypothesized (12). In addition, Tarperi et al. demonstrated that serum concentration CGRP levels increase with physical activity and it is positively correlated with the intensity of exertion (13). These findings suggest a possible link of primary exercise headache with CGRP. To add to that list, the efficacy of erenumab in our HSA case report supports the hypothesis that CGRP might also be an important mediator in facilitating HSA.

### Clinical implications

- Asking direct questions about headache with sexual activity in patients with migraine might improve the diagnostic accuracy of HSA.
- Anti-CGRP acting medications could be effective in preventing HSA.

### Declaration of conflicting interests

The authors declared no potential conflicts of interest with respect to the research, authorship, and/or publication of this article.

### Funding

The authors received no financial support for the research, authorship, and/or publication of this article.

### References

1. Bahra A. Other primary headaches—thunderclap-, cough-, exertional-, and sexual headache. *J Neurol* 2020; 267: 1554–1566.
2. Headache Classification Committee of the International Headache Society (IHS) The International Classification of Headache Disorders, 3rd edition. *Cephalalgia* 2018; 38: 1–211.
3. Frese A, Eikermann A, Frese K, et al. Headache associated with sexual activity: demography, clinical features, and comorbidity. *Neurology* 2003; 61: 796–800.
4. Frese A, Rahmann A, Gregor N, et al. Headache associated with sexual activity: prognosis and treatment options. *Cephalalgia* 2007; 27: 1265–1270.
5. Evans RW. Topiramate for the prevention of primary headache associated with sexual activity: the third and fourth case reports. *Headache* 2020; 60: 1800–1802.
6. Utku U. Primary headache associated with sexual activity: case report. *Med Princ Pract* 2013; 22: 588–589.
7. McAllister PJ, Turner I, Reuter U, et al. Timing and durability of response to erenumab in patients with episodic migraine. *Headache* 2021; 61: 1553–1561.
8. Gantenbein AR, Agosti R, Gobbi C, et al. Impact on monthly migraine days of discontinuing anti-CGRP antibodies after one year of treatment - a real-life cohort study. *Cephalalgia* 2021; 41: 1181–1186.
9. Imarhiagbe FA. Headache associated with sexual activity: From the benign to the life threatening. *Sahel Med J* 2016; 19: 1–4.
10. Iyengar S, Ossipov MH, Johnson KW. The role of calcitonin gene-related peptide in peripheral and central pain mechanisms including migraine. *Pain* 2017; 158: 543–59.
11. Ashina H, Iljazi A, Al-Khazali HM, et al. Hypersensitivity to Calcitonin Gene-Related Peptide in Post-Traumatic Headache. *Ann Neurol*. 2020; 88(6): 1220–1228.
12. Yiangou A, Mitchell JL, Vijay V, et al. Calcitonin gene related peptide monoclonal antibody treats headache in patients with active idiopathic intracranial hypertension. *J Headache Pain* 2020 Sep 25; 21(1): 116.
13. Tarperi C, Sanchis-Gomar F, Montagnana M, et al. Effects of endurance exercise on serum concentration of calcitonin gene-related peptide (CGRP): a potential link between exercise intensity and headache. *Clin Chem Lab Med* 2020; 58: 1707–12.