

Oncology

Splenogonadal Fusion: A Rare Benign Testicular Mass in a 55-Year-Old Male



Andrew M. Harris

Paul B. Hall Regional Medical Center, 625 James S. Trimble Blvd, Paintsville, KY 41240, USA

ARTICLE INFO

Article history:

Received 8 August 2016

Received in revised form

24 August 2016

Accepted 25 August 2016

Keywords:

Splenogonadal fusion

Testicular mass

Seminoma

ABSTRACT

Splenogonadal fusion (SGF) is a rare cause of testicular mass with the vast majority of cases presenting in men under the age of 30 and represents a diagnostic challenge. Discontinuous splenogonadal fusion presenting as a new testicular mass in a 55-year-old man is discussed to aid other surgeons in diagnosing this condition.

© 2016 The Author. Published by Elsevier Inc. This is an open access article under the CC BY-NC-ND license (<http://creativecommons.org/licenses/by-nc-nd/4.0/>).

Introduction

Splenogonadal fusion (SGF) is a rare congenital anomaly where splenic tissue fuses with gonadal tissue likely during the fifth to eighth week of gestation¹ and is rare with less than 200 cases reported.² SGF can be continuous, a fixed connection between the spleen and gonad, or discontinuous, no connection to the spleen.² The vast majority of cases are in males under the age of 39 and involve the left gonad.² SGF can present in the workup of infertility, cryptorchidism, inguinal hernia, or as a testicular mass as presented in this case.^{2–4}

Case report

A 55-year-old male presented to the urology clinic with obstructive voiding complaints. Past medical history was significant for cardiac disease, otherwise unremarkable. On physical exam he was found to have a 3 cm firm left sided upper pole testicular mass. On further questioning, he had never noticed this mass nor had any of his providers. Scrotal ultrasound revealed a well-circumscribed, focal, solid intratesticular lesion measuring 2.4 × 2.5 × 2.4 cm suspicious for testicular mass (Fig. 1) Serum AFP, HCG, and LDH were negative. Chest X-ray was negative for

metastatic disease. CT of the abdomen and pelvis showed no adenopathy in the retroperitoneum. Given the appearance on ultrasound and the history of new testicular mass, left radical inguinal orchiectomy was performed uneventfully. The pathology report revealed a spermatic cord lipoma, benign testicle and epididymis, and splenogonadal fusion with splenic tissue involving the superior pole, 2.5 cm in maximal diameter. The splenic tissue

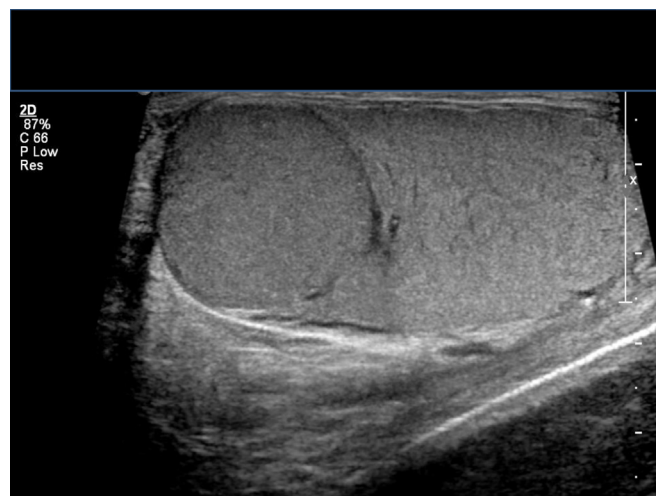

Figure 1. Rounded well-circumscribed intratesticular solid lesion.

Abbreviation: SGF, Splenogonadal fusion.

Funding: This research did not receive any specific grant from funding agencies in the public, commercial, or not-for-profit sectors.

E-mail address: Amharr2@gmail.com



Figure 2. Gross specimen, with splenic tissue being darker in color.

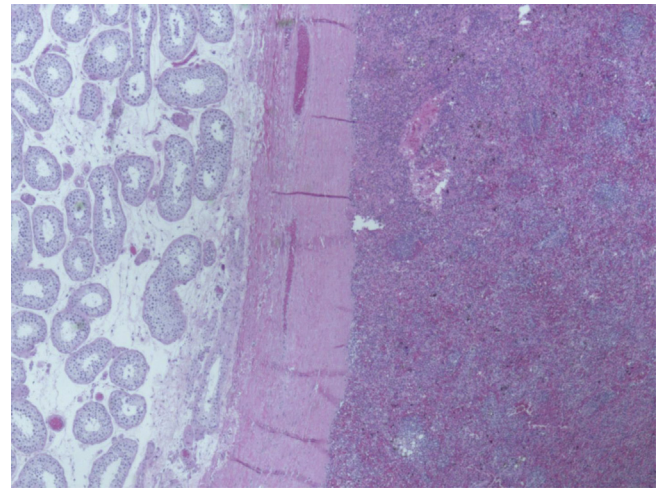


Figure 3. Microscopic view at 2× magnification. Fibrous capsule separating testicular tissue (left) and splenic tissue (right).

had a well delineated fibrous encapsulation, separate from the testicular tissue (Figs. 2 and 3).

Discussion

A new solid intratesticular lesion in a 55-year-old male is considered malignant until proven otherwise. Although, the patient underwent the correct diagnostic workup and treatment given his presentation, he was found to have a rare benign lesion. The question arises as to whether this could have been diagnosed prior to surgery, thus, preventing radical orchiectomy.

The majority of SGF cases are in younger men, continuous, and up to 26% are noted to have other congenital anomalies making the diagnosis more apparent.² The patient may also give a history of a long standing stable scrotal mass and ultrasound may show a very well circumscribed, rounded, slightly hypoechoic, homogeneous, focal mass. Such findings could prompt the physician to approach the mass in a testis sparing fashion, with intraoperative frozen section to confirm the diagnosis as well as preserve the remaining testis.³ Technetium-99m sulfur colloid scan may also be used to identify accessory splenic tissue when SGF is suspected.⁵ However, testicular tumors have been found concomitantly with SGF, further complicating the diagnosis.² When diagnostic indicators are absent, SGF represents a significant diagnostic challenge, requiring a high index of suspicion. Given the rarity of SGF, it may be difficult to recommend technetium scans for all patients presenting with testicular lesions. Yet, surgeons can also identify the tumor in the operating room by sending frozen sections if the diagnosis remains in question.³

Conclusion

SGF remains a diagnostic challenge, but remains a consideration in the differential diagnosis of a well circumscribed testicular lesion, especially in men presenting with a long history of a stable testicular mass. Technetium scan and testis sparing surgery with frozen section analysis may help aid in the diagnosis and prevent radical orchiectomy. Nevertheless, a new onset testicular mass should likely be considered malignant until proven otherwise.

Conflicts of interests

None.

Acknowledgments

I would like to thank Henry Harlamert, MD for his assistance in obtaining the pathology gross and microscopic photos.

References

1. Carragher AM. One hundred years of splenogonadal fusion. *Urology*. 1990;35:471–475.
2. Malik RD, Liu DB. Splenogonadal fusion: an unusual case of an acute scrotum. *Rev Urol*. 2013;15:197–201.
3. Croxford WC, Pfistermuller KL, Scott F, Pope AJ. Splenogonadal fusion presenting clinically and radiologically as a seminoma. *Urol Case Rep*. 2015;3:204–205.
4. Kumar S, Jayant K, Agrawal S, et al. A rare case of continuous type splenogonadal fusion in a young male with primary infertility. *Case Rep Urol*. 2014;2014:796761.
5. Steinmetz AP, Rappaport A, Nikolov G, et al. Splenogonadal fusion diagnosed by spleen scintigraphy. *J Nucl Med*. 1997;38:1153–1155.