

## F-18 Fluorodeoxyglucose Positron-Emission Tomography/Computed Tomography Showing Mammillary Body Involvement in a Case of Autoimmune Anti-N-Methyl D-Aspartate Antibody Encephalitis

### Abstract

Autoimmune encephalitis with antibodies against neuronal cell surface antigens is a group of neuropsychiatric disorders, with anti-N-methyl D-aspartate (NMDAR) encephalitis being one of them. We report a case of a young male patient who presented with complaints of seizures associated with fever, rapidly progressing memory loss, and choreoathetoid movements for 1 month. His serum was strongly positive for anti-NMDAR receptor antibodies. F-18 fluorodeoxyglucose positron-emission tomography/computed tomography for the brain revealed hypermetabolism involving bilateral basal ganglia and bilateral mammillary bodies associated with hypometabolism in bilateral occipital lobes.

**Keywords:** *Anti-N-methyl D-aspartate encephalitis, autoimmune encephalitis, fluorodeoxyglucose, mammillary body*

A 23-year-old male patient came with chief complaints of seizures (2–3 episodes/day) for 1 month associated with altered behavior and fever for 15 days. Later, his ability to respond to verbal commands slowly deteriorated along with the appearance of choreoathetoid movements for 7 days. EEG done for seizure evaluation revealed diffuse encephalitis. Serum tested strongly positive for anti-N-methyl D-aspartate (NMDAR) receptor antibodies (cell-based assays). Axial F-18 fluorodeoxyglucose (FDG) positron-emission tomography (PET), computed tomography (CT), and fused PET/CT brain images [Figure 1a-c] revealed hypermetabolism involving the bilateral basal ganglia (solid arrow) along with hypometabolism in the bilateral occipital cortices (filled arrow) with no morphological abnormality in the corresponding CT images. Axial [Figure 1d-f] and coronal [Figure 1g-i] F-18 FDG PET, CT, and fused PET/CT brain images revealed hypermetabolism involving bilateral mammillary bodies (dotted arrows) relative to cerebral cortex with no morphological abnormality in the corresponding CT images.

Anti-NMDAR receptor encephalitis is a most frequently reported autoimmune limbic

encephalitis characterized predominantly by IgG antibodies against the GluN1 subunit of NMDA receptor in the cerebrospinal fluid (CSF) and serum.<sup>[1]</sup> This disorder most frequently affects younger women and children, accounting for 80% of patients, but can also be seen in younger men and older individuals.<sup>[2]</sup> Most of the patients with this disorder show hypermetabolism involving the hippocampus, amygdala, and parahippocampal gyrus in isolation or bilateral occipital lobe hypometabolism on F-18 FDG PET.<sup>[3]</sup> In the case of severe neurological disability with choreoathetoid movements, bilateral basal ganglia are involved by these antibodies, as seen in our case.<sup>[4]</sup> This index case shows rare bilateral mammillary body involvement, representing a pair of paramedian small round bodies located in the undersurface of the brain. These play an important role in recollective memory formation by relaying impulses from the hippocampal region to the anterior thalamus (Papez circuit). Memory loss seen in this case may be attributed to the involvement of bilateral mammillary bodies.

In most cases, the exact trigger mechanism for these antibodies remains unknown, but few studies reported association with

**Kousik Vankadari, Rajender Kumar, Jayanta Samanta<sup>1</sup>, Harmandeep Singh, Bhagwant Rai Mittal**

*Departments of Nuclear Medicine and <sup>1</sup>Gastroenterology, Post Graduate Institute of Medical Education and Research, Chandigarh, India*

### Address for correspondence:

*Prof. Bhagwant Rai Mittal, Department of Nuclear Medicine, Post Graduate Institute of Medical Education and Research, Chandigarh - 160 012, India. E-mail: brmittal@yahoo.com*

**Received:** 23-04-2021

**Revised:** 22-09-2021

**Accepted:** 27-09-2021

**Published:** 15-12-2021

### Access this article online

**Website:** [www.ijnm.in](http://www.ijnm.in)

**DOI:** 10.4103/ijnm.ijnm\_54\_21

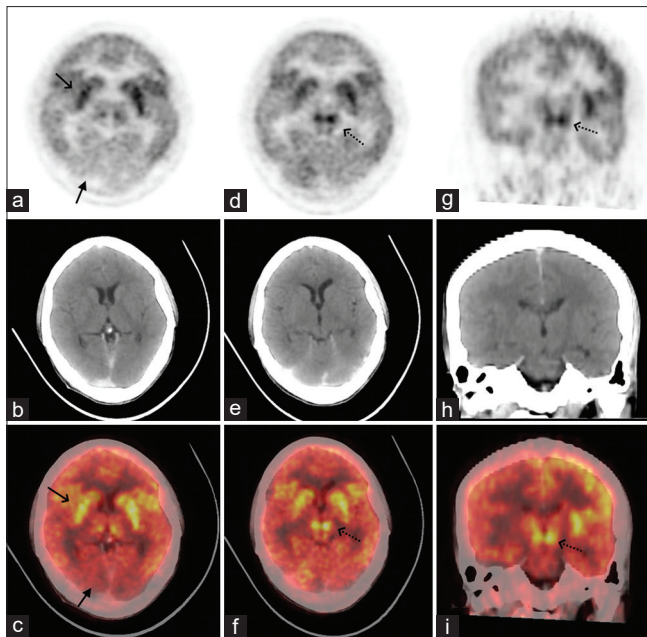
### Quick Response Code:



**How to cite this article:** Vankadari K, Kumar R, Samanta J, Singh H, Mittal BR. F-18 fluorodeoxyglucose positron-emission tomography/computed tomography showing mammillary body involvement in a case of autoimmune anti-N-methyl D-aspartate antibody encephalitis. *Indian J Nucl Med* 2021;36:451-2.

This is an open access journal, and articles are distributed under the terms of the Creative Commons Attribution-NonCommercial-ShareAlike 4.0 License, which allows others to remix, tweak, and build upon the work non-commercially, as long as appropriate credit is given and the new creations are licensed under the identical terms.

**For reprints contact:** [WKHLRPMedknow\\_reprints@wolterskluwer.com](mailto:WKHLRPMedknow_reprints@wolterskluwer.com)



**Figure 1:** Axial F-18 FDG PET, CT, and fused PET/CT brain images (a-c) revealed hypermetabolism involving the bilateral basal ganglia (solid arrow) along with hypometabolism in the bilateral occipital cortices (filled arrow) with no morphological abnormality in the corresponding CT images. Axial (d-f) and coronal (g-i) F-18 FDG PET, CT, and fused PET/CT brain images revealed hypermetabolism in red nucleus. FDG: Fluorodeoxyglucose, PET: Positron-emission tomography, CT: Computed tomography

herpes viral infections, ovarian and testicular teratomas.<sup>[5,6]</sup> Diagnosis is often confirmed by the presence of rapidly progressing clinical symptoms and elevated anti-NMDAR antibodies in the CSF and serum. F-18 FDG PET can support the diagnosis by showing hypermetabolism in the involved structures during the acute phase and also helps to rule out rare yet possible underlying malignancy in the body. Establishing the diagnosis with clinical features, serum investigations, and F-18 FDG PET is important because symptoms associated with this syndrome improve with immunotherapy in more than 60% of the cases.<sup>[7]</sup> Autoimmune encephalitis with antibodies against neuronal surface antigens confers better prognosis with lesser risk of cancer than those with antibodies against neurocytoplasmic antigen.<sup>[8,9]</sup> The findings, in this case, emphasize the potential role of F-18 FDG PET as an imaging biomarker for confirmation of autoimmune encephalitis.

#### Declaration of patient consent

The authors certify that they have obtained all appropriate

patient consent forms. In the form the patient (s) has/have given his/her/their consent for his/her/their images and other clinical information to be reported in the journal. The patients understand that their names and initials will not be published and due efforts will be made to conceal their identity, but anonymity cannot be guaranteed.

#### Financial support and sponsorship

Nil.

#### Conflicts of interest

There are no conflicts of interest.

#### References

1. Granerod J, Ambrose HE, Davies NW, Clewley JP, Walsh AL, Morgan D, *et al.* Causes of encephalitis and differences in their clinical presentations in England: A multicentre, population-based prospective study. *Lancet Infect Dis* 2010;10:835-44.
2. Titulaer MJ, McCracken L, Gabilondo I, Armangué T, Glaser C, Iizuka T, *et al.* Treatment and prognostic factors for long-term outcome in patients with anti-NMDA receptor encephalitis: An observational cohort study. *Lancet Neurol* 2013;12:157-65.
3. Probasco JC, Solnes L, Nalluri A, Cohen J, Jones KM, Zan E, *et al.* Decreased occipital lobe metabolism by FDG-PET/CT: An anti-NMDA receptor encephalitis biomarker. *Neuro Immunol Neuroinflamm* 2018;5:e413.
4. Maeder-Ingvar M, Prior JO, Irani SR, Rey V, Vincent A, Rossetti AO. FDG-PET hyperactivity in basal ganglia correlating with clinical course in anti-NMDA-R antibodies encephalitis. *J Neurol Neurosurg Psychiatry* 2011;82:235-6.
5. Hacoen Y, Deiva K, Pettingill P, Waters P, Siddiqui A, Chretien P, *et al.* N-methyl-D-aspartate receptor antibodies in post-herpes simplex virus encephalitis neurological relapse. *Mov Disord* 2014;29:90-6.
6. Dai Y, Zhang J, Ren H, Zhou X, Chen J, Cui L, *et al.* Surgical outcomes in patients with anti-N-methyl D-aspartate receptor encephalitis with ovarian teratoma. *Am J Obstet Gynecol* 2019;221:485.e1-485.e10.
7. Dalmau J, Gleichman AJ, Hughes EG, Rossi JE, Peng X, Lai M, *et al.* Anti-NMDA-receptor encephalitis: Case series and analysis of the effects of antibodies. *Lancet Neurol* 2008;7:1091-8.
8. Honnorat J, Cartalat-Carel S, Ricard D, Camdessanche JP, Carpentier AF, Rogemond V, *et al.* Onco-neural antibodies and tumour type determine survival and neurological symptoms in paraneoplastic neurological syndromes with Hu or CV2/CRMP5 antibodies. *J Neurol Neurosurg Psychiatry* 2009;80:412-6.
9. Dalmau J, Graus F, Villarejo A, Posner JB, Blumenthal D, Thiessen B, *et al.* Clinical analysis of anti-Ma2-associated encephalitis. *Brain* 2004;127:1831-44.