


Clinical case

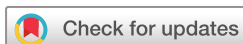Neuralgic amyotrophy and hepatitis
E infection: 6 prospective case reports

Romain Garofoli ¹, Paul Seror,² Jennifer Zauderer,¹ Alexandra Roren,¹ Henri Guerini,³ François Rannou,^{1,4} Jean-Luc Drapé,³ Christelle Nguyen,^{1,5,6} Marie-Martine Lefèvre-Colau¹

To cite: Garofoli R, Seror P, Zauderer J, *et al*. Neuralgic amyotrophy and hepatitis E infection: 6 prospective case reports. *RMD Open* 2020;**6**: e001401. doi:10.1136/rmdopen-2020-001401

RG and PS contributed equally.

Received 17 July 2020
Revised 30 September 2020
Accepted 1 November 2020



© Author(s) (or their employer(s)) 2020. Re-use permitted under CC BY-NC. No commercial re-use. See rights and permissions. Published by BMJ.

¹Service de Rééducation et de Réadaptation de l'Appareil Locomoteur et des Pathologies du Rachis, Hôpital Cochin, AP-HP, Centre-Université de Paris, Paris, France

²Département De Neurophysiologie, Univ. Paris Pierre Et Marie Curie, Hôpital Pitié-Salpêtrière, Assistance Publique-Hôpitaux de Paris, Paris, France

³Service de Radiologie ostéo-articulaire, Hôpital Cochin, Paris, France

⁴Université Paris Descartes, PRES Sorbonne Paris Cité, Paris, France

⁵Université de Paris, Faculté de Santé, UFR de Médecine, Paris, France

⁶INSERM UMR-S 1124, Toxicité Environnementale, Cibles Thérapeutiques, Signalisation Cellulaire et Biomarqueurs (T3S), Campus Saint-Germain-des-Prés, Paris, France

Correspondence to

Romain Garofoli;
romaingarofoli@gmail.com

ABSTRACT

Introduction Hepatitis E virus (HEV) represents the main cause of enterically transmitted hepatitis worldwide. It is known that neuralgic amyotrophy (NA) is one of the most frequent neurological manifestations of HEV. However, clinical, electrodiagnostic (EDX) and MRI characteristics, as well as long-term follow-up of HEV-related NA have not been fully described yet.

Case reports We describe longitudinally clinical, EDX, biological and MRI results of six cases of HEV-associated NA, diagnosed from 2012 to 2017. Patients were between the ages of 33 and 57 years old and had a positive HEV serology. Clinical patterns showed the whole spectrum of NA, varying from extensive multiple mononeuropathy damage to single mononeuropathy. EDX results showed that the patients totalised 26 inflammatory mononeuropathies (1 to 8 per patient). These involved classical nerves such as suprascapular (6/6 cases), long thoracic (5/6 cases) and accessory spinal nerves (2/6 cases) and, some less frequent more distal nerves like anterior interosseous nerve (3/6 cases), as well as some unusual ones such as the lateral antebrachial cutaneous nerve (1/6 case), sensory fibres of median nerve (1/6 case) and phrenic nerves (1/6 case). After 2 to 8 years, all nerves had clinically recovered (muscle examination above 3/5 on MRC scale for all muscles except in one patient).

Discussion HEV should be systematically screened when NA is suspected, whatever the severity, if the onset is less than 4 months (before IgM HEV-antibodies disappear) and appears to be frequently associated with severe clinical and EDX pattern, without increasing the usual recovery time.

INTRODUCTION

Neuralgic amyotrophy (NA) or Parsonage and Turner syndrome (PTS) is a rare and under-recognised syndrome, with a sex ratio M:F of 2:1, occurring in at least 2 per 100 000 per year¹ and up to 1 per 1000 per year in a cohort of patients examined by trained physicians.² NA is defined as (sub) acute (within hours or days) monophasic painful (numerical rating scale score $\geq 7/10$) neurologic injury, with multifocal distribution involving mainly the brachial plexus,

Key messages**What is already known about this subject?**

- ▶ Hepatitis E virus (HEV) is the main cause of enterically transmitted hepatitis worldwide.
- ▶ HEV-related neuralgic amyotrophy (NA) was first described in 2009 and is one of the most frequent extra-hepatic symptoms associated with HEV; however, long-term follow-up data are sparse.

What does this study add?

- ▶ This study provides long-term follow-up (at least 2 years) data (clinical and electrodiagnostic) of patients with HEV-associated NA.
- ▶ HEV-related NA appears to be frequently associated with a severe clinical and EDX pattern, without increasing the usual recovery time.

How might this impact on clinical practice?

- ▶ HEV should be systematically screened when NA is suspected, whatever the severity, if the onset is less than 3 or 4 months (before IgM HEV-antibodies disappear).
- ▶ The finding of elevated liver enzymes associated with upper limb neurological disorder or shoulder pain should immediately raise the suspicion of NA and motivate a detailed neurological visit.
- ▶ If more physicians are aware of the potential associations between HEV and NA, serological tests will improve the chance of detecting this entity.

excluding a direct trauma, malignancy and local radiation, and with normal cervical spine MRI findings.^{2–5} It is triggered at least in 25% by viral infection⁶: Parvovirus B19 (PVB19), human cytomegalovirus (HCMV), herpes simplex virus (HSV), etc. In 2009, the first case of hepatitis E virus (HEV) associated NA was reported by Fong & Illahi⁷ and recently, some cases were reported.⁸ HEV represents the main cause of enterically transmitted hepatitis worldwide, being responsible for more than 50% of acute hepatitis cases in endemic developing countries.⁹ Transmission to humans comes mainly from eating undercooked meat of infected animals (pork, wild boar

in particular).¹⁰ HEV was long considered as endemic only in developing countries, mostly South and East Asia and India but the virus is now known to be endemic in developed European countries.¹¹ Indeed, Mansuy found an overall seroprevalence of 39.1% among blood donors in 2011 in the South of France, ranging from 20% to 71.3% depending on geographical area.¹²

The association between HEV and NA remains little known and overlooked; the most described neurological manifestation associated with HEV being Guillain-Barré syndrome. Besides, clinical, electrodiagnostic (EDX) and MRI characteristics, as well as evolution of HEV-related NA have not been fully described yet.

Case reports

We describe (tables 1 and 2) longitudinally clinical, EDX, biological and MRI results of 6 cases of HEV-associated NA, diagnosed in our centre from February 2012 to September 2017. All clinical evaluations were performed by the same physician, and all EDX examinations were performed by the same operator, using the same protocol.

Clinical evaluation was made 1 to 3 months after symptoms onset and again 2 to 8 years later. All patients underwent cervical spine MRI to rule out a differential diagnosis of cervical nerve entrapment.^{13 14} All but one had bilateral scapular MRI with the following protocol: axial T1-weighted sequence and short-T1 inversion recovery (STIR) sequence in axial and coronal planes, of shoulder girdle. All participants gave an informed agreement for the use of their anonymous clinical, EDX, biological and MRI data in this study. We received a local committee approval for this study.

The 6 cases were between the ages of 33 and 57 years old (mean 44.5), sex ratio was 5 M/1 F. All patients had positive serology: IgM HEV-antibodies above normal range on Wantai test. Liver enzymes were initially increased in all cases and varied from 4 N to 200 N but went back to normal range in all cases without any treatment.

Clinical patterns showed the whole spectrum of NA, varying from extensive multiple mononeuropathy damage (5/6 cases) to single mononeuropathy. 4/6 patients had bilateral proximal and distal symptoms and 1/6 had bilateral phrenic involvement.

EDX results showed that the 6 patients totalised 26 inflammatory mononeuropathies (1 to 8 per patient). These involved classical nerves such as suprascapular (6/6 cases, twice bilaterally), long thoracic (5/6 cases) and accessory spinal nerves (2/6 cases, one bilaterally) and, some less frequent more distal nerves like anterior interosseous nerve (3/6 cases, twice bilaterally), as well as some unusual ones such as the lateral antebrachial cutaneous nerve (LABCN) (1/6 case),^{15 16} the sensory fibres of median nerve (1/6 case) and phrenic nerves (1/6 case bilaterally), originating from cervical plexus. At the initial examination, EDX pattern demonstrated an acute and severe axonal loss indicated for motor nerves by: a very low (compound) motor action potential amplitude (nerve conduction study), and very reduced interference

pattern with high firing rate during maximal effort, with numerous fibrillations/positive sharp waves at rest (needle examination).

On scapular MRI, amyotrophy in at least one muscle was observed in all patients (figure 1). Out of 26 nerves involved, after 2 to 8 years, all had clinically recovered (muscle examination above 3/5 on MRC scale for all muscles except in one patient).

All patients had a cervical MRI that could not explain clinical presentation.

DISCUSSION

Previous authors stated that HEV-associated NA cases were more likely to be men, middle-aged, have bilateral involvement of brachial plexus (80% vs 8.6%),¹⁷ and a particularly high prevalence of phrenic nerve involvement was found by Van Eijk (24.5% vs 3.5%, $p=0.01$),¹⁸ along with Scanvion (18.0% vs 6.6%, $p=0.028$) compared with global population of NA.¹⁹

In our case series, 5 out of 6 patients were male, which was consistent with a recent study that suggested a higher likelihood of HEV-associated NA in men.¹⁹ Indeed, Ripellino *et al*, in their study of 141 acute HEV infection, found out that men had higher odds (OR =5.2, CI 1.12 to 24.0, $p=0.03$) of developing NA after infection with HEV. An interesting fact in this study was that three couples were simultaneously infected with HEV, in which only the men developed NA.¹⁹

In our case series, 3/6 patients had anterior interosseous nerve paresis, which might also induce a severe disability (in writing and fine motor control activities). This particular pattern may be overlooked and was not diagnosed in our patients before EDX was performed. Maldonado *et al* reported anterior interosseous nerve involvement in 3 out of 7 cases of supposed isolated long thoracic nerve palsy (HEV-status unknown).²⁰ Phrenic nerve lesion is a rare condition, seems to be more frequent in HEV-associated NA and is supposed to recover more slowly than other nerves involvement in NA, because of a longer length of nerve regrowth.²⁰

Patients with bilateral symptoms, proximal and distal nerves involvement, and extensive multiple mononeuropathy, can be considered severe clinical patterns of NA. HEV-related NA appears to be frequently associated with a severe clinical and EDX pattern, without modifying the usual recovery time. In our case series, after at least 2 years of follow-up, all patients had a good clinical and electrodiagnostic recovery. Therefore, HEV should be systematically screened when NA is suspected, whatever the severity, if the onset is less than 3 or 4 months (before IgM HEV-antibodies disappear).

Searching for liver enzyme elevation is not systematic in case of painful upper limb palsy or NA. Furthermore, bilateral and extensive NA are frequently unrecognised, so when liver enzymes are elevated, it is often related to painkiller medication such as paracetamol or nonsteroidal anti-inflammatory drugs (NSAIDs) medication ($n=2$

Table 1 Demographic, clinical, hepatic biological, and EDX data at the first evaluation, presented from the mildest to the severest

Case Number	1	2	3	4	5	6
Baseline characteristics						
Age	33	41	51	37	57	48
Work	Physiotherapist	Engineer	Train driver trainer	Removal man	University teacher	Winegrower
Body Mass Index (kg/m ²)	20.8	21.7	26.9	24.2	29.1	25.7
Gender	M	M	M	M	F	M
ALAT	↗	200 N	7 N	16 N	2 N	10 N
ASAT	↗	80 N	4 N	4 N	4 N	5 N
Hepatic symptoms	None	Icterus and poor general state	None	Loss of weight (8 kgs)	None	None
HEV testing						
Delay before blood testing	15 days	5 days	3 months	2 months	3 months	4 months
HEV IgM status (Wantal)	Positive	Positive	Positive	Positive	Positive	Positive
HEV RT-PCR	/	Positive	/	Negative	Negative	Negative
Clinical data:						
Pain (NRS)	3/10	4/10	4/10	6/10	5/10	6/10
Initial muscle motor deficiency (MRC scale)	- left IS: 1/5	- right SA: 4/5 - right upper T: 4/5 - right lower T: 1/5 - right IS: 4/5 - right deltoid: 4/5 - right elbow flexors: 3/5 - right biceps: 4/5	- right SA: 1/5 - right SSP: 4/5 - right IS: 4/5 - right deltoid: 4/5	- right SA: 1/5 - right IS: 3/5 - right FPL: 2/5 - left FPL/FDP2/PQ: 2/5	- right SA: 2/5 - right IS: 4/5, left 1/5 - left T: 4/5 - right FPL/FDP/PQ: 2/5 - left FPL/FDP/PQ: 3/5	- T: right 1/5, left 3/5 - SA: right 1/5, left 4/5 - IS: right 1/5, left: 2/5 - right FPL: 1/5 - left FPL: 3/5 - right FDP2: 1/5 - right PQ: 0/5 - left PQ: 3/5 - bilat diaphragm: orthopnoea requiring oxygen at night
EDX data						
Time since onset in months	3	1	3	6	3	3

Continued

Table 1 Continued

Case Number	1	2	3	4	5	6
EDX: importance of the initial nerve lesions	- severe left SSN	- severe right LTN - important right SAN - mild right SSN	- severe right LTN - moderate upper trunk of BP (C5C6C7) or C5C6C7 root entrapment	- important right LTN - moderate right SSN - moderate left LABCN - important bilat AIN	- obvious right LTN - obvious right sensory fibre of median nerve - severe left SSN - mild left C7 - important right & moderate left AIN	- severe right & mild left LTN - severe right & moderate left AIN - severe bilat SSN - severe bilat SAN - severe bilat PN
MRI data						
Cervical MRI data	/	No radicular impingement	Narrowing of the cervical spine canal	No radicular impingement	Left C7 impingement	No radicular impingement
Scapular MRI data						
Time since onset	/	3 years	6 months	8 months	6 months	10 months
Scapular MRI	/	- hyperT1*: right SA - amyotrophy right SA	- hyperT1: right TM - hyperT2 Dixon†: right SA/Deltoid - amyotrophy: right SA/Deltoid/TM/BB/IS/SSC	- hyperT2 Dixon: right SA - amyotrophy right SA	- hyperT1: both SA - hyperT2: left IS/SSp, - amyotrophy: left IS/SSp - hyperT2 Dixon: PQ/FDP/AM on left arm MRI	- hyperT2 Dixon: both T, both IS, right SA - amyotrophy: both SSp

*HyperT1 signal: muscle fatty infiltration.

†HyperT2 Dixon signal: muscle oedema.

/, Missing data.

AM, Antoneal muscle; ASAT, Aspartate aminotransferase; ALAT, Alanine aminotransferase; AIN, Anterior interosseous nerve; BP, Brachial plexus; bilat, bilateral, CMAP, Compound motor action potential; FPL: flexor pollicis longus; FDP2, Flexor digitorum profundus of digit 2; HEV, Hepatitis E virus; IS, Infraspinatus; LTN, Long thoracic nerve; LABCN, Lateral antebrachial cutaneous nerve; NRS, Numeric rating scale; PQ: Pronator quadratus; PN, Phrenic nerve; RT-PCR, reverse transcription PCR; SSN, Suprascapular nerve; SAN, Spinal accessory nerve; SA, Serratus anterior; SSp, Supraspinatus; T, Trapezius.

Table 2 Follow up clinical and EDX data, presented from the mildest to the severest

Case Number	1	2	3	4	5	6
Follow up data						
Clinical data:						
Time after onset	8 years	4 years	2 years	3 years	3 years	2.5 years
Pain (NRS)	0/10	0/10	0/10	0/10	0/10	0/10
Muscle motor deficiency	- left IS: 5/5	Complete recovery: all muscles 5/5	- right SA: 4/5 - right SSp: 4/5 - right IS: 4/5 - right deltoid: 5/5 - right elbow flexors/biceps: 4/5	Complete recovery: all muscles 5/5	- right SA: 4/5 - bilat IS: 4/5 - right FPL/FDP/PQ: 3/5 - left FPL/FDP/PQ: 5/5	- bilat T: 5/5 - SA: right 5/5, left: 4/5 - bilat IS: 4/5 - right FPL: 3/5 - left FPL: 4/5 - bilat FDP2: 5/5 - right PQ: 4/5 - left PQ: 5/5 - bilat diaphragm: orthopnoea improved but still requiring oxygen at night
EDX data:						
Time after onset	8 years	3.5 years	2 years	3 years	3 years	2.5 years
EDX	/ the patient was evaluated in our centre but didn't want to perform a new EDX as he felt totally fine	- normal interference pattern for deltoid, biceps and trapezius - outstanding increase of motor units number and of CMAP amplitude for SA, IS; T; PQ	- very good increase of motor units number with collateral reinnervation; and of CMAP amplitude for SA, IS; T; PQ - recovery limited by concomitant C6C7 root entrapment	the patient was evaluated in our centre but didn't want to perform a new EDX as he felt totally fine	- very good increase of motor units number and collateral reinnervation in left PQ, right SA and right IS - good but less significant increase of motor units in right PQ and left IS	- normal pattern in both T and right PQ - excellent increase of motor units number with direct and collateral reinnervation; with normal CMAP amplitude for right SA, and both IS - 50% recovery of PN

*HyperT1 signal: muscle fatty infiltration.

†HyperT2 Dixon signal: muscle oedema.

/, Missing data.

AIN, Anterior interosseous nerve; AM, Anconeal muscle; bilat, Bilateral; CMAP, Compound motor action potential; IS, Infraspinatus; FPL, Flexor pollicis longus; FDP2, Flexor digitorum profundus of digit 2; LABCN, Lateral antebrachial cutaneous nerve; LTN, Long thoracic nerve; LTN, Long thoracic nerve; PQ, Pronator quadratus; PN, Phrenic nerve; SSN, Suprascapular nerve; SAN, Spinal accessory nerve; SA, Serratus anterior; SSp, Supraspinatus; T, Trapezius.

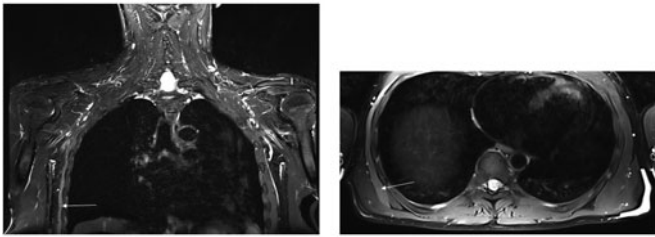


Figure 1 Scapular MRI of case n°4: coronal section, T2 Dixon water sequence (A), and axial section, T2 Dixon water sequence (B) showing hyper signal and amyotrophy of right serratus anterior muscle (white arrow).

in our case series), before considering a potential relation with HEV and especially HEV-associated NA. Of note, liver enzyme elevation was first related to paracetamol or AINS medication in two cases, before hepatitis E was diagnosed. In our case series, only 1 patient was viraemic: the only one that had been tested within 10 days of the onset of HEV infection. This is consistent with larger studies, highlighting the interest in early testing for HEV in case of NA.¹⁹

The main limitations of our study include reporting cases seen in a tertiary centre, which might be more severe than usual HEV-associated NA, and not including functional criteria in the assessment of our patients. This was not the goal of our work but limitation of activity, evaluated by functional criteria should be investigated in further studies. Indeed, having a pain of 0 associated with a MRC score of 5 does not mean a full recovery because some patients might experience early fatigability and some might have changed their habits or even their work.

Acknowledgements The authors wish to thank Julianne Ruetz for her help regarding English language usage.

Contributors All authors were involved in drafting the manuscript or revising it critically, and approved the final version. RG had full access to all the data in the study and takes responsibility for the integrity of the data and accuracy of the data analysis. Study design: JZ, PS, AR, MMLC. Data Collection: JZ, PS, AR, MMLC.

Funding The authors have not declared a specific grant for this research from any funding agency in the public, commercial or not-for-profit sectors.

Competing interests None declared.

Patient consent for publication Not required.

Ethics approval We received local committee approval for this study.

Provenance and peer review Not commissioned; externally peer reviewed.

Open access This is an open access article distributed in accordance with the Creative Commons Attribution Non Commercial (CC BY-NC 4.0) license, which

permits others to distribute, remix, adapt, build upon this work non-commercially, and license their derivative works on different terms, provided the original work is properly cited, appropriate credit is given, any changes made indicated, and the use is non-commercial. See: <http://creativecommons.org/licenses/by-nc/4.0/>.

ORCID iD

Romain Garofoli <http://orcid.org/0000-0003-3788-819X>

REFERENCES

- van Alfen N, van Engelen BG, Hughes RA. Treatment for idiopathic and hereditary neuralgic amyotrophy (brachial neuritis). *Cochrane Database Syst Rev* 2009;8.
- van Alfen N, van Eijk JJ, Ennik T, et al. Incidence of neuralgic amyotrophy (Parsonage Turner syndrome) in a primary care setting: a prospective cohort study. *PLoSOne* 2015;10:e0128361.
- van Alfen N, van Engelen BG. The clinical spectrum of neuralgic amyotrophy in 246 cases. *Brain* 2006;129:438–50.
- Seror P, Lenglet T, Nguyen C, et al. Unilateral winged scapula: clinical and electrodiagnostic experience with 128 cases, with special attention to long thoracic nerve palsy: winged scapula and LTN palsy. *Muscle Nerve* 2018;6:913–20.
- Seror P. Neuralgic amyotrophy. an update. *Joint Bone Spine* 2017;84:153–8.
- Van Eijk JJ, Groothuis JT, Van Alfen N, et al. Neuralgic amyotrophy: an update on diagnosis, pathophysiology, and treatment: neuralgic amyotrophy update. *Muscle Nerve* 2016;53:337–50.
- Fong F, Illahi M. Neuralgic amyotrophy associated with Hepatitis E virus. *Clin Neurol Neurosurg* 2009;111:193–5.
- Scanvion Q, Perez T, Cassim F, et al. Neuralgic amyotrophy triggered by Hepatitis E virus: a particular phenotype. *J Neurol* 2017;264:770–80.
- Lapa D, Capobianchi MR, Garbuglia AR, et al. Epidemiology of Hepatitis E virus in European countries. *Int J Mol Sci* 2015;10:25711–43.
- Kamar N, Bendall R, Legrand-Abravanel F, et al. Hepatitis E. *Lancet* 2012;379:2477–88.
- Dalton HR, Bendall R, Ijaz S, et al. Hepatitis E: an emerging infection in developed countries. *Lancet Infect Dis* 2008;8:698–09.
- Mansuy JM, Saune K, Rech H, et al. Seroprevalence in blood donors reveals widespread, multi-source exposure to hepatitis E virus, southern France, October 2011. *Euro Surveill* 2015;20:27–34.
- Gaskin CM, Helms CA. Parsonage-turner syndrome: MR imaging findings and clinical information of 27 patients. *Radiology* 2006;240:501–07.
- Nguyen C, Guerini H, Zauderer J, et al. Magnetic resonance imaging of dynamic scapular winging secondary to a lesion of the long thoracic nerve. *Joint Bone Spine* 2016;83:747–9.
- Seror P, Kuntz PP, Maisonobe T. Sensory nerve action potential abnormalities in neuralgic amyotrophy: a report of 18 cases. *J Clin Neuromuscul Dis* 2002;4:45–9.
- Seror P. Isolated sensory manifestations in neuralgic amyotrophy: report of eight cases. *Muscle Nerve* 2004;29:134–8.
- van Eijk JJ, Dalton HR, Ripellino P, et al. Clinical phenotype and outcome of Hepatitis E virus: associated neuralgic amyotrophy. *Neurology* 2017;89:909–17.
- Maldonado AA, Zuckerman SL, Howe BM, et al. 'Isolated long thoracic nerve palsy': more than meets the eye. *J Plast Reconstr Aesthet Surg* 2017;70:1272–79.
- Ripellino P, Pasi E, Melli G, et al. Neurologic complications of acute hepatitis E virus infection. *Neurol Neuroimmunol Neuroinflamm* 2019;5.
- Blasco-Perrin H, Madden RG, Stanley A, et al. Hepatitis E virus in patients with decompensated chronic liver disease: a prospective UK/ French Study. *Aliment Pharmacol Ther* 2015;42:574–81.