

Clinical Study on the Minimally Invasive-Guided Genioplasty Using Piezosurgery and 3D Printed Surgical Guide

Olivier Oth, Pierre Mestrallet, Régine Glineur

Department of Oral and Maxillofacial Surgery, Erasme Hospital, Université Libre De Bruxelles, Brussels, Belgium

Abstract

Introduction: A retrospective clinical study was performed regarding the minimally invasive-guided genioplasty technique (MIGG technique) described in a previous clinical note. The aims of this clinical study were to study the incidence of immediate complications with this technique compared with a control group using a nonminimally genioplasty technique, to validate the accuracy of the three-dimensional (3D) printed cutting guide, and to evaluate the duration of the surgery and the satisfaction of the surgeons with this technique. **Materials and Methods:** One controlled group, including 56 patients, operated with a classical genioplasty and one group, including 24 patients operated with the MIGG technique. The inclusion criteria were patients from 18 years old benefiting from orthognathic surgery for dysmorphic maxillofacial disorders, sleep apneas, or posttraumatic malocclusion; operated by the three same surgeons. A database was retrospectively made, including the demographics parameters, the indication, the type and the duration of surgery, the incidence of complication, and the type of complication. The accuracy of the cutting guide was also studied by the comparison of two distances in the MIGG group on the preoperative surgical simulation and on the postoperative cephalometric radiography. A satisfaction survey for the surgeons of the department regarding the MIGG technique was also analyzed. **Conclusion:** No statistical difference was found in the incidence of complications between the MIGG group and the control group. Using a guide does not cause more surgical infection. The protection of the inferior alveolar nerve is obvious. The absence of statistical difference is due to the fact that the majority of patients also benefited from the bilateral sagittal split osteotomy during surgery. The 3D-cutting guide used is very accurate: There is indeed no significative difference in the measurements A and B before and after the genioplasty. The MIGG technique is thus a predictable, safe, and easy-to-use technique that should be used routinely by maxillofacial surgeons. It combines the latest technologies in piezosurgery and in 3D-guided surgery by the creation of a validated-accurate 3D-printed cutting guide. This technique is affordable by the use of open-source program and a desktop fused deposit Modeling 3D-printer. Finally, the comfort of the surgeon is improved, and the operating time is decreased.

Keywords: Computer-assisted, genioplasty, piezosurgery, printing, surgery, three-dimensional

INTRODUCTION

Genioplasty consists of an osteotomy of the inferior border of the mandible, allowing movement of the chin in three dimensions and positioning it in its new desired position. It was first performed by Trauner and Obwegeser in 1957.^[1] It has since benefited from many modifications.^[2]

The development of three-dimensional (3D) printing techniques and piezosurgery led us to develop a new technique of genioplasty combining these two technologies: the minimally invasive-guided genioplasty technique (aka the MIGG technique). This technique consists of combining the advantages

of a 3D printed cutting genioplasty guide and the advantages of piezosurgery. The 3D printed cutting guide is obtained by a preoperative 3D simulation of the osteotomy and a 3D

Address for correspondence: Dr. Olivier Oth,
Department of Oral and Maxillofacial Surgery, Erasme Hospital, Université
Libre De Bruxelles, Route De Lennik 808, 1070 Brussels, Belgium.
E-mail: oth.olivier@gmail.com

Received: 01-04-2019

Revised: 18-02-2020

Accepted: 11-03-2020

Published: 08-06-2020

This is an open access journal, and articles are distributed under the terms of the Creative Commons Attribution-NonCommercial-ShareAlike 4.0 License, which allows others to remix, tweak, and build upon the work non-commercially, as long as appropriate credit is given and the new creations are licensed under the identical terms.

For reprints contact: WKHLRPMedknow_reprints@wolterskluwer.com

How to cite this article: Oth O, Mestrallet P, Glineur R. Clinical study on the minimally invasive-guided genioplasty using piezosurgery and 3D printed surgical guide. *Ann Maxillofac Surg* 2020;10:91-5.

Access this article online

Quick Response Code:



Website:
www.amsjournal.com

DOI:
10.4103/ams.ams_79_19

design and 3D printing of this guide. This was done only with open source programs (computed tomography-scanner, segmentation with 3D slicer[®], design of the cutting-guide with Blender[®]) and affordable 3D printing technology (3D printer: Replicator+[®] 3D-printer (from Makerbot Industries[®], New York, USA; Biomaterial: Polyethylene Terephthalate Glycol aka PETG (Taulman[®] 3D guideline[®] filament 1.75 mm). The MIGG technique is described in detail in a previous technical note.^[3]

As we know it, the main immediate complications of genioplasty are mental nerve injuries with neurosensory deficits, asymmetries, and intraoperative bleeding.^[4]

3D-printed cutting guide could improve the predictability and accuracy of the surgical technique and protect the anatomical structures (mental nerve and dental roots) providing, by this way, safer results as described in a recent systematic review.^[5]

Piezosurgery helps to give to this technique a minimally invasive character by minimizing the immediate complications because of the intrinsic characteristics of piezoelectric surgery: selective cut of mineralized structure with less risk of vascular and nervous damage (microvibrations), intraoperative precision (thin cutting scalpel and no macrovibrations) and blood-free site (cavitation effect).^[6]

We carried out a retrospective clinical study to evaluate the MIGG technique by comparing two groups: a control group benefiting from a conventional genioplasty (without a guide and with a reciprocal saw to perform the osteotomy) and a group benefiting from the MIGG technique. The control group includes 56 patients operated from January 2007 to December 2015 and the MIGG group includes 24 patients operated from January 2016 to December 2018. All the patients were operated by the same three surgeons.

The aims of this clinical study were:

1. To study the incidence of immediate complications of genioplasties in both groups
2. To study the precision of the guide by comparing two distances in the presurgical 3D simulation and postoperative cephalometry in each patient of the MIGG group
3. To compare the duration of the intervention in the control group and in the MIGG group
4. To evaluate the satisfaction of the surgeons with the MIGG technique.

MATERIALS AND METHODS

This was a retrospective-controlled study conducted in the Maxillo-Facial department of the University Erasme Hospital of the Université Libre de Bruxelles, Brussels, Belgium.

The approval of the Ethics Committee of Erasme Hospital was first received before to conduct this study and create a database (ref: P2017/046-P2018/470).

Eligible participants were patients from 15 years old benefiting from orthognathic surgery for dysmorphic maxillofacial

disorders, sleep apneas, or posttraumatic malocclusion; operated by the three same surgeons.

Two groups were created: one controlled group including patients operated from January 2007 to December 2015 with our previous classical technique (namely without a cutting guide and with a reciprocal saw to perform the osteotomy) and one group including patients operated from January 2016 to December 2018 benefiting from the introduction of our new MIGG technique.

The demographic parameters, including age and sex were retrospectively studied. The indication of the surgery, the type of surgery (genioplasty alone or associated with a Fort I osteotomy and/or a bilateral sagittal split osteotomy [BSSO]), the duration of the surgery, the incidence of complication and the type of complication were also studied in both groups.

To study the precision of the cutting guide, two distances were compared in the MIGG group on the preoperative surgical simulation and on the postoperative cephalometric radiography: measurement A (distance between the tip of the lower incisors and the plane of osteotomy on the anterior border of the mandible) and measurement B (minimal distance between the lowest part of the curve formed by the inferior alveolar nerve during its intraosseous path in the mandible and the plane of the osteotomy) [Figure 1].

A satisfaction questionnaire was created, and each of the surgeons involved in the surgery in the MIGG group (chief surgeon, first assistant, and second assistant) responded to this questionnaire at the end of each surgery.

RESULTS

The control group included 56 patients (37 females and 19 males) aged from 15 to 62 years old (mean = 28). The

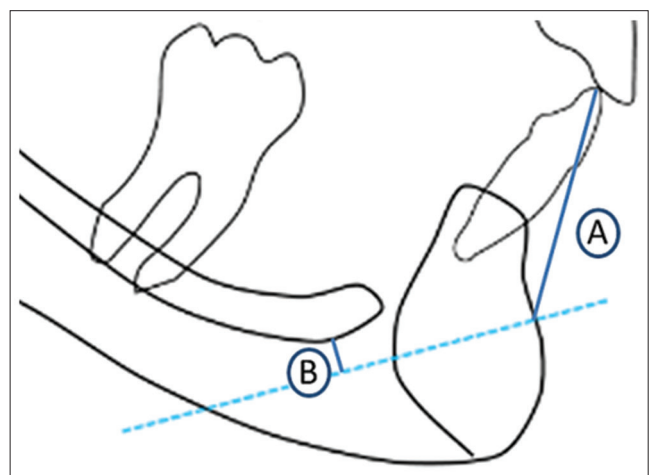


Figure 1: (A) = Measurement A (distance between the tip of the lower incisors and the plane of osteotomy on the anterior border of the mandible). B = Measurement B (minimal distance between the lowest part of the curve formed by the inferior alveolar nerve during its intraosseous path in the mandible and the plane of the osteotomy)

MIGG group included 24 patients (18 females and 6 males) aged from 18 to 49 years old (mean = 26). In the control group, 37 patients on 56 underwent a surgery combining Le Fort I osteotomy + BSSO + genioplasty; 13 patients Le Fort I + genioplasty; 6 patients BSSO + genioplasty and 0 patient genioplasty alone [Table 1]. In the MIGG group, 12 patients on 24 underwent a surgery combining Le Fort I osteotomy + BSSO + genioplasty; 7 patients Le Fort I + genioplasty; 5 patients BSSO + genioplasty and 0 patient genioplasty alone. All the patients in both groups were operated for maxillofacial dysmorphic disorders; only one patient was operated for sleep apnea in the control group. The mean time for the genioplasty was 47 min in the MIGG technique, 53 min in the control group [Table 1].

Thirteen of 56 patients (23.2%) had a complication in the control group (11 temporary neurosensory disorders; 2 infections). Six out of 24 patients (25%) had a complication in the MIGG group (5 temporary neurosensory disorders; 1 infection). There is no statistical difference in the incidence of complications between the two groups (odds ratio = 1.1; [0.36–3.36]) [Table 2].

To evaluate the accuracy of the 3D printed cutting guide, measurement A (distance between the tip of the lower incisors and the plane of osteotomy on the anterior border of the mandible) and measurement B (minimal distance between the lowest part of the curve formed by the inferior alveolar nerve during its intraosseous path in the mandible and the plane of the osteotomy) were compared before the surgery (in the 3D simulation in the open-source program Blender® [see technical note]) and after the surgery (on the postoperative cephalometric radiography). For measurement A, one-sample Kolmogorov–Smirnov test for the evaluation of the normality

followed by a Wilcoxon test showed a $P = 0.10$, meaning that there is no significant difference between the measurement A on the 3D planned simulation of the genioplasty and after the surgery [Figure 2]. For measurement B, one-sample Kolmogorov–Smirnov test for the evaluation of the normality followed by a Student’s t -test showed a P value of 0.36. There is thus also no significant difference in measurement B before and after the genioplasty [Figure 3].

The qualitative surveys of satisfaction of the surgical cutting guide [Figure 4] were analyzed and showed the followings results: the surgical cutting guide has reassured 100% regarding the risk of damage to surrounding anatomical structures. Two-third of the questionnaires found the use of the guide to be satisfactory, the last third finding, it very satisfactory. We also wanted to evaluate the stability of this one: the set of protagonists finds its stability satisfactory. The general impression of the use of a surgical guide is satisfactory for 2/3 of the questionnaires, the last third finding it very satisfactory. Finally, all practitioners would like to reuse a surgical guide during a genioplasty.

DISCUSSION

The incidence of complications is identical in both groups. The appearance of a neurosensory disorder of the labiomental area is the most frequent complication, although none was definitive in both groups. Only one neurosensory disorder is clearly attributable to the genioplasty in the MIGG group because it appeared in a patient who benefited of a genioplasty associated with a Le Fort I osteotomy. The five other cases of neurosensory disorder appeared in patients who underwent intervention that also included a BSSO. In the control group, all patients with neurosensory disorder also underwent a BSSO during the surgery. Genioplasty alone is rarely performed in our department but would be ideal as future study design. Although this complication rate may seem important, it corresponds to that found by other authors in the literature.^[4] It should also be noted that all these neurosensory disorders have been shown to be temporary.

Table 1: Characteristics of both group

	Control group	MIGG group
Sample size (male/female)	56 (19/37)	24 (6/18)
Age in years (minimum-maximum) (mean)	15-62 (28)	18-49 (26)
LFI + BSSO + genioplasty	37	12
LFI + genioplasty	13	7
BSSO + genioplasty	6	5
Genioplasty alone	0	0
Mean surgical time (in min)	47	53

BSSO: Bilateral sagittal split osteotomy, MIGG: Minimally invasive guided genioplasty, LFI: Le Fort I osteotomy

Table 2: Comparison of the complications

	Control group	MIGG group
Presence of complication	13	6
Absence of complication	43	18
Total of patients per group	56	24
OR (95% CI)	1.10 (0.36-3.36)	

OR: Odds ratio, CI: Confidence interval, MIGG: Minimally invasive guided genioplasty

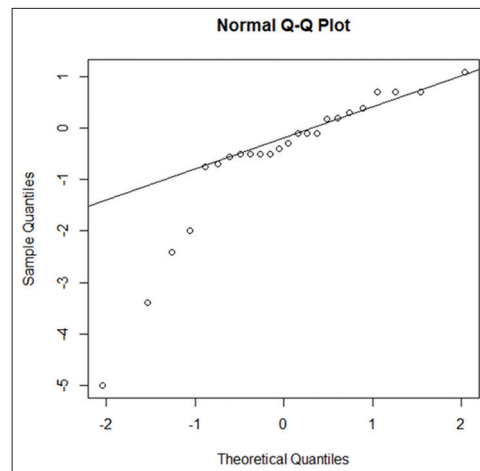


Figure 2 : Q-Q plot measurement A

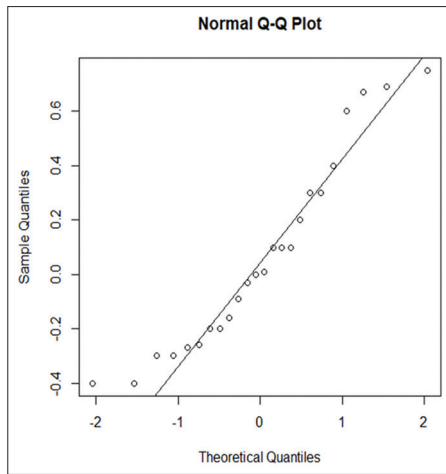


Figure 3: Q-Q plot measurement B

The main goal of a surgical cutting guide in genioplasty is to ensure during the presurgical simulation that the osteotomy line will be under the dental roots and under the lower alveolar nerves. It is, therefore, important that the osteotomy line defined during this simulation corresponds well to the surgical reality. Many factors could make that the cutting plane chosen preoperatively does not correspond exactly to the inferior border of the cutting guide during the surgery: 3D printing problems (inaccuracy of the 3D printer, insufficient quality of rendering,), deformation of the guide during the process, instability of the guide when used intraoperatively, reason why our team did an *in vitro* study that proves that no volumetric deformation of the guide appeared during the 3D printing or during the sterilization process of the guide (we use a low-temperature hydrogen peroxide gas plasma sterilization technique (Sterrad® technique). The results of this clinical retrospective study show that there is no significant difference between the cutting plan defined preoperatively and the cutting plan observed postoperatively on the control cephalometric radiograph. This was checked at two distinct sites of the operating site (measurement A and B). Those results suggest that the MIGG technique is very accurate surgical technique in terms of compliance with the osteotomy cutting plan chosen preoperatively.

The results of the satisfaction questionnaire show great confidence of the surgeons in this technique. The MIGG technique should be used routinely according to them. The application of this technique by other surgical teams and the response to the same questionnaire would remove the bias related to the fact that the contributor of this technique is part of the same department, in which these surgeons work.

Two other clinical studies about 3D printed surgical guide in genioplasties of the level of evidence type III, according to the Oxford center for evidence-based medicine were found in the literature: one is multicentric^[7] and one is a controlled one.^[8] Both concluded in increasing in accuracy, safer results but a small increase in surgical times, and a modest increase in cost. Hsu also proposes that this technique be used routinely.^[7]

1. Did the surgical guide reassure you about the operative risks of genioplasty?
Not satisfactory - unsatisfactory - moderately satisfactory - satisfactory - very satisfactory
2. Is the guide easy to use?
Not satisfactory - unsatisfactory - moderately satisfactory - satisfactory - very satisfactory
3. Is the guide stable?
Not satisfactory - unsatisfactory - moderately satisfactory - satisfactory - very satisfactory
4. Would you like to reuse a surgical guide during a genioplasty?
Yes - No
5. What is your overall impression of the surgical guide?
Not satisfactory - unsatisfactory - moderately satisfactory - satisfactory - very satisfactory

Figure 4: Survey on the overall satisfaction of the surgeons with the surgical cutting guide

These authors use a repositioning guide and these are focused on the accuracy of the repositioning of the chin according to the preoperative simulation. We have in our study concentrated on the accuracy of the cutting plan chosen preoperatively.

Little has been published over minimally invasive techniques in genioplasty. One technical note by Nadjmi *et al.* uses a vertical incision to protect the peribuccal tissues and minimize the functional recovery time.^[9] This author focused on the direction of the initial mucosal incision but used a conventional reciprocating saw instead of piezoelectric cutting device and do not use any cutting guide for preserving anatomical structures as opposed to our technique. The use of a 3D cutting guide is also used by several others.^[5] Its use allows to have a reduced surgical field, as noted by Costa *et al.*^[10] Polley and Figueroa^[11] find as we do that 3D cutting guide simplifies the execution of the surgery and give better confidence for the surgeon in the technique.

CONCLUSIONS

No statistical difference was found in the incidence of complications between the MIGG group and the control group. The protection of the anatomical structures (e.g., the inferior alveolar nerve) is obvious and is the main advantage of this technique. The absence of statistical difference is due to the fact that the majority of patients also benefited from a BSSO during surgery. Indeed, the majority of patients also benefited from a BSSO during the surgery. Performing the same study on genioplasties alone could clarify the advantage of the onset of the neurosensory disorder. It should also be noted that the use of a surgical guide did not cause more infection. This guide used is totally accurate; there is indeed no significant difference in the measurements A and B before and after the genioplasty. The advantages of the MIGG technique are numerous: the high predictability of the results thanks to a presurgical simulation and a validated printing and sterilization technique, a precise cutting plane respecting the surrounding anatomical structures in addition to the contribution of the piezosurgery. It is an easy-to-use technique with a space-safe

cutting guide and does not require a huge budget to be set up in a surgical service through the use of open-source software and affordable 3D printing technology. The comfort of the surgeon is also increased, as seen with the survey, and the operating time is decreased.

All of these reasons make the MIGG technique a predictable, safe, and easy-to-use technique that should be used routinely by maxillofacial surgeons.

A new design study with genioplasties alone is planned in our department to study more precisely the reduction of complications that this technique could bring.

Financial support and sponsorship

Dr. Olivier Oth received financial grants of the direction Board of Erasme Hospital to conduct this study.

Conflicts of interest

There are no conflicts of interest.

REFERENCES

1. Trauner R, Obwegeser H. The surgical correction of mandibular prognathism and retrognathia with consideration of genioplasty. I surgical procedures to correct mandibular prognathism and reshaping of the chin. *Oral Surg Oral Med Oral Pathol* 1957;10:677-89.
2. San Miguel Moragas J, Oth O, Büttner M, Mommaerts MY. A systematic review on soft-to-hard tissue ratios in orthognathic surgery part II: Chin procedures. *J Craniomaxillofac Surg* 2015;43:1530-40.
3. Oth O, Glineur R. The minimally invasive-guided genioplasty technique using piezosurgery and 3D printed surgical guide: An innovative technique. *Ann Maxillofac Surg* 2020;10:178-81.
4. Richard O, Ferrara JJ, Cheynet F, Guyot L, Thierry G, Blanc JL. Complications of genioplasty. *Rev Stomatol Chir Maxillofac* 2001;102:34-9.
5. Oth O, Durieux V, Orellana MF, Glineur R. Genioplasty with surgical guide using 3D-printing technology: A systematic review. *J Clin Exp Dent* 2020;12:e85-92.
6. Bertossi D, Albanese M, Mortellaro C, Malchiodi L, Kumar N, Nocini R, *et al.* Osteotomy in genioplasty by piezosurgery. *J Craniofac Surg* 2018;29:2156-9.
7. Hsu SS, Gateno J, Bell RB, Hirsch DL, Markiewicz MR, Teichgraeber JF, *et al.* Accuracy of a computer-aided surgical simulation protocol for orthognathic surgery: A prospective multicenter study. *J Oral Maxillofac Surg* 2013;71:128-42.
8. Li B, Shen SG, Yu H, Li J, Xia JJ, Wang X. A new design of CAD/CAM surgical template system for two-piece narrowing genioplasty. *Int J Oral Maxillofac Surg* 2016;45:560-6.
9. Nadjmi N, Van Roy S, Van de Castele E. Minimally invasive genioplasty procedure. *Plast Reconstr Surg Glob Open* 2017;5:e1575.
10. Costa PJ, Demétrio MS, Nogueira PT, Rodrigues LR, Júnior PD. A new proposal for three-dimensional positioning of the chin using a single computer-aided design/computer-aided manufacturing surgical guide. *J Craniofac Surg* 2018;29:1963-4.
11. Polley JW, Figueroa AA. Orthognathic positioning system: Intraoperative system to transfer virtual surgical plan to operating field during orthognathic surgery. *J Oral Maxillofac Surg* 2013;71:911-20.