



## Case report

## En face swept-source optical coherence tomographic analysis of X-linked juvenile retinoschisis



Shinji Ono\*, Atsushi Takahashi, Tomoko Mase, Taiji Nagaoka, Akitoshi Yoshida

Department of Ophthalmology, Asahikawa Medical University, Asahikawa, Japan

## ARTICLE INFO

## Article history:

Received 25 December 2015

Received in revised form

20 February 2016

Accepted 7 March 2016

Available online 20 April 2016

## Keywords:

X-linked juvenile retinoschisis

En face image

Swept-source optical coherence

## ABSTRACT

**Purpose:** To clarify the area of retinoschisis by X-linked juvenile retinoschisis (XLRS) using swept-source optical coherence tomography (SS-OCT) en face images.

**Observations:** We report two cases of XLRS in the same family. The patients presented with bilateral blurred vision. The posterior segment examination showed a spoked-wheel pattern in the macula. SS-OCT cross-sectional images revealed widespread retinal splitting at the level of the inner nuclear layer bilaterally. We diagnosed XLRS. To evaluate the area of retinoschisis, we obtained en face SS-OCT images, which clearly visualized the area of retinoschisis seen as a sunflower-like structure in the macula.

**Conclusion and Importance:** We report the findings on en face SS-OCT images from patients with XLRS. The en face images using SS-OCT showed the precise area of retinoschisis compared with the SS-OCT thickness map and are useful for managing patients with XLRS.

© 2016 The Authors. Published by Elsevier Inc. This is an open access article under the CC BY-NC-ND license (<http://creativecommons.org/licenses/by-nc-nd/4.0/>).

## 1. Introduction

X-linked juvenile retinoschisis (XLRS) is the most common cause of juvenile macular degeneration [1]. Although previous reports have shown that spectral-domain optical coherence tomography (SD-OCT) is useful for diagnosing XLRS [2,3], it is difficult to evaluate the precise area of retinoschisis using SD-OCT cross-sectional images and thickness maps. We present en face images obtained using swept-source OCT (SS-OCT) to clarify the area of retinoschisis by XLRS.

## 2. Findings

## 2.1. Case 1

A 16-year-old boy (case 1) presented with bilateral blurred vision. The family history showed that his maternal grandfather had visual loss. At presentation, the best-corrected visual acuity (BCVA) was 20/60 bilaterally. The intraocular pressures (IOPs) were normal in both eyes. The anterior segment examination was unremarkable. The posterior segment examination showed a spoked-

wheel pattern in the macula. There were no pigmentary changes suggesting retinoschisis in the peripheral retina. Full-field electroretinography showed a reduced b/a ratio. SS-OCT (DRI OCT-1 Atlantis, Topcon Corp., Tokyo, Japan) cross-sectional images showed widespread retinal splitting at the level of the inner nuclear layer (INL) bilaterally (Fig. 1A).

To further evaluate the area of retinoschisis, we evaluated en face SS-OCT images, which clearly visualized the area of retinoschisis seen as a sunflower-like structure in the macula (Fig. 1B). The area of thickened retina observed on the SS-OCT thickness map was narrower than the area of retinoschisis on the en face images (Fig. 1C).

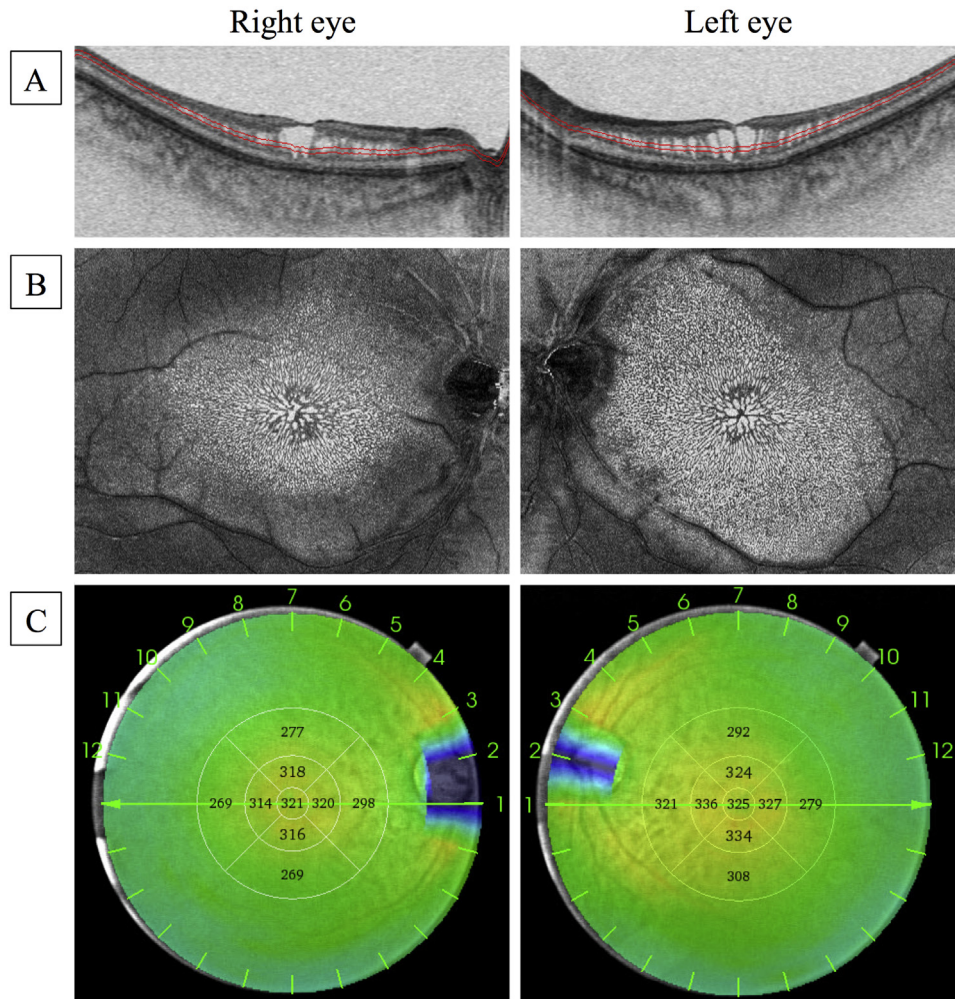
## 2.2. Case 2

A 12-year-old boy (case 2), the younger brother of case 1, presented with bilateral blurred vision and metamorphopsia. The BCVA values were 20/32 in the right eye and 20/40 in the left eye. The IOPs were normal bilaterally. The anterior segment examination was unremarkable. The fundus examination showed a spoked-wheel pattern in the foveal region but no schisis in the peripheral retina. SS-OCT cross-sectional images showed elevated retinoschisis bilaterally (Fig. 2A).

The en face SS-OCT images showed a sunflower-like structure around the fovea (Fig. 2B). The area of retinal thickening on the

\* Corresponding author. Department of Ophthalmology, Asahikawa Medical University, Midorigaoka Higashi 2-1-1-1, Asahikawa, 078-8510, Japan.

E-mail address: [o-shinji@asahikawa-med.ac.jp](mailto:o-shinji@asahikawa-med.ac.jp) (S. Ono).



**Fig. 1.** Cross-sectional, En face, and Thickness Map Swept-Source Optical Coherence Tomography (SS-OCT) Images of Case 1. A, Cross-sectional images show the splitting of the retina at the level of the inner nuclear layer in the macula. The red lines represent the position and thickness of the slab obtaining the en face images. B,  $9 \times 12$ -mm en face images show the area of retinoschisis as a sunflower-like structure in the macula. C, The retinal thickness maps obtain using SS-OCT. (For interpretation of the references to colour in this figure legend, the reader is referred to the web version of this article.)

thickness map was similar to the area of retinoschisis on the en face images (Fig. 2C).

Both patients provided written consent for publication of personal information including medical record details and photographs.

### 3. Discussion

X-linked juvenile retinoschisis causes breaks in the inner retina, vitreous hemorrhage, and serious complications such as retinal detachment in some cases as a result of disruption of the separate inner retina [4]. Therefore, it is important to accurately evaluate the area of retinoschisis to manage XLRS. Cozzi and Pagliarini [5] reported the findings of retinoschisis on en face SD-OCT images. By contrast, we used en face SS-OCT images to more clearly visualize the area of retinoschisis in patients with XLRS. In addition, the en face SS-OCT images more accurately demonstrate the area of retinoschisis compared with the SS-OCT thickness map. We are unaware of previous reports of this finding.

Previous report has shown that retinoschisis in patients with XLRS can occur in a number of different layers (the retinal nerve fiber layer in 12%, the INL in 85%, and the outer nuclear layer/outer plexiform layer in 65%) [6]. In the current cases, the retinoschisis

was localized to the INL and the en face images were created using the  $30\text{-}\mu\text{m}$  slab at  $120\text{--}130\ \mu\text{m}$  above the ellipsoidal zone. These slab images are useful to visualize the retinoschisis at the INL because they show the clearest area of the retinoschisis. If a different depth is selected, en face SS-OCT images also can visualize other layers of retinoschisis. Further study is needed to determine whether SS-OCT en face images are useful in patients with retinoschisis in other layers besides the INL and across multiple layers.

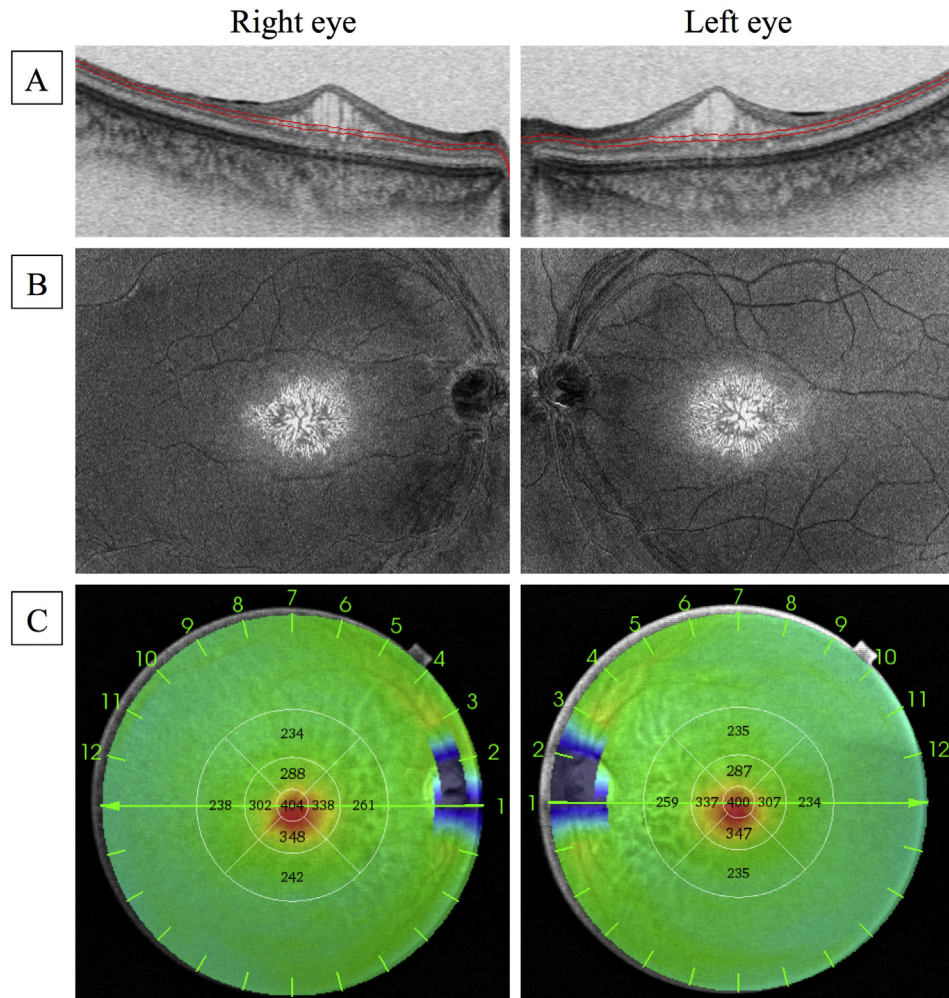
The current SS-OCT technology requires a fixation time of about 3 seconds to obtain en face images, and it is difficult to acquire images of the peripheral retina. It is necessary to reduce the imaging time and to have an eye-tracking system because patients with XLRS do not have good central fixation.

### 4. Conclusions

We report the findings on en face SS-OCT images from patients with XLRS. The en face images showed the precise area of retinoschisis and are useful for managing patients with XLRS.

### Conflict of interest disclosures

The authors have no financial/conflicting interests to disclose.



**Fig. 2.** Cross-sectional, En face, and Thickness Map Swept-Source Optical Coherence Tomography (SS-OCT) Images of Case 2. A, Cross-sectional images show the elevated retinoschisis in the macula. The red lines represent the position and thickness of the slab obtaining the en face images. B,  $9 \times 12$ -mm en face images show the area of retinoschisis as a sunflower-like structure around the fovea. C, The retinal thickness maps obtained using SS-OCT. (For interpretation of the references to colour in this figure legend, the reader is referred to the web version of this article.)

## Support

None.

## References

- [1] C.M. Mooy, L.I. Van Den Born, S. Baarsma, et al., Hereditary X-linked juvenile retinoschisis: a review of the role of Muller cells, *Arch. Ophthalmol.* 120 (7) (2002) 979–984.
- [2] N.Z. Gregori, A.M. Berrocal, G. Gregori, et al., Macular spectral-domain optical coherence tomography in patients with X linked retinoschisis, *Br. J. Ophthalmol.* 93 (3) (2009) 373–378.
- [3] T. Leng, Two cases of X-linked retinoschisis with different spectral domain optical coherence tomography findings, *Clin. Ophthalmol.* 6 (2012) 1563–1565.
- [4] N.D. George, J.R. Yates, A.T. Moore, X linked retinoschisis, *Br. J. Ophthalmol.* 79 (7) (1995) 697–702.
- [5] M. Cozzi, S. Pagliarini, Retinoschisis microstructure visualization with en face spectral domain optical coherence tomography, *Retina* 36 (1) (2015) 227–228.
- [6] J. Yu, Y. Ni, P.A. Keane, C. Jiang, W. Wang, G. Xu, Foveomacular schisis in juvenile X-linked retinoschisis: an optical coherence tomography study, *Am. J. Ophthalmol.* 149 (6) (2010) 973–978 e972.