

Patterns of Uveitis at a Tertiary Referral Center in Northeastern Iran

Seyedeh Maryam Hosseini¹, MD; Nasser Shoeibi¹, MD; Raheleh Ebrahimi², MD; Mehdi Ghasemi¹, MD

¹Eye Research Center, Mashhad University of Medical Sciences, Mashhad, Iran

²Retina Research Center, Mashhad University of Medical Sciences, Mashhad, Iran

Abstract

Purpose: To describe the demographic and clinical patterns of patients with uveitis referred to a tertiary center in northeastern Iran.

Methods: This cross-sectional retrospective study included 235 patients with uveitis who had been referred to the uveitis clinic of Khatam-Al-Anbia eye hospital, affiliated to Mashhad University of Medical Sciences, from February 2013 to March 2014. Data regarding patient age, sex, anatomical location of the disease, and etiologic and clinical features were analyzed.

Results: Mean patient age at the onset of uveitis was 35.75 ± 16.3 (range: 3–82) years. The ratio of females to males was 1.5 to 1. Sixty-four percent had bilateral involvement. The predominant type of inflammation was non-granulomatous (76%). Panuveitis (46.8%, 110 cases) was the most common form of uveitis followed by anterior (37%, 87 cases), intermediate (11.9%, 28 cases), and posterior uveitis (4.25%, 10 cases). The most common diagnoses were “idiopathic” in anterior and intermediate uveitis cases, toxoplasmosis in posterior uveitis group, and Behçet and Vogt-Koyanagi-Harada diseases in panuveitis cases. Overall, noninfectious causes (80.42%) of uveitis were more frequent than infectious causes (19.57%). The proportion of noninfectious uveitis was 82.75% in anterior uveitis, 78.18% in panuveitis, 92.85% in intermediate uveitis, and 50% in posterior uveitis. The most common associated systemic disease was Behçet disease.

Conclusion: In contrast to most epidemiologic studies of uveitis, the clinical and etiologic patterns of uveitis were different in a tertiary referral center in northeastern Iran. Panuveitis was the most common clinical pattern in this study, and the most common associated systemic disease was Behçet disease.

Keywords: Behcet Syndrome; Panuveitis; Uveitis; Epidemiology

J Ophthalmic Vis Res 2018; 13 (2): 138–143

INTRODUCTION

Uveitis is a vision threatening intraocular inflammatory disease of uveal tissues with or without involvement

Correspondence to:

Mehdi Ghasemi, MD. Eye Research Center, Khatam-Al-Anbia Eye Hospital, Abutalib Junction, Koleh Douz Blvd, Mashhad 91959, Iran. E-mail: ghasemi760@gmail.com

Received: 25-03-2017

Accepted: 29-10-2017

of adjacent tissues such as the retina, optic nerve, and sclera. It can be induced by infectious or non-infectious etiologies, as well as by a variety of systemic diseases. If not managed in a timely manner, uveitis leads to severe vision loss. Uveitis is estimated to be the cause of 5–10% of blindness or visual impairment worldwide.^[1] Up to 20% of legal blindness in developed countries can be attributed to complications of uveitis.^[2-7] Uveitis most often affects patients of working age (20–50 years);^[5,6]

This is an open access journal, and articles are distributed under the terms of the Creative Commons Attribution-NonCommercial-ShareAlike 4.0 License, which allows others to remix, tweak, and build upon the work non-commercially, as long as appropriate credit is given and the new creations are licensed under the identical terms.

For reprints contact: reprints@medknow.com

How to cite this article: Hosseini SM, Shoeibi N, Ebrahimi R, Ghasemi M. Patterns of uveitis at a tertiary referral center in Northeastern Iran. *J Ophthalmic Vis Res* 2018;13:138-43.

Access this article online

Quick Response Code:



Website:

www.jovr.org

DOI:

10.4103/jovr.jovr_67_17

hence, the socioeconomic burden of the disease is significant.

The pattern and prevalence of uveitis varies according to age, sex, race, and genetics, as well as environmental factors and the study center (private clinics or tertiary centers). There are several reports regarding patterns of uveitis in different parts of Iran.^[8-12] However, the epidemiology and etiology of uveitis in northeastern Iran is not fully defined. Understanding the demographic and clinical patterns of uveitis in different geographic areas will prevent unnecessary laboratory testing and waste of valuable and limited resources. The present study is a retrospective chart review of uveitis cases in Khatam-Al-Anbia Hospital, Mashhad, Iran, the largest tertiary referral center in northeast Iran, to show the pattern of the disease in this area of the country.

METHODS

This cross-sectional retrospective study included new patients referred to the uveitis clinic at Khatam-Al-Anbia Eye Hospital, affiliated to Mashhad University of Medical Sciences (MUMS), from February 2013 to March 2014. The institutional review board and ethics committee of MUMS approved this study, which adhered to the tenets of the Declaration of Helsinki.

Following accurate history taking, patients suspected to have uveitis received detailed eye examinations, physical examinations, and laboratory work-up for infectious or inflammatory etiologies or systemic diseases. The following laboratory tests tailored to eye examination, systemic symptom associations and most probable differentials were conducted: complete blood count, erythrocyte sedimentation rate, C-reactive protein level, urinalysis, venereal disease research laboratory test or fluorescent treponemal antibody-absorption for syphilis, polymerase chain reaction (PCR) of aqueous or vitreous humor for herpetic and cytomegalovirus uveitis, chest X-ray (CXR) or high-resolution computed tomography (CT) of the chest for sarcoidosis and tuberculosis (TB), sputum smear and culture and purified protein derivative (PPD) skin test for TB, antinuclear antibody testing, antineutrophil cytoplasmic antibody testing, angiotensin-converting enzyme level, human leukocyte antigen (HLA) typing, sinus, sacroiliac and brain imaging, and skin and mucus membrane biopsy. In cases with anterior chamber and vitreous reactions without obvious retinitis or choroiditis, fluorescein angiography (FA) and/or indocyanine green angiography was performed to detect subclinical retinal vasculitis, the extent of the non-perfusion area, and choroidal inflammation. In particular, in nearly all cases suspected of Behçet disease, wide-field FA (Spectralis; Heidelberg Engineering, Heidelberg, Germany) was performed. The diagnosis of infectious uveitis was based on typical clinical findings

(for most cases of toxoplasmosis, cytomegalovirus [CMV] retinitis, and herpes simplex virus [HSV] uveitis), serology confirmation (toxoplasmosis, and human T-lymphotropic virus [HTLV-1]), eyelid skin biopsy (leishmaniasis), PCR result (CMV, HSV, and TB), CXR or chest CT, and PPD skin test (TB). Because isolation of *Mycobacterium tuberculosis* bacilli from ocular tissues is required for definitive diagnosis of TB and this is difficult to achieve (high incidence of false negative results), the diagnosis of ocular TB is often presumed in the presence of suggestive ocular findings. Where needed, specialists in rheumatology, infectious diseases, and neurology were consulted. Systemic disease diagnosis was based on defined standard criteria (for example, Behçet disease). Rheumatologic diseases that were not classified as a specific entity at the time of study were considered as undifferentiated connective tissue disease.

Eyes with mutton fat keratic precipitates, iris nodules, or choroidal and optic nerve granuloma were considered to have granulomatous uveitis. Others were considered to have non-granulomatous or an undetermined histologic type of uveitis. In cases where the etiology could not be ascertained by the above-mentioned work-up, the disorder was considered to be idiopathic. Incomplete profiles and uveitis as a result of trauma or surgery were excluded.

Based on the Standardization of Uveitis Nomenclature Working Group criteria, anatomical location was classified into four groups: anterior (the anterior chamber is the primary site of inflammation), intermediate (the major site of inflammation is the vitreous cavity), posterior uveitis (intraocular inflammation primarily involving the retina and/or choroid), and panuveitis (diffuse inflammation without a predominant site of involvement).^[13]

Data regarding age, sex, etiology, anatomical location, and associated systemic disease were entered into SPSS version 16 (SPSS Inc., Chicago, IL, USA). A descriptive statistical analysis was conducted for the variables.

RESULTS

A total of 235 newly diagnosed patients with uveitis were evaluated, including 141 (60%) women and 94 (40%) men, with a female to male ratio of 1.5 to 1. In 150 (63.8%) patients, ocular involvement was bilateral and in 85 (36.2%) patients, it was unilateral. Mean age of patients was 35.75 (± 16.34) years and their ages ranged from three to 82 years. A statistically significant difference was observed between male and female patients' age (32.05 ± 15.76 years for males and 38.16 ± 16.47 years for females; $P < 0.05$). Non-granulomatous inflammation was found in 179 (76%) patients whereas 32 (13.6%) cases were affected by granulomatous inflammation. In 24 (10%) cases, the type of inflammation was not defined.

Demographics for the study patients are summarized in Table 1.

Non-infectious uveitis (189 cases, 80.42%) was more common than infectious uveitis (46 cases, 19.57%). Infectious etiologies (based on the clinical and paraclinical findings) were responsible for 17.2% of anterior uveitis, 7.14% of intermediate uveitis, 50% of posterior uveitis, and 21.81% of panuveitis cases. Based on the anatomical location of the disease, panuveitis was the most frequent (46.8%) form of uveitis, followed by anterior uveitis (37%), intermediate uveitis (11.9%), and posterior uveitis (4.25%) [Figure 1].

A specific etiology was found in 168 (71.5%) patients based on clinical and laboratory findings, and in 67 (28.5%) patients, the etiology was unknown (idiopathic). The most frequent causes were Behçet disease (16.6%), Vogt-Koyanagi-Harada (VKH) disease (10.6%), herpetic uveitis including acute retinal necrosis (ARN) (8.9%), seronegative spondyloarthropathies (6.8%), Fuchs' uveitis (FU) (formerly known as FHI, Fuchs' heterochromic iridocyclitis) and presumed TB uveitis (5.1%), respectively. Other less common causes

include sympathetic ophthalmia, juvenile idiopathic arthritis, toxoplasmosis, sarcoidosis, serpiginous choroidopathy, HTLV-1-associated uveitis, multifocal choroiditis and panuveitis, multiple sclerosis, celiac disease, CMV, punctate inner choroidopathy (PIC), and leishmaniasis.

The results indicated that the most prevalent cause of anterior uveitis was idiopathic (24 cases, 27.48%), and other causes in descending order of frequency were FU (15 cases, 17.24%), herpetic uveitis (12 cases, 13.79%), seronegative spondyloarthropathies (12 cases, 13.79%), Behçet disease (11 cases, 12.64%), and juvenile idiopathic arthritis (four cases, 4.59%).

The most frequent causes of panuveitis were Behçet disease, idiopathic uveitis, and VKH, with 25 cases (22.72%) each; herpetic uveitis (acute retinal necrosis) and presumed TB, with seven cases (6.3%) each; and toxoplasmosis, with five cases (4.5%) were the most next prevalent diagnoses. Ten of 235 patients had posterior uveitis; of these, three (30%) had toxoplasmosis, and two (20%) had serpiginous choroidopathy. The following diseases were diagnosed in one patient (10%) each: idiopathic uveitis, ARN, presumed tuberculosis, sarcoidosis, and PIC. In the intermediate type, idiopathic uveitis (pars planitis) (17 cases, 60.7%), Behçet disease, and seronegative spondyloarthropathies (each with three cases, 10.7%), sarcoidosis (two cases, 7.1%), and other associated disease (one case, 3.3%) were identified. The results are presented in Table 2.

The causes of 27.5% of anterior uveitis, 60.7% of intermediate uveitis, 10% of posterior uveitis, and 22.72% of panuveitis cases remain unknown.

Table 1. General features and demography of patients based on different schemes for classification of uveitis

Characteristic	n (%)
Mean age (years)	35.75; range, 3-82
Sex	
Male	94 (40)
Female	141 (60)
Laterality	
Unilateral	85 (36.2)
Bilateral	150 (63.8)
Histologic type of inflammation	
Granulomatous	32 (13.6)
Non-granulomatous	179 (76)
Undefined	24 (10)
Infectious vs. Non-infectious	
Infectious	46 (19.57)
Non-infectious	189 (80.42)

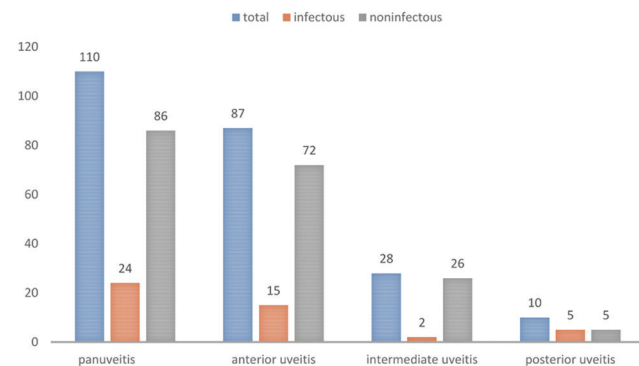


Figure 1. The prevalence of uveitis and the infectious and non-infectious cases based on anatomical location of uveitis.

DISCUSSION

In the current study, mean age of patients was 35.7 years, women were 1.5 times more likely to have uveitis than men, and the most common type of uveitis was panuveitis.

Uveitis may affect people of different ages. As studies show, young adults are more frequently affected by uveitis, which imposes enormous economic impact on individuals as well as on the society. The mean age of patients in this study is consistent with other studies.^[8,14-17] Most studies indicate that women are more likely to be affected.^[9,15,18-20]

Finding panuveitis as the most common type of uveitis is consistent with the results of studies by Merrille, Gregoire, and Al Dhahri.^[21-23] Most studies found anterior uveitis to be the most prevalent,^[10,11,20,24-26] while Wakabayashi^[27] and Al-Shakarchi^[28] reported posterior uveitis as the prevalent type.

Retrospective studies have shown that 26–40% of uveitis cases referred to educational centers are associated with an infection or a systemic disease.^[29,30] Current research and developments in different diagnostic

Table 2. Etiologies of uveitis in different uveitis types

Uveitis entity	Anterior uveitis	Intermediate uveitis	Posterior uveitis	Panuveitis	Total
Idiopathic	24 (27.5)	17 (60.7)	1 (10)	25 (22.72)	67 (28.5)
Behçet syndrome	11 (12.6)	3 (10.7)		25 (22.72)	39 (16.6)
Vogt-Koyanagi-Harada				25 (22.72)	25 (10.6)
Herpetic uveitis	12 (13.7)	1 (3.5)	1 (10)	7 (6.3)	21 (8.9)
Seronegative spondyloarthropathy	12 (13.7)	3 (10.7)		1 (0.9)	16 (6.8)
Fuchs' uveitis	15 (17.24)				15 (6.4)
Presumed tuberculosis	3 (3.4)	1 (3.5)	1 (10)	7 (6.3)	12 (5.1)
Sarcoidosis	3 (3.4)	2 (7.1)	1 (10)	3 (2.7)	9 (3.8)
Toxoplasmosis			3 (30)	5 (4.5)	8 (3.4)
Juvenile idiopathic arthritis	4 (4.6)				4 (1.7)
Multifocal choroiditis and panuveitis				4 (3.6)	4 (1.7)
UCTD	1 (1.1)			2 (1.8)	3 (1.3)
Serpiginous choroidopathy			2 (20)		2 (0.9)
HTLV-1				2 (1.8)	2 (0.9)
Cytomegalovirus				2 (1.8)	2 (0.9)
Sympathetic ophthalmia	1 (1.1)			1 (0.9)	2 (0.9)
PIC			1 (10)		1 (0.4)
Multiple sclerosis		1 (3.5)			1 (0.4)
Celiac disease	1 (1.1)				1 (0.4)
Leishmaniasis				1 (0.9)	1 (0.4)
Total	87 (37)	28 (11.9)	10 (4.25)	110 (46.8)	235 (100)

Data presented as *n* (%). HTLV-1, human T-lymphotropic virus; PIC, punctate inner choroidopathy; UCTD, undifferentiated connective tissue disease

methods have reduced the number of idiopathic cases. The patient's history, review of systems, and a conscientious physical examination are helpful in selecting diagnostic tests. Despite international efforts to unify the uveitis naming system and its diagnostic tests, ophthalmologists have yet to reach unanimity regarding this issue. For instance, there were huge inconsistencies regarding the use of diagnostic tests in a study conducted recently by uveitis specialists, which underlines the need for evidence-based guidelines.^[31]

In the current study, there were 20 different causes for uveitis. Idiopathic cases (28.5%) were the most common, followed by Behçet disease, VKH, herpetic uveitis, seronegative spondyloarthropathies, FU, and presumed TB. The most frequent causes of anterior and intermediate uveitis, as well as of panuveitis, were idiopathic, while in posterior uveitis, idiopathic causes were responsible for only 10% of the cases. The most commonly associated systemic disease was Behçet disease.

In a study conducted in Iran by Soheilian et al, 45.5% of uveitis cases were idiopathic, and Behçet disease, Fuchs' uveitis, Eales disease, and toxocariasis were the most prevalent causes of uveitis.^[8] An Iranian study by Kianersi indicated that 35.5% of uveitis cases were idiopathic, and that toxoplasma, Behçet disease, and Fuchs' uveitis were the main known causes.^[12] In another study by Kianersi et al, 43.9% of cases were idiopathic.

^[10] In a study in southern Iran, the etiologies of 61.9% of uveitis cases were identifiable; the most common causes were HLA B27-associated uveitis for anterior uveitis, Behçet disease for panuveitis, and toxoplasmosis for posterior uveitis.^[11]

In a study performed in France by Khairallah et al, Behçet syndrome, toxoplasmosis, and VKH were the most common causes of posterior uveitis and panuveitis.^[32] Behçet disease was reported to be the main known cause of uveitis in a Turkish study by Sengun et al, with 28.3% of patients affected by idiopathic uveitis.^[24] Guney's study from Turkey found that HLA B27-associated uveitis, Fuchs' uveitis, herpetic disease, and Behçet disease were the main causes of anterior uveitis.^[33] In Cimino's study, the most frequent causes were Fuchs' uveitis, herpes, toxoplasmosis, HLA B27-associated uveitis, and Behçet disease.^[25]

This study is distinguished from other studies in that more cases of panuveitis were found in comparison with anterior uveitis; this is because the study was conducted in a referral center. Panuveitis can become chronic and might entail severe complications.^[2]

In Chen's study, anterior uveitis was most common, followed by panuveitis, posterior uveitis, and intermediate uveitis. In 258 non-infectious uveitis cases, HLA-B27-associated uveitis was most commonly seen, followed by VKH disease and Posner-Schlossman

syndrome.^[34] In 2016, Yalcindag et al reported Behçet disease to be the leading cause (24.9%), followed by ankylosing spondylitis and/or HLA-B27-associated anterior uveitis (9.7%), toxoplasmosis (7.1%), Fuchs' uveitis (6.3%), and presumed herpetic anterior uveitis (6.0%).^[35]

Anterior uveitis, which is the most common type of uveitis in many studies,^[7,8,21-23] is usually treated by ophthalmologists in the office and most cases are not referred to a tertiary center. This type of uveitis can sometimes recur or extend to involve more posterior parts of the eye, warranting referral. Therefore, these cases have lower prevalence in studies performed in tertiary centers. In the current study, patients with toxoplasmosis comprised a small portion of cases in comparison to TB and VKH cases, which were more prevalent. These differences might be due to true differences in their epidemiology or, because most toxoplasmosis cases are easily diagnosed by an eye examination and treatment is started, patients are less likely to be referred to tertiary referral centers. Also, many cases are treated in the hospital emergency departments and patients are not referred to uveitis clinics. Diagnosis of patients with TB or VKH requires advanced diagnostic procedures and their treatments are more often hospital-based. Thus, these cases aggregate in tertiary referral centers.

Based on findings of the current study and other epidemiological studies of uveitis, specific uveitis workup should be tailored based on a detailed history taking and thorough ocular examination. Paraclinical tests must be limited to the most probable differential diagnoses provided by an accurate examination. Finally, ocular imaging could be valuable in narrowing the differential diagnoses, especially in posterior involvement.

The main limitations of the present study are the retrospective and hospital-based design of the study, which cannot represent the entire population. The duration of study was short; some diagnoses may change during follow-up and some cases of idiopathic uveitis may obtain a specific diagnosis.

In conclusion, in contrast to most epidemiologic studies of uveitis, the clinical patterns of uveitis are different in Khatam-Al-Anbia Eye Hospital, a tertiary referral center in northeastern Iran, as panuveitis was the most common clinical pattern in this study. The most common associated systemic disease was Behçet disease. Further prospective studies are required.

Financial Support and Sponsorship

Nil.

Conflicts of Interest

There are no conflicts of interest.

REFERENCES

- Miserochchi E, Fogliato G, Modorati G, Bandello F. Review on the worldwide epidemiology of uveitis. *Eur J Ophthalmol* 2013;23:705-717.
- Rothova A, Suttorp-van Schulten M, Treffers WF, Kijlstra A. Causes and frequency of blindness in patients with intraocular inflammatory disease. *Br J Ophthalmol* 1996;80:332-336.
- Suttorp-Schulten M, Rothova A. The possible impact of uveitis in blindness: A literature survey. *Br J Ophthalmol* 1996;80:844.
- Chang JH, Wakefield D. Uveitis: A global perspective. *Ocul Immunol Inflamm* 2002;10:263-279.
- Darrell RW, Wagener HP, Kurland LT. Epidemiology of uveitis. Incidence and prevalence in a small urban community. *Arch Ophthalmol* (Chicago, Ill: 1960) 1962;68:502-514.
- Nussenblatt RB. The natural history of uveitis. *Int Ophthalmol* 1990;14:303-308.
- Durrani OM, Meads CA, Murray PI. Uveitis: A Potentially Blinding Disease. *Ophthalmologica* 2004;218:223-236.
- Soheilian M, Heidari K, Yazdani S, Shahsavari M, Ahmadi H, Dehghan M. Patterns of uveitis in a tertiary eye care center in Iran. *Ocul Immunol Inflamm* 2004;12:297-310.
- Soheylan M, Heydari K, Khosravi-Jafari M. Epidemiology and referral pattern of uveitis in a tertiary eye care center in Tehran. *Bina J Ophthalmol* 2002;7:81-90.
- Kianersi F, Mohammadi Z, Ghanbari H, Ghoreyshi SM, Karimzadeh H, Soheilian M. Clinical patterns of uveitis in an Iranian tertiary eye-care center. *Ocul Immunol Inflamm* 2015;23:278-282.
- Rahimi M, Mirmansouri G. Patterns of uveitis at a tertiary referral center in southern Iran. *J Ophthalmic Vis Res* 2014;9:54.
- Kianersi F. Clinical Patterns of Uveitis in an Iranian Tertiary Eye Care Center. *Bina J Ophthalmol* 2005;10:147-154.
- Jabs DA, Nussenblatt RB, Rosenbaum JT. Standardization of uveitis nomenclature for reporting clinical data. Results of the First International Workshop. *Am J Ophthalmol* 2005;140:509-516.
- Päivönsalo-Hietanen T, Vaahtoranta-Lehtonen H, Tuominen J, Saari K. Uveitis survey at the University Eye Clinic in Turku. *Acta Ophthalmol* 1994;72:505-512.
- Khairallah M, Yahia SB, Ladjimi A, Messaoud R, Zaouali S, Attia S, et al. Pattern of uveitis in a referral centre in Tunisia, North Africa. *Eye* 2007;21:33.
- Kazokoglu H, Onal S, Tugal-Tutkun I, Mirza E, Akova Y, Özyazgan Y, et al. Demographic and clinical features of uveitis in tertiary centers in Turkey. *Ophthalmic Epidemiol* 2008;15:285-293.
- Yang P, Zhang Z, Zhou H, Li B, Huang X, Gao Y, et al. Clinical patterns and characteristics of uveitis in a tertiary center for uveitis in China. *Curr Eye Res* 2005;30:943-948.
- Torun N PA, Liekfeld H, Baatz C. Epidemiology and referral pattern in a tertiary eye care center. *Ophthalmol Int Med* 1999;33:28-30.
- Michelokis MECM, Karavella P, Theodossiadis G, Papadopoulos I, Papaefthymiou E, et al. Clinical patterns of uveitis in a Greek tertiary Eye care center. *Greek Ann Ophthalmol* 1998;1:43-55.
- Singh R, Gupta V, Gupta A. Pattern of uveitis in a referral eye clinic in north India. *Indian J Ophthalmol* 2004;52:121-125.
- Grégoire M-A, Kodjikian L, Varron L, Grange J-D, Broussolle C, Seve P. Characteristics of uveitis presenting for the first time in the elderly: Analysis of 91 patients in a tertiary center. *Ocul Immunol Inflamm* 2011;19:219-226.
- Merrill PT, Kim J, Cox TA, Betor CC, McCallum RM, Jaffe GJ. Uveitis in the southeastern United States. *Curr Eye Res* 1997;16:865-874.
- Al Dhahri H, Al Rubaie K, Hemachandran S, Mousa A, Gikandi PW, Al-Mezaine HS, et al. Patterns of uveitis in a university-based tertiary referral center in Riyadh, Saudi Arabia.

- Ocul Immunol Inflamm* 2015;23:311-319.
24. Şengün A, Karadağ R, Karakurt A, Sarıcaoğlu MS, Abdik O, Hasrıpi H. ORIGINAL ARTICLE Causes of Uveitis in a Referral Hospital in Ankara, Turkey. *Ocul Immunol Inflamm* 2005;13:45-50.
 25. Cimino L, Aldigeri R, Salvarani C, Zotti C, Boiardi L, Parmeggiani M, et al. The causes of uveitis in a referral centre of Northern Italy. *Int Ophthalmol* 2010;30:521-529.
 26. Barisani-Asenbauer T, Maca SM, Mejdoubi L, Emminger W, Machold K, Auer H. Uveitis- a rare disease often associated with systemic diseases and infections- a systematic review of 2619 patients. *Orphanet J Rare Dis* 2012;7:57.
 27. Wakabayashi T, Morimura Y, Miyamoto Y, Okada AA. Changing patterns of intraocular inflammatory disease in Japan. *Ocul Immunol Inflamm* 2003;11:277-286.
 28. Al-Shakarchi FI. Pattern of Uveitis at a Referral Center in Iraq. *Middle East Afr J Ophthalmol* 2014;21:291-295.
 29. Rothova A, Buitenhuis HJ, Meenken C, Brinkman CJ, Linszen A, Alberts C, et al. Uveitis and systemic disease. *Br J Ophthalmol* 1992;76:137-141.
 30. Rodriguez A CM, Pedroza-Seres M, Akova YA, Messmer EM, D'Amico DJ, et al. Patterns of uveitis in a tertiary eye care center. *Arch Ophthalmol* 1996;114:593-599.
 31. Lee CS, Randhawa S, Lee AY, Lam DL, Van Gelder RN. Patterns of Laboratory Testing Utilization Among Uveitis Specialists. *Am J Ophthalmol* 2016;170:161-167.
 32. Khairallah M BYS, Ladjimi A, Messaoud R, Zaouali S, Jenzri S, et al. Etiology of posterior uveitis and panuveitis at the Central University Hospital in Monastir. *Bull Soc Belg Ophthalmol* 2004;292:37-41.
 33. Guney E AB, Erdogan G, Unlu C, Akcali G, Bayramlar H. The etiological features of anterior uveitis in a Turkish population. *Clin Ophthalmol* 2012;6:845-849.
 34. Chen S-C, Chuang C-T, Chu M-Y, Sheu S-J. Patterns and etiologies of uveitis at a tertiary referral center in Taiwan. *Ocul Immunol Inflamm* 2017;25(sup1):S31-S38.
 35. Yalçındağ FN, Özdal PC, Özyazgan Y, Batoğlu F, Tugal-Tutkun I. Demographic and Clinical Characteristics of Uveitis in Turkey: The First National Registry Report. *Ocul Immunol Inflamm* 2016:1-10.