

# Brachial plexopathy as a complication of COVID-19

Catherine Young Han,<sup>1</sup> Andrew M Tarr,<sup>2</sup> Alexandra N Gewirtz,<sup>2</sup> Ulrike W Kaunzner,<sup>3</sup> Paula Roy-Burman,<sup>1</sup> Todd S Cutler,<sup>1</sup> Daniel JL MacGowan<sup>3</sup>

<sup>1</sup>Medicine, Weill Cornell Medical College, New York City, New York, USA

<sup>2</sup>Neurology, NewYork-Presbyterian Hospital/Weill Cornell Medical Center, New York City, New York, USA

<sup>3</sup>Neurology, Weill Cornell Medicine, New York City, New York, USA

## Correspondence to

Catherine Young Han;  
cyh4001@med.cornell.edu

Accepted 21 December 2020

## SUMMARY

COVID-19 affects a wide spectrum of organ systems. We report a 52-year-old man with hypertension and newly diagnosed diabetes mellitus who presented with hypoxic respiratory failure due to COVID-19 and developed severe brachial plexopathy. He was not treated with prone positioning respiratory therapy. Associated with the flaccid, painfully numb left upper extremity was a livedoid, purpuric rash on his left hand and forearm consistent with COVID-19-induced microangiopathy. Neuroimaging and electrophysiological data were consistent with near diffuse left brachial plexitis with selective sparing of axillary, suprascapular and pectoral fascicles. Given his microangiopathic rash, elevated D-dimers and paucifascicular plexopathy, we postulate a patchy microvascular thrombotic plexopathy. Providers should be aware of this significant and potentially under-recognised neurologic complication of COVID-19.

## BACKGROUND

The current COVID-19 pandemic has resulted in approximately 57.8 million cases and 1.3 million deaths.<sup>1</sup> Although COVID-19 was originally seen as a predominantly respiratory illness, our understanding of its impact on multiple organ systems has evolved. It is often accompanied by a variety of neurologic symptoms such as headache, anosmia, confusion and altered mental status.<sup>2</sup> Ischaemic vascular events have been frequently observed.<sup>3,4</sup> Less commonly, neurologic presentations such as Guillain-Barre syndrome, necrotising haemorrhagic encephalopathy and focal status epilepticus have also been described.<sup>5-7</sup> Here, we seek to add to our understanding of COVID-19 by presenting a case of brachial plexopathy.

## CASE PRESENTATION

A 52-year-old man with hypertension and newly diagnosed diabetes mellitus presented to our emergency department in March 2020 after 4 days of cough, shortness of breath, fatigue and myalgias. He had no sick contacts or recent travel. He was febrile (38.6°C), tachycardic, tachypneic and hypoxic (90% on room air). At the time, neurologic examination was unremarkable. Chest X-ray demonstrated extensive bilateral opacities consistent with multifocal pneumonia. Diagnosis of COVID-19 was made by detection of SARS-CoV-2 nucleic acid by reverse transcription PCR.

The patient's oxygen requirements escalated, and he was intubated for respiratory failure within 24 hours of admission. For COVID-19-directed therapy, he received 5 days of hydroxychloroquine and two doses of a study drug (sarilumab vs

placebo) on days 8 and 24. His course was complicated by transient renal failure without need for dialysis, *Enterobacter* pneumonia and *Pseudomonas* cystitis (both treated with piperacillin/tazobactam) and a hypercoagulable state with elevated D-dimers (figure 1). He was treated continuously with high-dose prophylactic enoxaparin, 30–40 mg two times per day. During intubation, he had multiple, uncomplicated central venous and arterial lines. There was no left axillary arterial catheterisation, and he never received prone positioning respiratory therapy. On day 22, he underwent percutaneous tracheostomy.

On day 24, a livedoid, retiform, purpuric rash was noted on the left hand and forearm (figure 2). Dermatology was consulted. The rash was deemed characteristic of COVID-19-induced thrombotic microvascular injury based on the department's case series.<sup>8</sup> A biopsy was therefore not performed.

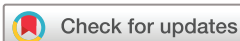Within 4 days, the patient was noted to have severe weakness of the left upper extremity and neuropathic pain in the left hand and forearm. Neurology was consulted. On examination, tone was absent in the left hand, wrist and elbow. The left biceps reflex was reduced with absence of the left brachioradialis and triceps reflexes. Pin and thermal sensation were absent over the entire left forearm and hand, with presence of tactile allodynia. Strength was reduced as follows: biceps 2/5, triceps 0/5, wrist and finger extensors 0/5, wrist and finger flexors 3/5, forearm pronation 3/5, forearm supination 2/5, superficial and deep finger flexors 3/5 and intrinsic hand muscles 3/5. The left deltoid, infraspinatus and pectoral muscles were strong at 5/5. There was no scapular winging (table 1).

## INVESTIGATIONS

Subsequent chest X-ray showed resolving multifocal pneumonia without elevation of the left hemidiaphragm.

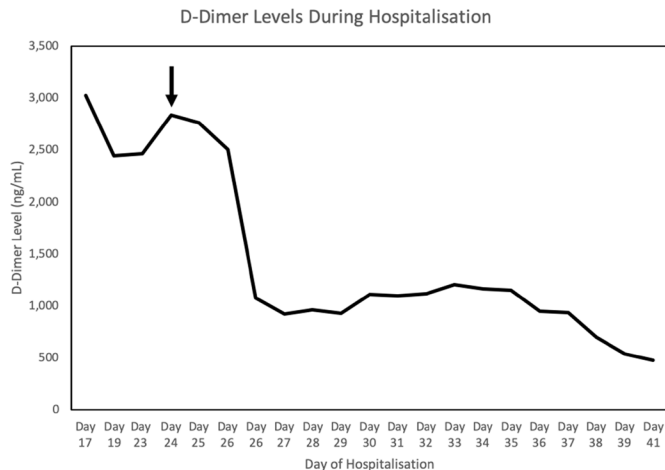
MRI of the left brachial plexus with and without intravenous contrast revealed T2 hyperintensity and thickening of the entire brachial plexus without contrast enhancement (figure 3A). There was enhancement and T2 hyperintensity of the left serratus anterior reflecting acute denervation oedema (figure 3B).

Nerve conduction studies (NCSs) and needle electromyography (EMG) were performed on day 49 (online supplemental tables 1A, 2A, 3A). NCS revealed markedly reduced left median and ulnar compound muscle action potential response amplitudes with slowing of motor conduction velocities due to axon loss. The left-sided median, ulnar, radial, musculocutaneous and medial antebrachial cutaneous responses were all absent. Needle EMG



© BMJ Publishing Group Limited 2021. No commercial re-use. See rights and permissions. Published by BMJ.

**To cite:** Han CY, Tarr AM, Gewirtz AN, et al. *BMJ Case Rep* 2021;**14**:e237459. doi:10.1136/bcr-2020-237459



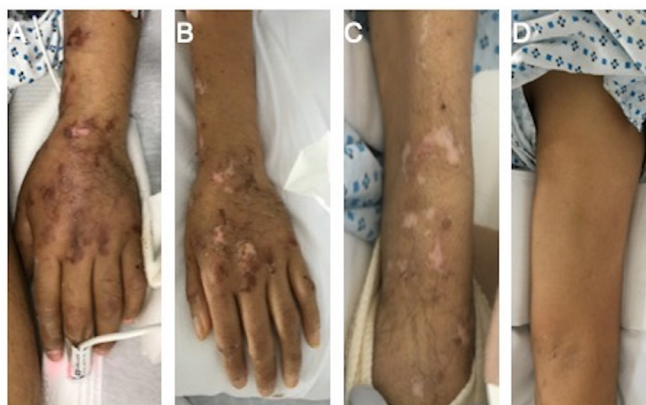
**Figure 1** D-dimer levels in the patient over the course of his hospitalisation. The black arrow indicates the first appearance of the microthrombotic rash. Reference range: 0–229 ng/mL.

of muscles in the left upper extremity showed fibrillations and positive sharp waves in all muscles except the deltoid, where examination was normal. Recruitment was absent in the left triceps, brachioradialis, extensor carpi radialis, extensor digitorum communis and extensor indicis. Recruitment was reduced in the remaining assessed muscles. A selective fascicular biopsy of the brachial plexus was felt to be against the best interests of the patient.

Laboratory studies were sent to evaluate vasculitides and coagulation disorders. Factor VIII activity was elevated (184%; reference 50%–150%) and protein S activity was mildly reduced (65%; reference 75%–125%). Work-up was otherwise unremarkable (online supplemental table 4).

**DIFFERENTIAL DIAGNOSIS**

Injury to the brachial plexus can be caused by a variety of mechanisms including trauma/compression, autoimmune reactions, direct viral infection and microvascular ischaemia.<sup>9</sup> Traumatic plexopathies are occasionally seen secondary to stretch injury, often from intraoperative positioning and typically with good recovery of symptoms.<sup>10</sup> Prone positioning, frequently employed in the management of acute respiratory distress syndrome, has



**Figure 2** Livedoid, retiform purpura of the left hand and forearm (A) on day 24, (B) on day 45 (day of initial neurological consultation) and (C) on day 50 (day following EMG/NCS). (D) The rash did not involve the left upper arm, despite weakness of these muscle groups. EMG, electromyography; NCS nerve conduction study.

**Table 1** Neurologic examination of left upper extremity—inpatient examination and postdischarge follow-up

		Inpatient examination	Postdischarge follow-up
Tone	Hand	Absent	Reduced
	Wrist	Absent	Reduced
	Elbow	Absent	Reduced
Strength (MRC scale)†	Triceps	0/5	4/5
	Biceps	2/5	*
	Supinator	2/5	4/5
	Wrist extensors	0/5	0/5
	Finger extensors	0/5	0/5
	Wrist flexors	3/5	4/5
	Finger flexors superficial	3/5	4/5
	Finger flexors deep	3/5	4/5
	Interossei	3/5	4-5
	Abductor digiti minimi	*	4-5
Abductor pollicis brevis	*	2/5	
Reflexes	Biceps	Reduced	Absent
	Brachioradialis	Absent	Absent
	Triceps	Absent	Absent
Sensation	Pin	Reduced	Reduced
	Vibration	*	Absent in the left elbow
	Proprioception	*	Absent in the left wrist

\*Not documented on examination.

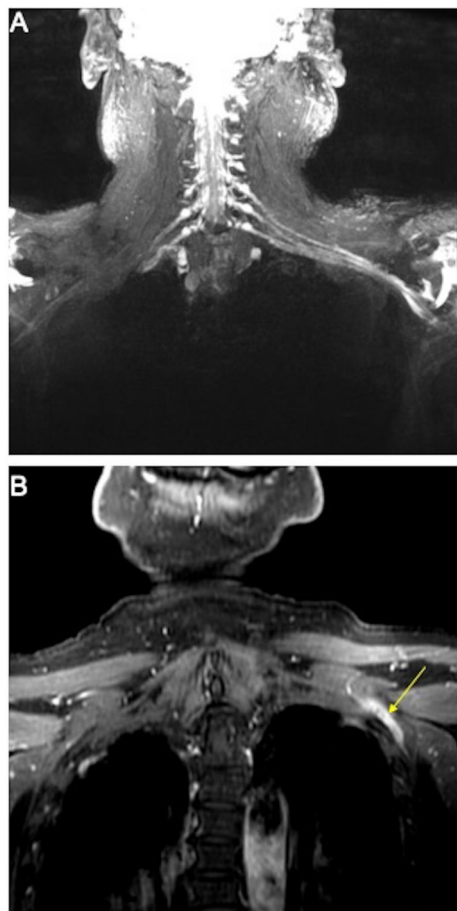
†Medical Research Council.

been reported to cause neurapraxic brachial plexopathy from pressure injury.<sup>11 12</sup> Brachial plexus injury has also been reported in conjunction with trauma to the axillary artery, including complications of axillary arterial lines (eg, local thromboses, haematomas and pseudoaneurysms).<sup>13 14</sup> In our case, traumatic and compressive aetiologies were ruled out. The patient was never prone, nor his left arm was ever hyperabducted or cannulated by an axillary line. Additionally, there was no evidence of focal trauma or compression on MRI. The severe weakness and numbness with axonometric electrodiagnostic findings eliminate a stretching neurapraxic injury.

Given his concurrent rash, vasculitis of the brachial plexus was considered. Medium and small vessel vasculitides can cause inflammation of the epineural arteries of the vasa nervorum with subsequent thrombosis and ischaemia.<sup>15–18</sup> However, most vasculitides present with mononeuritis or mononeuritis multiplex; vasculitis-associated plexopathies are rare.<sup>19</sup> In our patient, autoimmune and vasculitis labs were unremarkable. His new diagnosis of diabetes mellitus prompted consideration of diabetic radiculoplexus neuropathy. Most cases, however, progress to involve the contralateral side or are associated with lumbosacral plexus disease.<sup>20</sup>

Direct viral invasion of the plexus, as with varicella-zoster virus (VZV)-associated plexopathy, was also plausible. VZV can rarely infect the plexus with a radial nerve-predominant palsy, however the distribution of weakness and rash would be expected to colocalise.<sup>21 22</sup> In this case, weakness was found in muscle groups beyond the distribution of the rash.

Another possibility was Parsonage-Turner syndrome (or neuralgic amyotrophy) in a postviral setting. Classically, patients report



**Figure 3** MRI reveals diffuse left brachial plexitis (A: coronal T2 STIR 20 mm reformat) with denervation enhancement and oedema of the left serratus anterior (B: coronal T1 with gadolinium). STIR, short tau inversion recovery.

sudden-onset, severe but self-limited unilateral shoulder pain. Weakness, generally localised to the upper proximal limb, is noted 1–2 weeks after onset of pain. Neuralgic amyotrophy of the brachial plexus has been described in association with COVID-19, with the proposed mechanism of action being a COVID-19 immune-mediated inflammation.<sup>23</sup> However, the focal demyelination that would be seen with this process differs from the patchy pattern of axonotmesis seen in our patient with complete sparing of axillary, pectoral and suprascapular fascicles.<sup>24 25</sup>

The complete sparing of some fascicles and severe denervation of other fascicles that run through the same trunks and cords suggest a microvascular paucifascicular infarction due to thrombosis of the vasa nervorum in the setting of COVID-19-induced hypercoagulability. The pattern of brachial plexus injury with selective fascicular involvement, along with the microthrombotic rash on the ipsilateral arm, supports this mechanism of disease.

### TREATMENT

His wrist was splinted to prevent contractures. He received physical therapy, and his pain improved with gabapentin, oxycodone and acetaminophen.

### OUTCOME AND FOLLOW-UP

The patient was transferred to a rehabilitation unit on day 69 and was discharged home on day 106 of his hospitalisation. A neurological follow-up examination and EMG were conducted 3 months after discharge. His neuropathic pain had resolved.

On examination of the left upper extremity, tone was no longer absent but was reduced across the left wrist. The left triceps and forearm showed severe muscle atrophy without fasciculations. Tendon reflexes were absent in the left arm. There was reduced pin and thermal sensation in the left C5-T1 dermatomes with absent vibration to the left elbow and absent proprioception to the left wrist. Strength was reduced as follows: triceps 4/5, wrist and finger extensors 0/5, wrist and finger flexors 4/5, forearm supination 4/5 and intrinsic hand muscles 4/5 (table 1). NCSs were unchanged, but needle EMG of the left upper extremity showed complete reinnervation of the biceps, flexor carpi radialis, first dorsal interosseous, superficial and deep finger flexors, partial reinnervation of the triceps, abductor digiti minimi and abductor pollicis brevis and persisting, complete denervation of the wrist and finger extensors (online supplemental table 1B, 2B, 3B).

### DISCUSSION

To our knowledge, this is the first reported case of brachial plexopathy associated with COVID-19 in a patient never placed in the prone position. We propose that a COVID-19-induced hypercoagulable state resulted in microthrombi which occluded portions of the vasa nervorum supplying the brachial plexus, thereby causing nerve ischaemia and infarction.

COVID-19 can cause a hypercoagulable state due to activation of the coagulation cascade and complement system.<sup>8 26 27</sup> Laboratory abnormalities include elevated fibrinogen, elevated D-dimer and changes to prothrombin time (PT), activated partial thromboplastin time (aPTT), and international normalized ratio (INR).<sup>27 28</sup> Multiple reports have described the high likelihood of pulmonary embolism and deep venous thrombosis in

### Patient's perspective

I have spent a lot of time in the hospital, so I feel anxious about what comes next. I worry about my ability to return to work as I did before. But my family waits for me, and I miss them as well; I want to see them again.

Specific to my hand, I still have some swelling, pain and numbness, but I have a little more strength and range of motion than before. I feel like I have received good care here in the hospital. Though I need assistance, I am now able to walk. I hope that I get better, and that I am able to leave here soon. I hope to get back mobility in my hand, to be able to lift myself up and to be able to eat by myself.

If I were to give advice to someone in my shoes, I would advise them to have patience and to always hope for recovery. The main thing that brought me hope during my own hospital stay was God. (Translated from Spanish, interviewed before patient's discharge.)

### Learning points

- ▶ Injury to the brachial plexus can be caused by a variety of mechanisms including trauma/compression, autoimmune responses, direct viral infection or microvascular ischaemia.
- ▶ Clinicians should be aware that COVID-19-induced hypercoagulability may present with microthrombotic complications in multiple organ systems.
- ▶ Early splinting and physiotherapy should be considered in patients who show evidence of brachial plexus injury.

COVID-19, with Klok *et al* reporting a 49% incidence of large-vessel thrombotic complications in critically ill patients with COVID-19.<sup>29–31</sup> Additionally, multiple reports have described the formation of microthrombi in small vessels affecting the lungs, heart and skin.<sup>8 32–34</sup> Magro *et al* described COVID-19 patients with retiform, purpuric lesions identical to those in this case. These skin lesions, on immunohistochemical staining, showed thrombotic vasculopathy with significant deposition of C5b-9 in the microvasculature.<sup>8</sup>

In this patient, prior to the onset of his rash, D-dimers were elevated between 2400 ng/mL and 3000 ng/mL, with abnormal factor VIII and protein S levels supporting the presence of an acquired prothrombotic state during acute viral infection.<sup>35</sup> Electrophysiology showed a combination of complete or partial axonotmesis of most but not all of the motor fascicles, supporting a patchy infarction pattern of the brachial plexus. For example, though both radial and axillary nerves are branches of the posterior cord of the brachial plexus, muscles innervated by the radial nerve were affected, while those by the axillary nerve were spared. Considering the prothrombotic state, these findings support a variable microthrombosis of the vasa nervorum as has also been hypothesised by Needham *et al* in a recent case series of patients with COVID-19 and mononeuritis multiplex.<sup>36</sup>

Further investigations should examine microthrombi formation as an important mechanism by which COVID-19 affects the peripheral nervous system and also explore more effective therapy against microthrombi formation in COVID-19 infection.

**Contributors** CYH contributed to writing/manuscript preparation, writing the initial draft, making critical revisions and creating figures/tables. She aided with translation and patient communication. AMT contributed to writing/manuscript preparation, making critical revisions and creating figures/supplemental tables. He wrote portions of the paper including the summary. He was part of the neurology consult team that was involved in the patient's care. ANG contributed to writing/manuscript preparation, making critical revisions and writing portions of the paper including the differential diagnoses. She was part of the neurology consult team that was involved in the patient's care. UWK contributed to project conception, writing/manuscript preparation and critical revisions. She was part of the neurology consult team that was involved in the patient's care. PRB contributed to writing/manuscript preparation, making critical revisions and finalising manuscript content. She contributed to direct patient care as the attending physician taking care of the patient. She also obtained final patient's consent and patient's quotations. DJLM contributed to analysis and interpretation of vital data as the consulting electromyographer and also made critical revisions of the manuscript. TC contributed to project conception, as project supervisor and as the attending physician taking care of the patient when the brachial plexopathy was initially investigated. He also made contributions to writing and critical revisions. All authors gave final approval of the case report before publication.

**Funding** The authors have not declared a specific grant for this research from any funding agency in the public, commercial or not-for-profit sectors.

**Competing interests** None declared.

**Patient consent for publication** Obtained.

**Provenance and peer review** Not commissioned; externally peer reviewed.

This article is made freely available for use in accordance with BMJ's website terms and conditions for the duration of the covid-19 pandemic or until otherwise determined by BMJ. You may use, download and print the article for any lawful, non-commercial purpose (including text and data mining) provided that all copyright notices and trade marks are retained.

## REFERENCES

- Weekly epidemiological update – 24 November 2020. *World Health Organization* 2020.
- Asadi-Pooya AA, Simani L. Central nervous system manifestations of COVID-19: a systematic review. *J Neurol Sci* 2020;413:116832.
- Oxley TJ, Mocco J, Majidi S, *et al*. Large-Vessel stroke as a presenting feature of Covid-19 in the young. *N Engl J Med* 2020;382:e60.
- Merkler AE, Parikh NS, Mir S, *et al*. Risk of ischemic stroke in patients with coronavirus disease 2019 (COVID-19) vs patients with influenza. *JAMA Neurol* 2020;77:1366–72.
- Sedaghat Z, Karimi N. Guillain Barre syndrome associated with COVID-19 infection: a case report. *J Clin Neurosci* 2020;76:233–5.
- Vollono C, Rollo E, Romozzi M, *et al*. Focal status epilepticus as unique clinical feature of COVID-19: a case report. *Seizure* 2020;78:109–12.
- Poyiadji N, Shahin G, Noujaim D, *et al*. COVID-19-associated acute hemorrhagic necrotizing encephalopathy: imaging features. *Radiology* 2020;296:E119–20.
- Magro C, Mulvey JJ, Berlin D, *et al*. Complement associated microvascular injury and thrombosis in the pathogenesis of severe COVID-19 infection: a report of five cases. *Transl Res* 2020;220:1–13.
- Zakrasek EM, Karandikar NSM. Brachial plexopathy: differential diagnosis and treatment. *American Academy of Physical Medicine and Rehabilitation*.
- Ben-David B, Stahl S. Prognosis of intraoperative brachial plexus injury: a review of 22 cases. *Br J Anaesth* 1997;79:440–5.
- Goettler CE, Pryor JP, Reilly PM. Brachial plexopathy after prone positioning. *Crit Care* 2002;6:540–2.
- Diprose WK *et al*. Bilateral upper limb neuropathies following prone ventilation for COVID-19 pneumonia. *Neurology: Clinical Practice* 2020.
- Kuo F, Park J, Chow K, *et al*. Avoiding peripheral nerve injury in arterial interventions. *Diagn Interv Radiol* 2019;25:380–91.
- Graham JM, Mattox KL, Feliciano DV, *et al*. Vascular injuries of the axilla. *Ann Surg* 1982;195:232–8.
- Blaes F. Diagnosis and therapeutic options for peripheral vasculitic neuropathy. *Ther Adv Musculoskelet Dis* 2015;7:45–55.
- Naseri Alavi SA, Meshkini M, Pourlak T, *et al*. Microscopic polyangiitis complicated with bilateral brachial plexopathy: a case report and review of the literature. *Rheumatol Int* 2016;36:997–1001.
- Raz I, Leitersdorf E, Kleinman Y. Acute bilateral brachial plexus neuritis associated with hypersensitivity vasculitis. A case report and review of literature. *Klin Wochenschr* 1985;63:643–5.
- Aralasmak A, Karaali K, Cevikol C, *et al*. Mr imaging findings in brachial plexopathy with thoracic outlet syndrome. *AJNR Am J Neuroradiol* 2010;31:410–7.
- Imboden JB. Involvement of the peripheral nervous system in polyarteritis nodosa and antineutrophil cytoplasmic Antibodies-Associated vasculitis. *Rheum Dis Clin North Am* 2017;43:633–9.
- Massie R, Mauermann ML, Staff NP, *et al*. Diabetic cervical radiculoplexus neuropathy: a distinct syndrome expanding the spectrum of diabetic radiculoplexus neuropathies. *Brain* 2012;135:3074–88.
- Jeevarethinam A, Ihuoma A, Ahmad N. Herpes zoster brachial plexopathy with predominant radial nerve palsy. *Clin Med* 2009;9:500–1.
- Liu Y, Wu B-Y, Ma Z-S, *et al*. A retrospective case series of segmental zoster paresis of limbs: clinical, electrophysiological and imaging characteristics. *BMC Neurol* 2018;18:121.
- Siepmann T, Kitzler HH, Lueck C, *et al*. Neuralgic amyotrophy following infection with SARS-CoV-2. *Muscle Nerve* 2020;62: :E68–70.
- Feinberg JH, Radecki J. Parsonage-turner syndrome. *Hss J* 2010;6:199–205.
- Ortiz Torres M, Gudlavalleti A, Mesfin FB. Brachial plexitis (Parsonage Turner syndrome, brachial neuropathy, brachial radiculitis). *StatPearls* 2020.
- Huang C, Wang Y, Li X, *et al*. Clinical features of patients infected with 2019 novel coronavirus in Wuhan, China. *Lancet* 2020;395:497–506.
- Ranucci M, Ballotta A, Di Dedda U, *et al*. The procoagulant pattern of patients with COVID-19 acute respiratory distress syndrome. *J Thromb Haemost* 2020;18:1747–51.
- Thachil J, Tang N, Gando S, *et al*. ISTH interim guidance on recognition and management of coagulopathy in COVID-19. *J Thromb Haemost* 2020;18:1023–6.
- Klok FA, Kruij M, van der Meer NJM. Incidence of thrombotic complications in critically ill ICU patients with COVID-19. *Thromb Res* 2020.
- Klok FA, Kruij MJHA, van der Meer NJM, *et al*. Confirmation of the high cumulative incidence of thrombotic complications in critically ill ICU patients with COVID-19: an updated analysis. *Thromb Res* 2020;191:148–50.
- Helms J, Tacquard C, Severac F, *et al*. High risk of thrombosis in patients with severe SARS-CoV-2 infection: a multicenter prospective cohort study. *Intensive Care Med* 2020;46:1089–98.
- Luo W, Yu H. Clinical pathology of critical patient with novel coronavirus pneumonia (COVID-19). *Preprints*.
- Liu PP, Blet A, Smyth D, *et al*. The science underlying COVID-19: implications for the cardiovascular system. *Circulation* 2020;142:68–78.
- Ackermann M, Verleden SE, Kuehnel M. Pulmonary vascular Endothelialitis, thrombosis, and angiogenesis in Covid-19. *N Engl J Med* 2020.
- Goeijenbier M, van Wissen M, van de Weg C, *et al*. Review: viral infections and mechanisms of thrombosis and bleeding. *J Med Virol* 2012;84:1680–96.
- Needham E, Newcombe V, Michell A. Mononeuritis multiplex: an unexpectedly common feature of severe COVID-19. *medRxiv* 2020.

Copyright 2021 BMJ Publishing Group. All rights reserved. For permission to reuse any of this content visit <https://www.bmj.com/company/products-services/rights-and-licensing/permissions/>  
BMJ Case Report Fellows may re-use this article for personal use and teaching without any further permission.

Become a Fellow of BMJ Case Reports today and you can:

- ▶ Submit as many cases as you like
- ▶ Enjoy fast sympathetic peer review and rapid publication of accepted articles
- ▶ Access all the published articles
- ▶ Re-use any of the published material for personal use and teaching without further permission

**Customer Service**

If you have any further queries about your subscription, please contact our customer services team on +44 (0) 207111 1105 or via email at [support@bmj.com](mailto:support@bmj.com).

Visit [casereports.bmj.com](http://casereports.bmj.com) for more articles like this and to become a Fellow