

A Novel Method for Accurate Preoperative Templating for Total Hip Arthroplasty Using a Biplanar Digital Radiographic (EOS) System

Jun Huang, MD*, Ye Zhu*, Wenxia Ma, Zhigang Zhang, MD, Weidong Shi, MD, and Jun Lin, PhD

Investigation performed at the First Affiliated Hospital of Soochow University, Suzhou, People's Republic of China

Background: Accurate preoperative planning for total hip arthroplasty (THA) relies on conventional anteroposterior radiographs. The difficulty of determining the magnification factor of radiographs is a major limitation. Despite the use of markers for calibration, identifying the plane of the hip joint is a major challenge. The aim of this study was to evaluate the accuracy of a novel method for image calibration and preoperative planning in THA involving the use of a biplanar radiographic (EOS imaging) system and a self-designed coin device.

Methods: Biplanar radiographs (with the self-designed coin device) and a conventional anteroposterior radiograph (with a coin) were made for 26 patients after primary THA. The agreement between the actual and calculated diameters for each method was assessed using the concordance correlation coefficient (CCC) and Bland-Altman plots. In addition, 15 patients undergoing primary THA were prospectively enrolled to evaluate the EOS imaging-based method (EOS method), with biplanar radiographs made with use of the coin device. The accuracy of the preoperative predicted size of the implants was evaluated.

Results: Both the EOS and conventional anteroposterior radiograph-based methods were reliable in repeated measurements of the diameter of the artificial femoral head in the reproducibility study, with the average CCCs for both methods >0.990 . The agreement between the actual and EOS-based calculated diameters of the artificial femoral head was excellent, with a CCC of >0.990 , while the agreement was poor between the actual and anteroposterior radiograph-based calculated diameters, with a CCC of <0.75 . The EOS method exhibited a lower absolute difference (0.09 ± 0.07 mm) between the actual and calculated diameters compared with conventional anteroposterior radiography (1.26 ± 0.86 mm) ($p < 0.001$). EOS-based preoperative plans also exhibited excellent performance on the accuracy of the planning of the cups and stems; only 1 patient (6.7%) had a final implanted cup that differed by 1 size from the predicted size. Two patients (13.3%) had final implanted stems that differed by 1 size from the predicted size, and for 1 patient (6.7%), the stem size was off by ≥ 2 sizes.

Conclusions: We describe a novel and easy-to-use method for the accurate calibration of radiographs and preoperative planning for THA. The EOS method evaluated in this study is an alternative method for preoperative planning in clinical practice.

Total hip arthroplasty is one of the most successful orthopaedic procedures. For patients with severe hip pain and dysfunction, it can effectively relieve pain, restore function, and improve quality of life. However, an incorrect size or position of the prosthesis may cause total

hip arthroplasty failure¹⁻⁶. While the final implant size is determined at the time of surgical implantation, accurate preoperative planning can improve surgical precision, shorten operative time, and reduce the incidence of complications⁷⁻¹⁰.

*Jun Huang, MD, and Ye Zhu contributed equally to this work.

Disclosure: This study was funded by the National Natural Science Foundation of China (81871789) and the Natural Science Foundation of Jiangsu Province (BK20180052). The **Disclosure of Potential Conflicts of Interest** forms are provided with the online version of the article (<http://links.lww.com/JBJSOA/A214>).

Copyright © 2020 The Authors. Published by The Journal of Bone and Joint Surgery, Incorporated. All rights reserved. This is an open-access article distributed under the terms of the [Creative Commons Attribution-Non Commercial-No Derivatives License 4.0](https://creativecommons.org/licenses/by-nc-nd/4.0/) (CCBY-NC-ND), where it is permissible to download and share the work provided it is properly cited. The work cannot be changed in any way or used commercially without permission from the journal.

Whether using traditional analogue or digital methods, preoperative planning relies on accurately scaled radiographs. However, one of the major challenges is accurately determining the magnification factor of radiographs, which can vary among patients according to body size, mattress thickness, and the distance from the x-ray detector^{11,12}. Despite the use of external scaling markers, previous studies showed that the distribution of the average absolute difference between the actual and calculated size ranged from 0.16 to 1.40 mm^{11,13,14}. Therefore, it is of crucial importance to search for better methods to estimate the magnification factor for preoperative radiographs.

To obtain an accurately scaled radiograph, several methods have been tested. Calibration markers of known size are placed in the plane of the hip joint, typically using palpation of the greater trochanter to estimate the location of the hip-joint plane. These markers can be a sphere¹⁵, a coin¹⁴, or a ruler. To accurately calibrate the radiograph, it is of crucial importance to place the markers as close as possible to the plane of the hip joint. However, correct positioning of the calibration markers is one of the major challenges. The difficulty of identifying the correct anatomic landmarks in select patients (e.g., obese patients or patients with a deformity in the proximal part of the femur) and other factors

can decrease the accuracy of positioning the calibration markers. More importantly, a structural error in calibration will occur if the markers' position differs too much from the plane of interest¹⁶. It was previously reported that templated cup sizes differed from 48 to 62 mm according to varying differences in the position of the scaling sphere relative to the center of the greater trochanter¹⁷. The biplanar low-dose imaging system by EOS imaging, the radiation dose of which is much less than that of a computed tomography (CT) scan and conventional radiography¹⁸, can be an alternative in clinical practice. Based on the ability of the EOS imaging system to perform the simultaneous acquisition of 2 orthogonal head-to-foot radiographs, we aimed in this study to describe the validation of a method that allows correct calibration of radiographs and thus, more accurate preoperative planning for total hip arthroplasty.

Materials and Methods

Prospective Validation of the Digital Calibration Systems

Twenty-six patients who had undergone primary total hip arthroplasty performed by 2 qualified arthroplasty surgeons in a single institution were enrolled in the prospective validation study. There were 7 male and 19 female patients with a

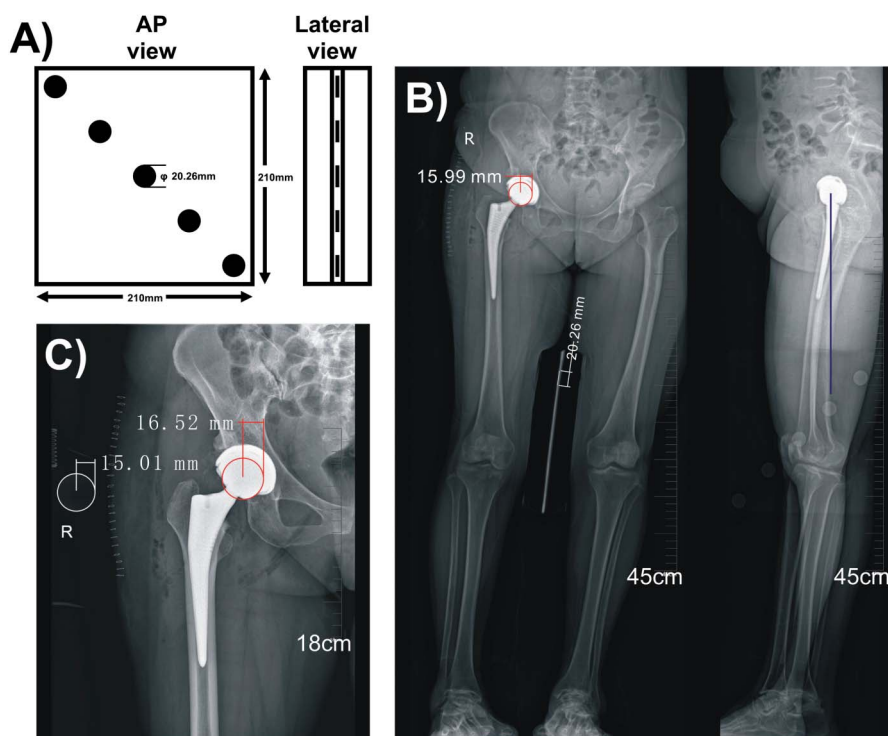


Fig. 1

Fig. 1-A Anteroposterior (AP) and lateral views of the coin device. The diameter of each of the coins was 20.26 mm. **Fig. 1-B** The representative image shows the measurement workflow based on EOS biplanar images. The coin that is closest to the anteroposterior level of the artificial femoral head (purple line), is identified on the lateral radiograph. The diameter of this coin is measured on the anteroposterior radiograph (white line). Then, the image scale is calibrated with the known coin diameter. Finally, the diameter of the artificial femoral head is measured on the anteroposterior radiograph (red circle). **Fig. 1-C** The representative image shows the measurement workflow based on a traditional anteroposterior radiograph. Patients are positioned supine on the radiographic table. A coin of known diameter ($\varphi = 30.02$ mm) is placed at the same height as the greater trochanter. The diameter of this coin is measured (white circle). Then, the image scale is calibrated with the known coin diameter. Finally, the diameter of the artificial femoral head is measured (red circle).

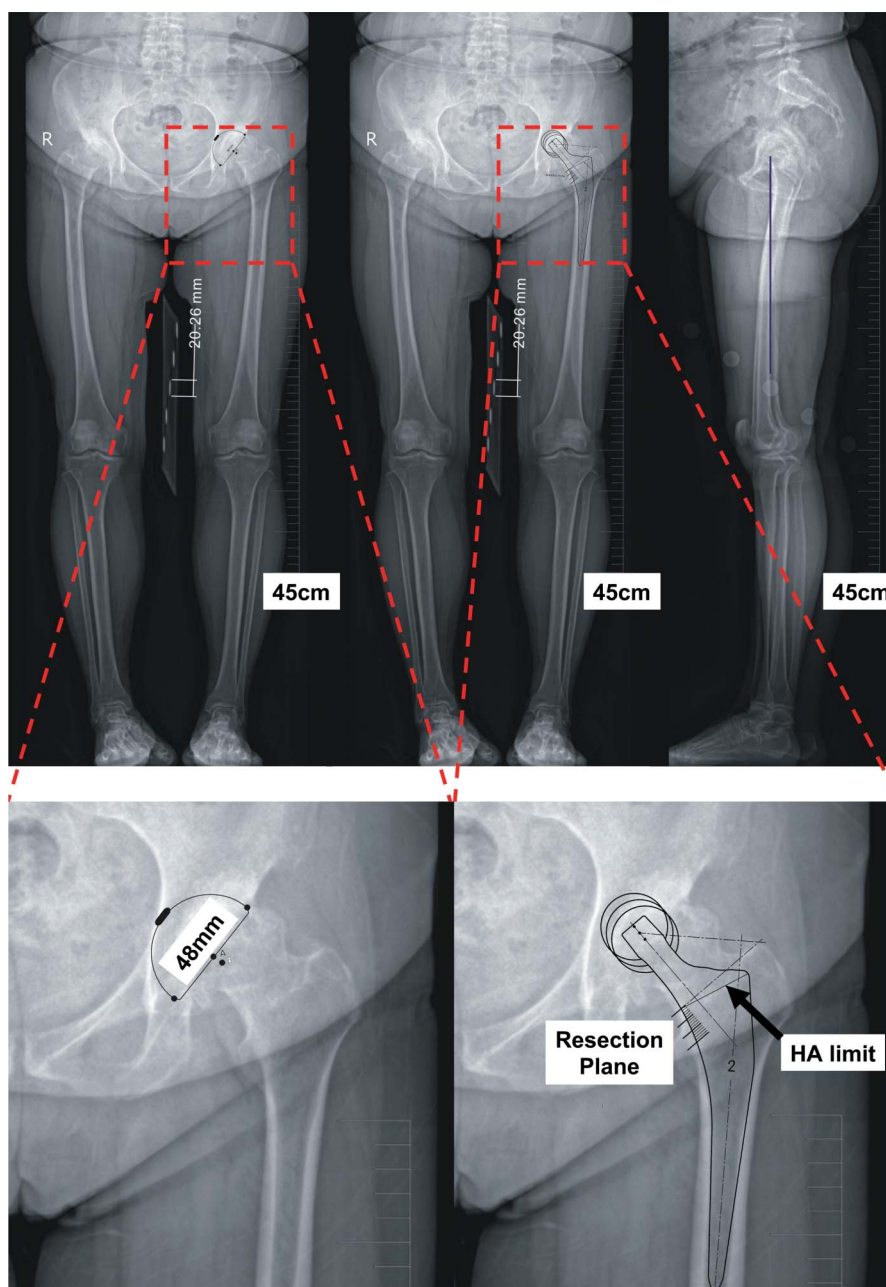


Fig. 2
The representative image shows the preoperative planning workflow based on EOS biplanar images. The coin, which is at the anteroposterior level of the artificial femoral head (purple line), is identified on the lateral radiograph. The diameter of this coin is measured on the anteroposterior radiograph (between horizontal white lines). Then, the image scale is calibrated with the known coin diameter. Finally, both the acetabular and femoral components are determined by overlaying the transparency on the EOS anteroposterior radiograph of the operative side. HA = hydroxyapatite.

median age of 63 years (range, 41 to 78 years). Both biplanar radiographs (EOS imaging) and a conventional anteroposterior radiograph were made for each patient. The image scale was calibrated with a known coin diameter. Both the EOS imaging and conventional anteroposterior radiograph-based calculations of the diameter of the artificial femoral head were evaluated for all patients. The actual diameter of the artificial femoral head as

determined intraoperatively during trial fitting was compared with the measured values using the 2 methods.

Protocol of the EOS Imaging-Based Calculation (EOS Method)

Biplanar radiographs were made according to the protocol described in a previous study¹⁸, by 1 qualified radiologist (J.H.).

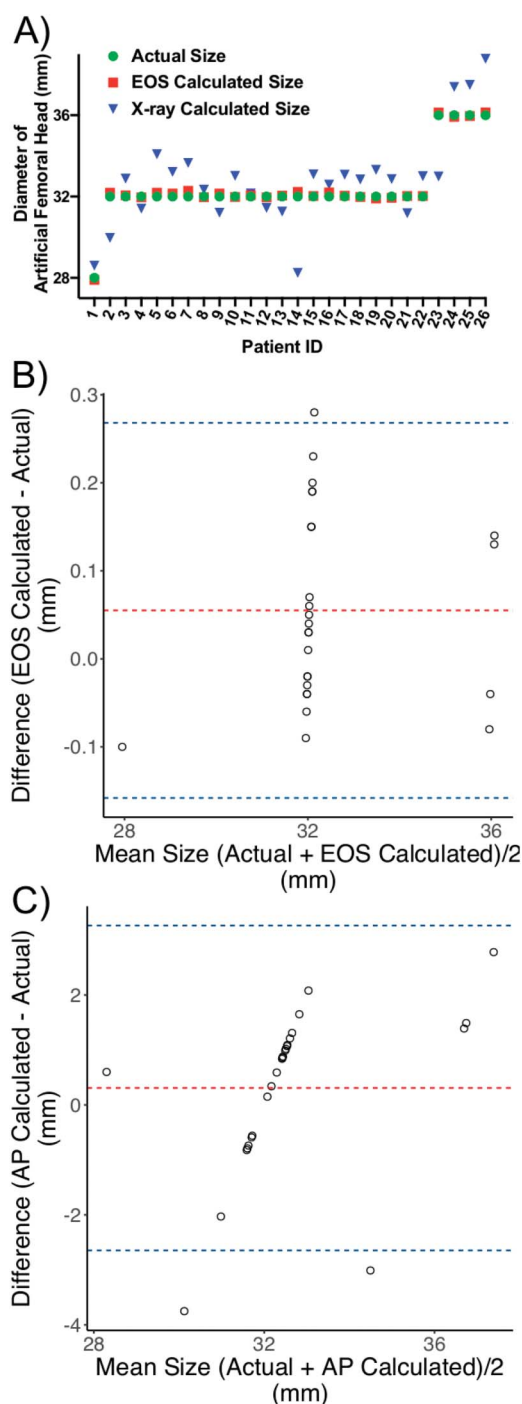


Fig. 3
The results of the first part of the study, which included 26 patients following primary THA. **Fig. 3-A** The distribution of actual, EOS and anteroposterior (AP) radiograph-based calculated diameters of the artificial femoral head. **Figs. 3-B and 3-C** Bland-Altman plots of the average versus the difference between EOS-calculated and actual diameters (EOS – Actual, **Fig. 3-B**), and the difference between AP radiograph-based calculated and actual diameters (AP – Actual, **Fig. 3-C**). The red line indicates the average difference, and the blue lines indicate ± 1.96 standard deviation from the average difference.

Each patient stood with feet parallel in the conventional double-leg-stance, full-weight-bearing position. During the radiographic procedure, it was ensured that both knees were extended maximally and the patellae were pointing forward. A device holding 5 coins of known diameter ($\phi = 20.26$ mm) was placed between the patient's thighs (Fig. 1-A).

EOS measurements were performed by 1 qualified orthopaedic surgeon (J.L.), using CorelDRAW (version 12.0; Corel). Briefly, the lateral radiograph is used for drawing the initial line. A vertical line is first drawn from the center of the artificial femoral head on the lateral radiograph to the coin identified to be closest to the anteroposterior level of the artificial femoral head (Fig. 1-B, purple line). The diameter of this coin is measured on the anteroposterior radiograph (Fig. 1-B, white line). Then, the image scale is calibrated with the known coin diameter ($\phi = 20.26$ mm). Finally, the diameter of the artificial femoral head is measured on the anteroposterior radiograph (Fig. 1-B, red circle). The examiner (J.L.), who was blinded to the actual size, completed all of the measurements within 2 weeks, and repeated all of the measurements after 2 weeks. The examiner was asked to perform measurements 3 times for each of the 26 patients.

Protocol of the Conventional Anteroposterior Radiograph-Based Calculation

A conventional anteroposterior radiograph was also made. Each patient was positioned supine on the radiographic table with both legs in maximum internal rotation. A coin of known diameter ($\phi = 30.02$ mm) was placed at the same anteroposterior level as the greater trochanter. The image was confirmed to cover both the prosthesis and the coin.

Anteroposterior radiograph-based measurements were performed by the same examiner (J.L.) using CorelDRAW (version 12.0). The first step was to measure the diameter of the coin on the radiograph (Fig. 1-C, white circle). Then, the image scale was calibrated with the known coin diameter ($\phi = 30.02$ mm). Finally, the diameter of the artificial femoral head was measured (Fig. 1-C, red circle). The examiner (J.L.) also performed 3 anteroposterior radiograph-based measurements for each of the 26 patients.

Recorder

Documentation of all measurements was completed by 1 independent recorder (W.S.).

Prospective Evaluation of EOS-Based Preoperative Planning

Fifteen nonconsecutive patients undergoing primary total hip arthroplasty in a single institution by 2 qualified arthroplasty surgeons were prospectively enrolled in this study. Inclusion criteria were primary hip osteoarthritis and unresponsiveness to nonoperative therapy. Exclusion criteria were fractures, revision arthroplasty, disturbance of the osseous anatomy of the hip joint (including slipped capital femoral epiphysis, osteonecrosis of the femoral head, developmental dysplasia of the hip, and other conditions), and patients who could not stand. There were 2

TABLE I Average Concordance Correlation Coefficients (CCCs) for Measurements of the Diameter of the Artificial Femoral Head According to Method*

	N	EOS Imaging-Based Method		AP Radiograph-Based Method	
		CCC	95% CI	CCC	95% CI
Intrater	26	0.997	0.994-0.999	0.996	0.993-0.998
Compared with the actual size	26	0.998†	0.994-0.999	0.727†	0.522-0.852

*Three repeat measurements were made per patient per method. AP = anteroposterior, and CI = confidence interval. †The EOS imaging-based method exhibited a lower absolute difference (0.09 ± 0.07 mm) between the actual and calculated diameters compared with the AP radiograph-based method (1.26 ± 0.86 mm) ($p < 0.001$).

male and 13 female patients with a median age of 61 years (range, 41 to 81 years). All of the prostheses were uncemented. All of the arthroplasty procedures were performed using a posterior approach. Prior to surgery, biplanar radiographs were also made by the same radiologist (J.H.) using the EOS imaging system. Patients stood with their feet parallel in a conventional double-leg-stance, full-weight-bearing position. During the radiographic procedure, it was ensured that both knees were extended maximally and the patellae were pointing forward. A device holding 5 coins of known diameter ($\phi = 20.26$ mm) was placed between the patient's thighs (Fig. 1-A).

The preoperative templating was conceived by the senior arthroplasty surgeon (J.L.). As described above, a vertical line is first drawn from the center of the femoral head on the lateral radiograph to the coin identified to be closest to the anteroposterior level of the artificial femoral head (Fig. 2, purple line). The diameter of this coin is measured on the anteroposterior radiograph (Fig. 2, white line). Then, the image scale is calibrated with the known coin diameter ($\phi = 20.26$ mm). Both the acetabular and femoral components were determined by manually overlaying the digital transparency on the EOS anteroposterior radiograph of the operative side. The chosen implant sizes were recorded in the patients' medical records and communicated to the surgeon the day before surgery. The surgeon determined the final component sizes intraoperatively during trial fitting and as confirmed by intraoperative radiographs. Uncemented R3 and POLARSTEM (Smith & Nephew) prostheses were used for all patients. The R3 cups were available in 15 sizes (40 to 68 mm), and the POLARSTEM stems were available in 9 sizes (01 to 8). The main outcome was the accuracy of the preoperative plan to predict the actual size of the implants as chosen by the surgeon.

Statistical Analysis

R software (version 3.5.3; The R Project for Statistical Computing) was used for the data analyses. P values of <0.05 were considered significant.

The reliability of the EOS and anteroposterior radiograph-based measurements within each method (3 repeat measurements) was assessed by the concordance correlation coefficient (CCC)¹⁹, calculated using the cccrm 1.2.1 package with R software. The agreements between actual and calculated diameters

were also assessed using the CCC. The results are presented with 95% confidence intervals (CIs).

We used Bland-Altman plots²⁰ to assess the agreement visually by way of scatterplots displaying the average of the actual and calculated diameters versus their differences. If agreement is good, then the differences should be randomly scattered around the zero-difference reference line.

Results

We first performed prospective validation of the digital templating systems. The results are presented in Appendix Table 1 and Figure 3-A. The values are given as the mean and standard deviation (SD). The intrater reliability of measurements for both the anteroposterior radiograph-based and EOS methods was excellent, with the average CCCs for both methods >0.990 (Table I). The agreement between the actual and EOS-based calculated diameters of the artificial femoral head was excellent, with a CCC of >0.990 , while the agreement was poor between the actual and anteroposterior radiograph-based calculated diameters, with a CCC of <0.75 (Table I). The EOS method exhibited a lower absolute difference (0.09 ± 0.07 mm) between the actual and calculated diameters compared with the anteroposterior radiograph-based method (1.26 ± 0.86 mm) ($p < 0.001$).

The limits of agreement for a Bland-Altman plot are defined as the mean difference ± 1.96 times the SD of the differences. If these limits do not exceed the maximum allowed difference between methods (i.e., if differences within 1.96 SD of the mean difference would not be considered large enough to be considered clinically important), the 2 methods are considered to be in agreement and may be used interchangeably²⁰. A Bland-Altman plot of the actual diameters paired with the EOS-based calculated diameters showed the differences for 25 measurement pairs (96.2%) to be within 1.96 SD of the mean difference (Fig. 3-B). The value equal to 1.96 times the SD of the signed difference between the actual and EOS-based calculated diameters was 0.21 mm, indicating a strong agreement between the actual and EOS-based calculated diameters. The Bland-Altman plot for the actual diameters paired with the anteroposterior radiograph-based calculated diameters showed the

differences for 24 measurement pairs (<95%) to be within 1.96 SD of the mean difference (Fig. 3-C). However, the value equal to 1.96 SD of the signed difference between the actual and anteroposterior radiograph-based calculated diameters was 2.95 mm, revealing a poor agreement between the actual and anteroposterior radiograph-based calculated diameters. These results agree well with the prior results of CCC analysis.

A prospective validation study was further performed to evaluate the accuracy of EOS-based preoperative planning for total hip arthroplasty. The results are presented in Figure 4 and Table II. EOS preoperative plans exhibited an excellent performance with respect to the accuracy of planning of the cups and stems, with accuracy of $\geq 80.0\%$ (14 patients with the correctly predicted size of cups and 12

	Correct	Error = 1 Size	Error = ≥ 2 Sizes
Cups	14/15 (93.3%)	1/15 (6.7%)	0/15 (0%)
Stems	12/15 (80.0%)	2/15 (13.3%)	1/15 (6.7%)

patients with the correctly predicted size of stems). If a margin of error of 1 component size was allowed, the accuracy could be $\geq 93.3\%$. For only 1 patient was there an error of ≥ 2 component sizes of the stem. No patient experienced an intraoperative complication.

Discussion

Although total hip arthroplasty is one of the most successful orthopaedic procedures, malpositioning or incorrect sizing of the prostheses can still cause severe intraoperative and postoperative complications, and can even cause total hip arthroplasty failure. Malpositioning of the prostheses can increase the risk of dislocation and loosening. Oversized prostheses can increase the risk of acetabular and femoral fracture, while undersized prostheses may cause dislocation, instability, and early-stage loosening. Therefore, aims of preoperative planning are to search for the optimal size of the prostheses, drive a higher degree of efficiency in delivering the right prosthesis to the operation room, improve surgical precision, and relatively reduce the risk of complications. However, the accuracy of preoperative planning relies on accurately scaled radiographs. Several previous studies have tried to identify the magnification factor of radiographs by placing a calibration marker in the plane of the hip joint^{14,15,17}. The main limitation of these methods is the difficulty of identifying the correct anatomic landmarks by palpation and placing the calibration markers correctly in the plane of the hip joint. Our study also revealed that the scaling of radiographs using a coin at the anteroposterior level of the greater trochanter showed a poor agreement with the actual size (CCC of <0.750).

Measurements with the novel method using the EOS imaging system and a self-designed coin device exhibited excellent agreement with the actual diameter of the artificial femoral head (CCC of >0.990). With this method, 96.2% of the EOS-based calculated diameters were located within 0.21 mm of the mean difference between the EOS-based diameter and the corresponding actual diameter (where 0.21 mm is 1.96 times the SD of the mean difference between pairs of measurements). The EOS-based preoperative plans also exhibited excellent performance with respect to the accuracy of predicting the size of both cups and stems, with prediction accuracy of $\geq 80.0\%$. In previous studies using a conventional anteroposterior radiograph, the prediction accuracy was reported to range from 16% to 69%^{16,21}.

The EOS preoperative planning method is easy to use. The coin device can be easily prepared with 5 coins and 1 plastic plate. The radiologist only needs to place the coin device between the patient's thighs; no training is necessary. With the

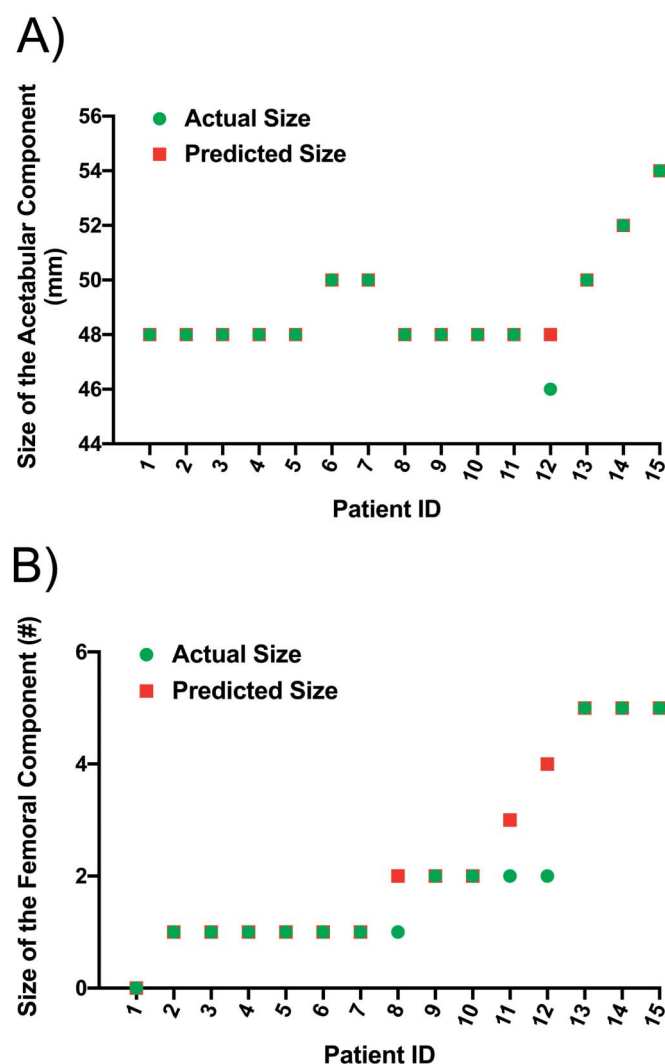



Fig. 4 The results of the second part of the study showing the difference between the preoperative predicted implant sizes and the actual sizes of the implants used. The distribution of actual and EOS-predicted sizes of the cups (Fig. 4-A) and stems (Fig. 4-B) is shown.

ability of the EOS imaging system to perform the simultaneous acquisition of 2 orthogonal head-to-foot radiographs, we found it quite easy to identify the coin closest to the plane of the hip joint by using our self-designed coin device. The calibration of the radiographs could be completed easily based on the known coin diameter using any kind of digital software. After calibration of the radiographs, an orthopaedic surgeon can easily use the digital templating system for preoperative planning without the need to purchase complex software at an additional cost.

The limitations of this study include (1) a limited sample size, (2) limited blinding (the surgeon was informed of the predicted implant sizes before surgery), and (3) a single type of hip disease. We did not evaluate Crowe Type-III or IV hip dysplasia, Legg-Calvé-Perthes disease, ankylosing spondylitis, and other hip diseases. We hope that, in follow-up studies, we can enroll a larger sample of patients, covering various types of hip diseases. Another limitation was the limited popularity of the EOS imaging system. Because of the high price (almost 10 times that of ordinary x-ray machines), currently no more than 500 units of the EOS system are deployed globally (number according to the manufacturer's data).

In summary, we described a novel and easy-to-use method for the accurate calibration of radiographs and preoperative planning for total hip arthroplasty. The EOS method evaluated in this study is an alternative method for preoperative planning in clinical routine.

Appendix

 Supporting material provided by the authors is posted with the online version of this article as a data supplement at [jbjs.org \(http://links.lww.com/JBJSOA/A215\)](http://links.lww.com/JBJSOA/A215). ■

Note: The authors thank all patients who participated in this study.

Jun Huang, MD^{1*}
Ye Zhu^{1*}
Wenxia Ma¹
Zhigang Zhang, MD¹
Weidong Shi, MD¹
Jun Lin, PhD¹

¹Departments of Orthopaedic Surgery (J.H., Z.Z., W.S., and J.L.), Clinical Pharmacology (Y.Z.), and Quality Management (W.M.), the First Affiliated Hospital of Soochow University, Suzhou, People's Republic of China

E-mail address for Z. Zhang: zhangzhigang@suda.edu.cn
E-mail address for W. Shi: shiweidongsuzhou@163.com
E-mail address for J. Lin: linjun@suda.edu.cn

ORCID iD for J. Huang: [0000-0001-7139-544X](https://orcid.org/0000-0001-7139-544X)

ORCID iD for Y. Zhu: [0000-0001-8609-0171](https://orcid.org/0000-0001-8609-0171)

ORCID iD for W. Ma: [0000-0002-0750-7440](https://orcid.org/0000-0002-0750-7440)

ORCID iD for Z. Zhang: [0000-0003-3057-4956](https://orcid.org/0000-0003-3057-4956)

ORCID iD for W. Shi: [0000-0001-7821-2888](https://orcid.org/0000-0001-7821-2888)

ORCID iD for J. Lin: [0000-0002-8094-5826](https://orcid.org/0000-0002-8094-5826)

References

- Moskal JT, Capps SG. Improving the accuracy of acetabular component orientation: avoiding malposition. *J Am Acad Orthop Surg*. 2010 May;18(5):286-96.
- Ezzet KA, McCauley JC. Use of intraoperative x-rays to optimize component position and leg length during total hip arthroplasty. *J Arthroplasty*. 2014 Mar;29(3):580-5. Epub 2013 Sep 26.
- Murphy WS, Yun HH, Hayden B, Kowal JH, Murphy SB. The safe zone range for cup anteversion is narrower than for inclination in THA. *Clin Orthop Relat Res*. 2018 Feb;476(2):325-35.
- Aldinger PR, Jung AW, Pritsch M, Breusch S, Thomsen M, Ewerbeck V, Parsch D. Uncemented grit-blasted straight tapered titanium stems in patients younger than fifty-five years of age. Fifteen to twenty-year results. *J Bone Joint Surg Am*. 2009 Jun;91(6):1432-9.
- Schwartz JT Jr, Mayer JG, Engh CA. Femoral fracture during non-cemented total hip arthroplasty. *J Bone Joint Surg Am*. 1989 Sep;71(8):1135-42.
- O'Sullivan M, Tai CC, Richards S, Skyrme AD, Walter WL, Walter WK. Iliopsoas tendonitis a complication after total hip arthroplasty. *J Arthroplasty*. 2007 Feb;22(2):166-70.
- The B, Verdonschot N, van Horn JR, van Ooijen PM, Diercks RL. Digital versus analogue preoperative planning of total hip arthroplasties: a randomized clinical trial of 210 total hip arthroplasties. *J Arthroplasty*. 2007 Sep;22(6):866-70. Epub 2007 Mar 28.
- Lakstein D, Tan Z, Oren N, Mäkinen TJ, Gross AE, Safir O. Preoperative planning of total hip arthroplasty on dysplastic acetabuli. *Hip Int*. 2017 Feb 21;27(1):55-9. Epub 2016 Oct 24.
- Shi XT, Li CF, Cheng CM, Feng CY, Li SX, Liu JG. Preoperative planning for total hip arthroplasty for neglected developmental dysplasia of the hip. *Orthop Surg*. 2019 Jun;11(3):348-55. Epub 2019 Jun 13.
- Colombi A, Schena D, Castelli CC. Total hip arthroplasty planning. *EFORT Open Rev*. 2019 Nov 1;4(11):626-32.
- Brew CJ, Simpson PM, Whitehouse SL, Donnelly W, Crawford RW, Hubble MJW. Scaling digital radiographs for templating in total hip arthroplasty using conventional acetate templates independent of calibration markers. *J Arthroplasty*. 2012 Apr;27(4):643-7. Epub 2011 Oct 5.
- Knight JL, Atwater RD. Preoperative planning for total hip arthroplasty. Quantitating its utility and precision. *J Arthroplasty*. 1992;7(Suppl):403-9.
- Heep H, Xu J, Löchteken C, Wedemeyer C. A simple and convenient method guide to determine the magnification of digital x-rays for preoperative planning in total hip arthroplasty. *Orthop Rev (Pavia)*. 2012 Jan 2;4(1):e12. Epub 2012 Mar 2.
- Wimsey S, Pickard R, Shaw G. Accurate scaling of digital radiographs of the pelvis. A prospective trial of two methods. *J Bone Joint Surg Br*. 2006 Nov;88(11):1508-12.
- Boese CK, Lechler P, Rose L, Dargel J, Oppermann J, Eysel P, Geiges H, Bredow J. Calibration markers for digital templating in total hip arthroplasty. *PLoS One*. 2015 Jul 13;10(7):e0128529.
- The B, Diercks RL, van Ooijen PM, van Horn JR. Comparison of analog and digital preoperative planning in total hip and knee arthroplasties. A prospective study of 173 hips and 65 total knees. *Acta Orthop*. 2005 Feb;76(1):78-84.
- Ramme AJ, Fisher ND, Egol J, Chang G, Vigdorich JM. Scaling marker position determines the accuracy of digital templating for total hip arthroplasty. *HSS J*. 2018 Feb;14(1):55-9. Epub 2017 Sep 12.
- Huang J, Tian F, Zhang Z, Shi W, Lin J, Chen L, Yang H. Reliability and concurrent validity of angle measurements in lower limb: EOS 3D goniometer versus 2D manual goniometer. *J Orthop Translat*. 2020 Sep;24:96-102. Epub 2020 May 20.
- Lin LI. A concordance correlation coefficient to evaluate reproducibility. *Biometrics*. 1989 Mar;45(1):255-68.
- Bland JM, Altman DG. Statistical methods for assessing agreement between two methods of clinical measurement. *Lancet*. 1986 Feb 8;1(8476):307-10.
- González Della Valle A, Comba F, Taveras N, Salvati EA. The utility and precision of analogue and digital preoperative planning for total hip arthroplasty. *Int Orthop*. 2008 Jun;32(3):289-94. Epub 2007 Apr 3.