








# Comparison of the accuracy of the cannulated pedicle screw and the classical pedicle screw in the treatment of Scheuermann's kyphosis: A retrospective study

Sinan Yılar, MD<sup>1</sup> , Mete Zeynal, MD<sup>2</sup> , Serdar Toy, MD<sup>3</sup> , Mehmet Köse, MD<sup>1</sup> , Ahmet Köse, MD<sup>4</sup> 

<sup>1</sup>Department of Orthopedics and Traumatology, Medical Faculty of Atatürk University, Erzurum, Turkey

<sup>2</sup>Department of Neurosurgery, Medical Faculty of Atatürk University, Erzurum, Turkey

<sup>3</sup>Department of Orthopedics and Traumatology, Ağrı State Hospital, Ağrı, Turkey

<sup>4</sup>Department of Orthopedics and Traumatology, Health Sciences University, Regional Training and Research Hospital, Erzurum, Turkey

Scheuermann's kyphosis (SK) is a spinal deformity characterized by anterior angulation of more than 5 degrees in three successive vertebra, stenosis in the disc interval, irregularity, and Schmorl nodes in lateral radiography (Figure 1c, 2c). The incidence of this disease, which was first designated by Scheuermann<sup>[1]</sup> in 1921, varies between 4 to 8%.<sup>[2]</sup>

As the pedicles are usually sclerotic and rotated or too narrow in adolescent spinal deformities, it is considerably challenging to place pedicle screws in these patients.<sup>[3,4]</sup> For this reason, methods that facilitate screw placement were developed to reduce complications that might develop following potentially incorrect screw placement. Cannulated pedicle screws (CPSs) are increasingly preferred by many spinal surgeons to increase the accuracy of the screws.<sup>[5,6]</sup>

Cannulated pedicle screws had been previously used in adolescent idiopathic scoliosis (AIS) patients, and their effectiveness was proven. Although CPS

## ABSTRACT

**Objectives:** This study aims to investigate if use of cannulated pedicle screw (CPS) in the dysplastic pedicles in Scheuermann's kyphosis (SK) increases the accuracy rate of the screw and reduces screw-related complications.

**Patients and methods:** This retrospective study included 21 patients (11 males, 10 females; mean age 19.1 years; range, 13 to 22 years) (550 screws) who received correction with pedicle screws due to SK deformity between May 2015 and January 2019. Between 2017 and 2018, classical pedicle screws were used in addition to CPSs in the upper thoracic region (T2, T3, T4) and thin pedicles (group 1). However, during the years 2015 to 2016, only classical pedicle screws were used for the patients who underwent posterior instrumentation for SK (group 2). Computed tomography scanning was used to investigate the accuracy of the screws.

**Results:** There were 12 patients (316 screws) in group 1 and nine patients (234 screws) in group 2. Seventy-four (13.4%) of all screws were inserted incorrectly. Incorrect screw rate in group 1 was significantly lower than group 2; 21 (6.6%) and 53 (22.6%), respectively ( $p < 0.001$ ). There were no complications related to the use of CPSs after a mean follow-up of two-and-a-half years.

**Conclusion:** The use of CPS in the surgical treatment of SK does not increase the complication rate; instead it increases the accuracy of the screw. For this reason, we believe that CPS may be an effective and reliable option in the treatment of SK.

**Keywords:** Adolescence, adolescent kyphosis, pedicle screws, Scheuermann's kyphosis, scoliosis.

Received: January 06, 2020

Accepted: March 30, 2020

Published online: April 23, 2020

**Correspondence:** Serdar Toy, MD. Ağrı Devlet Hastanesi Ortopedi ve Travmatoloji Kliniği, 04200 Ağrı, Türkiye.

E-mail: serdartyoy737@gmail.com

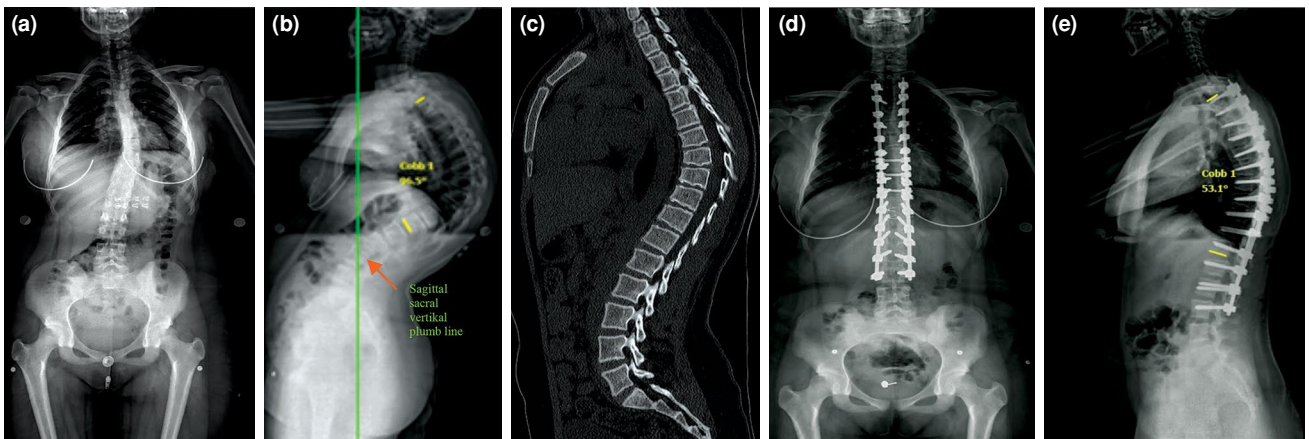
Doi: 10.5606/ehc.2020.73017

**Citation:** Yılar S, Zeynal M, Toy S, Köse M, Köse A. Comparison of the accuracy of the cannulated pedicle screw and the classical pedicle screw in the treatment of Scheuermann's kyphosis: A retrospective study. Jt Dis Relat Surg 2020;31(2):201-208.

©2020 All right reserved by the Turkish Joint Diseases Foundation

This is an open access article under the terms of the Creative Commons Attribution-NonCommercial License, which permits use, distribution and reproduction in any medium, provided the original work is properly cited and is not used for commercial purposes (<http://creativecommons.org/licenses/by-nc/4.0/>).

is frequently preferred in SK and we opine that it reduces the rate of screws implanted incorrectly, we could not find any study about this subject in the literature. Furthermore, we could not find any study clarifying the accuracy of the screw in SK. Therefore, our study is probably the first investigation that searches the accuracy of CPS in SK.<sup>[7]</sup> Thus, in this study, we aimed to investigate if use of CPS in the dysplastic pedicles in SK increases



**FIGURE 1.** (a, b) A 15-year-old female patient had preoperative 96-degree curvature. (c) Radiologic signs of Scheuermann's kyphosis were more clearly seen by tomography. (d, e) Classical pedicle screws were implanted to all vertebra and seen on postoperative anteroposterior and lateral radiographs.

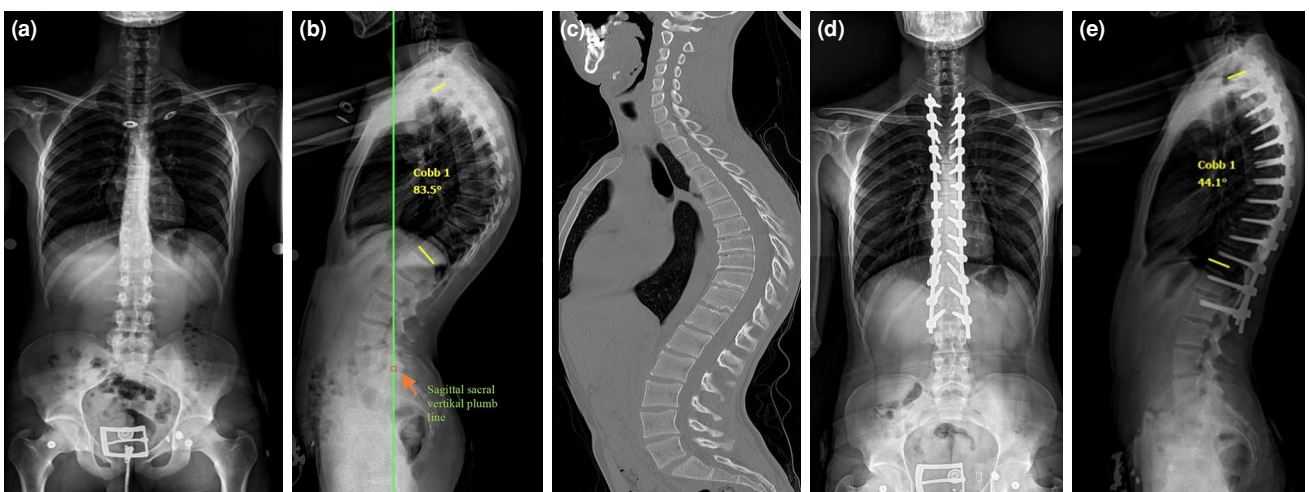
the accuracy rate of the screw and reduces screw-related complications.

## PATIENTS AND METHODS

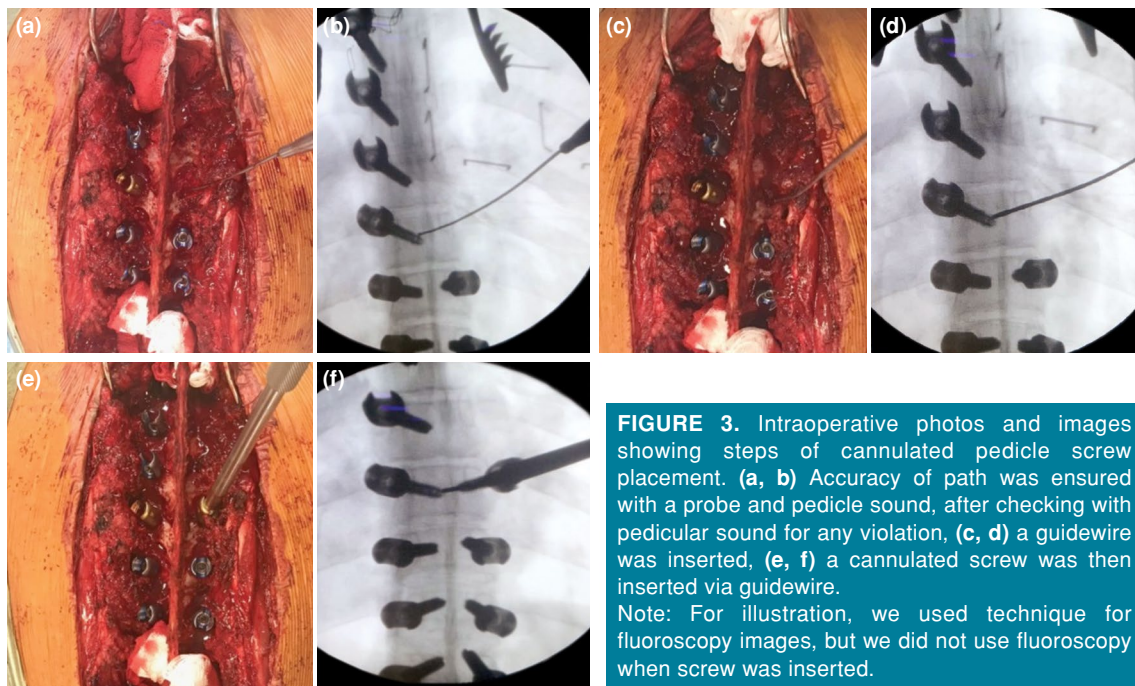
This retrospective study was conducted at Atatürk University Research Hospital. The study included 21 patients (11 males, 10 females; mean age 19.1 years; range, 13 to 22 years) (550 screws) who received correction with pedicle screws due to SK deformity between May 2015 and January 2019. Patients who underwent posterior instrumentation due to SK, who had good-quality postoperative computed tomography scans, and at least one-year of follow-up were included. Care was taken to establish that

all patients were diagnosed with SK radiologically. Patients who were operated due to positional and congenital kyphosis were excluded. The study protocol was approved by the Atatürk University Faculty of Medicine Ethics Committee. A written informed consent was obtained from each patient. The study was conducted in accordance with the principles of the Declaration of Helsinki.

Surgical intervention of all patients was performed by the author, who had more than nine years of experience in spinal deformities. Only a polyaxial screw was used as the instrumentation tool in all patients, and screws were tried to be implanted to all segments bilaterally. The proximal fusion level was



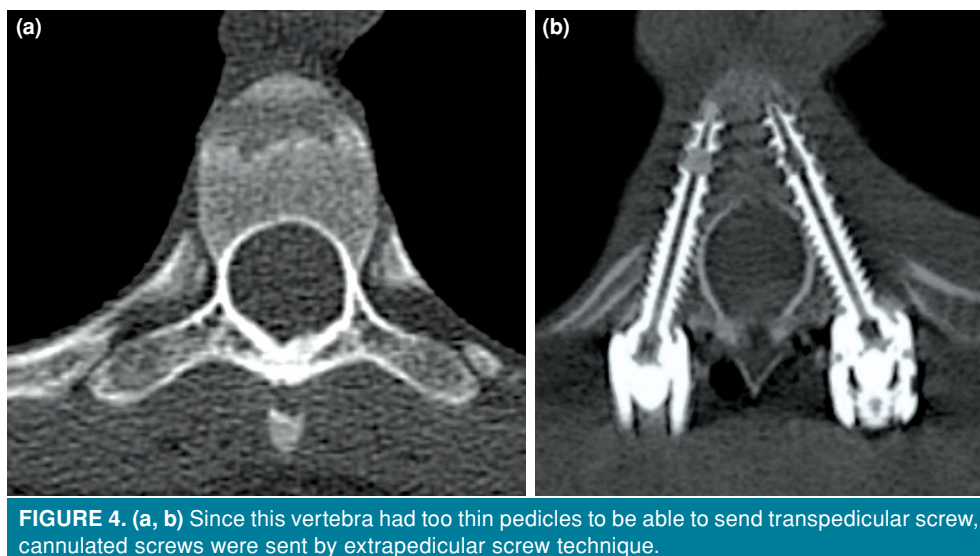
**FIGURE 2.** (a, b) A 17-year-old male patient with 84-degree preoperative kyphosis angle. (c) Irregularities in disc space, loss of height in vertebral corpus, wedging, and angulation of more than five degrees in three consecutive vertebra are more clearly seen on tomography. (d, e) Postoperative anteroposterior and lateral radiographs of patient in whom we used cannulated screws in dysplastic pedicles.



determined as the second or third thoracic vertebra in all patients, and fixation was attempted at that level. Distally, an attempt was made to settle where it would bisect the sagittal sacral vertical plumb line or nearly bisect the vertebra that was anticipated to be the distal instrumented vertebra. Between 2017 and 2018, classical pedicle screws were used in addition to CPSs in the upper thoracic region (T2, T3, T4) and thin pedicles (group 1). However, during the years of 2015 and 2016, only classical pedicle screws were used for the patients who underwent posterior

instrumentation for SK (group 2) (Figure 1). Also, considering the incorrectly sent screws during fluoroscopic control, those screws were removed and replaced with the CPSs (group 1) (Figure 2).

While implanting the transpedicular screw, a path of 15-20 mm was opened with a pedicle finder after the insertion site had been opened. Later, the route was expanded with a tapper, and an appropriate-length screw was placed. The screw thickness was 5 or 6 mm (Figure 3). While implanting screws to the dysplastic and thin pedicles, the lateral wall of the vertebra was



found with a pedicle finder, and an insertion path was formed after the insertion site was opened. The guidewire of CPS was inserted into the paved route. The screw was implanted without a tapper through the guidewire (Figure 4). When we concluded that the screw found its path, the guidewire was removed to avoid visceral organ injury. The thicknesses of the CPS were 5.5 or 6.5 mm (Figure 4).

Preoperatively, all patients underwent ambulatory anteroposterior and lateral X-ray and computed tomography (CT) investigations of the thoracic vertebra. Postoperatively, early period X-ray, final control X-ray, and CT investigation at postoperative day one were performed for all patients. In this study, the degree of malposition in the screws was determined using the Rao's classification.<sup>[8]</sup> According to this classification, screw placement was graded in the CT scans as follows: grade 0: no pedicle perforation, grade I: only the threads outside the pedicle (less than 2 mm), grade II: core screw diameter outside the pedicle (2-4 mm), and grade III: screw entirely outside the pedicle. The distance between the medial border of the malpositioned screw and the medial wall of the vertebra was measured (Figure 5).

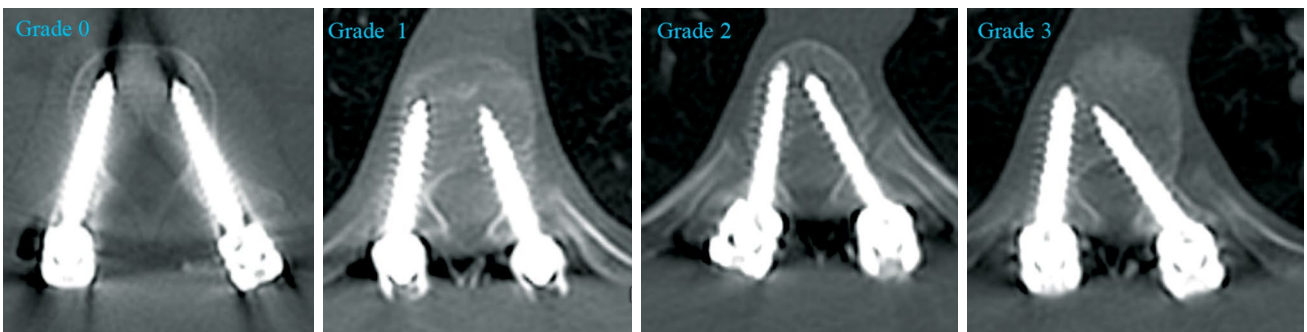
The distance between the lateral edge of the lateral malpositioned screw and the lateral wall of the corpus was measured as well (Figure 6).

Total perforation rates, medial perforation rates, lateral perforation rates, and perforation grades of the two groups were compared. Furthermore, the perforation rates of each vertebral segment were analyzed separately.

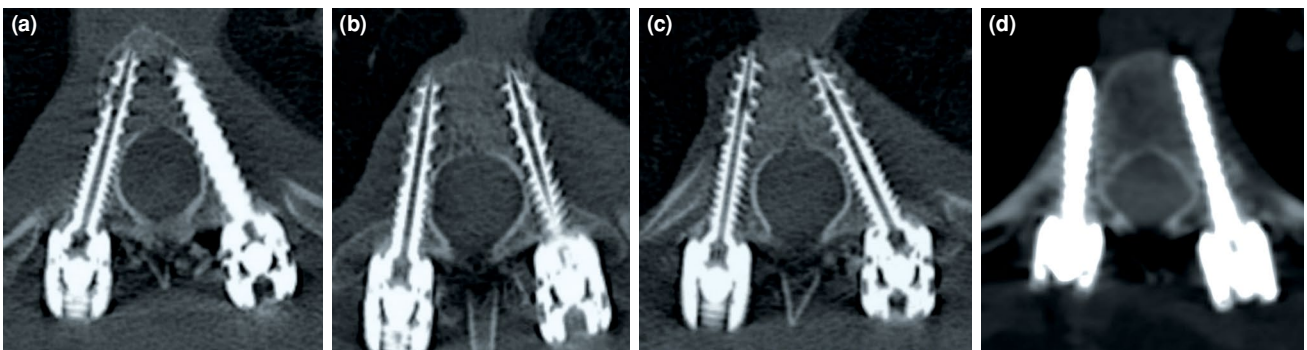
Intraoperatively, all patients were monitored using somatosensory evoked potentials and neurogenic motor evoked potentials by experts of neuromonitoring to improve screw placement accuracy and avoid complications associated with screw misplacement.

#### Statistical analysis

The IBM SPSS version 20.0 software (IBM Corp., Armonk, NY, USA) was used for statistical analysis. Data were presented as mean, median, minimum, maximum, standard deviation, percentage, and proportions. The normal distribution of the numerical variables was checked with the Shapiro-Wilk test. Independent samples t-test was used in the comparison of two independent groups with normal distribution;



**FIGURE 5.** Grading of Rao et al.<sup>[8]</sup> for medial perforations.



**FIGURE 6.** (a) At ideal position, right cannulated, left classic pedicle screw, (b) bilateral grade 1 lateral perforation, (c) right grade 2 perforation, (d) right grade 3 perforation.

otherwise, the Mann-Whitney U test was used. The Pearson chi-square test (or Fisher exact test) was used to compare categorical variables between groups. A *p* value of less than 0.05 was regarded as statistically significant.

## RESULTS

Fifty-three patients who received correction with pedicle screws due to kyphosis deformity between the years of 2015 and 2019 were evaluated. Of these patients, seven with corpectomy, nine with positional kyphosis, eight missing postoperative good-quality CT, and eight with less than one year of follow-up were excluded. The results of the remaining 21 patients (550 screws) were analyzed (Table I).

There were 12 patients (316 screws) in group 1 and nine patients (234 screws) in group 2. There were no differences regarding the preoperative kyphosis angles (81.5 vs. 82.3) ( $p=0.63$ ), scoliosis angles (5.87-5.35) ( $p=0.74$ ), and the mean ages (19.5-18.8) ( $p=0.54$ ) between the groups. A total of 74 screws (13.4%) were sent incorrectly. The incorrect screw rate in group 1 was significantly lower than group 2 ( $n=21$ , 6.6% vs.  $n=53$ , 22.6%, respectively) ( $p<0.001$ ). The majority of the incorrectly implanted screws were used for the lateral ( $n=60$ , 10.9%). A comparison of lateral perforation rates showed that perforations in group 1 were significantly lower than in group 2 ( $n=14$ , 4.4% vs.  $n=46$ , 19.7%, respectively) ( $p<0.001$ ). There was no significant difference between the two groups concerning medial perforation (group 1:  $n=7$ , 2.2% vs. group 2:  $n=7$ , 3.0%) (Table II).

When the perforation degrees were compared, grade I perforation was less in group 1 (group 1:  $n=8$ , 2.5% vs. group 2:  $n=17$ , 7.3%). However, there

was no significant difference between two groups regarding grade II perforation (group 1:  $n=10$ , 3.2% vs. group 2:  $n=14$ , 6.0%); grade III perforation, which is accepted as a critical perforation, was less in group 1 ( $n=3$ , 0.9%) compared to group 2 ( $n=22$ , 9.4%) (Table II).

The highest perforation was in the T2 vertebra. Besides, there were significantly fewer perforations in the CPS group as proceeded towards the proximal vertebra, whereas there was no significant difference in T8, which was usually the apex of the curvature, as well as its distal side (Table III).

No complications were seen at the end of the 30-month follow-up period in both groups, except for superficial wound infection in the early postoperative period and a fracture in the screw of the third lumbar vertebra after falling in group 2. The patient had no clinical symptoms due to the fall. No complication arising from the screws was encountered in group 1.

## DISCUSSION

Although the anterior approach was routinely applied in SK before the pedicle screws, currently, with the demonstration of the strength and reliability of the pedicle screws in posterior osteotomies, the treatment of SK is mostly performed via the posterior approach.<sup>[9,10]</sup> To avoid the potential catastrophic complications in SK as well as other spinal deformities, all surgeons try to place the pedicle screws into the safest area possible. Diverse methods were developed for this. Among the most-known ones of these methods, intraoperative Iso-C 3-dimensional navigation and CT navigation have been demonstrated to decrease perforation rates.<sup>[11,12]</sup> However, these systems increase the duration of

**TABLE I**  
Demographic data of study groups 1 and 2

	Total		Group 1		Group 2		<i>p</i>
	<i>n</i>	%	<i>n</i>	%	<i>n</i>	%	
Total	21		12		9		
Gender							
Male	11		5		6		
Female	10		7		3		
Age		19.1		19.5		18.8	0.54
Preoperative kyphosis angle (T2-T12)		82.2		81.5		82.3	0.63
Preoperative scoliosis angle		5.64		5.87		5.35	0.74
Postoperative kyphosis angle (T2-T12)		46.6		45.2		46.5	0.49
Total screws	550		316		234		
Cannulated screws	76		76		0		

**TABLE II**  
Comparison of pedicle perforation between groups 1 and 2

	Total		Group 1		Group 2		<i>p</i>
	n	%	n	%	n	%	
Total perforations	74	13.5	21	6.6	53	22.6	<0.001
Grade 1	25	4.5	8	2.5	17	7.3	0.08
Grade 2	24	4.4	10	3.2	14	6.0	0.11
Grade 3	25	4.5	3	0.9	22	9.4	<0.001
Medial perforation	14	2.5	7	2.2	7	3.0	0.56
Lateral perforation	60	10.9	14	4.4	46	19.7	<0.001

surgery and are unavailable in most medical centers. Also, studies showed that even though they are superior to the freehand technique, these methods are not perfect; screws might be used incorrectly even with these systems.

Although the reliability of the cannulated screws was proven in AIS patients, we could not find any study in which the cannulated screws were used in SK. To avoid postjunctional kyphosis that might develop postoperatively, as many surgeons do, we tried not to fully open the facet of the last vertebra to which a screw is sent in the proximal side. Soft tissues around the area to which a screw will be inserted make it considerably challenging to insert screws.

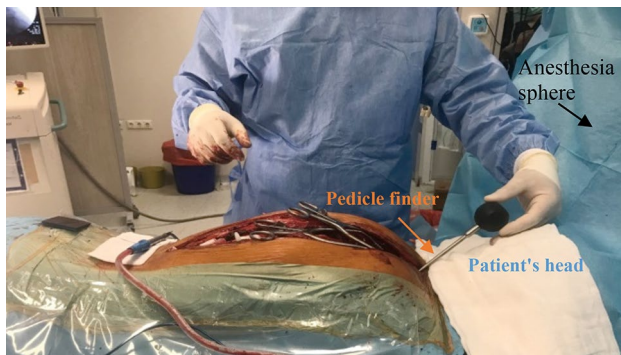
Furthermore, the anesthesia sphere and the patient's head are other factors, which make it challenging to insert screws in the proximal area (Figure 7).

Due to the reasons mentioned above, we decided to use CPSs to place the screws more safely in SK patients. Cannulated pedicle screws provide the opportunity to control the screw accuracy as well as prevent the screw from deviating from its direction through the guidewire. However, it controls the screw accuracy only in the lateral plane. In other words, it is not possible to control the precision in the medial plane. Compatible with this, there was no significant difference between the two groups concerning medial perforation; the lateral perforation

**TABLE III**  
Comparison of perforation between groups 1 and 2 according to vertebral level

Level	Overall			Group 1			Group 2			<i>p</i>
	Total screws		Perforations	Total screws		Perforations	Total screws		Perforations	
	n	%		n	%		n	%		
T2	38	36.8	14	24	4	16.7	14	10	71.4	<0.001
T3	42	23.8	10	24	5	20.8	18	5	27.7	0.87
T4	41	17.0	7	23	1	4.3	18	6	33.3	<0.04
T5	41	14.6	6	24	0	0	17	6	35.2	0.003
T6	41	21.9	9	24	3	12.5	17	6	35.2	0.17
T7	42	11.9	5	24	0	0	18	5	27.7	0.01
T8	42	9.5	4	24	0	0	18	4	22.2	0.02
T9	42	11.9	5	24	1	4.6	18	4	22.2	0.14
T10	42	4.7	2	24	1	4.6	18	1	5.5	0.67
T11	42	7.1	3	24	1	4.6	18	2	11.1	0.56
T12	42	11.9	5	24	3	12.5	18	2	11.1	0.63
L1	41	7.3	3	23	1	4.3	18	2	11.1	0.57
L2	40	2.5	1	24	1	4.6	16	0	0	0.60
L3	10	0	0	6	0	0	4	0	0	

T: Thoracic vertebra; L: Lumbar vertebra.



**FIGURE 7.** Patient's head and anesthetic cover make it difficult to screw the most proximal vertebra of patient with Scheuermann's kyphosis. Upper left screws are challenging to place, particularly for surgeon who sends screw with his right hand.

rate was significantly less in group 1. There may be several reasons for the higher lateral perforation rate in the group with classical pedicle screws. The screw may easily direct to the lateral area due to the horizontal shape of the vertebra. Besides, since the vertebra becomes more concave in the upper thoracic region, misplacements may occur even though the path of the screw is prepared by tapping when the extrapedicular screw is sent.<sup>[4,6]</sup>

Moreover, as the screw heads are much wider than the screw, the transverse process may turn the direction of the screw towards the lateral area when the screw heads contact with the transverse processes while the screw is advanced. However, in the presence of a guidewire, this wire will assure the direction of the screw. As in many other studies, our lateral perforation rate was higher than the medial perforation.<sup>[13]</sup> We consider that the reason for this arises from the medial wall's being harder than the lateral ones. Furthermore, many spinal surgeons orient towards the lateral walls due to the fear of spinal injury. Indeed, our lateral perforation rate should be lower because we could control the lateral perforation in group 1. However, in deformities in which the screw placement was already difficult, we did not replace the screws for which the screw position was not excellent but acceptable in the fluoroscopy. Also, we did not replace the screws in cases of lateral perforation with a good holding power of the screw (Figure 6b, c).

Although grade I and grade II perforations are generally acceptable in spinal deformities, grade III perforations have the risk of visceral organ and spinal cord damage.<sup>[8,14]</sup> We also saw that the use of CPS reduced the grade III perforation rate to a significant degree.

Although this is the first study in which the screw accuracy is investigated in SK patients, it was a retrospective study. Hence, we could not examine the effects of the cannulated screws on radiation exposure, the operation period, and the bleeding amount. Furthermore, the screws were used at different times, even though all screws were placed by the same experienced spinal surgeon. We think that prospective studies with more extended follow-up periods and more patients will clarify these discussions.

In conclusion, the use of CPS in SK reduces the rate of incorrectly sent screws and the critical perforation rates. The use of CPS in SK substantially reduces the lateral perforation rate but does not affect the medial perforation rate. Therefore, CPS seems to be an effective and reliable option in the treatment of SK.

#### Declaration of conflicting interests

The authors declared no conflicts of interest with respect to the authorship and/or publication of this article.

#### Funding

The authors received no financial support for the research and/or authorship of this article.

#### REFERENCES

1. Scheuermann HW. The classic: kyphosis dorsalis juvenilis. *Clin Orthop Relat Res* 1977;128:5-7.
2. Ali RM, Green DW, Patel TC. Scheuermann's kyphosis. *Curr Opin Pediatr* 1999;11:70-5.
3. Liljenqvist UR, Link TM, Halm HF. Morphometric analysis of thoracic and lumbar vertebrae in idiopathic scoliosis. *Spine (Phila Pa 1976)* 2000;25:1247-53.
4. Zindrick MR, Knight GW, Sartori MJ, Carnevale TJ, Patwardhan AG, Lorenz MA. Pedicle morphology of the immature thoracolumbar spine. *Spine (Phila Pa 1976)* 2000;25:2726-35.
5. Yilar S. Comparison of the accuracy of cannulated pedicle screw versus conventional pedicle screw in the treatment of adolescent idiopathic scoliosis: A randomized retrospective study. *Medicine (Baltimore)* 2019;98:e14811.
6. Lee CK, Chan CYW, Gani SMA, Kwan MK. Accuracy of cannulated pedicle screw versus conventional pedicle screw for extra-pedicular screw placement in dysplastic pedicles without cancellous channel in adolescent idiopathic scoliosis: a computerized tomography (CT) analysis. *Eur Spine J* 2017;26:2951-60.
7. Atik OŞ. Which articles do we prefer to publish? *Ekleml Hastalıkları Cerrahisi* 2018;29:1.
8. Rao G, Brodke DS, Rondina M, Bacchus K, Dailey AT. Inter- and intraobserver reliability of computed tomography in assessment of thoracic pedicle screw placement. *Spine (Phila Pa 1976)* 2003;28:2527-30.
9. Cobden A, Albayrak A, Camurcu Y, Sofu H, Tacal T, Kaygusuz MA. Posterior-Only Approach with Pedicle Screws for the Correction of Scheuermann's Kyphosis. *Asian Spine J* 2017;11:513-9.

10. Tsirikos AI, Jain AK. Scheuermann's kyphosis; current controversies. *J Bone Joint Surg Br* 2011;93:857-64.
11. Fujimori T, Iwasaki M, Nagamoto Y, Kashii M, Takao M, Sugiura T, et al. Reliability and Usefulness of Intraoperative 3-Dimensional Imaging by Mobile C-Arm With Flat-Panel Detector. *Clin Spine Surg* 2017;30:E64-E75.
12. Rajasekaran S, Vidyadhara S, Ramesh P, Shetty AP. Randomized clinical study to compare the accuracy of navigated and non-navigated thoracic pedicle screws in deformity correction surgeries. *Spine (Phila Pa 1976)* 2007;32:E56-64.
13. Kwan MK, Chiu CK, Gani SM, Wei CC. Accuracy and Safety of Pedicle Screw Placement in Adolescent Idiopathic Scoliosis Patients: A Review of 2020 Screws Using Computed Tomography Assessment. *Spine (Phila Pa 1976)* 2017;42:326-35.
14. Sarwahi V, Wendolowski SF, Gecelter RC, Amaral T, Lo Y, Wollowick AL, Thornhill B. Are We Underestimating the Significance of Pedicle Screw Misplacement? *Spine (Phila Pa 1976)* 2016;41:E548-55.