

Aura in trigeminal autonomic cephalalgia is probably mediated by comorbid migraine with aura

Cephalalgia

2022, Vol. 42(1) 31–36

© International Headache Society 2021



Article reuse guidelines:

sagepub.com/journals-permissions

DOI: 10.1177/03331024211030499

journals.sagepub.com/home/cepKuan-Po Peng , Marlene Schellong and Arne May 

Abstract

Objective: The presence of aura is rare in cluster headache, and even rarer in other trigeminal autonomic cephalalgias. We hypothesized that the presence of aura in patients with trigeminal autonomic cephalalgias is frequently an epiphenomenon and mediated by comorbid migraine with aura.

Methods: The study retrospectively reviewed 480 patients with trigeminal autonomic cephalalgia in a tertiary medical center for 10 years. Phenotypes and temporal correlation of aura with headache were analyzed. Trigeminal autonomic cephalalgia patients with aura were further followed up in a structured telephone interview.

Results: Seventeen patients with aura (3.5%) were identified from 480 patients with trigeminal autonomic cephalalgia, including nine with cluster headache, one with paroxysmal hemicrania, three with hemicrania continua, and four with probable trigeminal autonomic cephalalgia. Compared to trigeminal autonomic cephalalgia patients without aura, trigeminal autonomic cephalalgia patients with aura were more likely to have a concomitant diagnosis of migraine with aura (odds ratio [OR] = 109.0, 95% CI 30.9–383.0, $p < 0.001$); whereas the risk of migraine without aura remains similar between both groups (OR = 1.10, 95% CI = 0.14–8.59, $p = 0.931$). Aura was more frequently accompanied with migraine-like attacks, but not trigeminal autonomic cephalalgia attacks.

Interpretation: In most patients with trigeminal autonomic cephalalgia, the presence of aura is mediated by the comorbidity of migraine with aura. Aura directly related to trigeminal autonomic cephalalgia attack may exist but remains rare. Our results suggest that aura may not be involved in the pathophysiology of trigeminal autonomic cephalalgia.

Keywords

Cluster headache, aura, migraine, comorbidity, trigemino-autonomic headaches

Date received: 6 April 2021; revised: 27 May 2021; accepted: 17 June 2021

Introduction

Trigeminal autonomic cephalalgia (TAC) is a group of headache disorders characterized by predominantly unilateral headache and accompanied by cranial autonomic symptoms and/or restlessness (1). Cluster headache (CH) is one of the most common forms of TAC, and a typical visual aura, like those seen in patients with migraine, has been reported to be present in patients with CH. The prevalence of aura among CH patients varies greatly, ranging from 2% to 35.5% in European and North American studies (2–9). Some authors hence suggested that aura may be a common presentation in CH or other headaches and not pathognomonic of migraine (6,10). Cases of aura in other

TACs have been reported but remain extremely rare (11–13). If the mechanism of aura generation were directly related to TAC (as is the case with migraine), we would expect to see a stable prevalence of aura among TAC (just like the case with migraine, where the prevalence of aura is similar across different

Department of Systems Neuroscience, University Medical Center
Hamburg-Eppendorf, Hamburg, Germany

Corresponding author:

Kuan-Po Peng, Department of Systems Neuroscience, University Medical
Center Hamburg-Eppendorf, Martinistraße 52, 20246 Hamburg,
Germany.

Email: k.peng@uke.de

migraine studies (14)). However, the variation of aura prevalence in TAC is remarkable (2–35.5%) (2–9); we hence suspect that this is mediated by other factors.

From the mechanism of aura generation, a direct causal relationship between TAC and aura is also less likely. Cortical spreading depression (CSD) has been implicated in the development of migraine aura; however, the role of CSD in other headache disorders (including migraine without aura) is dubious and still under debate (15). Clinical evidence supporting the role of CSD in CH is lacking, even though a hypothetical link may exist between CSD and CH via nitric oxide (16) or orexin (in the hypothalamus) (17) in animal models. An alternative hypothesis is that the presence of aura is mediated by comorbid migraine with aura (MwA). Approximately 15.6–45% of patients with CH have a comorbid migraine (18), one-third of which have aura (14). This hypothesis may also explain why aura may be present in other TACs than CH, provided that the pathophysiology of various forms of TAC is still different. Based on these assumptions, we investigated the presence of aura in different forms of TAC and whether a comorbid MwA is over-represented in TACs with aura.

Methods

Standard protocol approval and patient consents

Data were collected in a local database and the use of the data for scientific analysis and publication was approved by the local ethics committee of the chamber of physicians of Hamburg, Germany (PV3185). Written informed consent was obtained from all participants.

Study setting and patients

We retrospectively reviewed 480 patients diagnosed with TAC in a tertiary medical center (headache outpatient clinic of the University Medical Center Hamburg-Eppendorf) between November 2009 and June 2020. The TAC was diagnosed by trained headache specialists following ICHD criteria; that is, ICHD-2 between 2009–2013, ICHD-3 (and ICHD-3 beta) since 2013 (19,20). All patients fulfilled an electronic questionnaire covering demographic information, clinical symptoms, and comorbidities. This questionnaire also includes information regarding aura, including the presence, types, localization, and duration, and whether the aura predicts a subsequent headache attack.

Follow up of headache and aura

Patients with aura were followed up with telephone interviews using a structural questionnaire. The questionnaire collected information on the clinical progress of the primary headache disorders; that is, TAC, whether other headache diagnosis exists – for example, MwA, change in the pattern of aura, and the correlation between aura and headache attacks, including the type of headache attack and its temporal association with aura.

Statistical analyses

Data are presented as number (percentage) or mean \pm standard deviation. The Chi-square test was performed for categorical variables and in the case of cell numbers ≤ 5 , Fisher's exact test. Independent t-test for continuous variables was used for comparison of continuous variables to describe the population characteristics. A two-sided p -value of <0.05 was considered significant. All analyses were performed using SPSS statistics version 27 (IBM, Armonk, NY).

Results

Prevalence of aura and comorbidities of migraine in different forms of trigeminal autonomic cephalalgias

The mean age of the TAC cohort was 44.8 ± 12.9 years (range 18–88 years), 159 of 480 were female (33.1%), with a corresponding male-to-female ratio of 2.02, and 41 (8.5%) of whom had a comorbid migraine. Seventeen patients with aura (3.5%) were identified, among which nine had CH, one had paroxysmal hemicrania (PH), three had hemicrania continua (HC), and four were probable trigeminal autonomic cephalalgia. The average age and the sex ratio do not differ in those with and without aura ($p = 0.246$ for age, $p = 0.214$ for sex). There was no difference in the prevalence of aura among different forms of TAC (Fisher's exact test, $p = 0.501$). The prevalence of aura in each subtype of TAC is summarized in Table 1. Among the 480 patients, 16 (3.3%) had a concomitant diagnosis of MwA, whereas another 25 (5.2%) patients had a concomitant diagnosis of migraine without aura. TAC patients with aura, compared to those without aura, were more likely to have a concomitant diagnosis of MwA (odds ratio [OR] = 109.0, 95% CI 30.9–383.0, $p < 0.001$); whereas a concomitant diagnosis of migraine without aura remains comparable in TAC patients with and without aura (OR = 1.10, 95% CI = 0.14–8.59, $p = 0.931$).

Table 1. The prevalence of aura in patients with different forms of trigeminal autonomic cephalalgias.

Diagnosis (n)	Aura, n (%)	Comorbid migraine with aura
3.1 Cluster headache		
eCH (226)	7 (3.1%)	4 of 7 (57.7%)
cCH (102)	2 (2.0%)	1 of 2 (50%)
3.2 Paroxysmal hemicrania		
ePH (14)	1 (7.1%)	0 (%)
cPH (10)	0 (0%)	–
3.3 Short-lasting unilateral neuralgiform headache attacks		
SUNCT (13)	0 (0%)	–
SUNA (7)	0 (0%)	–
3.4 Hemicrania continua		
HC (58)	3 (5.2%)	1 of 3 (33%)
3.5 Probable trigeminal autonomic cephalalgia		
pTAC (50)	4 (8%)	4 of 4 (100%)

eCH: episodic cluster headache; cCH: chronic cluster headache; ePH: episodic paroxysmal hemicrania; cPH: chronic paroxysmal hemicrania; SUNCT: short-lasting unilateral neuralgiform headache with conjunctival injection and tearing; SUNA: short-lasting unilateral neuralgiform headache with cranial autonomic symptoms; HC: hemicrania continua; pTAC: probable trigeminal autonomic cephalalgia.

Aura and association with headaches

Among the 17 TAC patients with aura, aura was always (100%) associated with headache attacks in four, in another two never (0%) associated with headache, whereas 13 patients reported the presence of aura in 5–80% headache attacks. Aura developed before the headache attacks in six, during the headache attacks in eight, and with a variable temporal relationship in three. Of the 17 patients, visual aura was present in 12 (70.6%), sensory aura in five (29.4%), and motor (5.9%) or aphasic aura in one (5.9%), respectively. Of note, one patient had three different types of auras (visual, aphasic, and sensory). Thirteen of the 17 patients had an aura that lasted 5–60 min, whereas the other four patients had aura length longer than 60 min (68 min, 90 min, 150 min, 180 min, respectively). Notably, 16 from 17 patients had a side-locked aura, only one with an aura that shifted side.

Telephone follow-up of the patients

Nine of 17 patients (five with CH, three with HC, and one with chronic PH) were successfully followed up after multiple attempts, corresponding to a response rate of 53%. A mean of 6.3 ± 2.0 years has elapsed since the initial clinical visit. Six of nine still have active TAC, and the remaining three (two patients with HC, one with CH) are now free from headache attacks. One patient who used to have HC now has headache attacks up to 30 min in duration at maximal that fulfill the diagnostic criteria of PH with good

clinical response to indomethacin. During the follow-up, only five patients (four with CH, one with HC) still had an aura. Four of them had active MwA, three of which reported that the aura was usually followed by migrainous headache instead of TAC-like headaches, the other reported the presence of aura as independent of both headache types (CH and MwA). The other patient had visual aura only during the CH attack. The study cohort and the follow up of patients with aura is summarized in Figure 1.

Discussion

TAC patients with aura compared to those without aura were more likely to have a concomitant diagnosis of MwA (OR = 109.0), but not migraine without aura (OR = 1.10), suggesting that MwA mediates the presence of aura in patients with TAC. Surprisingly, the comorbidity of MwA has rarely been explored in previous TAC series – only two studies explored the role of MwA in CH patients: Bahra et al. reported a prevalence of 14.4% of MwA in CH patients with aura without mentioning the prevalence in CH patients without aura (8); Ofte et al. reported 7.8% comorbid MwA in CH patients but did not compare CH patient with vs. without aura (3). The role of comorbid migraine (regardless of aura) has been explored before and no difference in CH patients with and without aura was reported (2,4–6). This is in line with our findings that only comorbid MwA, but not comorbid migraine without aura, contributes to the presence of aura in patients with TAC. The comparison of the comorbidity of migraine, MwA, and the presence of aura in CH patients are summarized in Table 2.

Aura does not belong to the diagnostic criteria in any form of TACs. The first question would be why it appears in patients with TAC. There are at least two hypotheses for why aura may appear in (some) CH patients and both are somewhat contradictory: i) aura may be a rather common phenomenon in headaches other than migraine, and its presence in CH might have been overshadowed by the prominent excruciating headache and therefore underestimated (6); (ii) aura may be found specifically in patients with CH and suggests common pathophysiology or triggers; for example, shared genetic predisposition (2) or the role of orexin (17) or melatonin deficiency (21,22). The problem with both hypotheses is that both are insufficient to explain the presence of aura in other TACs, since this is extremely rare, suggesting aura is not universally a common phenomenon in all headache disorders. Perhaps a more critical question to ask is whether the aura is simply observed in CH patients as opposed to the aura being directly related to CH attacks. Some studies have used relatively strict criteria

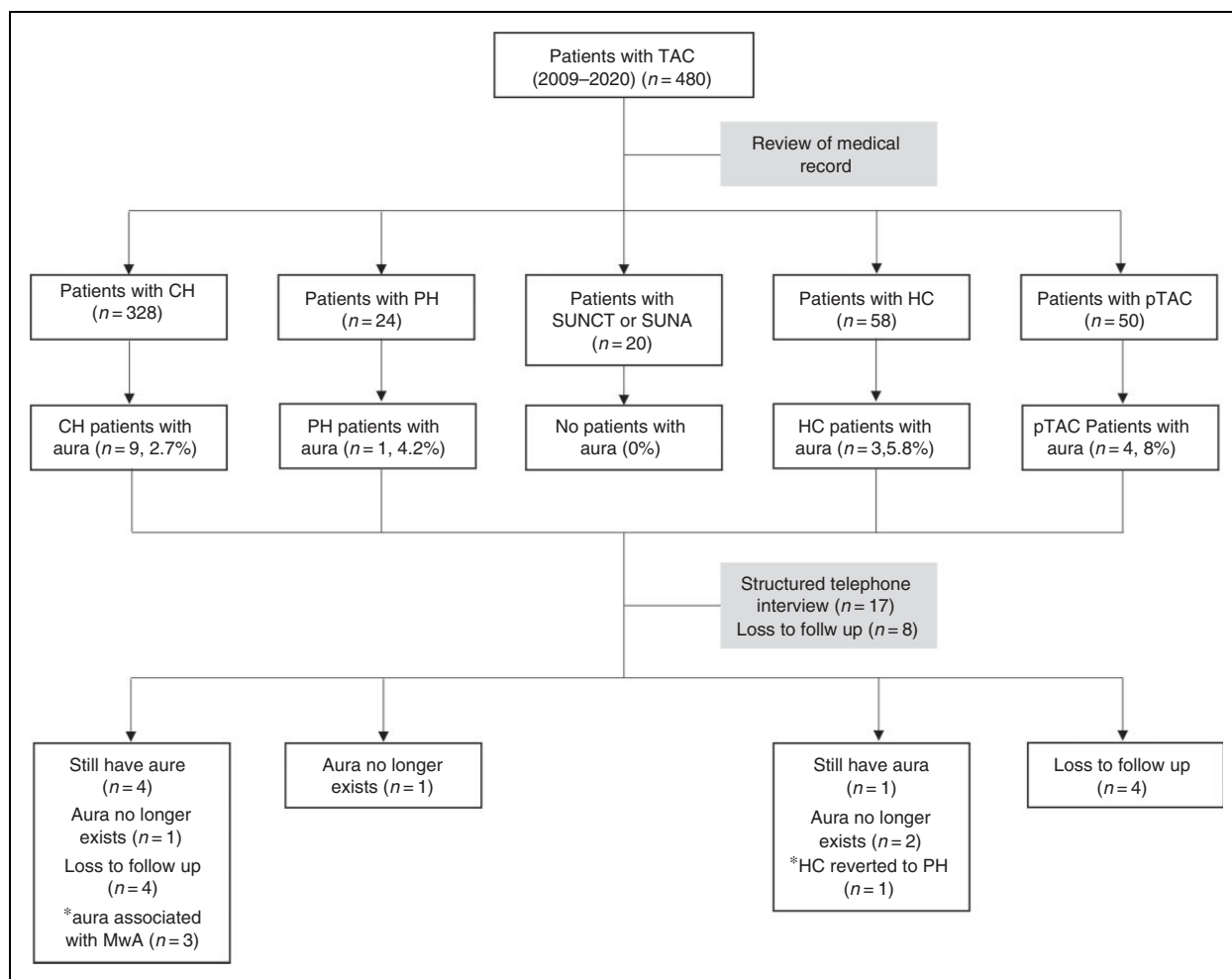


Figure 1. Flowchart of study population and telephone follow-up.

TAC: trigeminal autonomic cephalgia; CH: cluster headache; PH: paroxysmal hemicrania; SUNCT: short-lasting unilateral neuralgiform headache with conjunctival injection and tearing; SUNA: short-lasting unilateral neuralgiform headache with cranial autonomic symptoms; HC: hemicrania continua; pTAC: probable trigeminal autonomic cephalgia; MwA: migraine with aura.

for aura associated with CH; that is, aura must be accompanied or followed by CH-like headaches, and in these studies the prevalence of aura was comparably lower (2,4,5,8). The current study also reported a low prevalence of aura, and compared to the other previous studies, we enrolled not only patients with CH, but other TACs as well. Contrary to both hypotheses, our data suggest that aura is not a common phenomenon and the presence of aura is simply attributed to a comorbid MwA.

Nearly half of our patients whom we contacted no longer had an active aura, suggesting that aura is a transient phenomenon in TAC. Even in those who still had an aura, most had a concomitant diagnosis of MwA, and these patients reported that the aura is usually followed by migraine-like, not TAC-like headaches. Only one patient had aura exclusively during CH attacks. This case, in line with the studies from

Silberstein et al. and Martínez-Fernández (2,5), suggests that aura directly related to TAC attacks might still exist but remains relatively rare. In the majority of TAC patients who experience an aura, the aura is mediated by the comorbidity of MwA.

Based on our assumption that the presence of aura is mediated by the coexistence of MwA, we would assume that the prevalence of MwA in the general population may affect the presence of aura in TAC patients, that is, lower prevalence of MwA in the general population leads to lower comorbidity of MwA in TAC patients, hence the lower proportion of aura presence. This assumption may be supported by CH studies from different racial groups. Migraine prevalence is somewhat comparable worldwide (23); however, MwA accounted for only 10% of all migraine patients in Asian populations (23), compared to 30–40% in European or North American populations (14). Similarly, the comorbidity

Table 2. The presence of aura and comorbidity of migraine and/or migraine with aura in patients with cluster headache.

Authors	Country	CH patient number	Aura seen in	Comorbidity of migraine	Comorbid migraine with aura
Bahra et al. (8)	UK	230	14%	36% (CH patients with aura)	14.4% (CH patients with aura)
Silberstein et al. (2)	US	106	6%	1 of 6 (CH patients with aura)	–
Donnet et al. (9)	France	109	20%	–	–
Rozen et al. (10)	US	1134	21%	–	–
Ofte et al. (3)	Norway	88	35.5%	13.6% (all CH patients)	7.8% (all CH patients)
de Coo et al. (4)	Netherland	629	7%	13.6% (CH patients with aura) vs. 10.4% (CH patients without aura)	–
Martinez-Fernandez et al. (5)	Spain	254	2%	0 of 5 (CH patients with aura)	–
Schürks et al. (6)	Germany	208	23%	No number reported, but nausea/vomiting was seen in 27.8%, photo- and phonophobia in 61.2%	–

CH: cluster headache.

of migraine did not differ between Asian and European patients with CH (15.6% in Asian countries vs. 9–26% in European studies), but comorbid MwA is extremely rare (24). The presence of aura among Asian patients with CH happened to be extremely rare, only 0.4% using data pooled from five different Asian countries (24) compared to 2% to 35.5% in European and North American studies (2–9). This geographical difference of aura supports our hypothesis that in most patients with TAC, the presence of aura is mediated by the prevalence of MwA.

Certain limitations must be addressed: i) this study is conducted in a tertiary medical center; the patient population may deviate from the community-based population. Indeed, the clinical setting and patient recruitment may be a major confounding factor explaining the discrepancy of aura presence between different studies (3,4). The generalizability of the results must therefore be prudent; ii) the differentiation between typical visual aura and other transient visual phenomena may sometimes be blurred (25). Some questionnaires may help to validate an aura from other visual phenomena but remain rarely used in clinical routine (26). Therefore, the diagnosis of “aura” depends on the clinicians’ judgment, and this may be another factor in the inter-study differences. In

our study, the diagnosis of TAC and aura were made by headache specialists with more than 10 years of experience; iii) even though we enrolled nearly five hundred patients with TAC, the events number of auras remained low. This study hence lacks the statistical power to inform on the differences (if any) between different forms of TAC diagnoses (e.g. CH vs. HC); iv) a second type of headache (e.g. milder migraine without aura) may sometimes be obscured by the prominent features of TAC and hence underestimated. Nonetheless, there is no evidence to suggest that such “potential” underestimation differs in TAC patients with vs. without aura. The odds ratio (migraine without aura in TAC patients with aura/migraine without aura in TAC patients without aura) should therefore remain unchanged.

Conclusion

Frequent comorbidity of MwA in patients with TAC suggests that aura is an epiphenomenon in most TAC patients. Aura solely associated with TAC attacks may still exist but is certainly extremely rare. Whether the identification of comorbid MwA and simultaneous treatment of migraine brings additional benefits to these TAC patients with aura remains to be explored.

Clinical implications

- In most patients with TAC, the presence of aura is mediated by the comorbidity of migraine with aura.
- Aura directly related to TAC attack may exist but remains rare.
- Our results suggest that aura may not be involved in the pathophysiology of TAC.

Authors' contributions

KP: Data acquisition and analysis, data interpretation, drafting and writing of the manuscript; MS: Data acquisition, data interpretation, drafting of the manuscript; AM: Drafting of the study, data analysis, data interpretation, drafting and writing of the manuscript.


Declaration of conflicting interests


The authors declared no potential conflicts of interest with respect to the research, authorship, and/or publication of this article. All authors agree with the content of this manuscript.

Funding

The authors disclosed receipt of the following financial support for the research, authorship, and/or publication of this article: This work was supported by the German Research Foundation, SFB936/A5 to A.M. The funding source did not influence study conduction in any way.

ORCID iDs

Kuan-Po Peng  <https://orcid.org/0000-0002-2718-3738>

Arne May  <https://orcid.org/0000-0002-3499-1506>

References

1. May A and Jurgens TP. Trigeminal-autonomic headaches in daily clinical practice. *Expert Rev Neurother* 2006; 6: 1531–1543.
2. Silberstein SD, Niknam R, Rozen TD, et al. Cluster headache with aura. *Neurology* 2000; 54: 219–219.
3. Ofte HK, Berg DH, Bekkelund SI, et al. Insomnia and periodicity of headache in an Arctic cluster headache population. *Headache* 2013; 53: 1602–1612.
4. de Coo IF, Wilbrink LA, Ie GD, et al. Aura in cluster headache: A cross-sectional study. *Headache* 2018; 58: 1203–1210.
5. Martínez-Fernández E, Alberca R, Mir P, et al. Cluster headache with aura. *J Headache Pain* 2002; 3: 105–110.
6. Schürks M, Kurth T, de Jesus J, et al. Cluster headache: Clinical presentation, lifestyle features, and medical treatment. *Headache* 2006; 46: 1246–1254.
7. Rozen TD and Fishman RS. Cluster headache in the United States of America: Demographics, clinical characteristics, triggers, suicidality, and personal burden. *Headache* 2012; 52: 99–113.
8. Bahra A, May A and Goadsby PJ. Cluster headache: A prospective clinical study with diagnostic implications. *Neurology* 2002; 58: 354–361.
9. Donnet A, Lanteri-Minet M, Guegan-Massardier E, et al. Chronic cluster headache: A French clinical descriptive study. *J Neurol Neurosurg Psychiatry* 2007; 78: 1354–1358.
10. Rozen TD. Cluster headache with aura. *Curr Pain Headache Rep* 2011; 15: 98–100.
11. Seidel S and Wöber C. Paroxysmal hemicrania with visual aura in a 17-year-old boy. *Headache* 2009; 49: 607–609.
12. Peres M, Masruha M and Young W. Side-shifting hemicrania continua with aura (migraine with aura with autonomic symptoms responsive to indomethacin?). *Cephalalgia* 2006; 26: 917–919.
13. Vega J, Mauri G and Pascual J. Coexistence of SUNCT and aura? A case report. *Cephalalgia* 2012; 32: 940–941.
14. Merikangas KR. Contributions of epidemiology to our understanding of migraine. *Headache* 2013; 53: 230–246.
15. Harriott AM, Takizawa T, Chung DY, et al. Spreading depression as a preclinical model of migraine. *J Headache Pain* 2019; 20: 45.
16. Steinberg A, Wiklund NP, Brundin L, et al. Levels of nitric oxide metabolites in cerebrospinal fluid in cluster headache. *Cephalalgia* 2010; 30: 696–702.
17. Holland PR and Goadsby PJ. Cluster headache, hypothalamus, and orexin. *Curr Pain Headache Rep* 2009; 13: 147–154.
18. Song T-J, Lee MJ, Choi Y-J, et al. Differences in characteristics and comorbidity of cluster headache according to the presence of migraine. *J Clin Neurol* 2019; 15: 334.
19. Headache Classification Subcommittee of the International Headache Society. The International Classification of Headache Disorders, 2nd edition. *Cephalalgia* 2004; 24: 9–160.
20. Headache Classification Committee of the International Headache Society. The International Classification of Headache Disorders, 3rd edition. *Cephalalgia* 2018; 38: 1–211.
21. Ebert E, Hanke W, Wiedemann M, et al. Biphasic effects of melatonin on the propagation of excitation waves in the chicken retina. *Neurosci Lett* 1999; 268: 37–40.
22. Waldenlind E, Ekbom K, Wetterberg L, et al. Lowered circannual urinary melatonin concentrations in episodic cluster headache. *Cephalalgia* 1994; 14: 199–204.
23. Peng K-P and Wang S-J. Epidemiology of headache disorders in the Asia-pacific region. *Headache* 2014; 54: 610–618.
24. Peng K-P, Takizawa T and Lee MJ. Cluster headache in Asian populations: Similarities, disparities, and a narrative review of the mechanisms of the chronic subtype. *Cephalalgia* 2020; 40: 1104–1112.
25. Viana M, Tronvik EA, Do TP, et al. Clinical features of visual migraine aura: A systematic review. *J Headache Pain* 2019; 20: 64.
26. Eriksen MK, Thomsen LL and Olesen J. The Visual Aura Rating Scale (VARS) for migraine aura diagnosis. *Cephalalgia* 2005; 25: 801–810.