



Since January 2020 Elsevier has created a COVID-19 resource centre with free information in English and Mandarin on the novel coronavirus COVID-19. The COVID-19 resource centre is hosted on Elsevier Connect, the company's public news and information website.

Elsevier hereby grants permission to make all its COVID-19-related research that is available on the COVID-19 resource centre - including this research content - immediately available in PubMed Central and other publicly funded repositories, such as the WHO COVID database with rights for unrestricted research re-use and analyses in any form or by any means with acknowledgement of the original source. These permissions are granted for free by Elsevier for as long as the COVID-19 resource centre remains active.



## Case Report

## Neurologic complications of COVID-19

Rachel Bridwell, MD<sup>a</sup>, Brit Long, MD<sup>a,\*</sup>, Michael Gottlieb, MD<sup>b</sup><sup>a</sup> Department of Emergency Medicine, Brooke Army Medical Center, San Antonio, TX, United States of America<sup>b</sup> Department of Emergency Medicine, Rush University Medical Center, Chicago, IL, United States of America

## ARTICLE INFO

## Article history:

Received 8 May 2020

Accepted 10 May 2020

## Keywords:

COVID-19

Coronavirus

Infectious disease

Neurologic

HLH

Cerebrovascular disease

Encephalopathy

## ABSTRACT

**Background:** Much of the focus regarding the global pandemic of coronavirus disease of 2019 (COVID-19) has been on the cardiovascular, pulmonary, and hematologic complications. However, neurologic complications have arisen as an increasingly recognized area of morbidity and mortality.

**Objective:** This brief report summarizes the neurologic complications associated with COVID-19 with an emphasis on the emergency medicine clinician.

**Discussion:** COVID-19 has infected over 3.5 million people and killed over 240,000 people worldwide. While pulmonary complications are profound, the neurologic system is also significantly impacted, with complications including acute cerebrovascular events, encephalitis, Guillain-Barré syndrome, acute necrotizing hemorrhagic encephalopathy, and hemophagocytic lymphohistiocytosis. Additionally, patients on immunosuppressive medications for pre-existing neurologic issues are at an increased risk for complications with COVID-19 infection, and many of the currently proposed COVID-19 therapies can interact with these medications.

**Conclusions:** When caring for COVID-19 patients, emergency medicine clinicians should be aware of the neurologic complications from COVID-19.

Published by Elsevier Inc.

## 1. Introduction

First appearing in Wuhan, China, severe acute respiratory syndrome coronavirus 2 (SARS-CoV-2) is responsible for the coronavirus disease of 2019 (COVID-19), which the World Health Organization (WHO) declared a pandemic in March 2020 [1]. As of May 1, 2020, the COVID-19 pandemic has resulted in over 1 million cases and 62,406 deaths in the United States, and over 3.5 million cases and 240,000 deaths worldwide [1–3]. Despite the majority of the focus being placed on pulmonary and cardiovascular complications, emergency medicine clinicians must remain cognizant of the neurologic complications, which can present subtly and add substantially to the morbidity and mortality [4–7]. The following article reviews the neurologic complications from COVID-19, with an emphasis on the emergency medicine clinician.

## 2. Methods

Authors searched PubMed and Google Scholar for articles using the keywords “COVID-19”, “SARS-CoV-2”, “neurologic”, “brain”, “cerebral”, “cerebrovascular accident”, “HLH”, “hemophagocytic lymphohistiocytosis”, “stroke”, “altered level of consciousness”, “decreased level of consciousness”, “encephalopathy”, “cerebrovascular

disease”. Authors included case reports, retrospective studies, prospective studies, systematic reviews and meta-analyses, clinical guidelines, and narrative reviews focusing on COVID-19 and neurologic effects and complications. Preprinted articles were also included. The literature search was restricted to studies published in English. Emergency medicine physicians with experience in critical appraisal of the literature reviewed all of the articles and decided which studies to include for the review by consensus, with a focus on emergency medicine-relevant articles. A total of 60 articles were selected for inclusion.

## 3. Discussion

## 3.1. Pathophysiology and clinical features

A member of the beta-coronaviridae family, SARS-CoV-2 is an enveloped, non-segmented, single-stranded, positive-sense RNA virus [8–10]. The mechanisms by which SARS-CoV-2 causes neurologic damage are multifaceted, including direct damage to specific receptors, cytokine-related injury, secondary hypoxia, and retrograde travel along nerve fibers [11–15]. Much like its expression on lung epithelial cells, the expression of angiotensin converting enzyme 2 (ACE2) on endothelial cells of the blood-brain barrier can allow viral binding at this important site, facilitating viral entry into the central nervous system by attacking the vasculature [16,17]. The binding of SARS-CoV-2 at the pulmonary epithelial cells also generates a global systemic inflammatory response (SIRS), producing increased levels of interleukin (IL)-6,

\* Corresponding author at: 3841 Roger Brooke Dr, Fort Sam, Houston, TX 78234, United States of America.

E-mail address: [Brit.long@yahoo.com](mailto:Brit.long@yahoo.com) (B. Long).

IL-12, IL-15, and tumor necrosis factor alpha (TNF- $\alpha$ ); activating glial cells; and producing a massive pro-inflammatory central nervous system state [13]. In particular, IL-6 levels have been correlated with increased disease severity in COVID-19 [11–13]. These systemic effects combined with localized lung alveolar damage result in severe hypoxia, which can lead to cerebral vasodilation and may decompensate into cerebral edema and ischemia [13,14]. Finally, SARS-CoV-2 travels retrograde along the olfactory nerve and bulb, which provides an avenue between the nasal epithelium and the central nervous system and may also explain the common complaint of anosmia [15].

The prevalence of neurologic symptoms in COVID-19 patients has become more apparent, though pre-existing neurologic conditions have been linked to more severe COVID-19 infections [4–7,18]. In a recent review of patients diagnosed and hospitalized with COVID-19, 8% of the 4014 patients had pre-existing neurologic diseases, though this analysis mainly focused on those with prior strokes [6]. Interestingly, patients with prior neurologic conditions have less improvement of respiratory symptoms over their first 10 days of hospitalization and had a significantly increased risk of developing acute respiratory distress syndrome as compared to controls without neurologic disease [19,20]. In a separate cohort of 179 patients with SARS-CoV-2 pneumonia, pre-existing cerebrovascular disease was also found to be associated with increased mortality [21]. A similar mortality trend has been demonstrated in those with Parkinson's Disease [22]. A systematic review and meta-analysis also identified a 2.5-fold increased risk of severe infection among patients with a prior stroke [23].

While pre-existing neurologic conditions portend worse outcomes, the incidence of neurologic complications secondary to SARS-CoV-2 infection is also substantial. Among hospitalized COVID-19 patients, neurologic complications range from 6% to 36% [18,24]. Additionally, hypoxic ischemic encephalopathy was reported in 20% of patients in one series [25]. Focused efforts are also investigating the neurotropism of SARS-CoV-2 to account for the devastating brainstem-mediated complications in both the cardiovascular and pulmonary systems [16,26] (Fig. 1).

### 3.2. Neurologic complications associated with COVID-19 infection

#### 3.2.1. Acute cerebrovascular disease

Acute cerebrovascular disease remains one of the more common and serious neurologic complications seen in COVID-19 populations. However, this final common manifestation has a multifactorial etiology. SARS-CoV-2 causes a global inflammatory response and a hypercoagulable state evidenced by increased D-dimers, prolonged prothrombin time, and disseminated intravascular coagulation [20,27]. In an Italian cohort of COVID-19 patients admitted with confirmed infection, the rate of ischemic stroke was 2.5%, despite venous thromboembolism prophylaxis on admission [28]. In comparison, the rate of ischemic stroke in hospitalized COVID-19 patients in China was estimated to be as high as 5% [24]. Similarly, there was a 3.7% incidence of ischemic stroke in Dutch COVID-19 patients in the intensive care unit (ICU) despite venous thromboembolism prophylaxis [29]. Interestingly, COVID-19 has also led to younger patients presenting with ischemic stroke, including large vessel occlusions [30]. Additionally, COVID-19 patients can develop significant hypoxia leading to decreased cerebral oxygenation and infarcts, particularly in those with pre-existing cerebrovascular disease [13,14]. Infection, inflammation, and hypercoagulable states can further increase the risk of ischemic stroke, which can be even more pronounced in older patients [31–33].

When evaluating COVID-19 patients with stroke-like symptoms, it is important to protect the healthcare team while expediting this time-sensitive emergency. The American Heart Association has addressed this with guidelines for a protected code stroke, emphasizing screening guidelines, personal protective equipment, and crisis resource management [34]. However, once diagnosed with ischemic stroke, patients should still receive the standard of care based on their institution with consideration of intravenous thrombolytic medications and endovascular thrombectomy in the appropriate clinical scenarios, without any alteration to intervention criteria [35,36].

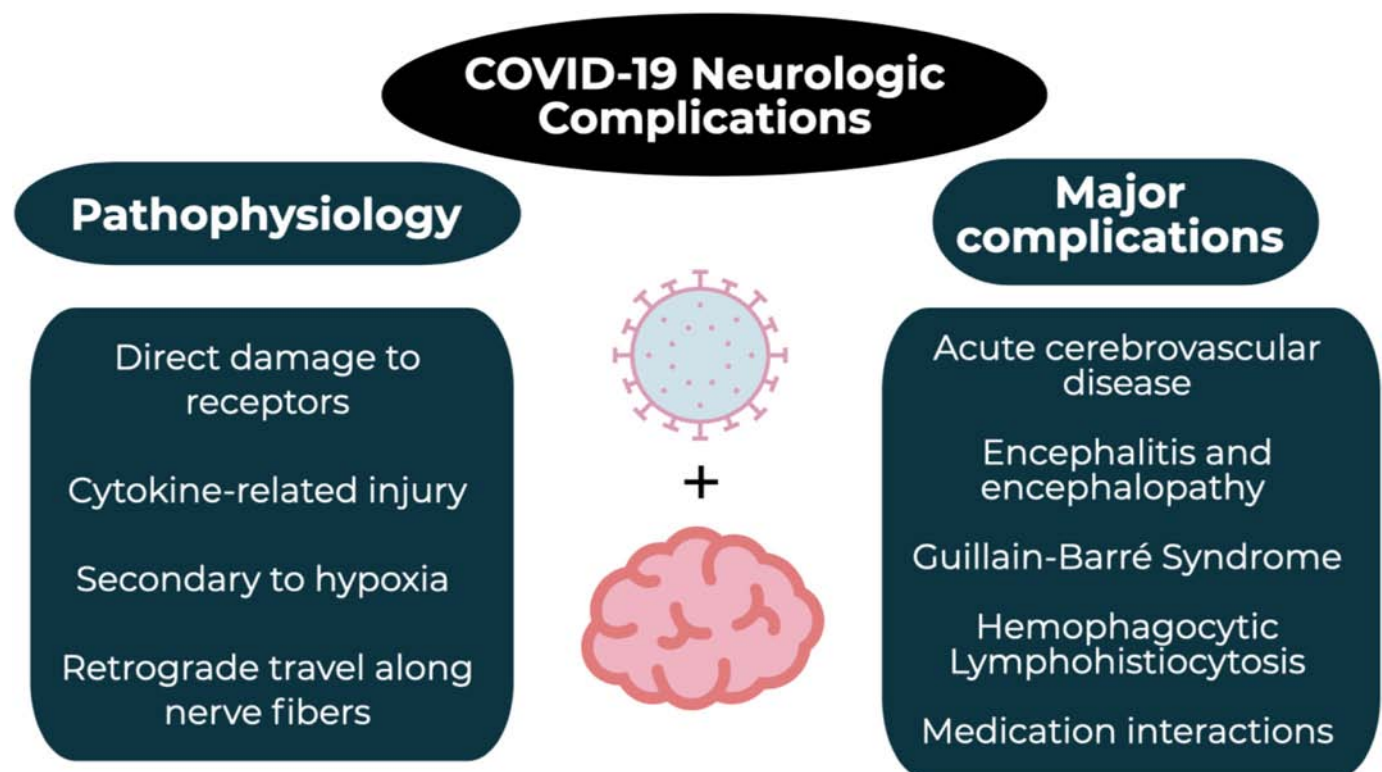


Fig. 1. COVID-19 and the neurologic system.

### 3.2.2. Encephalitis and encephalopathy

Encephalitis is characterized by acute onset of fever, vomiting, seizures, and decreased or changed consciousness [37]. While rare, SARS-CoV-2 encephalitis has been reported in several cases, though this was based on clinical and imaging findings as there has been no cerebral spinal fluid (CSF) evidence of SARS-CoV-2 to date [38,39]. The pathophysiology is unclear but may be related to edema secondary to inflammatory injury versus direct viral infection [39]. Similar to other cases of encephalitis, aggressive supportive care and treatment of increased intracranial pressure are paramount.

Acute necrotizing encephalopathy (ANE) is a rare neurologic complication caused by cytokine storm and damage to the blood-brain barrier [40]. Unlike other viral central nervous system infections, demyelination is not present in ANE [38]. Non-contrast head computed tomography (CT) can initially demonstrate symmetric, multifocal lesions, while magnetic resonance imaging (MRI) with T2-weighted-Fluid-Attenuated Inversion Recovery (FLAIR) may show hyperintense signal and internal hemorrhage [41]. The thalamus, brainstem, cerebellum, and cerebral white matter are the most common areas affected [41]. While this is more commonly associated with influenza or Zika infection, SARS-CoV-2 has also been associated with this condition [13]. The pathogenesis of ANE is poorly understood, but with the hyper-inflammatory state, treatment with intravenous immunoglobulin (IVIG) and steroids can be attempted [42,43].

### 3.2.3. Guillain-Barré Syndrome (GBS)

GBS is a symmetric, ascending flaccid paralysis, often preceded by respiratory or gastrointestinal infections from a virus or bacteria [44]. This progressive neuropathy has recently been linked to SARS-CoV-2 infection, with 5 cases reported in Italy and 2 additional cases from Wuhan, China [45–47]. All patients experienced a prodrome of an upper respiratory infection ranging from 5 to 14 days prior to the development of symmetric weakness, with 3 patients developing respiratory failure [45–47]. All patients had a positive nasopharyngeal polymerase chain reaction (PCR) test and chest imaging characteristic of SARS-CoV-2, but all cerebrospinal fluid (CSF) samples had a negative SARS-CoV-2 PCR [45–47]. While all of the patients received IVIG, those who developed respiratory failure had poor outcomes [45]. Interestingly, brain and spine MRI did not show abnormalities in half of the patients, highlighting the importance of consultation and additional testing, such as nerve conduction studies, when there is a high clinical suspicion even in the absence of radiographic findings [45–47].

### 3.2.4. Hemophagocytic Lymphohistiocytosis (HLH)

HLH is a severe dysregulation of T-lymphocyte, natural killer cell, and macrophage over-activation causing a massive cytokine storm and multiorgan injury [48]. This condition is often secondary to hematologic malignancy, immunosuppression, or critical infection, but has also been described in patients with SARS-CoV-2 [48]. HLH patients present with unremitting fevers, pancytopenia, coagulopathy, hepatic dysfunction, hypertriglyceridemia, and an elevated ferritin [48–50]. HLH is an underrecognized complication among COVID-19 patients as the innate immune system may result in uncontrolled cytokine storm, characterized by severely increased levels of IL-2, IL-6, IL-7, and TNF $\alpha$ . Up to one-third of COVID-19 patients with HLH develop neurologic abnormalities. Early recognition and scoring with the HScore allows for prompt consideration of immunosuppressive treatments (Table 1); an HScore of 200 predicts an 88% probability of HLH, while a score of 130 predicts a 9% probability of HLH [51]. Treatments include steroids and tocilizumab, both of which are currently under investigation for treatment in COVID-19 patients [51].

### 3.3. Medication interactions

Many of the recently proposed medications have significant drug interactions and side effects [4]. Azithromycin, corticosteroids, plasma

**Table 1**  
HScore.

Category	Number of points
Temperature	
<38.4 °	0
38.4–39.4 °C	33
>39.4 °C	49
Organomegaly	
None	0
Hepatomegaly or splenomegaly	23
Hepatomegaly and splenomegaly	38
Number of cytopenias	
One lineage	0
Two lineages	24
Three lineages	34
Triglycerides	
<1.5 mmol/L	0
1.5–4.0 mmol/L	44
>4.0 mmol/L	64
Fibrinogen	
>2.5 g/L	0
</=2.5 g/L	30
Ferritin	
<2000 ng/mL	0
2000–6000 ng/mL	35
>6000 ng/mL	50
Serum aspartate aminotransferase	
<30 IU/L	0
≥30 IU/L	19
Hemophagocytosis on bone marrow aspirate	
No	0
Yes	35
Known immunosuppression	
No	0
Yes	18

exchange, biologic agents (tocilizumab), antivirals (e.g., remdesivir, ribavirin, lopinavir/ritonavir, favipiravir), and antimalarials (e.g., hydroxychloroquine, chloroquine) are all currently under investigation, with a recent announcement for an accelerated trial devoted to remdesivir [52–54]. Lopinavir/ritonavir and azithromycin interact with many common medications in patients with prior strokes including antihypertensives, antiplatelets, statins, and anticoagulants [52–55]. These also carry an increased risk of neurocognitive impairment in longer courses [55–57]. Ribavirin and interferon alpha have both neuropathic and neuropsychiatric sequelae, while interferon carries a risk of retinopathy [58,59]. Similarly, antimalarials also carry the risk of neuropsychiatric side effects and less commonly ataxia, seizures, and limbic encephalitis [60]. A complete summary of mechanism of action, neurologic effects, and medication interactions can be found in Table 2.

## 4. Limitations

There are several limitations of this current literature review evaluating neurologic complications and effects connected to COVID-19. These include potential risk of bias, low patient numbers largely based on case reports, as well as heterogeneity in study design, outcomes, comparators, and patient populations. In this time of ultimate knowledge translation, a substantial portion of the literature is released as preprint without complete peer review; this highlights the need for further data to delineate these neurologic manifestations and complications secondary to SARS-CoV-2.

**Table 2**  
Medications and the nervous system.

Medication	Mechanism	Neurologic effects and medication interactions
Remdesivir	Nucleotide-analog inhibitor of RNA polymerases	- Unknown
Ribavirin	RNA and DNA virus replication inhibitor	- Interacts with anticoagulants - Neuropathy
Lopinavir/Ritonavir	Lopinavir inhibits protease Ritonavir inhibits CYP3A metabolism	- Interacts with anticoagulants, antiplatelets, statins - Cognitive and motor disturbances
Favipiravir	Inhibits RNA-dependent RNA polymerases	- Interacts with anticoagulants, statins, antiarrhythmics
Chloroquine and Hydroxychloroquine	Endosomal/organelle pH modifications	- Neuropsychiatric side effects - Ataxia, seizures
Azithromycin	Binds to 50s ribosome, inhibiting protein synthesis	- Interacts with anticoagulants, statins, antiarrhythmics
Interferon	Activates immune system	- Neuropsychiatric side effects - Retinopathy - Neuropathy
Methylprednisolone	Inflammation reduction	- Interacts with anticoagulants - Delirium
Tocilizumab	IL-6 inhibitor	- May increase medication metabolism (e.g., statins)

RNA, ribonucleic acid; DNA, deoxyribonucleic acid; IL, interleukin.

## 5. Conclusions

Significant neurologic complications are associated with COVID-19, such as impaired level of consciousness, cerebrovascular disease, encephalitis, encephalopathy, and GBS. Some of the medications utilized to treat COVID-19 also have potential neurologic effects and may interact with medications of pre-existing neurologic disease. Emergency medicine clinicians must be cognizant of these neurologic complications when treating COVID-19.

## Conflicts of interest

None.

## Acknowledgements

BL, RB, and MG conceived the idea for this manuscript and contributed substantially to the writing and editing of the review. This manuscript did not utilize any grants, and it has not been presented in abstract form. This clinical review has not been published, it is not under consideration for publication elsewhere, its publication is approved by all authors and tacitly or explicitly by the responsible authorities where the work was carried out, and that, if accepted, it will not be published elsewhere in the same form, in English or in any other language, including electronically without the written consent of the copyright-holder. This review does not reflect the views or opinions of the U.S. government, Department of Defense, U.S. Army, U.S. Air Force, or SAUSHEC EM Residency Program.

## References

- [1] World Health Organization. Coronavirus disease (COVID-19) situation report 102. . <https://www.who.int/emergencies/diseases/novel-coronavirus-2019/situation-reports/>; 2020. [Accessed 2 May 2020].
- [2] Cases in the U.S. CDC. <https://www.cdc.gov/coronavirus/2019-ncov/cases-updates/cases-in-us.html>. [Accessed 2 May 2020].
- [3] World Health Organization. Coronavirus disease (COVID-19): situation report 105. . <https://www.who.int/emergencies/diseases/novel-coronavirus-2019/situation-reports/>; 2020. [Accessed 2 May 2020].
- [4] Filatov A, Sharma P, Hindi F, Espinosa PS. Neurological complications of coronavirus disease (COVID-19): encephalopathy. *Cureus*. 2020;12(3). <https://doi.org/10.7759/cureus.7352>.
- [5] Sellner J, Taba P, Öztürk S, Helbok R. The need for neurologists in the care of COVID-19 patients. *Eur J Neurol*. 2020. <https://doi.org/10.1111/ene.14257>.
- [6] Herman C, Mayer K, Sarwal A. Scoping review of prevalence of neurologic comorbidities in patients hospitalized for COVID-19. *Neurology*. 2020. <https://doi.org/10.1212/WNL.0000000000009673> April.
- [7] Nath A. Neurologic complications of coronavirus infections. *Neurology*. March 2020:.. <https://doi.org/10.1212/WNL.0000000000009455>. doi:.. <https://doi.org/10.1212/wnl.0000000000009455>.
- [8] Wu Z, McGoogan JM. Characteristics of and important lessons from the coronavirus disease 2019 (COVID-19) outbreak in China: summary of a report of 72314 cases from the Chinese Center for Disease Control and Prevention. *JAMA - J Am Med Assoc*. 2020;323(13):1239–42. <https://doi.org/10.1001/jama.2020.2648>.
- [9] Schoeman D, Fielding BC. Coronavirus envelope protein: current knowledge. *Virology*. 2019;16(1):1–22. <https://doi.org/10.1186/s12985-019-1182-0>.
- [10] Jin YH, Cai L, Cheng ZS, et al. A rapid advice guideline for the diagnosis and treatment of 2019 novel coronavirus (2019-nCoV) infected pneumonia (standard version). *Mil Med Res*. 2020;7(1). <https://doi.org/10.1186/s40779-020-0233-6>.
- [11] Hamming I, Timens W, Bulthuis MLC, Lely AT, Navis GJ, van Goor H. Tissue distribution of ACE2 protein, the functional receptor for SARS coronavirus. A first step in understanding SARS pathogenesis. *J Pathol*. 2004;203(2):631–7. <https://doi.org/10.1002/path.1570>.
- [12] Wan S, Yi Q, Fan S, et al. Characteristics of lymphocyte subsets and cytokines in peripheral blood of 123 hospitalized patients with 2019 novel coronavirus pneumonia (NCP). *medRxiv*. February 2020:2020.02.10.20021832. doi:.. <https://doi.org/10.1101/2020.02.10.20021832>.
- [13] Wu Y, Xu X, Chen Z, et al. Nervous system involvement after infection with COVID-19 and other coronaviruses. *Brain Behav Immun*. 2020. <https://doi.org/10.1016/j.bbi.2020.03.031>.
- [14] Guo YR, Cao QD, Hong ZS, et al. The origin, transmission and clinical therapies on coronavirus disease 2019 (COVID-19) outbreak- a n update on the status. *Mil Med Res*. 2020;7(1). <https://doi.org/10.1186/s40779-020-00240-0>.
- [15] Desforges M, Le Coupancec A, Dubeau P, et al. Human coronaviruses and other respiratory viruses: underestimated opportunistic pathogens of the central nervous system? *Viruses*. 2019;12(1). <https://doi.org/10.3390/v12010014>.
- [16] Baig AM. Updates on what ACS reported: emerging evidences of COVID-19 with nervous system involvement. *ACS Chem Neurosci*. 2020. <https://doi.org/10.1021/acscchemneuro.0c00181> April.
- [17] Fu Y, Cheng Y, Wu Y. Understanding SARS-CoV-2-mediated inflammatory responses: from mechanisms to potential therapeutic tools. *Virology*. 2020. <https://doi.org/10.1007/s12250-020-00207-4>.
- [18] Mao L, Wang M, Chen S, et al. Neurological manifestations of hospitalized patients with COVID-19 in Wuhan, China: A retrospective case series study. *medRxiv*; February 2020. <https://doi.org/10.1101/2020.02.22.20026500> 2020.02.22.20026500.
- [19] Mo P, Xing Y, Xiao Y, et al. Clinical characteristics of refractory COVID-19 pneumonia in Wuhan, China. *Clin Infect Dis* March. 2020. <https://doi.org/10.1093/cid/ciaa270>.
- [20] Wang D, Hu B, Hu C, et al. Clinical characteristics of 138 hospitalized patients with 2019 novel coronavirus-infected pneumonia in Wuhan, China. *JAMA - J Am Med Assoc*. 2020;323(11):1061–9. <https://doi.org/10.1001/jama.2020.1585>.
- [21] Du RH, Liang LR, Yang CQ, et al. Predictors of mortality for patients with COVID-19 pneumonia caused by SARS-CoV-2: a prospective cohort study. *Eur Respir J*. 2020. <https://doi.org/10.1183/13993003.00524-2020> April.
- [22] Deng S-Q, Peng H-J. Characteristics of and public health responses to the coronavirus disease 2019 outbreak in China. *J Clin Med*. 2020;9(2):575. <https://doi.org/10.3390/jcm9020575>.
- [23] Aggarwal G, Lippi G, Michael Henry B. Cerebrovascular disease is associated with an increased disease severity in patients with coronavirus disease 2019 (COVID-19): a pooled analysis of published literature. *Int J Stroke*. April 2020:1747493020921664. doi:.. <https://doi.org/10.1177/1747493020921664>.
- [24] Li Y, Wang M, Zhou Y, et al. Acute cerebrovascular disease following COVID-19: a single center, retrospective, observational study. *SSRN Electron J*. March 2020: 1–20. <https://doi.org/10.2139/ssrn.3550025>.
- [25] Chen T, Wu D, Chen H, et al. Clinical characteristics of 113 deceased patients with coronavirus disease 2019: retrospective study. *BMJ*. 2020;368. <https://doi.org/10.1136/bmj.m1091>.
- [26] Li YC, Bai WZ, Hashikawa T. The neuroinvasive potential of SARS-CoV2 may be at least partially responsible for the respiratory failure of COVID-19 patients. *J Med Virology*. 2020. <https://doi.org/10.1002/jmv.25728> June.
- [27] González-Pinto T, Luna-Rodríguez A, Moreno-Estébanez A, Aguirre-Beitia G, Rodríguez-Antigüedad A, Ruiz-Lopez M. Emergency room neurology in times of COVID-19: malignant ischemic stroke and SARS-COV2 infection. *Eur J Neurol*. 2020. <https://doi.org/10.1111/ene.14286> April.
- [28] Lodigiani C, Iapichino G, Carezno L, et al. Venous and arterial thromboembolic complications in COVID-19 patients admitted to an academic hospital in Milan, Italy. *Thromb Res*. 2020;191:9–14. <https://doi.org/10.1016/j.thromres.2020.04.024>.
- [29] Klok FA, Kruijff MJHA, van der Meer NJM, et al. Incidence of thrombotic complications in critically ill ICU patients with COVID-19. *Thromb Res*. 2020. <https://doi.org/10.1016/j.thromres.2020.04.013>.

- [30] Oxley TJ, Mocco J, Majidi S, et al. Large-vessel stroke as a presenting feature of Covid-19 in the young. *N Engl J Med*. 2020. <https://doi.org/10.1056/NEJMc2009787> April.
- [31] Consoli D, Vidale S, Aguglia U, et al. Previous infection and the risk of ischaemic stroke in Italy: the IN2 study. *Eur J Neurol*. 2015;22(3):514–9. <https://doi.org/10.1111/ene.12601>.
- [32] Siniscalchi A, Iannacchero R, Anticoli S, Romana Pezzella F, De Sarro G, Gallelli L. Anti-inflammatory strategies in stroke: a potential therapeutic target. *Curr Vasc Pharmacol*. 2015;14(1):98–105. <https://doi.org/10.2174/1570161113666150923111329>.
- [33] Siniscalchi A, Gallelli L, Malferrari G, et al. Cerebral stroke injury: the role of cytokines and brain inflammation. *J Basic Clin Physiol Pharmacol*. 2014;25(2):131–7. <https://doi.org/10.1515/jbcpp-2013-0121>.
- [34] Khosravani H, Rajendram P, Notario L, Chapman MG, Menon BK. Protected code stroke: Hyperacute stroke management during the coronavirus disease 2019 (COVID-19) pandemic. *Stroke*. 2020. <https://doi.org/10.1161/STROKEAHA.120.029838> April.
- [35] Dafer RM, Osterreich ND, MD JB. Acute stroke care in the Coronavirus Disease 2019 pandemic. *J Stroke Cerebrovasc Dis*. 2020;104881. <https://doi.org/10.1016/j.jstrokecerebrovasdis.2020.104881> April.
- [36] Fraser JF, Arthur AS, Chen M, et al. Society of NeuroInterventional surgery recommendations for the care of emergent neurointerventional patients in the setting of covid-19. *J Neurointerv Surg*. 2020. <https://doi.org/10.1136/neurintsurg-2020-016098>.
- [37] Ellul M, Solomon T. Acute encephalitis - diagnosis and management. *Clin Med J R Coll Physicians London*. 2018;18(2):155–9. <https://doi.org/10.7861/clinmedicine.18-2-155>.
- [38] Poyiadji N, Shahin G, Noujaim D, Stone M, Patel S, Griffith B. COVID-19-associated acute Hemorrhagic necrotizing encephalopathy: CT and MRI features. *Radiology*. March 2020;201187. doi: <https://doi.org/10.1148/radiol.2020201187>.
- [39] Ye M, Ren Y, Lv T. Encephalitis as a clinical manifestation of COVID-19. *Brain Behav Immun*. 2020. <https://doi.org/10.1016/j.bbi.2020.04.017> April.
- [40] Rossi A. Imaging of acute disseminated encephalomyelitis. *Neuroimaging Clin N Am*. 2008;18(1):149–61. <https://doi.org/10.1016/j.nic.2007.12.007>.
- [41] Wong A, Simon E, Zimmerman R, Wang H, Toh C, Ng S. Acute necrotizing encephalopathy of childhood: correlation of MR findings and clinical outcome. *Am J Neuroradiol*. 2006;27(9):1919–23.
- [42] Alsolami A, Shiley K. Successful treatment of influenza-associated acute necrotizing encephalitis in an adult using high-dose oseltamivir and methylprednisolone: case report. *Open Forum Infect Dis*. 2017;4(3):145.
- [43] Das G, Mukherjee N, Ghosh S. Neurological insights of COVID-19 pandemic. *ACS Chem Neurosci*. 2020. <https://doi.org/10.1021/acscchemneuro.0c00201> April.
- [44] Sejvar JJ, Baughman AL, Wise M, Morgan OW. Population incidence of Guillain-Barré syndrome: a systematic review and meta-analysis. *Neuroepidemiology*. 2011;36(2):123–33. <https://doi.org/10.1159/000324710>.
- [45] Toscano G, Palmerini F, Ravaglia S, et al. Guillain-Barré syndrome associated with SARS-CoV-2. *N Engl J Med*. 2020. <https://doi.org/10.1056/nejmc2009191> April.
- [46] Sedaghat Z, Karimi N. Guillain Barre syndrome associated with COVID-19 infection: a case report. *J Clin Neurosci*. 2020. <https://doi.org/10.1016/j.jocn.2020.04.062> April.
- [47] Zhao H, Shen D, Zhou H, Liu J, Chen S. Guillain-Barré syndrome associated with SARS-CoV-2 infection: causality or coincidence? *Lancet Neurol*. 2020;19(5):383–4. [https://doi.org/10.1016/S1474-4422\(20\)30109-5](https://doi.org/10.1016/S1474-4422(20)30109-5).
- [48] Al-Samkari H, Berliner N. Hemophagocytic lymphohistiocytosis. *Annu Rev Pathol Mech Dis*. 2018;13(1):27–49. <https://doi.org/10.1146/annurev-pathol-020117-043625>.
- [49] Mehta P, McAuley DF, Brown M, Sanchez E, Tattersall RS, Manson JJ. COVID-19: consider cytokine storm syndromes and immunosuppression. *Lancet*. 2020;395(10229):1033–4. [https://doi.org/10.1016/S0140-6736\(20\)30628-0](https://doi.org/10.1016/S0140-6736(20)30628-0).
- [50] Huang C, Wang Y, Li X, et al. Clinical features of patients infected with 2019 novel coronavirus in Wuhan, China. *Lancet*. 2020;395(10223):497–506. [https://doi.org/10.1016/S0140-6736\(20\)30183-5](https://doi.org/10.1016/S0140-6736(20)30183-5).
- [51] Fardet L, Galicier L, Lambotte O, et al. Development and validation of the hscore, a score for the diagnosis of reactive hemophagocytic syndrome. *Arthritis Rheumatol*. 2014;66(9):2613–20. <https://doi.org/10.1002/art.38690>.
- [52] Wang Y, Zhang D, Du G, et al. Remdesivir in adults with severe COVID-19: a randomised, double-blind, placebo-controlled, multicentre trial. *Lancet*. 2020(0):0. [https://doi.org/10.1016/S0140-6736\(20\)31022-9](https://doi.org/10.1016/S0140-6736(20)31022-9).
- [53] Elfiky AA. Anti-HCV, nucleotide inhibitors, repurposing against COVID-19. *Life Sci*. 2020;248. <https://doi.org/10.1016/j.lfs.2020.117477>.
- [54] Chavez S, Long B, Koyfman A, Liang SY. Coronavirus disease (COVID-19): a primer for emergency physicians. *Am J Emerg Med*. 2020(0):0. <https://doi.org/10.1016/j.ajem.2020.03.036>.
- [55] Long B, Brady WJ, Koyfman A, Gottlieb M. Cardiovascular complications in COVID-19. *Am J Emerg Med*. 2020;38:1504–7.
- [56] AbbVie Inc. KALETRA(R) Oral film coated tablets, Oral solution, Lopinavir ritonavir Oral film coated tablets, Oral solution. North Chicago, IL. [www.fda.gov/medwatch](http://www.fda.gov/medwatch); 2013. [Accessed 3 May 2020].
- [57] Pistell PJ, Gupta S, Knight AG, et al. Metabolic and neurologic consequences of chronic lopinavir/ritonavir administration to C57BL/6 mice. *Antiviral Res*. 2010;88(3):334–42. <https://doi.org/10.1016/j.antiviral.2010.10.006>.
- [58] Sleijfer S, Bannink M, Van Gool AR, Kruit WHJ, Stoter G. Side effects of interferon- $\alpha$  therapy. *Pharm World Sci*. 2005;27(6):423–31. <https://doi.org/10.1007/s11096-005-1319-7>.
- [59] Russo MW, Fried MW. Side effects of therapy for chronic hepatitis C. *Gastroenterology*. 2003;124(6):1711–9. [https://doi.org/10.1016/S0016-5085\(03\)00394-9](https://doi.org/10.1016/S0016-5085(03)00394-9).
- [60] Maxwell NM, Nevin RL, Stahl S, et al. Prolonged neuropsychiatric effects following management of chloroquine intoxication with psychotropic polypharmacy. *Clin Case Reports*. 2015;3(6):379–87. <https://doi.org/10.1002/ccr3.238>.