

Visual prognosis and vitreous molecules after vitrectomy for macular edema with branch retinal vein occlusion

Hidetaka Noma¹
Hideharu Funatsu¹
Tatsuya Mimura²
Shuichiro Eguchi³
Katsunori Shimada⁴

¹Department of Ophthalmology, Yachiyo Medical Center, Tokyo Women's Medical University, Yachiyo, Chiba, Japan; ²Department of Ophthalmology, University of Tokyo Graduate School of Medicine, Bunkyo-ku, Tokyo, Japan;

³Department of Ophthalmology, Eguchi Eye Hospital, Hakodate, Japan;

⁴Department of Hygiene and Public Health II, Tokyo Women's Medical University, Shinjuku-ku, Tokyo, Japan

Abstract: This study investigated whether vascular endothelial growth factor (VEGF), soluble intercellular adhesion molecule-1 (sICAM-1), and pigment epithelium-derived factor (PEDF) influence the visual prognosis of patients with macular edema and branch retinal vein occlusion (BRVO). In 47 consecutive patients (47 eyes) undergoing vitrectomy, retinal thickness was examined by optical coherence tomography. Best-corrected visual acuity and the vitreous fluid levels of VEGF, sICAM-1, and PEDF were also determined. Patients were followed for at least 6 months after surgery. Vitreous fluid levels of VEGF and sICAM-1 were significantly lower in the patients with more marked improvement of visual acuity after vitrectomy, while PEDF was significantly higher. VEGF and sICAM-1 levels were significantly higher in patients with greater postoperative improvement of macular edema, while PEDF was significantly lower. In BRVO patients, vitreous fluid levels of VEGF, sICAM-1, and PEDF may influence both the response of macular edema to vitrectomy and the visual prognosis.

Keywords: branch retinal vein occlusion, macular edema, vitrectomy, vascular endothelial growth factor, soluble intercellular adhesion molecule-1, pigment epithelium-derived factor

Introduction

Branch retinal vein occlusion (BRVO) is a common retinal vascular disease that often leads to macular edema, which is the commonest reason for visual impairment in this disease.^{1,2} We recently reported that the ocular fluid levels of several molecules, including vascular endothelial growth factor (VEGF), soluble intercellular adhesion molecule-1 (sICAM-1), and pigment epithelium-derived factor (PEDF), had an independent influence on retinal vascular permeability in BRVO patients with macular edema.^{3,4} Therefore, changes in the vitreous levels of these molecules may influence the development of macular edema associated with BRVO and may also be related to improvement of macular edema in BRVO patients after pars plana vitrectomy (PPV).

We recently reported that a decrease of VEGF in the vitreous fluid was associated with improvement of visual acuity and macular edema after PPV in patients with BRVO.⁵ However, little is known about the relationship between occurrence of macular edema secondary to BRVO and the vitreous levels of sICAM-1 and PEDF. Therefore, we evaluated the outcome of PPV for the treatment of macular edema in patients with BRVO, measured the vitreous fluid levels of sICAM-1, PEDF, and VEGF, and examined the relationship between these molecules, improvement of the final best-corrected visual acuity (BCVA), and improvement of macular edema after PPV.

Correspondence: Hidetaka Noma
Department of Ophthalmology, Yachiyo Medical Center, Tokyo Women's Medical University, 477-96, Owada-shinden, Yachiyo, Chiba 276-8524, Japan
Tel +81 47 450 6000
Fax +81 47 458 7047
Email nomahide@tymc.twmu.ac.jp

Materials and methods

Patients

This study was performed in accordance with the Helsinki Declaration of 1975 (1983 revision), and the institutional review boards of Tokyo Women's Medical University and Eguchi Eye Hospital both approved the protocol for collection and testing of vitreous fluid. Written informed consent was obtained from each subject following an explanation of the purpose and potential adverse effects of the procedure. The patients all underwent PPV at Tokyo Women's Medical University Hospital or Eguchi Eye Hospital, and undiluted vitreous fluid samples were harvested at the start of surgery. Consecutive patients presenting with BRVO between December 2006 and November 2009 were screened according to the criteria listed below and 48 patients were enrolled. Complete data were available for 47 of the 48 patients enrolled, while one patient was lost to follow-up because of referral to another hospital. The indications for PPV were 1) clinically detectable diffuse macular edema or cystoid macular edema persisting for more than 3 months, 2) a best-corrected visual acuity worse than 20/40, and 3) persistent macular edema despite retinal photocoagulation.

The Branch Vein Occlusion Study demonstrated the effectiveness of argon laser photocoagulation for BRVO, but it was recommended that this should not be performed within 3 months of occlusion because spontaneous improvement may occur during that period.⁶ Accordingly, all 11 patients (11 eyes) who underwent focal laser photocoagulation for macular edema (mean: 242 shots; range: 120–374 shots) were treated for more than 3 months after the occurrence of BRVO. Absence of posterior vitreous detachment can contribute to persistent macular edema in patients with retinal vascular occlusion,⁷ and Saika et al reported the effectiveness of vitrectomy combined with surgical posterior vitreous detachment for macular edema in BRVO patients.⁸ Therefore, we performed vitrectomy for more than 3 months after the occurrence of BRVO in patients with clinically detectable diffuse macular edema, cystoid macular edema, or persistent macular edema despite photocoagulation.

All of the patients had significant macular edema, which was defined as retinal thickening of at least one optic disk area in size that involved the fovea.⁹ Exclusion criteria were 1) ocular surgery within the previous 6 months, 2) diabetic retinopathy, 3) intravitreal injection of anti-VEGF agents or triamcinolone acetonide, and 4) a history of ocular inflammation or vitreoretinal disease. A total of 25 of the 47 patients underwent PPV combined with cataract surgery. During the

6-month follow-up period after surgery, cataract extraction was not performed in the other 22 patients without baseline cataracts, and additional scatter laser photocoagulation was not done in any of the patients.

Fundus findings

Careful biomicroscopic examination was performed with a fundus contact lens. Fundus findings were confirmed preoperatively by standardized fundus color photography and fluorescein angiography, which was performed with a Topcon TRC-50EX fundus camera, an image-net system (Tokyo Optical Co Ltd, Tokyo, Japan), and a preset lens with a slit-lamp. BCVA was measured before and after PPV in decimal units, and the data were converted to the logarithm of the minimum angle of resolution (logMAR) scale.

Both preoperative and operative fundus findings were recorded for each subject. A masked grader independently assessed ischemic retinal vascular occlusion on fluorescein angiograms. The ischemic region of the retina was measured with the public domain Scion Image program (Scion Corporation, Frederick, MD), as reported previously.^{10–12} In brief, the disk area was outlined on a digital fluorescein photograph using a cursor and then was measured, as was the nonperfused area. Sites of retinal photocoagulation were excluded when calculating the nonperfused area, which was divided by the disk area as an index of retinal ischemia.

In each subject, optical coherence tomography (OCT) was performed with a unit from Zeiss-Humphrey Ophthalmic Systems (Dublin, CA) within 1 week before PPV. The fundi were scanned with the measuring beam focused on horizontal and vertical planes crossing the central fovea, the location of which was determined from the fundus photograph and by the patient's fixation. (All 47 subjects were able to fix on the central landmark during OCT.) Cross-sectional images were collected by a single, experienced examiner, who continued each OCT study until highly reproducible scans were obtained. The thickness of the central fovea was defined as the distance between the inner limiting membrane and the retinal pigment epithelium (including any serous retinal detachment). The thickness of the neurosensory retina was defined as the distance between the inner and outer neurosensory retinal surfaces,⁷ and the severity of macular edema was graded from the measured foveal thickness. Measurements were automatically performed by computer analysis.

Serous retinal detachment was defined as typical subretinal fluid accumulation on OCT that resulted in neurosensory retinal detachment with low or absent reflectivity anterior to a clearly

distinguishable outer band irrespective of the coexistence of cystoid macular edema.¹³ The 47 BRVO patients included 20 patients who had serous retinal detachment (mean age: 64.9 ± 11.0 years; 12 women and 8 men) and 27 patients without it (mean age: 66.7 ± 8.9 years; 14 women and 13 men).

Surgical technique

Under local anesthesia, all patients underwent standard three-port PPV. All epiretinal materials, the residual cortex, and the posterior hyaloid were removed from the retinal surface around the macula as completely as possible with the assistance of triamcinolone acetonide. The minimum volume necessary was injected into the eyeball and then was removed as thoroughly as possible at the end of surgery. Intraoperative scatter laser photocoagulation was not done for the ischemic region of the retina. Peeling of the internal limiting membrane was also not done either. All patients were followed up for at least 6 months postoperatively.

Measurement of VEGF, sICAM-1, and PEDF

Samples of undiluted vitreous fluid (300–500 μ L) were collected into sterile tubes at the time of surgery and were rapidly frozen at -80°C . Then sICAM-1 and VEGF were measured in vitreous fluid samples as well as in plasma by using enzyme-linked immunosorbent assay (ELISA) kits for human VEGF (R&D Systems, Minneapolis, MN) and sICAM-1 (Bender Med Systems, Burlingame, CA).⁴ PEDF was measured in vitreous and plasma samples with a human PEDF Sandwich ELISA kit (Chemicon International, Temecula, CA).³ The VEGF kit detected two of the four isoforms of VEGF, which were VEGF₁₂₁ and VEGF₁₆₅. Levels of sICAM-1, PEDF, and VEGF in the vitreous fluid were within the detection ranges of the assays, with the minimum detectable concentration being 15.6 pg/mL for VEGF (intra-assay coefficient of variation (CV): 5.5%; interassay CV: 6.9%), 3.3 ng/mL for sICAM-1 (intra-assay CV: 5.4%; interassay CV: 7.6%), and 1.95 ng/mL for PEDF (intra-assay CV: 5.4%; interassay CV: 7.7%).

Statistical analysis

All analyses were performed with SAS software (v. 9.1; SAS Institute Inc, Cary, NC). Data are presented as frequencies or as the mean \pm SD. The paired *t* test was used to compare the retinal thickness and the improvement of BCVA from before surgery until 6 months after surgery. The mean improvement of visual acuity and percent change of macular edema were

compared between patients with and without focal laser coagulation by Student's *t*-test. To investigate the relation between each of the factors that we assessed and the percent change of macular edema, Spearman's rank-order correlation coefficients were calculated. A two-tailed *P* value of <0.05 was taken to indicate statistical significance.

Results

Patient profile

Among the 47 patients, 26 were women and 21 were men. Their mean age was 65.9 ± 9.8 years (range: 43–87 years), and the mean duration of BRVO before surgery was 4.4 ± 1.9 months (range: 3–10 months). A diagnosis of hypertension was based on information from the medical records and was defined as current treatment with antihypertensive drugs or a blood pressure $> 140/90$ mm Hg.¹⁴ A total of 30 of the 47 BRVO patients (63.8%) had hypertension (Table 1).

Changes of visual acuity and foveal thickness after PPV

At the initial examination, mean BCVA was logMAR 0.81 ± 0.42 , and it improved significantly to logMAR 0.52 ± 0.41 by 6 months after PPV ($P < 0.001$) (Table 2). Three patients (6%) showed deterioration of visual acuity, including two with prolonged macular edema after surgery and one with macular atrophy. The initial mean foveal thickness was 587 ± 165 μ m, and it decreased significantly to 278 ± 114 μ m by 6 months after PPV ($P < 0.001$) (Table 2). During surgery, iatrogenic peripheral retinal tears occurred in two eyes, but these were successfully treated by endolaser photocoagulation and sulfur hexafluoride gas tamponade. Postoperatively, neovascular glaucoma did not develop in any of the patients after follow-up for 6 months.

BCVA and vitreous factors

When the improvement of BCVA was calculated by subtracting the postoperative BCVA from the preoperative

Table 1 Baseline clinical features of the BRVO

Findings	BRVO (N = 47)
Age (years)	65.9 ± 9.8^a
Gender (female/male)	26/21
Hypertension	30 (63.8%)
Duration of BRVO (months)	4.4 ± 1.9^a
Focal retinal photocoagulation	11 (23.4%)
Nonperfused area (disk areas)	30.9 ± 34.8^a

Note: ^aMean \pm standard deviation (SD).

Abbreviation: BRVO, branch retinal vein occlusion.

Table 2 Clinical outcome of the patients with BRVO

Variable	Preoperative	6 months	P value
Visual acuity (logMAR)	0.81 ± 0.42 ^a	0.52 ± 0.41 ^a	<0.001
Central macular thickness (µm)	587 ± 165 ^a	278 ± 114 ^a	<0.001

Note: ^aMean ± standard deviation (SD).

Abbreviations: BRVO, branch retinal vein occlusion; logMAR, logarithm of the minimum angle of resolution.

value, there was a significant negative correlation between the vitreous level of VEGF or sICAM-1 and improvement of BCVA. Accordingly, VEGF and sICAM-1 levels were significantly lower in patients who showed more marked improvement of BCVA after vitrectomy ($r = -0.38, P = 0.007$ and $r = -0.36, P = 0.010$, respectively) (Figure 1A, B). In contrast, there was a significant positive correlation between the vitreous level of PEDF and improvement of BCVA, so the PEDF level was significantly higher in patients with more marked improvement of BCVA after vitrectomy ($r = 0.32, P = 0.028$) (Figure 1C). In addition, there was no significant difference in the improvement of BCVA between the patients with or without focal laser coagulation ($P = 0.877$).

Foveal thickness and vitreous factors

Improvement of macular edema was evaluated by calculating the percent change of macular edema (%ΔME) as follows:

$$\% \Delta ME = \frac{ME_{pr} - ME_{po}}{ME_{pr}} \times 100 = \left(1 - \frac{ME_{po}}{ME_{pr}} \right) \times 100$$

where ME_{pr} and ME_{po} correspond to the foveal thickness before vitrectomy and 6 months after surgery, respectively.

As a result, a significant positive correlation was found between the vitreous level of VEGF or sICAM-1 and the percent change of macular edema, so VEGF and sICAM-1 levels were significantly higher in patients with more marked improvement of macular edema after PPV ($r = 0.41, P = 0.004$ and $r = 0.29, P = 0.046$, respectively) (Figure 2A, B). In contrast, there was a significant negative correlation between the vitreous level of PEDF and the percent change of macular edema, meaning that the PEDF level was significantly lower in patients who showed more marked improvement of macular edema ($r = -0.35, P = 0.016$) (Figure 2C). In addition, there was no significant difference in the percent change of macular edema between the patients with or without focal laser coagulation ($P = 0.289$).

Relation between improvement of BCVA and clinical factors

Multiple regression analysis was performed to investigate the influence of the following factors on BCVA: gender, hypertension (present/absent), duration of BRVO (months), nonperfused retinal area (disk areas), cataract surgery (yes/no), retinal photocoagulation (yes/no), serous retinal detachment (present/absent), the vitreous VEGF level, the vitreous sICAM-1 level, and the vitreous PEDF level. It was found that the vitreous fluid levels of sICAM-1 and PEDF were significant independent determinants of the improvement of BCVA ($P = 0.045$ and $P = 0.038$, respectively) (Table 3).

Discussion

The present study showed that the vitreous fluid levels of VEGF and sICAM-1 were significantly higher in BRVO

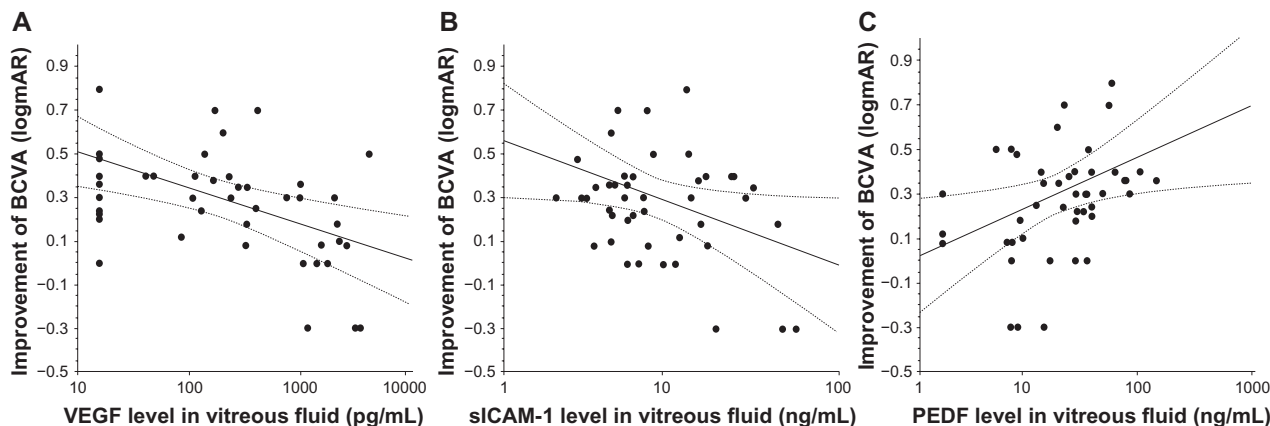


Figure 1 Correlations between vitreous fluid levels of VEGF, sICAM-1, or PEDF and improvement of BCVA. **A)** Significant negative correlation between the vitreous level of VEGF and the improvement of BCVA ($r = -0.38, P = 0.007$). **B)** Significant negative correlation between the vitreous level of sICAM-1 and the improvement of BCVA ($r = -0.36, P = 0.010$). **C)** Significant positive correlation between the vitreous level of PEDF and the improvement of BCVA ($r = 0.32, P = 0.028$).

Abbreviations: VEGF, vascular endothelial growth factor; sICAM-1, soluble intercellular adhesion molecule-1; PEDF, pigment epithelium-derived factor; BCVA, best-corrected visual acuity.

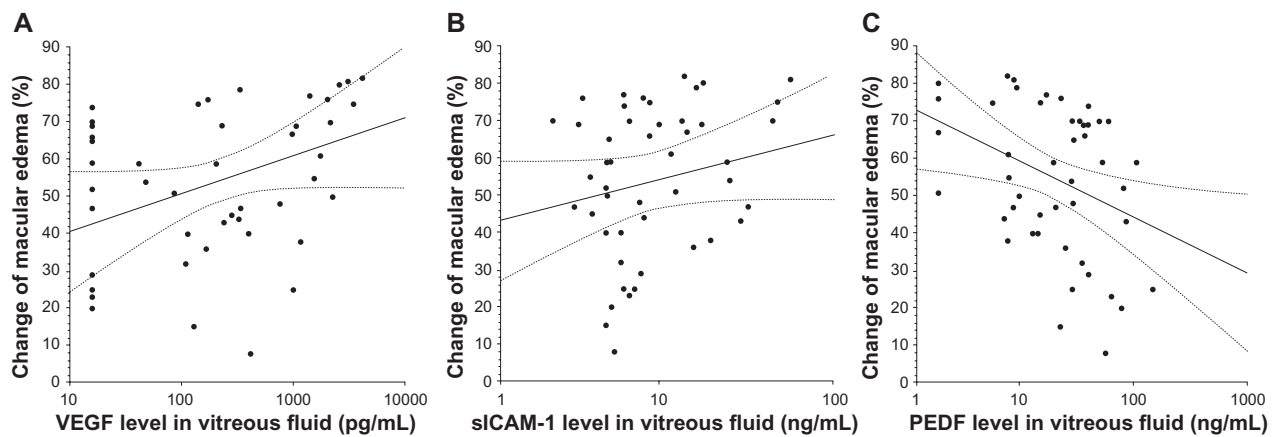


Figure 2 Correlations between vitreous fluid levels of VEGF, sICAM-1, or PEDF and the percent change of macular edema. **A)** Significant positive correlation between the vitreous level of VEGF and the percent change of macular edema ($r = 0.41, P = 0.004$). **B)** Significant positive correlation between the vitreous level of sICAM-1 and the percent change of macular edema ($r = 0.29, P = 0.046$). **C)** Significant negative correlation between the vitreous level of PEDF and the percent change of macular edema ($r = -0.35, P = 0.016$).

Abbreviations: VEGF, vascular endothelial growth factor; sICAM-1, soluble intercellular adhesion molecule-1; PEDF, pigment epithelium-derived factor.

patients with less marked improvement of BCVA after PPV, while the PEDF level was significantly lower in such patients. In addition, vitreous fluid levels of sICAM-1 and PEDF had a significant influence on the visual outcome according to multivariate analysis, although the vitreous VEGF level did not. This may have been because the effect of VEGF was counteracted by that of sICAM-1 due to the strong positive correlation between sICAM-1 and VEGF levels in the vitreous fluid (data not shown). These findings suggest that measurement of these molecules (sICAM-1 and PEDF) in the vitreous fluid may be useful for predicting the visual prognosis after PPV. The macula is a vital part of the retina for detailed vision, especially the fovea that consists entirely of cones.¹⁵ Histopathologic studies have shown that

macular edema is associated with swelling of the Müller cells, especially in the outer plexiform layer of the neurosensory retina.^{16–18} VEGF increases vascular permeability,¹⁹ and VEGF production is upregulated when retinal glial cells are exposed to hypoxia.²⁰ VEGF has also been reported to alter the conformation of tight junctions between retinal vascular endothelial cells.^{21,22} Furthermore, VEGF increases ICAM-1 production by capillary endothelial cells in a dose- and time-dependent manner, while intravitreal injection of VEGF at pathophysiologically relevant concentrations increases ICAM-1 protein and mRNA levels in retinal vessel walls.²³ It has been suggested that VEGF-induced breakdown of the blood–retinal barrier (BRB) partly depends on an interaction with leukocytes, because inhibition of ICAM-1 expression prevents the breakdown of this barrier when VEGF is injected into the eyes of rats,²⁴ while blocking ICAM-1 activity with a neutralizing antibody suppresses both retinal leukostasis and BRB breakdown.²⁴ Thus, VEGF increases ICAM-1 expression by capillary endothelial cells and by cells of the retinal vessels, suggesting that increased VEGF production may lead to upregulation of ICAM-1 expression that promotes adhesion of leukocytes to the retinal vessels in BRVO patients. On the other hand, injection of PEDF into the mice eyes has been shown to prevent an increase of vascular permeability,²⁵ and PEDF has also been reported to inhibit leukostasis related to diabetes or advanced glycation end products by suppressing ICAM-1 production.²⁶ Because VEGF-induced breakdown of the BRB seems to be partly dependent on leukocyte stasis,²⁴ as mentioned above, the present findings suggest that PEDF may ameliorate BRB breakdown and thus prevent an increase of vascular permeability in patients with BRVO. This conclusion is

Table 3 Results of multivariate analysis of factors influencing the improvement of BCVA

Variable	Improvement of BCVA (logMAR)	
	Standard partial regression coefficient	P value
Gender	−0.15	0.354
Hypertension	0.19	0.240
Duration of BRVO (months)	0.21	0.176
Nonperfused retinal area (disk areas)	0.02	0.936
Cataract surgery	0.13	0.398
Retinal photocoagulation	−0.09	0.549
Serous retinal detachment	0.31	0.088
Vitreous VEGF level (pg/mL)	−0.14	0.628
Vitreous sICAM-1 level (ng/mL)	−0.37	0.045
Vitreous PEDF level (ng/mL)	0.39	0.038

Abbreviations: BCVA, best-corrected visual acuity; logMAR, logarithm of the minimum angle of resolution; BRVO, branch retinal vein occlusion; VEGF, vascular endothelial growth factor; sICAM-1, soluble intercellular adhesion molecule-1; PEDF, pigment epithelium-derived factor.

supported by reports that intravitreal injection of PEDF significantly reduces VEGF-induced vascular endothelial hyperpermeability and BRB breakdown in models of diabetic retinopathy.^{27,28} Thus, an increase of both VEGF and sICAM-1 along with a decrease of PEDF may promote the development of macular edema in patients with BRVO, after which macular edema causes deterioration of retinal function and leads to visual impairment.

In the present study, we found that higher VEGF and sICAM-1 levels in the vitreous fluid at the time of PPV were significantly associated with more marked postoperative improvement of macular edema, as was a lower PEDF level. Intravitreal injection of VEGF has been reported to provoke retinal edema, dilated and tortuous retinal vessels, and capillary closure in adult primates,²⁹ while treatment with bevacizumab (a monoclonal anti-VEGF antibody) or ranibizumab (an Fab fragment that binds and neutralizes all isoforms of VEGF-A) improves macular edema in BRVO patients.^{30–32} In addition, an anti-ICAM-1 neutralizing antibody has been reported to suppress both retinal leukostasis and BRB breakdown.²⁴ Therefore, reduction of the vitreous levels of VEGF and sICAM-1 may be one of the mechanisms by which PPV improves macular edema in BRVO patients. In agreement with this hypothesis, we previously found that the vitreous level of VEGF was lower at the time of repeat vitrectomy than at the initial operation in patients with macular edema due to retinal vein occlusion,³³ and it was also reported that PPV prevents retinal hypoxia in patients with BRVO.³⁴ We recently demonstrated that the vitreous fluid level of PEDF has a significant negative correlation with the nonperfused area of the retina.³ Accordingly, expression of PEDF may be upregulated to prevent retinal hypoxia after PPV, and this may be another mechanism by which PPV improves macular edema in BRVO patients.

In agreement with our previous findings,⁵ improvement of BCVA and improvement of macular edema did not occur in parallel in the present study, although the retinal thickness at the central fovea is known to influence visual acuity.^{35,36} In other words, BCVA showed little improvement in some patients even if macular edema was resolved. This discrepancy may have arisen because improvement of BCVA requires longer than the 6-month follow-up period of our study. Alternatively, improvement of BCVA may not occur in some patients after macular edema resolves because of permanent photoreceptor cell damage due to macular ischemia (probably patients who have high levels of VEGF and sICAM-1 and a low PEDF level). It is also possible

that diffuse disorganization of the outer photoreceptor layer beneath the fovea or foveal bleeding could impair visual acuity. However, a larger, prospective, randomized study will be required to clarify the relationship among these vitreous factors and improvement of BCVA or macular edema in patients with BRVO.

In conclusion, the vitreous fluid levels of VEGF and sICAM-1 were significantly lower in BRVO patients who showed more marked improvement of BCVA after vitrectomy, while the PEDF level was significantly higher. Conversely, VEGF and sICAM-1 levels were significantly higher in patients who showed more marked improvement of macular edema after PPV, while the PEDF level was significantly lower. These results suggest that vitreous fluid levels of VEGF, sICAM-1, and PEDF influence the visual prognosis and the response of macular edema to vitrectomy in BRVO patients.

Acknowledgments

Financial support: None.

Disclosure

The authors report no conflicts of interest in this work.

References

1. Michels RG, Gass JD. The natural course of retinal branch vein obstruction. *Trans Am Acad Ophthalmol Otolaryngol.* 1974;78(2): OP166–OP177.
2. Gutman FA, Zegarra H. The natural course of temporal retinal branch vein occlusion. *Trans Am Acad Ophthalmol Otolaryngol.* 1974; 78(2):OP178–OP192.
3. Noma H, Funatsu H, Mimura T, Harino S, Eguchi S, Hori S. Pigment epithelium-derived factor and vascular endothelial growth factor in branch retinal vein occlusion with macular edema. *Graefes Arch Clin Exp Ophthalmol.* 2010;248(11):1559–1565.
4. Noma H, Funatsu H, Mimura T, Shimada K. Increase of aqueous inflammatory factors in macular edema with branch retinal vein occlusion: a case control study. *J Inflamm (Lond).* 2010;7(8):44.
5. Noma H, Funatsu H, Mimura T, Eguchi S, Shimada K. Visual acuity and foveal thickness after vitrectomy for macular edema associated with branch retinal vein occlusion: a case series. *BMC Ophthalmol.* 2010; 10(4):11.
6. The Branch Vein Occlusion Study Group. Argon laser photocoagulation for macular edema in branch vein occlusion. *Am J Ophthalmol.* 1984;98(3):271–282.
7. Otani T, Kishi S. Tomographic assessment of vitreous surgery for diabetic macular edema. *Am J Ophthalmol.* 2000;129(4):487–494.
8. Saika S, Tanaka T, Miyamoto T, Ohnishi Y. Surgical posterior vitreous detachment combined with gas/air tamponade for treating macular edema associated with branch retinal vein occlusion: retinal tomography and visual outcome. *Graefes Arch Clin Exp Ophthalmol.* 2001;239(10):729–732.
9. Battaglia Parodi M, Saviano S, Ravalico G. Grid laser treatment in macular branch retinal vein occlusion. *Graefes Arch Clin Exp Ophthalmol.* 1999;237(12):1024–1027.

10. Noma H, Funatsu H, Yamasaki M, et al. Pathogenesis of macular edema with branch retinal vein occlusion and intraocular levels of vascular endothelial growth factor and interleukin-6. *Am J Ophthalmol*. 2005;140(2):256–261.
11. Noma H, Minamoto A, Funatsu H, et al. Intravitreal levels of vascular endothelial growth factor and interleukin-6 are correlated with macular edema in branch retinal vein occlusion. *Graefes Arch Clin Exp Ophthalmol*. 2006;244(3):309–315.
12. Noma H, Funatsu H, Yamasaki M, et al. Aqueous humour levels of cytokines are correlated to vitreous levels and severity of macular oedema in branch retinal vein occlusion. *Eye (Lond)*. 2008;22(1):424–428.
13. Park SP, Ahn JK, Mun GH. Aqueous vascular endothelial growth factor levels are associated with serous macular detachment secondary to branch retinal vein occlusion. *Retina*. 2010;30(2):281–286.
14. 1999 World Health Organization-International Society of Hypertension Guidelines for the Management of Hypertension. Guidelines Subcommittee. *J Hypertens*. 1999;17(2):151–183.
15. Hogan MJ, Alvarado JA, Weddell JE. *Histology of the Human Eye: An Atlas and Textbook*. Philadelphia, PA: Saunders; 1971:492.
16. Fine BS, Brucker AJ. Macular edema and cystoid macular edema. *Am J Ophthalmol*. 1981;92(4):466–481.
17. Tso MO. Pathology of cystoid macular edema. *Ophthalmology*. 1982;89(8):902–915.
18. Yanoff M, Fine BS, Brucker AJ, Eagle RC Jr. Pathology of human cystoid macular edema. *Surv Ophthalmol*. 1984;28 Suppl:505–511.
19. Dvorak HF, Brown LF, Detmar M, Dvorak AM. Vascular permeability factor/vascular endothelial growth factor, microvascular hyperpermeability, and angiogenesis. *Am J Pathol*. 1995;146(5):1029–1039.
20. Behzadian MA, Wang XL, Al-Shabrawey M, Caldwell RB. Effects of hypoxia on glial cell expression of angiogenesis-regulating factors VEGF and TGF-beta. *Glia*. 1998;24(2):216–225.
21. Viores SA, Derevanik NL, Ozaki H, Okamoto N, Campochiaro PA. Cellular mechanisms of blood-retinal barrier dysfunction in macular edema. *Doc Ophthalmol*. 1999;97(3–4):217–228.
22. Gardner TW, Antonetti DA, Barber AJ, Lieth E, Tarbell JA; Penn State Retina Research Group. The molecular structure and function of the inner blood-retinal barrier. *Doc Ophthalmol*. 1999;97(3–4):229–237.
23. Lu M, Perez VL, Ma N, et al. VEGF increases retinal vascular ICAM-1 expression in vivo. *Invest Ophthalmol Vis Sci*. 1999;40(8):1808–1812.
24. Miyamoto K, Khosrof S, Bursell SE, et al. Prevention of leukostasis and vascular leakage in streptozotocin-induced diabetic retinopathy via intercellular adhesion molecule-1 inhibition. *Proc Natl Acad Sci U S A*. 1999;96(19):10836–10841.
25. Ogata N, Ando A, Uyama M, Matsumura M. Expression of cytokines and transcription factors in photocoagulated human retinal pigment epithelial cells. *Graefes Arch Clin Exp Ophthalmol*. 2001;239(2):87–95.
26. Yamagishi S, Matsui T, Nakamura K, Takeuchi M, Imaizumi T. Pigment epithelium-derived factor (PEDF) prevents diabetes- or advanced glycation end products (AGE)-elicited retinal leukostasis. *Microvasc Res*. 2006;72(1–2):86–90.
27. Liu H, Ren JG, Cooper WL, Hawkins CE, Cowan MR, Tong PY. Identification of the antivasopermeability effect of pigment epithelium-derived factor and its active site. *Proc Natl Acad Sci U S A*. 2004;101(17):6605–6610.
28. Zhang SX, Wang JJ, Gao G, Shao C, Mott R, Ma JX. Pigment epithelium-derived factor (PEDF) is an endogenous antiinflammatory factor. *FASEB J*. 2006;20(2):323–325.
29. Tolentino MJ, Miller JW, Gragoudas ES, et al. Intravitreal injections of vascular endothelial growth factor produce retinal ischemia and microangiopathy in an adult primate. *Ophthalmology*. 1996;103(11):1820–1828.
30. Pai SA, Shetty R, Vijayan PB, et al. Clinical, anatomic, and electrophysiologic evaluation following intravitreal bevacizumab for macular edema in retinal vein occlusion. *Am J Ophthalmol*. 2007;143(4):601–606.
31. Rabena MD, Pieramici DJ, Castellarin AA, Nasir MA, Avery RL. Intravitreal bevacizumab (Avastin) in the treatment of macular edema secondary to branch retinal vein occlusion. *Retina*. 2007;27(4):419–425.
32. Campochiaro PA, Hafiz G, Shah SM, et al. Ranibizumab for macular edema due to retinal vein occlusions: implication of VEGF as a critical stimulator. *Mol Ther*. 2008;16(4):791–799.
33. Noma H, Funatsu H, Mimura T, Hori S. Changes of vascular endothelial growth factor after vitrectomy for macular edema secondary to retinal vein occlusion. *Eur J Ophthalmol*. 2008;18(6):1017–1019.
34. Stefansson E, Novack RL, Hatchell DL. Vitrectomy prevents retinal hypoxia in branch retinal vein occlusion. *Invest Ophthalmol Vis Sci*. 1990;31(2):284–289.
35. Suzuma K, Kita M, Yamana T, et al. Quantitative assessment of macular edema with retinal vein occlusion. *Am J Ophthalmol*. 1998;126(3):409–416.
36. Imasawa M, Iijima H, Morimoto T. Perimetric sensitivity and retinal thickness in eyes with macular edema resulting from branch retinal vein occlusion. *Am J Ophthalmol*. 2001;131(1):55–60.

Clinical Ophthalmology

Publish your work in this journal

Clinical Ophthalmology is an international, peer-reviewed journal covering all subspecialties within ophthalmology. Key topics include: Optometry; Visual science; Pharmacology and drug therapy in eye diseases; Basic Sciences; Primary and Secondary eye care; Patient Safety and Quality of Care Improvements. This journal is indexed on PubMed

Submit your manuscript here: <http://www.dovepress.com/clinical-ophthalmology-journal>

Dovepress

Central and CAS, and is the official journal of The Society of Clinical Ophthalmology (SCO). The manuscript management system is completely online and includes a very quick and fair peer-review system, which is all easy to use. Visit <http://www.dovepress.com/testimonials.php> to read real quotes from published authors.