

A rare case of Ewing sarcoma metastasis to the oral cavity

Riéli Elis Schulz¹, Matheus Henrique Alves de Lima¹, Rodrigo Nascimento Lopes¹,
Clovis Antonio Lopes Pinto², Ulisses Ribaldo Nicolau³, Juliane Piragine Araujo^{1,*}

¹Department of Stomatology, A.C. Camargo Cancer Center, São Paulo, SP, Brazil

²Department of Anatomic Pathology, A.C. Camargo Cancer Center, São Paulo, SP, Brazil

³Department of Oncology, A.C. Camargo Cancer Center, São Paulo, SP, Brazil

ABSTRACT

Ewing sarcoma in the head and neck is rare, and metastasis from other bones to the mandible accounts for 0.7% of cases. This report presents a case of oral metastasis in a 24-year-old male patient diagnosed with Ewing sarcoma of the femur (p53 gene mutation and *EWSRI-ERG* fusion). The chief complaint was numbness in the mandible and pain for 1 month and a hardened, ulcerated exophytic lesion in the right retromolar region. Imaging exams revealed an unspecified thinning of the cortical bone of the inferior alveolar canal in the right mandibular ramus, associated with erosion of the alveolar bone. Histopathological analysis confirmed metastasis of Ewing sarcoma. The patient presented an aggressive disease progression and died 1 month after the oral diagnosis. It is important to recognize the signs and symptoms compatible with rare clinical outcomes, leading to an early diagnosis that can improve patients' quality of life and survival. (*Imaging Sci Dent 2021; 51: 217-22*)

KEY WORDS: Sarcoma, Ewing; Neoplasm Metastasis; Mandible; Hypesthesia

Introduction

Ewing sarcoma was first described by James Ewing in 1921 as a tumor originating from the undifferentiated vascular component of bone; the disease was classified as diffuse endothelioma of bone. The pathogenesis of Ewing sarcoma is not well established,¹ but it is suspected to arise from stem cells, progenitor mesenchymal cells, and neuroectodermal cells.^{2,3}

The Ewing sarcoma family of tumors includes extrasosseous Ewing sarcoma, peripheral primitive neuroectodermal tumor, malignant small-cell tumor of the thoracic pulmonary region (Askin tumor), atypical Ewing sarcoma (large-cell variant) and classic Ewing sarcoma (poorly differentiated, small, blue round-cell tumors). These tumors are considered to be derived from the same cellular origins.⁴

Ewing sarcoma is a rare malignancy that comprises 4%

to 15% of all primary bone tumors. It is the fourth most common bone malignancy after myeloma, osteosarcoma, and chondrosarcoma and also the second most frequent primary bone cancer in infancy and childhood after osteosarcoma, representing 1% of all malignant tumors in children.^{5,6} Ewing sarcoma may occur in any bone; the most frequent locations are the long bones (58%), pelvis (20%) and ribs (7%).⁷ The mandible accounts for 0.7% of all sites and is more frequently affected than the maxilla.^{7,8}

Ewing sarcoma is characterized by rapid growth and a tendency for metastasis to distant organs, mainly the lungs and bones. Thus, mandibular involvement may occur due to rare metastasis from another bone site.^{9,10} The related signs and symptoms are swelling, pain, and paresthesia.¹¹ The aim of this report was to present a case of metastatic Ewing sarcoma to the mandibular ramus, with paresthesia as the first symptom described.

Case Report

A 24-year-old male patient was referred to the Depart-

Received November 27, 2020; Revised December 31, 2020; Accepted January 14, 2021

*Correspondence to : Dr. Juliane Piragine Araujo

Department of Stomatology, A.C. Camargo Cancer Center, Rua Prof. Antônio Prudente, 211 Liberdade, São Paulo, SP, Brazil

Tel) 55-11-21895129, E-mail) juliane.piragine@accamargo.org.br

Copyright © 2021 by Korean Academy of Oral and Maxillofacial Radiology

This is an Open Access article distributed under the terms of the Creative Commons Attribution Non-Commercial License (<http://creativecommons.org/licenses/by-nc/3.0>) which permits unrestricted non-commercial use, distribution, and reproduction in any medium, provided the original work is properly cited.

Imaging Science in Dentistry · pISSN 2233-7822 eISSN 2233-7830

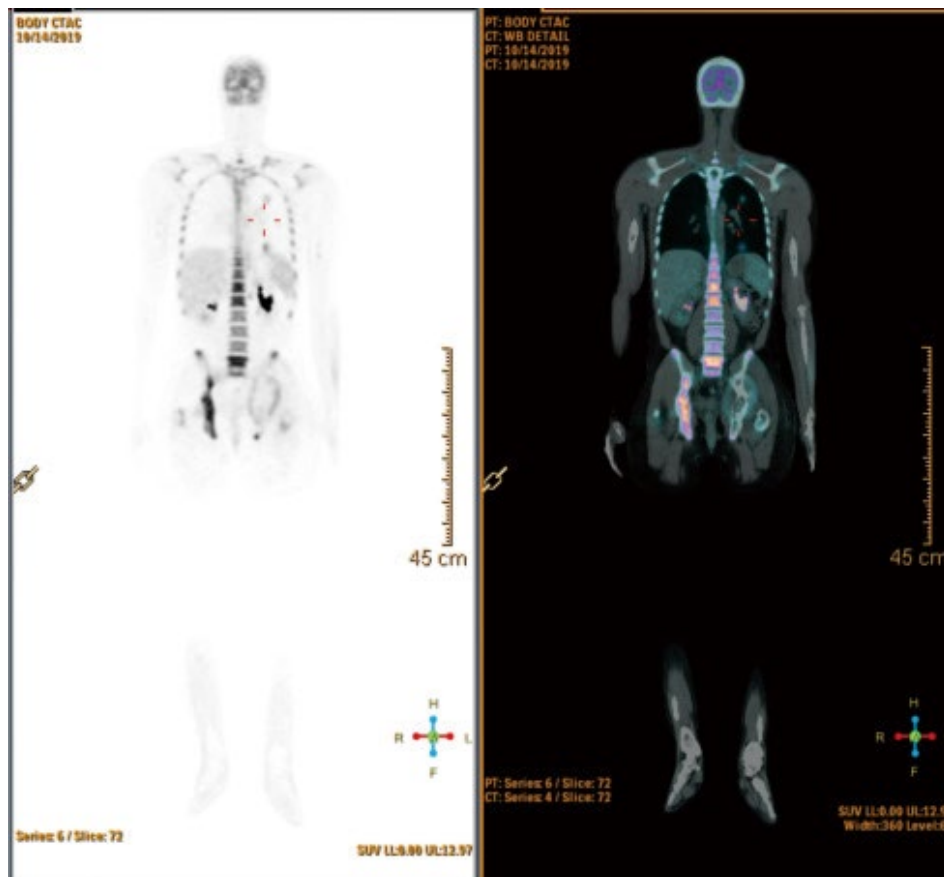


Fig. 1. Positron emission tomography-computed tomography images show signs of neoplastic activity on the spine and acetabulum, in addition to pulmonary nodules.

ment of Stomatology complaining of numbness in the right mandibular bone, associated with a swelling sensation on the lower lip and pain for the last 4 weeks.

The anamnesis revealed his oncological history: Two years ago an Ewing sarcoma in the right distal femur metaphysis was diagnosed. The patient underwent surgery, with perioperative chemotherapy (CHT) and radiotherapy (RTD). The treatment consisted of 6 cycles of CHT, comprising 4 cycles of VAC (vincristine, dactinomycin, and cyclophosphamide) interspersed with 2 cycles of ifosfamide and etoposide. Due to the partial response of the tumor, the patient was referred for RTD and received 31 sessions (55.8 Gy). At the end of this treatment, a new finding was observed, a 3-mm pulmonary nodule, and the patient underwent 9 cycles of the same CHT protocol.

One year later, the patient was diagnosed with metastasis in the spine and acetabulum, in addition to others pulmonary nodules. The diagnosis of a metastatic tumor led to palliative systemic therapy with a CHT combination of temozolomide and irinotecan. Moreover, the patient underwent palliative radiotherapy (25 Gy in 5 sessions) capturing all lesions shown on positron emission tomography-computed tomography (PET-CT) (multiple solid pulmonary nodules, right

clavicle, the T3 vertebra, spinous process of the L3 vertebra, the iliac wing, acetabulum, and ischium, with associated soft tissue components). Six months later, second-line CHT treatment was started, with docetaxel and gemcitabine, and the patient presented disease progression after the third CHT cycle.

Two months later, another PET-CT examination (Fig. 1) was performed and persistent signs of neoplastic activity were observed, with the emergence of new pulmonary nodules and detection of increased dimensions of the nodules and higher standardized uptake values than those on previous imaging. Moreover, new periprosthetic lesions in the right femur and intramedullary lesions in the left lower limb were identified when compared to the previous exam.

Before a proposing a third line of CHT, the possibility was discussed of examining a tumor specimen with next-generation sequencing. The tumoral sequencing findings were compatible with Ewing sarcoma breakpoint region 1-ETS-related gene (*EWSRI-ERG*) fusion transcripts, which yielded no additional information for a specific therapeutic approach. Five months later, a third line of CHT was proposed (dacarbazine monotherapy) and 1 month later, PET-CT showed local recurrence in the right distal femur and proxi-

mal tibia, simultaneously with the onset of the oral lesion.

On an intraoral examination, a hardened ulcerated exophytic lesion was observed in the right retromolar area (Fig. 2). Based on the patient's clinical features and oncological history, the diagnostic hypothesis of Ewing sarcoma metastasis to the oral cavity was established.

Panoramic radiography and computed tomography (CT) images revealed thinning of the upper cortical bone around the alveolar nerve located on the distal second molar and cortical erosion of the alveolar bone (Fig. 3). An incisional biopsy was performed on the distal and buccal gingiva next to the mandibular right second molar. The histopathological analysis confirmed the diagnosis of Ewing sarcoma metastasis (Fig. 4). Reverse transcription polymerase chain reaction (PCR) analysis identified an *EWSRI-ERG* fusion transcript.

The patient's pulmonary condition worsened during the coronavirus disease 2019 (COVID-19) pandemic. Two chest CT scans were performed, with worsening ground-glass opacities. Two PCR tests were performed for severe acute respiratory syndrome coronavirus 2 (SARS-CoV-2) and both were negative. The patient presented a rapid and aggressive disease progression and died of pulmonary failure attributed to tumor-associated complications in the intensive care unit 1 month after the oral metastasis was diagnosed.

Discussion

Reports of Ewing sarcoma in the jaws are uncommon; Margaix-Muñoz et al.⁹ presented 71 cases of Ewing sarcoma

in the oral cavity in the English-language literature from January 1960 to June 2014, of which only 6 (8.5%) corresponded to oral metastasis from other sites. The mandible is most frequently affected, accounting for 68% of cases in the head and neck region. Moreover, Gupta et al.¹² described 65 cases of primary sarcoma of the jaws, of which 70.7% affected the mandible, with a predilection for the ascending ramus. The location of Ewing sarcoma metastasis in this

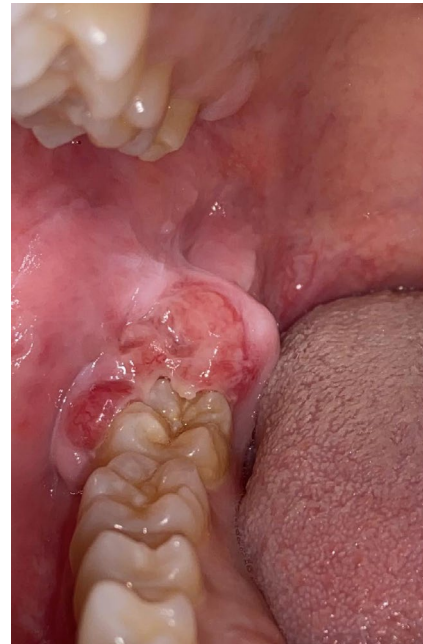

Fig. 2. Intraoral photograph shows a hardened, ulcerated, exophytic lesion in the right retromolar area.

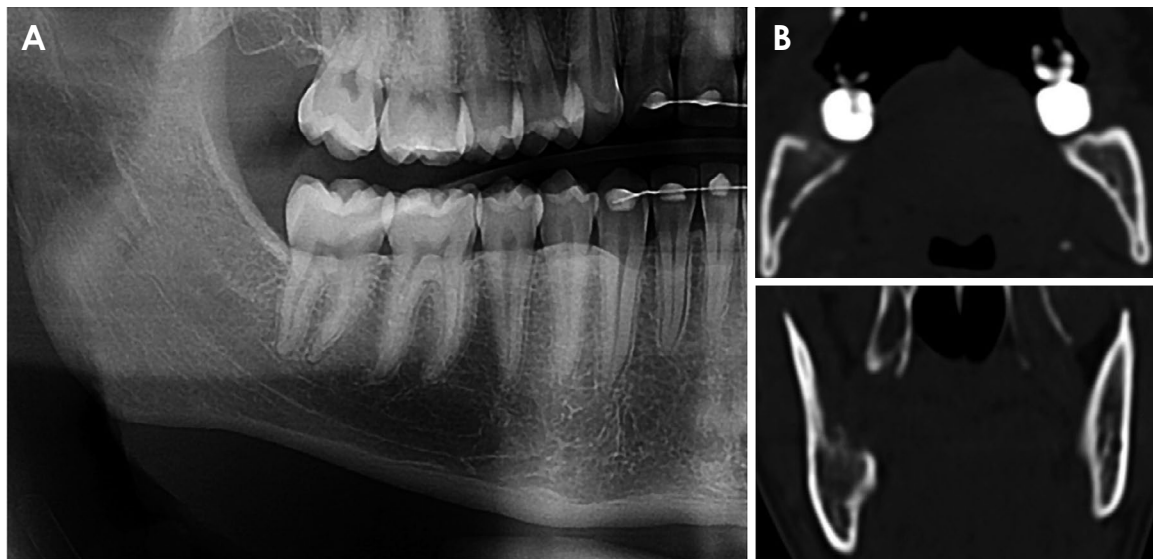


Fig. 3. A. A cropped panoramic radiograph reveals thinning of the upper cortical bone around the alveolar nerve located distal to the second molar. B. Computed tomographic images reveal an irregular cortical erosion of the alveolar bone distal to the second molar.

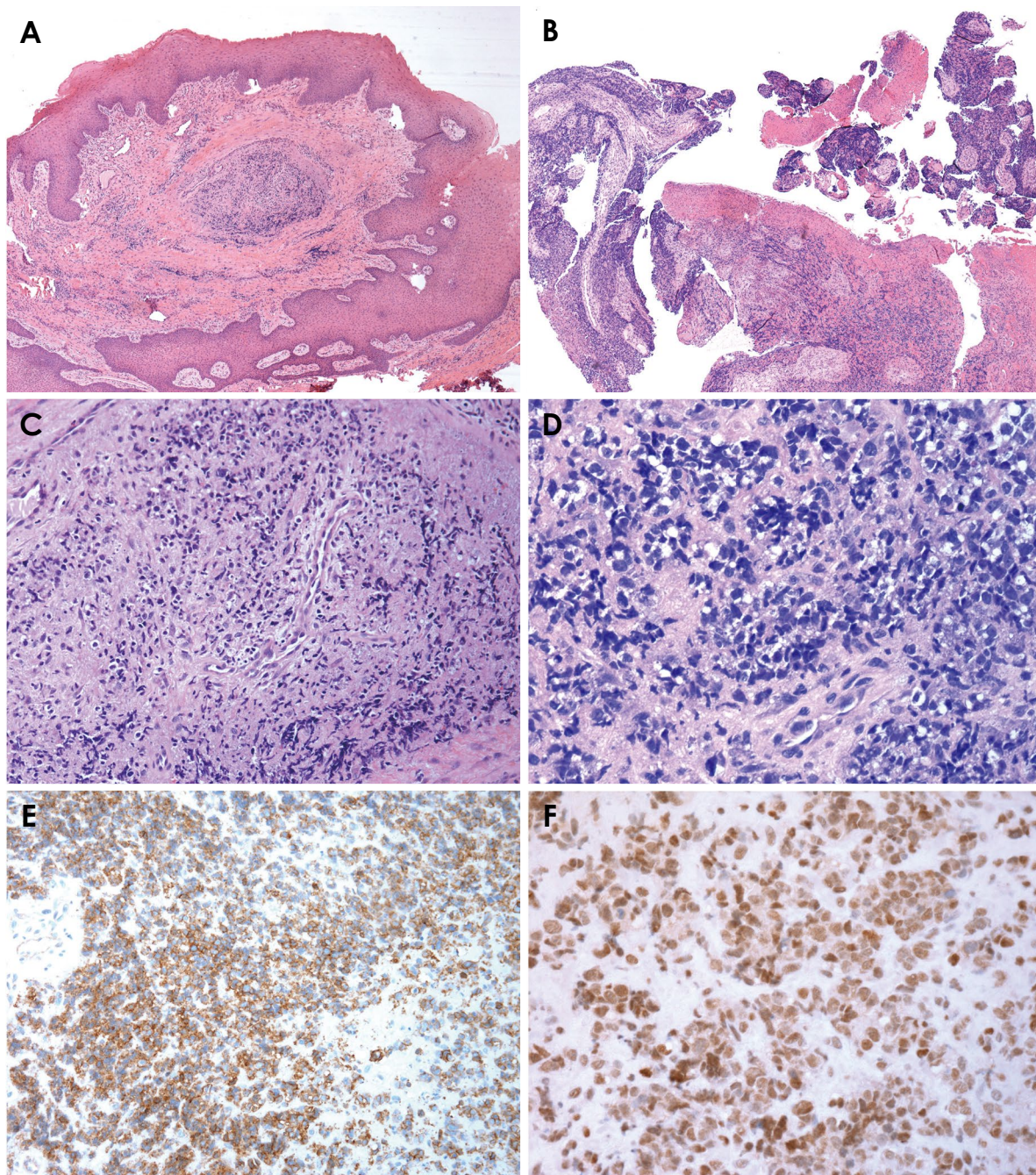


Fig. 4. A. Histological section shows squamous mucosa with epithelial hyperplasia and a cluster of cells in the stroma (H&E stain, ×40). B. Histological section demonstrates an area of ulceration with proliferation of basophilic cells (H&E stain, ×40). C and D. Histological sections shows a neoplasm characterized by round cells, small and blue with little cytoplasm, corresponding to metastasis of Ewing sarcoma (H&E stain, C: ×40, D: ×200). E. Immunohistochemistry photomicroscopy shows cytoplasmic and diffuse expression in neoplastic cells of Ewing sarcoma (CD99 stain, ×200). F. Immunohistochemistry photomicroscopy shows nuclear and diffuse expression in neoplastic cells of Ewing sarcoma (FLI-1 stain, ×400).

case is in accordance with the literature.

The signs and symptoms are nonspecific and could be misdiagnosed as dental infections, such as swelling, paresthesia, and pain.¹³ In the present case, the chief complaint

was paresthesia in the lower lip and chin for a month, followed by pain. Known as numb chin syndrome, unilateral numbness of the chin and lower lip can be an important complaint in cancer patients. This symptom is associated with

tumor progression, metastatic disease to the mandible, tumoral invasion of the inferior alveolar nerve, or a disseminated leptomeningeal tumor.¹⁴

Clinically, a soft tissue component of the tumor and ulcerated tissue can be observed,¹⁵ as in the present case. In addition, Margaix-Muñoz et al.⁹ reported that dental infections and periodontal inflammation were the main differential diagnoses of Ewing sarcoma. The literature contains a case, in which the patient was first diagnosed with pericoronitis.¹⁶ In the present study, if the patient had no history of Ewing sarcoma, a diagnostic hypothesis would be an inflammatory infection due to the location (retromolar area) and the condition could be misdiagnosed as pericoronitis or periodontal inflammation.

The radiological features of primary Ewing sarcoma are permeative bone destruction, with the possibility of accentuated displacement of teeth, cortical erosion, a soft tissue mass adjacent to bony destruction, and a widened periodontal ligament space.¹⁵ The tumor is predominantly radio-transparent, with poorly defined limits and no peripheral sclerotic reaction. Some sporadic cases have described a radiopaque or mixed pattern, with a well-defined contour.⁹ In this case, panoramic radiography revealed thinning of upper cortical bone around the alveolar nerve and cortical erosion of alveolar bone; furthermore, there was no tooth displacement or mobility.

Multimodal therapy for nonmetastatic Ewing sarcoma consists of an aggressive combination of surgery, perioperative CHT, and localized RTD. Ewing sarcoma has a poor prognosis due to its hematogenous spread and the occurrence of pulmonary metastases, often occurring a few months after diagnosis.¹⁷ In the present case, the patient had pulmonary and bone metastases and had received several treatment modalities, including surgery, CHT, and palliative RTD.

In the present case, the patient did not respond well to treatment with CHT. According to the literature, this mutation is unusual in Ewing sarcoma and may alter the response to treatment.¹⁸ Huang et al.¹⁸ reported that p53 gene mutations were present in 8 patients (13.3%) out of 60 with Ewing sarcoma. Mutations in the p53 gene or p16/p14ARF were found in a fourth of Ewing sarcoma cases and define a subset with highly aggressive behavior, poor response to CHT, and high mortality (with a survival of 2 years). The patient described herein died 2 years and 5 months after the initial diagnosis, and the p53 gene mutation was an important independent prognostic factor.

At the molecular level, 90% to 95% of Ewing sarcoma cases present the same genetic alteration process, which is a

chromosomal translocation t(11;22)(q24;q12), fusing the *EWSRI* gene to friend leukemia integration locus-1 (*FLII*) or *EWSERG* (5% to 10%) due to a variant translocation with the *ERG* gene at 21q22.¹⁹ This case fell within that small percentage of genetic alterations. Recent studies have suggested that the type of fusion transcript may affect the prognosis, with the presence of the *EWS-FLII* type 1 fusion transcript associated with a better result than other types of fusion transcripts.²⁰

It is important to recognize signs and symptoms compatible with unusual metastatic tumor dissemination. Idiopathic numbness in the region of the lower alveolar nerve may indicate metastasis to the oral cavity, and recognition of this possibility may facilitate diagnostic investigations. An early diagnosis is necessary to improve the patient's quality of life and survival.

Conflicts of interest: None

References

1. Hajdu SI. The enigma of Ewing's sarcoma. *Ann Clin Lab Sci* 2006; 36: 108-10.
2. Arndt CA, Rose PS, Folpe AL, Laack NN. Common musculoskeletal tumors of childhood and adolescence. *Mayo Clin Proc* 2012; 87: 475-87.
3. Grier HE. The Ewing family of tumors. Ewing's sarcoma and primitive neuroectodermal tumors. *Pediatr Clin North Am* 1997; 44: 991-1004.
4. Jedlicka P. Ewing sarcoma, an enigmatic malignancy of likely progenitor cell origin, driven by transcription factor oncogenic fusions. *Int J Clin Exp Pathol* 2010; 3: 338-47.
5. Wood RE, Nortje CJ, Hesselting P, Grotepass F. Ewing's tumor of the jaw. *Oral Surg Oral Med Oral Pathol* 1990; 69: 120-7.
6. Esiashvili N, Goodman M, Marcus RB Jr. Changes in incidence and survival of Ewing sarcoma patients over the past 3 decades: Surveillance Epidemiology and End Results Data. *J Pediatr Hematol Oncol* 2008; 30: 425-30.
7. Gorospe L, Fernández-Gil MÁ, García-Raya P, Royo A, López-Barea F, García-Miguel P. Ewing's sarcoma of the mandible: radiologic features with emphasis on magnetic resonance appearance. *Oral Surg Oral Med Oral Pathol Oral Radiol Endod* 2001; 91: 728-34.
8. Qureshi SS, Bhagat M, Laskar S, Kembhavi S, Vora T, Ramadwar M, et al. Local therapy in non-metastatic primary Ewing sarcoma of the mandible and maxilla in children. *Int J Oral Maxillofac Surg* 2016; 45: 938-44.
9. Margaix-Muñoz M, Bagán J, Poveda-Roda R. Ewing sarcoma of the oral cavity. A review. *J Clin Exp Dent* 2017; 9: e294-301.
10. Oliveira SV, Fernandes LG, Soares LA Jr, Moraes MF, Almeida MT, Pinto DS Jr, et al. Mandible Ewing sarcoma in a child: clinical, radiographic and diagnosis considerations. *Oral Oncol* 2019; 98: 171-3.
11. Wang CL, Yacobi R, Pharoah M, Thorner P. Ewing's sarcoma:

- metastatic tumor to the jaw. *Oral Surg Oral Med Oral Pathol* 1991; 71: 597-602.
12. Gupta S, Gupta OP, Mehrotra S, Mehrotra D. Ewing sarcoma of the maxilla: a rare presentation. *Quintessence Int* 2009; 40: 135-40.
 13. Balkaya E, Bozkurt C, Aksu AE, Özmen S, Özdemir Sİ, Şahin G. Ewing's sarcoma of the mandible misdiagnosed as periodontal inflammation: report of three cases. *Turk J Pediatr* 2017; 59: 704-7.
 14. Lossos A, Siegal T. Numb chin syndrome in cancer patients: etiology, response to treatment, and prognostic significance. *Neurology* 1992; 42: 1181-4.
 15. de Santos LA, Jing BS. Radiographic findings of Ewing's sarcoma of the jaws. *Br J Radiol* 1978; 51: 682-7.
 16. Takami Y, Aga F, Mitamura K, Norikane T, Okuda H, Yamamoto Y, et al. A case of Ewing sarcoma of the mandible on ¹⁸F-FDG PET/CT. *Asia Ocean J Nucl Med Biol* 2020; 8: 84-7.
 17. Yogesh T, Shetty A, Keswani H, Rishi D. Aggressive high-grade Ewing's sarcoma of maxilla: a rare case report. *J Oral Maxillofac Pathol* 2018; 22 (Suppl 1): S48-53.
 18. Huang HY, Illei PB, Zhao Z, Mazumdar M, Huvos AG, Healey JH, et al. Ewing sarcomas with p53 mutation or p16/p14ARF homozygous deletion: a highly lethal subset associated with poor chemoresponse. *J Clin Oncol* 2005; 23: 548-58.
 19. Zucman J, Delattre O, Desmaze C, Plougastel B, Joubert I, Melot T, et al. Cloning and characterization of the Ewing's sarcoma and peripheral neuroepithelioma t(11;22) translocation breakpoints. *Genes Chromosomes Cancer* 1992; 5: 271-7.
 20. Zoubek A, Dockhorn-Dworniczak B, Delattre O, Christiansen H, Niggli F, Gatterer-Menz I, et al. Does expression of different EWS chimeric transcripts define clinically distinct risk groups of Ewing tumor patients? *J Clin Oncol* 1996; 14: 1245-51.