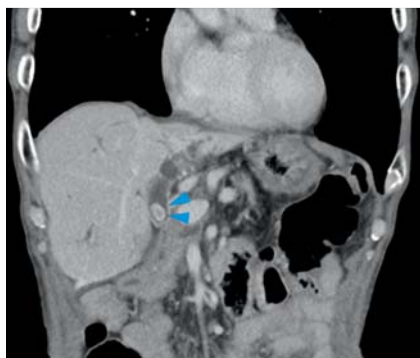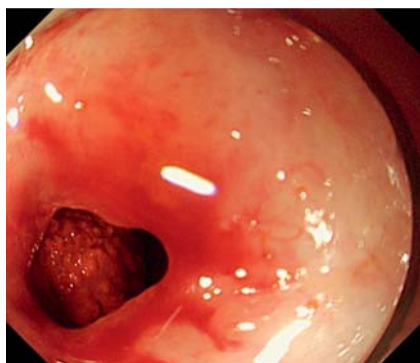


Electrohydraulic lithotripsy for a large biliary stone at a hepaticojejunal anastomosis site by refluxing water from a contrast catheter ▶

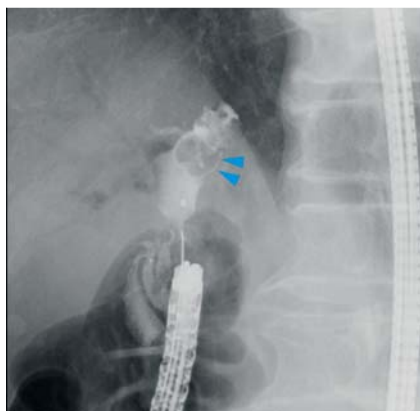OPEN
ACCESS



▶ **Fig. 1** A large biliary stone (arrows) in the hepaticojejunal anastomosis site.



▶ **Fig. 2** The anastomosis could be observed using a single-balloon enteroscope; when opened, the stone was directly visible.



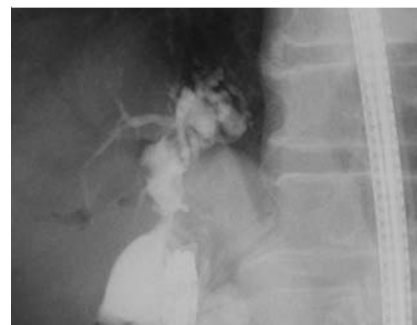
▶ **Fig. 3** Cholangiography revealed a large stone in the left bile duct (arrows).



▶ **Fig. 4** An EHL probe was inserted into a contrast catheter, and EHL was performed with continuous water flow through the catheter.

Electrohydraulic lithotripsy (EHL) is used to remove huge bile duct stones [1, 2]. The treatment of biliary stones after hepaticojejunostomy is often performed using a balloon enteroscope, which proves to be difficult in many cases. Recently, direct insertion of a peroral cholangioscope (POCS) into the bile duct using a balloon endoscope to perform EHL has been reported [3, 4]. However, hepaticojejunal anastomoses are anatomical sites where fluids do not easily accumulate, often making EHL challenging.

The patient, an 81-year-old man, had undergone pancreaticoduodenectomy for pancreatic cancer 10 years prior. He developed a huge stone at the hepaticojejunal anastomosis site and was admitted for stone removal (▶ **Fig. 1**). Because the afferent loop was too long for the colonoscope to reach the anastomosis, a short single-balloon enteroscope (SIF-H290S; Olympus, Japan) was used to reach the hepaticojejunal anastomosis site. When the anastomosis was opened without balloon dilation, the stone was directly visible (▶ **Fig. 2**, ▶ **Fig. 3**). The usual process of stone removal via lithotripsy was attempted, but the stone was difficult to remove. Therefore, we decided to remove it using EHL. However, inserting the POCS directly or the balloon enteroscope itself into the bile duct was difficult.



▶ **Fig. 5** After stone removal, cholangiogram showed that the stones were removed and no coarse stones were identified.

Instead, an EHL probe was inserted into a contrast catheter (MTW ERCP catheter, MTW, Germany) and lithotripsy by EHL was performed with continuous water flow through the catheter (▶ **Fig. 4**). The stone was crushed by EHL and removed using a lithotripsy basket catheter (▶ **Video 1** and ▶ **Fig. 5**).


As shown, this method can effectively remove large stones as EHL can be performed with continuous water flow from the catheter, even when maintaining fluid in the bile duct is difficult. In addition, because an EHL probe can only be inserted into the catheter, it is considered very easy to crush bile duct stones that are directly in visual range.

VIDEO

Case

The patient was an 81-year-old male who had undergone pancreatoduodenectomy for pancreatic cancer 10 years prior. He developed a huge stone at the hepaticojejunal anastomosis site and was admitted for stone removal.

WBC	8200/μl	373IU*	16.2mg/dl
RBC	349 × 10 ⁴ /μl		1.03mg/dl
Hb	8.7g/dl	γ-GTP 540IU/L	Amy 85IU/L
Plt	16.5 × 10 ⁴ /μl	ALP 335IU/L	LDH 374IU/L
PT-INR	1.04	T-Bil 1.1mg/dl	CRP 0.19mg/dl
D-dimer	6μg/ml	D-Bil 0.67mg/dl	



► **Video 1** EHL using a contrast catheter for a large biliary stone at a hepaticojejunal anastomosis site. An EHL probe was inserted into the contrast catheter and EHL was performed while refluxing water through the catheter. EHL was performed by endoscopic observation to confirm crushing of the bile duct stones. Thereafter, the stones were removed using a basket catheter.

Competing interests

The authors declare that they have no conflict of interest.

The authors

Naosuke Kuraoka¹  **Tetsuro Ujihara¹,**
Shun Sakai¹, Satoru Hashimoto¹

¹ Department of Gastroenterology, Saiseikai Kawaguchi General Hospital, Saitama, Japan

Corresponding author

Naosuke Kuraoka, MD, PhD
Department of Gastroenterology, Saiseikai Kawaguchi General Hospital, 5-11-6 Nishikawaguchi, Kawaguchi, Saitama, 332-8558, Japan
Fax: +81-48-256-5703
kuraoka0926@gmail.com

References

- [1] Veld JV, van Huijgevoort NCM, Boermeester MA et al. A systematic review of advanced endoscopy-assisted lithotripsy for retained biliary tract stones: laser, electrohydraulic or extracorporeal shock wave. *Endoscopy* 2018; 50: 896–909
- [2] Yasuda I, Itoi T. Recent advances in endoscopic management of difficult bile duct stones. *Dig Endosc* 2013; 25: 376–385
- [3] Tonozuka R, Itoi T, Sofuni A et al. Novel peroral direct digital cholangioscopy-assisted lithotripsy using a monorail technique through the overtube in patients with surgically altered anatomy (with video). *Dig Endosc* 2019; 31: 203–208
- [4] Atalla H, Sakai A, Shiomi H et al. Overtube-guided electrohydraulic lithotripsy through digital cholangioscopy for difficult biliary stones in a postoperative patient: challenging points with salvage techniques. *Video. VideoGIE. GIE Publishing* 2021; 6: 19–21

Bibliography

Endosc Int Open 2023; 11: E466–E467

DOI 10.1055/a-2041-2779

ISSN 2364-3722

© 2023. The Author(s).

This is an open access article published by Thieme under the terms of the Creative Commons Attribution-NonDerivative-NonCommercial License, permitting copying and reproduction so long as the original work is given appropriate credit. Contents may not be used for commercial purposes, or adapted, remixed, transformed or built upon. (<https://creativecommons.org/licenses/by-nc-nd/4.0/>)

Georg Thieme Verlag KG, Rüdigerstraße 14, 70469 Stuttgart, Germany

