

OPEN

Patient Pain Sketches Can Predict Surgical Outcomes in Trigger-Site Deactivation Surgery for Headaches

Lisa Gfrerer, M.D., Ph.D.
 Marek A. Hansdorfer, M.D.
 Ricardo Ortiz, M.D.
 Kassandra P. Nealon, B.Sc.
 Christian Chartier
 Gem G. Runyan, M.S.
 Samuel D. Zarfos, B.A.
 William Gerald Austen, Jr.,
 M.D.
 Boston, Mass.

PATIENT
SAFETY



Background: Patient selection for headache surgery is an important variable to ensure successful outcomes. In the authors' experience, a valuable method to visualize pain/trigger sites is to ask patients to draw their pain. The authors have found that there are pathognomonic pain patterns for each site, and typically do not operate on patients with atypical pain sketches, as they believe such patients are poor surgical candidates. However, a small subset of these atypical patients undergo surgery based on other strong clinical findings. In this study, the authors attempt to quantify this clinical experience.

Methods: Patients were prospectively enrolled and completed pain sketches at screening. One hundred six diagrams were analyzed/categorized by two independent, blinded reviewers as follows: (1) typical (pain over nerve distribution, expected radiation); (2) intermediate (pain over nerve distribution, atypical radiation); or (3) atypical (pain outside of normal nerve distribution, atypical radiation). Preoperative and postoperative Migraine Headache Index was compared between subgroups using unpaired *t* tests.

Results: Migraine Headache Index improvement was 73 ± 38 percent in the typical group, 78 ± 30 percent in the intermediate group, and 30 ± 40 percent in the atypical group. There was a significant difference in Migraine Headache Index between the typical and atypical groups ($p = 0.03$) and between the intermediate and atypical groups ($p < 0.01$). The chance of achieving Migraine Headache Index improvement greater than 30 percent in the atypical group was 20 percent.

Conclusions: Patient pain sketches classified as atypical (facial pain, atypical pain point origin, diffuse pain) can predict poor outcomes in headache surgery. As the authors continue to develop patient selection criteria for headache surgery, patient sketches should be considered as an effective, cheap, and simple-to-interpret tool for selecting candidates for surgery. (*Plast. Reconstr. Surg.* 146: 863, 2020.)

From the Division of Plastic and Reconstructive Surgery, Massachusetts General Hospital, Harvard Medical School. Received for publication September 9, 2019; accepted April 24, 2020.

Presented at the 64th Annual Meeting of the Plastic Surgery Research Council, in Baltimore, Maryland, May 2 through 5, 2019; Plastic Surgery The Meeting 2019, 88th Annual Meeting of the American Society of Plastic Surgeons, in San Diego, California, September 20 through 23, 2019; and the American Society for Peripheral Nerve Annual Meeting, in Palm Desert, California, February 1 through 3, 2019.

Copyright © The Author(s). Published by Wolters Kluwer Health, Inc. on behalf of the American Society of Plastic Surgeons. This is an open-access article distributed under the terms of the Creative Commons Attribution-Non Commercial-No Derivatives License 4.0 (CCBY-NC-ND), where it is permissible to download and share the work provided it is properly cited. The work cannot be changed in any way or used commercially without permission from the journal.

DOI: 10.1097/PRS.0000000000007162

Trigger-site deactivation surgery has evolved as an effective method to alleviate pain in patients suffering from refractory headaches.¹⁻³ Successful surgery heavily relies on selection of appropriate

Disclosure: The authors have no financial interest to declare in relation to the content of this article.

Related digital media are available in the full-text version of the article on www.PRSJournal.com.

By reading this article, you are entitled to claim one (1) hour of Category 2 Patient Safety Credit. ASPS members can claim this credit by logging in to PlasticSurgery.org Dashboard, clicking "Submit CME," and completing the form.

candidates and identification of all trigger sites.⁴⁻⁶ Several different screening tools including headache history, physical examination, validated questionnaires, and imaging studies are available to aid in choosing suitable candidates. However, verbal communication with the patient and written information in the form of questionnaires often do not accurately reflect complex pain patterns. In our experience, pain sketches that depict where the pain starts and to where it radiates are a superior patient-reported method of visualizing pain and identifying trigger sites.

Pain sketches have been used as an easy and inexpensive tool to illustrate pain in different acute and chronic conditions.^{7,8} Furthermore, clinical outcomes research in patients undergoing spine surgery has demonstrated that pain sketches predict surgical outcomes for lumbar radiculopathy.^{9,10}

In our headache patient population, we have found that there are pathognomonic pain sketch patterns for each trigger site that correspond with the anatomical location of affected nerves. Typically, we do not operate on patients with abnormal pain sketches, because in our experience they are not good candidates for surgery and do not display good outcomes after surgery. Only a small group of patients with abnormal patterns have undergone surgery if there were other strong clinical indications that surgery could be beneficial. This study describes the different pain patterns headache patients present with and investigates whether pain pattern sketches can predict surgical outcomes following trigger-site deactivation surgery.

PATIENTS AND METHODS

The Massachusetts General Hospital Institutional Review Board approved this study. Patients who presented to the senior author's (W.G.A.) outpatient clinic were prospectively enrolled in a Research Electronic Data Capture database. All patients were diagnosed with either migraine headache, headache, or occipital neuralgia by a neurologist and had failed conservative management before presentation. Patients were instructed to draw a preoperative pain sketch at screening. (See **Figure, Supplemental Digital Content 1**, which shows pain sketch blank form, <http://links.lww.com/PRS/E195>.) Patients drew where the pain originates in black or as a cross/dot, and where the pain radiates (if radiating pain is present) in a different color, or with lines/arrows. Patients who did not complete a screening pain sketch or did not have at least 1-year follow-up were excluded. One hundred six patients met inclusion criteria. Patients subsequently completed preoperative and postoperative (at 3, 12, and

24 months) Migraine Headache Index questionnaires to evaluate surgical outcomes. The Migraine Headache Index is calculated by multiplying headache frequency (days per month) by headache duration (as a fraction of 24 hours) by headache intensity (pain on a scale of 0 to 10).

Pain pattern diagrams were analyzed by two independent reviewers who were blinded to the identity of the patient, procedure performed, and the outcome of the patient as a result of surgery. The reviewers had 7 years and 2 years of clinical research experience, respectively. Pain diagrams were analyzed and categorized as follows: (1) typical (pain over nerve distribution, expected radiation pattern along anatomical nerve course); (2) intermediate (not atypical, but does not follow the exact nerve distribution); and (3) atypical (pain outside of normal nerve distribution, atypical radiation pattern diverting from anatomical nerve course). Pain sketches did not substitute for preoperative visit/examination, but were used as an adjunct to evaluate candidacy for surgery. Patients were not questioned about their sketches unless they had atypical features. No patients were excluded from preoperative assessment regardless of atypical pain sketch features. Patients with atypical sketches were only considered candidates for surgery if there was sufficient evidence on preoperative examination that an intervention may help their symptoms (identification of trigger sites on examination, improvement of pain after nerve block, and positive Doppler examination and computed tomography findings).

Improvement in Migraine Headache Index was compared between groups. Change in Migraine Headache Index from before trigger-site deactivation surgery to the most recent postoperative follow-up was calculated and expressed as a percentage change from baseline. Migraine Headache Index outcomes were compared using unpaired *t* tests between patients in each pain pattern category (i.e., typical, intermediate, and atypical). Data were compiled with Microsoft Excel (Microsoft Corp., Redmond, Wash.). Statistical analysis was performed with STATA (StataCorp, College Station, Texas).

RESULTS

One hundred thirty-one patients were enrolled in a prospective fashion and completed a pain sketch at screening. One hundred six patients (81.5 percent) had at least 1-year follow-up and were included in the final analysis. Mean follow-up was 14.1 months. Eighty-two patients (77 percent) were female and 24 (23 percent) were male. Mean age at surgery was 45 years (range, 18 to 73 years).

Typical (pain over nerve distribution, expected radiation pattern along anatomical nerve course) and atypical pain patterns (pain outside of normal nerve distribution, atypical radiation pattern diverting from anatomical nerve course) were present for each trigger site. Intermediate pain patterns (pain over nerve distribution, atypical radiation pattern diverting from anatomical nerve course) were present for all triggers except for the lesser occipital nerve site.

Both reviewers graded 62 pain sketches as typical (59 percent), 31 as intermediate (29 percent), and 13 (12 percent) as atypical. Interrater reliability was 94.3 percent, with a kappa value of 0.8984.

For patients with typical and intermediate drawings, the triggers identified on pain drawings correlated with the clinical examination in 79 cases (85 percent). In three cases, the rhinogenic trigger site was not marked on the drawings, although on examination/imaging, septoplasty was required. In 10 cases, the pain drawing identified both frontal and occipital trigger sites, but only either the frontal ($n = 5$) or the occipital site ($n = 5$) was confirmed on examination. One patient marked all known trigger sites on the drawing, but only the auriculotemporal site was confirmed.

For patients with abnormal pain sketches, 10 out of 13 sketches (77 percent) showed either diffuse pain or pain that did not correlate with specific trigger sites. Therefore, trigger-site detection was based on clinical examination findings only. Three patient pain sketches displayed specific known trigger sites that correlated with the clinical examination. The drawings were classified as abnormal because patients also drew facial pain (e.g., cheek, jaw, anterior neck).

Mean Migraine Headache Index improvement for patients with typical pain sketches was 73 ± 38 percent; for intermediate pain sketches, 78 ± 30 percent; and for atypical pain sketches, 30 ± 40 percent. There was no significant difference in percentage Migraine Headache Index improvement between classic and intermediate pain sketch patients ($p = 0.43$). There was, however, a significant difference in Migraine Headache Index percentage improvement between the typical and atypical groups ($p = 0.03$), and between the intermediate and atypical groups ($p < 0.01$) (Fig. 1).

The chance of having Migraine Headache Index improvement greater than 30 percent in the atypical group was 20 percent. The chance of having Migraine Headache Index less than 50 percent in the typical and intermediate groups combined was 20 percent.

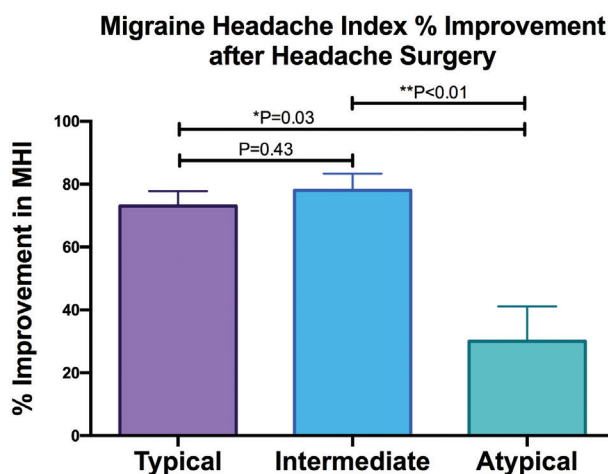


Fig. 1. Migraine Headache Index improvement after surgery between different pain sketch groups. There was no significant difference in Migraine Headache Index between the typical and intermediate pain sketch groups ($p = 0.43$). There was a significant difference between the typical and atypical groups ($p = 0.03$), and between the intermediate and atypical groups ($p < 0.01$).

Atypical pain patterns were analyzed as a group to establish more detailed and easier-to-understand criteria that define atypical sketches. The criteria for atypical sketches are as follows:

1. Facial pain that is not located at or above the eyebrows/forehead, temples, or around the eye (e.g., cheek, jaw, anterior neck).
2. Pain that starts in an atypical location that does not correspond to a trigger site. Ensure that the patient does not have nummular headache by Doppler ultrasound.¹¹
 - a. At the occiput, this is pain that radiates toward the spine/shoulders/arms and does not radiate up the head.
 - b. For the frontotemporal site, refer to point 1.
3. Diffuse pain that is not localized.

PAIN SKETCH PATTERNS

Occipital Pain Sketches

Greater Occipital Nerve

A typical pain sketch depicts the origin of pain at the occiput approximately 3 cm below the occipital protuberance and 1.5 cm lateral to the midline, which marks the point where the greater occipital nerve pierces the semispinalis muscle.¹² Pain usually radiates toward the forehead (Fig. 2, above) or to the eye (Fig. 2, second row).

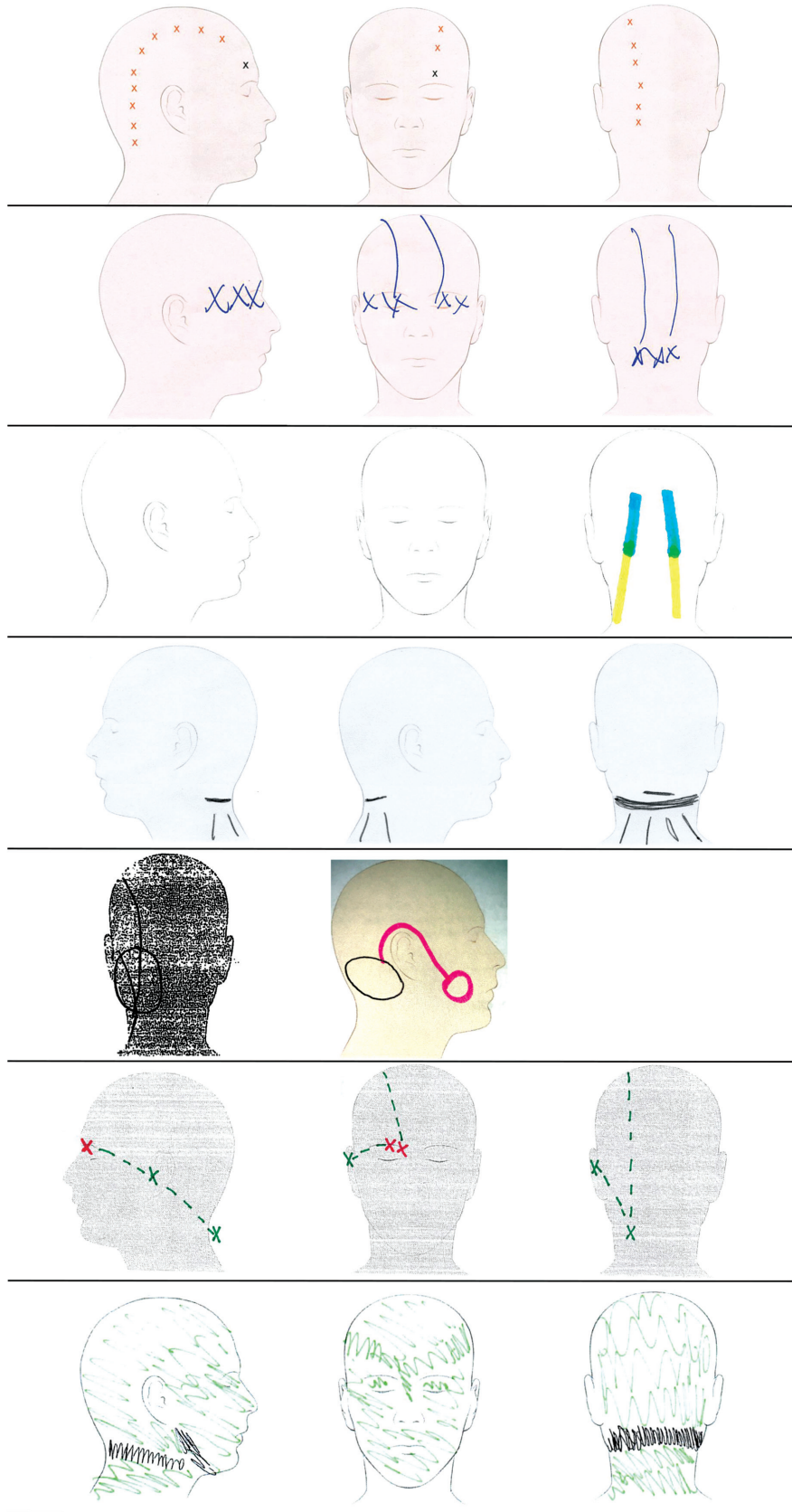


Fig. 2. (Continued).

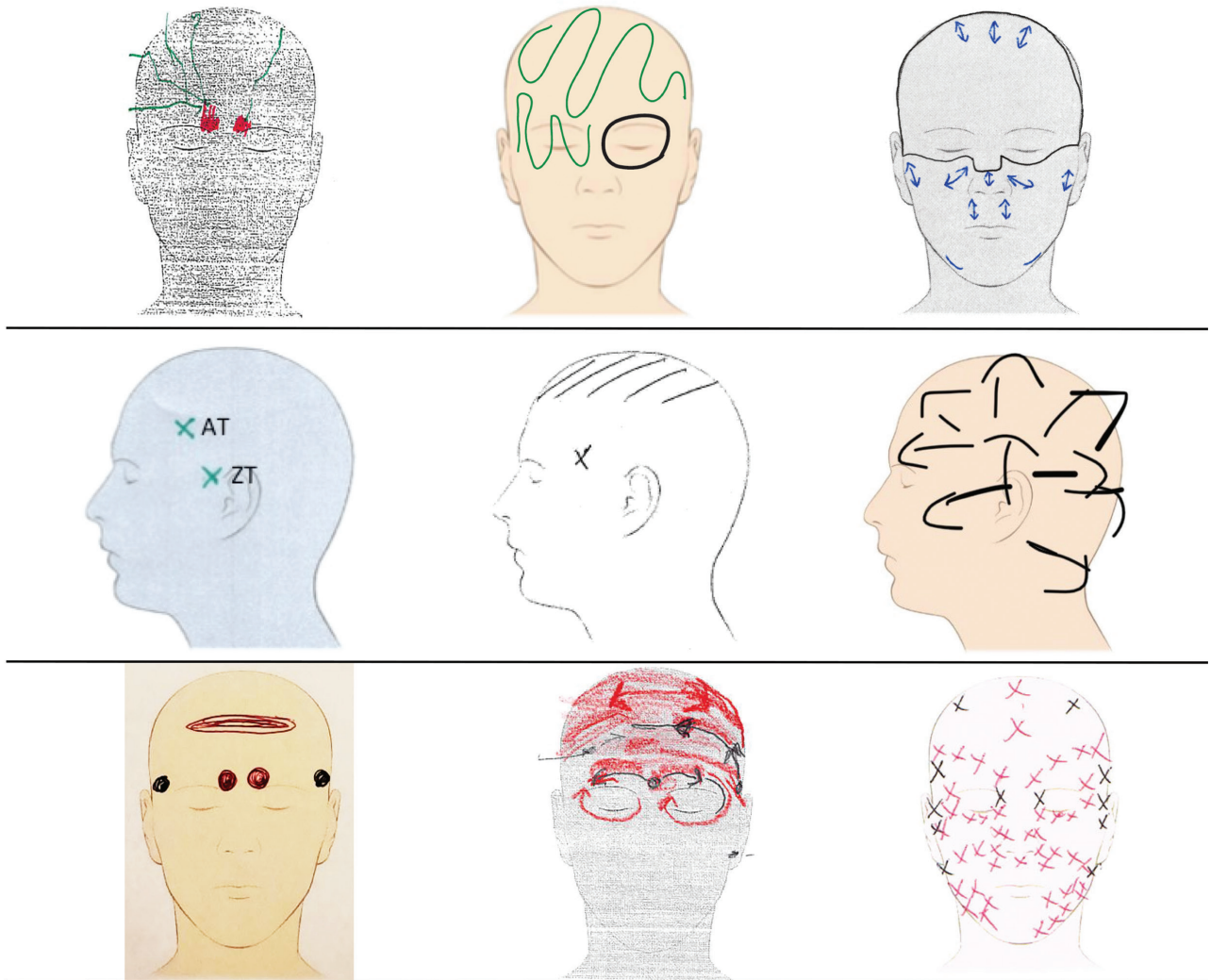


Fig. 3. Frontotemporal pain sketches. (Above, left) Typical frontal pain pattern, with pain origin at the eyebrow radiating across the forehead. (Above, center) Intermediate pain pattern, with pain that originates at or around the eye with a broad radiation pattern. (Above, right) Atypical pain pattern, with pain starting broadly and radiating across the face. (Center, left) Typical zygomaticotemporal (ZT) and auriculotemporal (AT) pain patterns are drawn at the temple. Intermediate patterns start in the right location but radiate to an unusual location such as the vertex of the scalp. (Center, center) Abnormal patterns have no clear point of onset and no clear radiation pattern. Frontal and temporal pain often occurs together (below). Typical pain patterns start over the frontal and temporal trigger site (below, left). Intermediate patterns start in the correct location, with a broad radiation pattern (below, center), and abnormal patterns encompass the entire face with no clear onset or radiation pattern (below, right).

Fig. 2. (Continued). Occipital pain sketches. (Above) Typical pain pattern with pain origin at greater occipital nerve exit from semispinalis muscle and radiating pain toward the forehead and (second row) behind the eye. (Third row) Intermediate pain pattern with pain that originates at the greater occipital nerve exit site with partial radiation along the nerve course, but also radiation toward the neck. (Center) Atypical pain pattern with pain in atypical anatomical position. (Fourth row, left) Typical lesser occipital nerve pain sketch drawn more lateral than greater occipital nerve pain. (Fifth row, center) Atypical lesser occipital nerve pain radiating to the cheek. (Sixth row) Typical pain sketch for combined greater and lesser occipital nerves. (Below) Atypical greater and lesser occipital nerve pain sketch.

Intermediate pain sketches show pain that originates at the exit point of the greater occipital nerve from the semispinalis muscle but does not radiate along the anatomical nerve distribution, or only partially radiates along the anatomical course of the nerve (Fig. 2, third row). Atypical greater occipital nerve pain patterns can be variable. Often, pain sketches depict pain over the posterior neck that is lower than expected and may radiate toward the spine/shoulders/arms. Another atypical pattern is pain that does not start at a specific location but spreads diffusely across the occiput (Fig. 2, center).

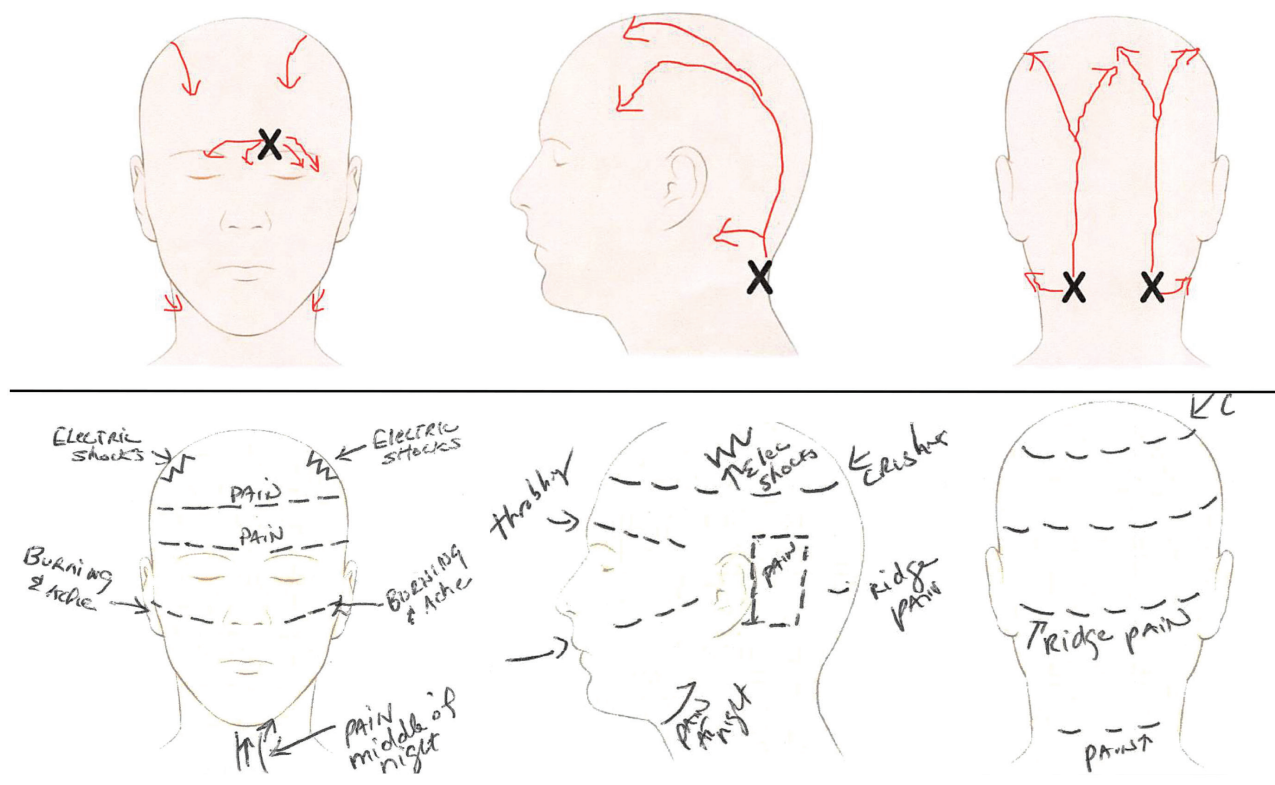


Fig. 4. Multiple trigger pain sketches. (Above) Typical pain sketches show pain at different trigger sites with typical radiation patterns. (Below) Atypical sketches depict pain all across the head and neck in nonanatomical locations and radiation patterns.

Lesser Occipital Nerve

Typically, lesser occipital pain is drawn farther lateral and inferior as compared to the greater occipital nerve pattern, with radiation toward the ear and temple (Fig. 2, fourth row, left). No intermediate sketches were identified for this trigger site. Atypical lesser occipital nerve pain sketches show either diffuse pain in the back of the head or pain radiating toward the jaw/arms (Fig. 2, fourth row, center).

Greater and Lesser Occipital Nerve

The above pain patterns may be combined if both nerves are affected. Examples of typical (Fig. 2, fifth row) and atypical (Fig. 2, below) greater/lesser occipital nerve pain are demonstrated in Figure 2.

Frontal/Temporal Pain Sketches

Frontal Supraorbital and Supratrochlear Nerves

Typical frontal pain sketches demonstrate pain originating at or above the eyebrow radiating along the forehead (Fig. 3, above, left). Intermediate pain patterns start at the site of the nerve but may radiate in a large radius across the front of the head and/or around the eye (Fig. 3, above, center).

Atypical pain is drawn as broad pain across the forehead radiating across the face or in an atypical location (facial pain that is not located at or

above the eyebrows/forehead or temples, around the eye) (Fig. 3, above, right).

Temporal: Zygomaticotemporal and Auriculotemporal Nerves

Both zygomaticotemporal and auriculotemporal pain is typically drawn at the temple. Auriculotemporal pain usually occurs superolateral to zygomaticotemporal pain in the hair-bearing area of the scalp, but patients often consider both types of pain to occur at the temple (Fig. 3, center, left). Intermediate pain patterns originate at the temple and radiate to an unusual location such as the vertex (Fig. 3, center, center). Atypical pain is drawn at the temple, with no distinct starting point, and is drawn diffusely (Fig. 3, center, right).

Frontal and Temporal Pain

Often, frontal pain (supraorbital and supratrochlear nerves) and temporal pain occur simultaneously. Typical combined pain is drawn as starting at both frontal and temporal sites and radiating across the forehead (Fig. 3, below, left).

Intermediate pain patterns originate at the site of both nerves but radiate in a large radius across the front of the head or to an abnormal location (Fig. 3, below, center). Atypical combined patterns have no starting point and often have

	P	A	I	N	S
	Pain point	Appropriate symptoms	Injection sites	Neurologist diagnosis	Sketch matching
Occipital		Pain starts 3cm caudal to occipital protuberance and 1.5cm from the midline Pain radiates to the forehead / behind the eye History of head / neck trauma common Tight neck muscles Triggered by stress / exercise / heavy lifting Doppler often identifiable at most tender spots		Migraine without aura	
Occipital		Pain starts more lateral and caudal than the GON Ear pain can occur Vertigo common Doppler often identifiable at most tender spot		Migraine with aura Chronic migraine, without aura	
Frontal - SON/STN		Pain starts at or above the eyebrows Pain can radiate towards the temples Deep frown lines can be present Eyelid ptosis common		Migraine unspecified, intractable Cluster headache unspecified	
Temporal - ZT		Pain starts approx 17mm lateral and 6mm cephalad to the lateral canthus History of teeth grinding common Pain starts in the morning Temporalis / masseter tender to touch Doppler signal often present		Episodic cluster headache	
Temporal - AT		Pain starts cephalad to the ZT Typically confined to the hair bearing area Oftentimes mistaken for temporomandibular joint disorders Doppler signal present		Chronic cluster headache Occipital neuralgia	
Rhinogenic		Pain starts behind the eye Pain is present in the morning and can wake patients up at night Weather / allergies / hormone changes influence pain On CT, deviated septum / turbinate hypertrophy / Haller's cell can be seen Rhinorrhea can occur		Headache Other Dorsalgia	
Nummular		Pain occurs in a small area on the scalp Parietal location common, but can occur anywhere on the scalp Doppler signal can be detected		Cervicalgia	

Fig. 5. PAINS diagram. *P*, Pain point identifiable with one finger.^{4-6,14,16} Greater occipital nerve (GON): 3 cm caudal to the occipital protuberance and 1.5 cm lateral to the midline.^{12,17-19} Lesser occipital nerve (LON): variable, lateral and caudal to the greater occipital nerve.^{20,21} Supraorbital and supratrochlear nerves: at or above the eyebrow.²²⁻²⁴ Zygomaticotemporal: non-hair-bearing temple.^{25,26} Auriculotemporal: hair-bearing scalp.²⁷⁻²⁹ Rhinogenic: behind the eye.¹⁶ Nummular: variable, oftentimes parietal scalp.¹¹ *A*, Appropriate symptoms.^{4-6,14,16} *I*, Injectables improve pain.^{4-6,14,16} *Blue points* indicate injection sites. Greater occipital nerve: (1) point of maximum pain, which may be at or cephalad to the exit site of the greater occipital nerve from the semispinalis muscle;

multiple starting points across the face, with radiation across the face diffusely (Fig. 3, below, right).

Multitrigger Pain Sketches

Typical multitrigger pain sketches display pain origin at typical trigger locations with radiation along the expected anatomical nerve distribution (Fig. 4, above). Atypical patterns show pain starting in nontrigger locations that is diffuse across the head and face (Fig. 4, below).

DISCUSSION

Pain sketches are an important tool for chronic pain patients to visually express complex pain conditions, and communicate their symptoms to health care providers.^{7,8} Pain diagrams have previously been used as a screening tool to predict surgical outcomes in patients undergoing spine surgery for lumbar radiculopathy.¹¹ This is the first time that this concept has been applied to trigger-site deactivation surgery for headaches. Advantages of pain drawings include the ability for patients to independently perform this task free of bias that can occur at the office visit. Furthermore, drawings are inexpensive, readily available, and easy to interpret by practitioners with limited experience. They are a useful supplement to, but not a substitute for, the trigger-site detection algorithm pioneered by Guyuron et al.^{4-6,13,14} This algorithm varies per site, but consists of identification of the headache origin with one finger, presence of a constellation of headache symptoms, identification of arterial Doppler signal, and nerve block/chemodenervation of

the trigger site. The authors have developed and published the PAINS diagram (Fig. 5)⁴⁻³⁰ to summarize the Guyuron trigger-site algorithm and amend the preoperative algorithm to include the use of pain sketches to identify trigger sites.^{14,15}

In this study, we demonstrate that three different types of pain sketches exist in patients undergoing trigger-site deactivation surgery, and we provide definitions and examples for each trigger site (Figs. 2 through 4):

1. Typical: Pain origin at the anatomical trigger site with radiation pattern along the anatomical nerve course.
2. Intermediate: Not atypical, but does not follow the exact nerve distribution.
3. Atypical:
 - a. Facial pain that is not located at or above the eyebrows/forehead or temples (e.g., cheek, jaw, anterior neck).
 - b. Pain that originates in an atypical location that does not correspond to a trigger site.
 - c. Diffuse pain that is not localized.

Although there are distinct differences between typical and intermediate pain sketches, surgical outcomes do not differ between groups (Migraine Headache Index improvement of 73 ± 38 percent in the typical versus 78 ± 30 percent in the atypical group; $p = 0.43$). Therefore, there is no need to distinguish between the two on screening. However, it is important to detect atypical pain sketches, as surgical outcomes are significantly worse in this group (30 ± 40 percent) as compared to the typical ($p = 0.03$) and intermediate ($p = 0.01$) groups (Fig. 1). Pain sketch red flags such as facial pain, pain starting at an atypical location, and diffuse pain should alert surgeons to consider patient classification as “atypical.” One limitation of this concept is the subjective nature of evaluating sketches. However, interrater reliability was high in our study and specific criteria for atypical sketches were developed to help clearly define atypical pain patterns.

Only 20 percent of patients in the atypical group have a mean Migraine Headache Index improvement of over 30 percent. Therefore, in general, we do not operate on patients with atypical pain sketches in our practice, as we have always suspected and have now demonstrated that they are poor candidates for surgery. However, patients with atypical sketches should not be excluded from preoperative assessment by a physician. If there is a compelling reason to operate regardless of an atypical sketch, it is important to counsel the patient about lower chances of a positive outcome.

Fig. 5. (Continued). (2) if continued pain, inject 3 cm caudal to the occipital protuberance and 1.5 cm lateral to the midline. Lesser occipital nerve: (1) point of maximum pain, which is typically higher (*dark blue point*) than the exit point of the lesser occipital nerve from the sternocleidomastoid muscle (*light blue point*). Supraorbital and supratrochlear nerves: over the bilateral corrugator muscles and the procerus muscle. Again, patient pain points should guide the surgeon. Zygomaticotemporal and auriculotemporal nerves: variable, correspond with the specific site of pain and often a positive Doppler signal. As an anatomical reference point, the zygomaticotemporal nerve exits the temporalis fascia 17 mm lateral and 6 mm cephalad to the lateral canthus. Similarly, the auriculotemporal nerve crosses the superficial temporal artery on average 19 mm lateral and 40 mm cephalad to the external auditory canal. Rhinogenic: lidocaine spray. Nummular: point of maximum pain/positive Doppler sign. *N*, Neurologist diagnosis.^{4-6,14,16} *S*, Sketch matching.³⁰ As part of patient screening before the office visit, we find it very helpful to have patients draw the point where their pain starts and where it radiates. See column 5 for typical sketches per site.

CONCLUSIONS

Patient pain sketches classified as atypical (facial pain, atypical pain starting point and radiation, diffuse pain) can predict poor outcomes in headache surgery. As we continue to develop algorithms to select patients for headache surgery, patient drawings should be considered as an effective, inexpensive, and simple-to-interpret tool for selecting candidates for surgery.

William Gerald Austen, Jr., M.D.

Division of Plastic and Reconstructive Surgery
 Massachusetts General Hospital
 15 Parkman Street, WACC 435
 Boston, Mass. 02114
wausten@partners.org
[@drjayausten](https://www.instagram.com/drjayausten)
[@harvardplasticsurgery](https://www.instagram.com/harvardplasticsurgery)
[@migrainesurgerysociety](https://www.instagram.com/migrainesurgerysociety)

PATIENT CONSENT

The patient provided written consent for the use of her images.

REFERENCES

- Guyuron B, Reed D, Kriegler JS, Davis J, Pashmini N, Amini S. A placebo-controlled surgical trial of the treatment of migraine headaches. *Plast Reconstr Surg.* 2009;124:461–468.
- Janis JE, Barker JC, Javadi C, Ducic I, Hagan R, Guyuron B. A review of current evidence in the surgical treatment of migraine headaches. *Plast Reconstr Surg.* 2014;134(Suppl 2):131S–141S.
- Gfrerer L, Maman DY, Tessler O, Austen WG Jr. Nonendoscopic deactivation of nerve triggers in migraine headache patients: Surgical technique and outcomes. *Plast Reconstr Surg.* 2014;134:771–778.
- Ascha M, Kurlander DE, Sattar A, Gatherwright J, Guyuron B. In-depth review of symptoms, triggers, and treatment of occipital migraine headaches (site IV). *Plast Reconstr Surg.* 2017;139:1333e–1342e.
- Kurlander DE, Ascha M, Sattar A, Guyuron B. In-depth review of symptoms, triggers, and surgical deactivation of frontal migraine headaches (site I). *Plast Reconstr Surg.* 2016;138:681–688.
- Kurlander DE, Punjabi A, Liu MT, Sattar A, Guyuron B. In-depth review of symptoms, triggers, and treatment of temporal migraine headaches (site II). *Plast Reconstr Surg.* 2014;133:897–903.
- Shaballout N, Aloumar A, Neubert TA, Dusch M, Beissner F. Digital pain drawings can improve doctors' understanding of acute pain patients: Survey and pain drawing analysis. *JMIR Mhealth Uhealth* 2019;7:e11412.
- Hüllemann P, Keller T, Kabelitz M, Freynhagen R, Tölle T, Baron R. Pain drawings improve subgrouping of low back pain patients. *Pain Pract.* 2017;17:293–304.
- Voorhies RM, Jiang X, Thomas N. Predicting outcome in the surgical treatment of lumbar radiculopathy using the Pain Drawing Score, McGill Short Form Pain Questionnaire, and risk factors including psychosocial issues and axial joint pain. *Spine J.* 2007;7:516–524.
- MacDowall A, Robinson Y, Skeppholm M, Olerud C. Pain drawings predict outcome of surgical treatment for degenerative disc disease in the cervical spine. *Ups J Med Sci.* 2017;122:194–200.
- Guyuron B, Gatherwright J, Reed D, Ansari H, Knackstedt R. Treatment of Dopplerable nummular headache with minimally invasive arterectomy under local anesthesia. *J Plast Reconstr Aesthet Surg.* 2018;71:1010–1014.
- Mosser SW, Guyuron B, Janis JE, Rohrich RJ. The anatomy of the greater occipital nerve: Implications for the etiology of migraine headaches. *Plast Reconstr Surg.* 2004;113:693–697; discussion 698–700.
- Guyuron B, Kriegler JS, Davis J, Amini SB. Comprehensive surgical treatment of migraine headaches. *Plast Reconstr Surg.* 2005;115:1–9.
- Guyuron B, Nahabet E, Khansa I, Reed D, Janis JE. The current means for detection of migraine headache trigger sites. *Plast Reconstr Surg.* 2015;136:860–867.
- Gfrerer L, Austen WG Jr, Janis JE. Migraine surgery. *Plast Reconstr Surg Glob Open* 2019;7:e2291.
- Guyuron B. *Migraine Surgery.* New York: Thieme; 2018.
- Israel JS, Kempton SJ, Afifi AM. Prospective analysis of the greater occipital nerve location in patients undergoing occipital nerve decompression. *Ann Plast Surg.* 2018;81:71–74.
- Janis JE, Hatef DA, Ducic I, et al. The anatomy of the greater occipital nerve: Part II. Compression point topography. *Plast Reconstr Surg.* 2010;126:1563–1572.
- Junewicz A, Katira K, Guyuron B. Intraoperative anatomical variations during greater occipital nerve decompression. *J Plast Reconstr Aesthet Surg.* 2013;66:1340–1345.
- Lee M, Brown M, Chepla K, et al. An anatomical study of the lesser occipital nerve and its potential compression points: Implications for surgical treatment of migraine headaches. *Plast Reconstr Surg.* 2013;132:1551–1556.
- Peled ZM, Pietramaggiore G, Scherer S. Anatomic and compression topography of the lesser occipital nerve. *Plast Reconstr Surg Glob Open* 2016;4:e639.
- Fallucco M, Janis JE, Hagan RR. The anatomical morphology of the supraorbital notch: Clinical relevance to the surgical treatment of migraine headaches. *Plast Reconstr Surg.* 2012;130:1227–1233.
- Hagan RR, Fallucco MA, Janis JE. Supraorbital rim syndrome: Definition, surgical treatment, and outcomes for frontal headache. *Plast Reconstr Surg Glob Open* 2016;4:e795.
- Janis JE, Ghavami A, Lemmon JA, Leedy JE, Guyuron B. The anatomy of the corrugator supercilii muscle: Part II. Supraorbital nerve branching patterns. *Plast Reconstr Surg.* 2008;121:233–240.
- Janis JE, Hatef DA, Thakar H, et al. The zygomaticotemporal branch of the trigeminal nerve: Part II. Anatomical variations. *Plast Reconstr Surg.* 2010;126:435–442.
- Totonchi A, Pashmini N, Guyuron B. The zygomaticotemporal branch of the trigeminal nerve: An anatomical study. *Plast Reconstr Surg.* 2005;115:273–277.
- Chim H, Okada HC, Brown MS, et al. The auriculotemporal nerve in etiology of migraine headaches: Compression points and anatomical variations. *Plast Reconstr Surg.* 2012;130:336–341.
- Janis JE, Hatef DA, Ducic I, et al. Anatomy of the auriculotemporal nerve: Variations in its relationship to the superficial temporal artery and implications for the treatment of migraine headaches. *Plast Reconstr Surg.* 2010;125:1422–1428.
- Sanniec K, Borsting E, Amirlak B. Decompression-avulsion of the auriculotemporal nerve for treatment of migraines and chronic headaches. *Plast Reconstr Surg Glob Open* 2016;4:e678.
- Gfrerer L, Hansdorfer MA, Ortiz R, Nealon KP, Austen WG Jr. Pain drawings can predict poor surgical outcomes in migraine surgery. Paper presented at: 88th Annual Meeting of the American Society of Plastic Surgeons; September 20–23, 2019; San Diego, California.