

Distraction osteogenesis of free flap reconstructed mandible following ameloblastoma resection for optimal functional rehabilitation

Access this article online

Website:
www.amsjournal.com

DOI:
10.4103/2231-0746.147162

Quick Response Code:



V. A. Bousdras, N. Kalavrezos¹

Private Practice, Al Mihailidi 9, Thessaloniki 54640 Greece, ¹Clinical Head and Neck Centre, University College Hospital, London NW1 2PG, United Kingdom

Address for correspondence:

Mr. Vasilios Bousdras, Maxillofacial Surgeon, Al Mihailidi 9, Thessaloniki 54640 Greece.
E-mail: vbousdras@yahoo.com

ABSTRACT

This case highlights the use of a custom-made distractor (Synthes GmbH, Oberdorf, Switzerland), used to increase bone height prior to rehabilitation with implant placement, in a patient following excision of an ameloblastoma and reconstruction of her mandible with a fibular flap. A 27-year-old patient had her mandible reconstructed following wide resection of an ameloblastoma. Although a 2.0 LOCK reconstruction plate (Synthes GmbH, Oberdorf, Switzerland) was used for fixation of the fibular bone, the vertical deficiency between the reconstructed segment and the occlusal plane made oral rehabilitation impossible. To overcome this, the fibular bone segment was vertically distracted following a latency period of 4 days. Distractor was left in place for 20 weeks for bone consolidation. Following device removal implants were placed. The novelty of this approach included fixation of the lower arm of the distractor on the LOCK plate. The distractor was unidirectional with two arms of different length. The lower arm composed of a 2.0 mini-plate to fit exactly on the 2.0 LOCK plate whereas the upper arm used a standard 1.5 mini-plate. Advantages of this custom-made distractor included: (i) No need for removal of the reconstruction plate, (ii) no need for an extraoral surgical approach, and (iii) no need for additional drilling to fit the lower arm of the distractor. Technical details and limitations are presented.

Keywords: Ameloblastoma, distraction osteogenesis, free flap, mandible

INTRODUCTION

Extensive mandibular bone defects, as a result, from trauma, infection or tumor resection are commonly reconstructed with vascularized fibular flaps^[1] due to their sufficient length, good quality of bone and vascularization. The main drawback is its limited diameter, which when compared with the height of the mandible it often leads to a considerable deficient vertical distance between the reconstructed segment and the occlusal plane.^[2]

In order to overcome problems with insufficient bone height distraction osteogenesis of the fibular bony flap through either an extraoral,^[3] or intraoral^[4] approach has been increasingly gaining popularity. Preliminary results have shown the formation of good quality bone for implant osseointegration. An intraoral approach

without necessary removal of the reconstruction plate could offer advantages in terms of less invasive surgery and intervention.

In this report, a young patient had treatment at University College London Hospital, for ameloblastoma, following a wide resection and a hemi-mandibulectomy and vascularized fibula flap reconstruction initially. Prior achieving oral rehabilitation with implants, vertical distraction of the reconstructed mandible was carried out in order to achieve optimal bone dimensions for successful treatment.

Novel distractor

A novel custom-made distractor (Synthes, Switzerland) was fabricated. The distractor was unidirectional with two arms of different length and plate thickness [Figure 1]. The lower arm

composed of a 2.0 mm plate to fit exactly on the 2.0 LOCK plate (Synthes, Switzerland) while the upper arm used a standard thickness 1.5 mm mini-plate.

The custom-made distractor had 2 arms, of different size and of maximum opening 15 mm. Advantages of this custom-made distractor included: (i) No need for removal of the reconstruction plate, (ii) no need for an extraoral surgical approach, and (iii) no need for additional drilling to fit the lower arm of the distractor.

The protocol followed at University College Hospital for all patients undergoing hemi-mandibulectomy/maxillectomy, and free flap reconstruction is to use the 2.0 Uni-LOCK plate for better fixation of the flap segment.^[5] The novelty of this approach included fixation of the lower arm of the distractor on the Uni-LOCK plate, avoiding removal of the plate.

CASE REPORT

Patient and surgical approach

A 42-year-old patient had his left mandible reconstructed following wide resection of an ameloblastoma in 2004. While a 2.0 Unilock reconstruction plate was used for fixation of the fibular bone (right neo-mandible), the vertical deficiency between the reconstructed segment and the occlusal plane made oral rehabilitation impossible [Figure 2a and b]. To overcome this, the fibular bone segment was vertically distracted (rate of 0.75 mm/day twice daily [2×0.375 mm])



Figure 1: The custom-made distractor's lower arm composed of a 2.0 mini-plate to fit exactly on the 2.0 Uni-Lock plate, while the upper arm used a standard 1.5 mm mini-plate

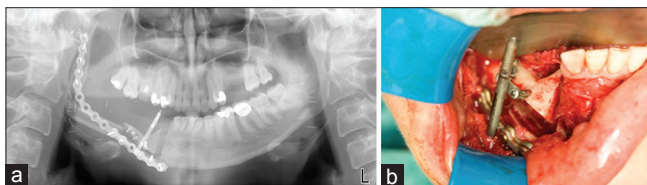


Figure 3: (a) Orthopantomograph of the distractor intraorally fitted on the Uni-Lock reconstruction plate (b) Fixation of the custom-made distractor on the Uni-Lock plate

for 12 days, following a latency period of 6 days. The distractor was left in place for 16 weeks for bone consolidation. The distractor was relatively simple to insert and was tolerated well by the patient. No mucosa breakdown was noted during the healing phase.

The novelty of this approach included fixation of the lower arm of the distractor on the Uni-Lock plate [Figure 3a and b]. Vertical distraction of the fibular flap was uneventful. The overall increase of vertical height was 9 mm [Figure 4a and b] ensuring adequate bone height of optimal oral rehabilitation. Three implants were placed in June 2008 and oral rehabilitation was achieved 2 years later.

DISCUSSION

Extensive mandibular bone defects, as a result, from trauma, infection or tumor resection are commonly reconstructed with free fibular flaps.^[1,6] This flap was first used by Hidalgo in 1989^[7] for reconstruction of mandibular defects and presents many advantages as:

- Sufficient length of the bony segment with adequate length of the vascular pedicle
- Good quality and shape of bone
- Good vascularization.

The main drawback is its limited diameter/height, which when compared with the height of the mandible often leads to a considerable deficient vertical distance between the reconstructed segment and the occlusal plane of the dentate mandible. This can cause both functional and aesthetic problems.^[4] Moreover, in cases with reconstructed dentate mandibles rehabilitation with implants can be challenging^[2] due to: (i) Bulk of soft tissues and (ii) poor retention of the over denture.

In order to overcome these problems, a number of alternative approaches have been introduced:

- Interpositional and/or onlay bone grafting
- The double-barrel fibula flap^[6]
- Distraction osteogenesis of the fibular bony flap.

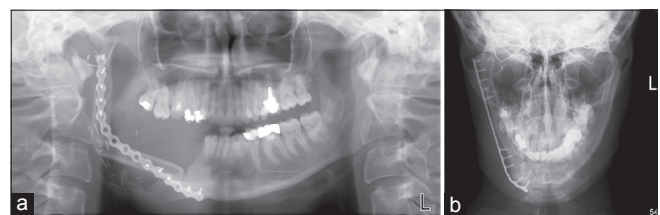


Figure 2: (a and b) Reconstructed mandible following wide resection of an ameloblastoma in 2004. A 2.0 Unilock reconstruction plate was used for fixation of the fibular bone

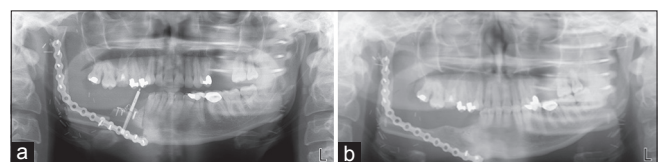


Figure 4: (a and b) Orthopantomograph of the same patient demonstrating vertical bone gain of 9 mm

While the first two approaches are not popular due to higher infection, morbidity and risk of the pedicle, vertical distraction through an extraoral^[3,8] or intraoral^[4] approach has been increasingly gaining popularity. Preliminary results have shown the formation of good quality bone for implant osseointegration.

A variety of distractors has been used with intraoral (MOD, Gebruder Martin GmbH and Co, Tuttlingen, Germany),^[4] and extraoral (MODUS ARS1.4/V Medartis AG, Basel)^[3] approaches. To the authors' knowledge this is the first case report that distraction osteogenesis was introduced with an intraoral distractor fitted on the initially placed reconstruction plate, which had been used to fix the fibular flap to the native mandible.

This distractor can be used to increase bone height prior to oral rehabilitation, in patients with vertical bone deficiency following mandibular reconstruction with a fibular free flap.

REFERENCES

1. Chana JS, Chang YM, Wei FC, Shen YF, Chan CP, Lin HN, *et al*. Segmental mandibulectomy and immediate free fibula osteoseptocutaneous flap reconstruction with endosteal implants: An ideal treatment method for mandibular ameloblastoma. *Plast Reconstr Surg* 2004;113:80-7.
2. Iizuka T, Häfliger J, Seto I, Rahal A, Mericske-Stern R, Smolka K. Oral rehabilitation after mandibular reconstruction using an osteocutaneous fibula free flap with endosseous implants. Factors affecting the functional outcome in patients with oral cancer. *Clin Oral Implants Res* 2005;16:69-79.
3. Eski M, Turegun M, Deveci M, Gokce HS, Sengezer M. Vertical distraction osteogenesis of fibular bone flap in reconstructed mandible. *Ann Plast Surg* 2006;57:631-6.
4. Chiapasco M, Brusati R, Galioto S. Distraction osteogenesis of a fibular revascularized flap for improvement of oral implant positioning in a tumor patient: A case report. *J Oral Maxillofac Surg* 2000;58:1434-40.
5. Bousdras V, Young H, Norris P, Kalavrezos N. A novel distractor for a free flap reconstructed mandible. *J Craniomaxillofac Surg* 2008;36(Suppl1):S44. [O.172].
6. Bähr W, Stoll P, Wächter R. Use of the "double barrel" free vascularized fibula in mandibular reconstruction. *J Oral Maxillofac Surg* 1998;56:38-44.
7. Hidalgo DA. Fibula free flap: A new method of mandible reconstruction. *Plast Reconstr Surg* 1989;84:71-9.
8. Nocini PF, Wangerin K, Albanese M, Kretschmer W, Cortelazzi R. Vertical distraction of a free vascularized fibula flap in a reconstructed hemimandible: Case report. *J Craniomaxillofac Surg* 2000;28:20-4.

Cite this article as: Bousdras VA, Kalavrezos N. Distraction osteogenesis of free flap reconstructed mandible following ameloblastoma resection for optimal functional rehabilitation. *Ann Maxillofac Surg* 2014;4:237-9.

Source of Support: Nil, **Conflict of Interest:** None declared.