



Case report

Hyperpharmacotherapy in ageing cystic fibrosis patients: The first report of an atypical hip fracture



W.A.K. Al-Azzani ^a, L. Evans ^a, L. Speight ^a, M. Lea-Davies ^a, M.D. Stone ^b, D. Lau ^a,
R.I. Ketchell ^a, J. Duckers ^{a,*}

^a All Wales Adult Cystic Fibrosis Centre, University Hospital Llandough, Cardiff, CF64 2XX, United Kingdom

^b Bone Unit, University Hospital Llandough, Cardiff, CF64 2XX, United Kingdom

ARTICLE INFO

Article history:

Received 22 August 2015

Accepted 29 September 2015

Keywords:

Bone mineral density

Fracture

Bisphosphonate

Multimorbidity

ABSTRACT

Cystic fibrosis (CF) is a common autosomal recessive disorder in Caucasian populations with respiratory, gastrointestinal and endocrine manifestations. Thanks to recent advances in medical therapies and infection control, life expectancy of a patient with CF has significantly increased from less than 5 years in the mid-1900s to almost 50 years nowadays. However, as CF patients are living longer, multimorbidity and Hyperpharmacotherapy are becoming more common. This case illustrates a cascade of problems that ensued from medication side-effects, highlighting the increasing challenge of managing an ageing CF population.

© 2015 The Authors. Published by Elsevier Ltd. This is an open access article under the CC BY-NC-ND license (<http://creativecommons.org/licenses/by-nc-nd/4.0/>).

1. Introduction

Cystic fibrosis (CF) is a common autosomal recessive disorder in Caucasian populations [1]. It is caused by mutations in cystic fibrosis transmembrane conductance regulator (CFTR) gene giving rise to respiratory, gastrointestinal and endocrine manifestations [1]. Survival rates for patients with CF have been increasing with continued developments of CF specific therapies. This trend is likely to increase in decades to come. Currently the median survival in the UK is 43.5 years and it is estimated that a child born today with CF will live into their fifties [2,3]. As patients are ageing they accumulate more complications and comorbidities and these go hand in hand with an increasing treatment burden. Here the authors present the first report of an atypical hip fracture in a CF patient.

2. Ethical approval

No identifiable patient information are presented. Patient consent was sought and documented in clinical notes.

3. Case description

The case of a 54-year-old male who was a late diagnosis of cystic fibrosis (DF508/D1152H) is presented. He was diagnosed at the age

of 48 after 8 years of poorly controlled allergic bronchopulmonary aspergillosis (ABPA) necessitating long term prednisolone therapy. Four years prior to his diagnosis of CF he sustained several rib fractures during a coughing episode. At this juncture his bone density (DXA) scan T scores were T score Total Hip –0.6, T score Lumbar spine (LS) –1.5 and he was maintained on Calchichew D3 Forte, Prednisolone 10 mg and Itraconazole. His serum calcium, vitamin D, Testosterone, Thyroid function and parathyroid hormone were all normal. He was started on Alendronic acid 70 mg once weekly. He remained on this treatment for five years during which he had annual DXA scans and was noted that his Bone Mineral Densities (BMDs) were improving (T score hip –0.4, LS –1.2). He was given a bisphosphonate holiday for one year but a mild drop of his BMD (T score LS –1.3) whilst on long term prednisolone (10 mg) for ABPA prompted the initiation of Ibandronate 150 mg once monthly which he continued for four years.

During this period he accrued several co morbidities including pancreatic insufficiency, impaired oral glucose tolerance, hypertension, hypercholesterolaemia, obstructive sleep apnoea, elevated body mass index (BMI) of 30 kg/m² and chronic methicillin resistant staphylococcus aureus (MRSA) colonisation.

His forced expiratory volume in 1 s percent predicted (FEV₁%) dropped to 30%, his quality of life deteriorated and exacerbation frequency increased with two admissions with acute type two respiratory failure necessitating non-invasive ventilation. He was referred for consideration of lung transplantation and concerns were raised regarding MRSA colonisation (repeat eradication

* Corresponding author.

E-mail address: jamie.duckers@wales.nhs.uk (J. Duckers).

therapy initiated) and BMI (exercise and dietary modification instated).

During this period he presented with a respiratory exacerbation and he was commenced on Ciprofloxacin 1g twice daily orally. Unfortunately he developed Achilles tendonitis and the Ciprofloxacin was stopped but due to weakness he tripped whilst walking down a step and sustained a fracture at the base of his right 5th metatarsal bone.

Ibandronic acid was stopped since the fracture had not healed after 20 weeks and he was given a non-weight bearing-orthotic shoe and crutches. Fractures of the 5th metatarsal would usually be expected to heal in around six to eight weeks.

As there was poor callus formation and ongoing pain over a period of several months he was commenced on daily subcutaneous Teriparatide (recombinant human 1–34 parathyroid hormone) to stimulate bone formation.

There was some bone healing and eight months after the fracture he began weight bearing.

Four months later, he complained of pain in his left groin after twisting when carrying his ambulatory oxygen through a narrow doorway. Examination was unremarkable and an XR was performed (Fig. 1).

The appearances were highly suggestive of an atypical fracture meeting all the major criteria (between lesser trochanter and supracondylar flare, minimal trauma, transverse or short oblique configuration, non-comminuted, incomplete fracture involving only the lateral cortex)[4]. The fracture necessitated internal fixation performed under general anaesthetic. The operative bone biopsy revealed degenerative change and markers of bone turnover, urinary N Telo peptide and P1NP, were within quoted normal range. [Urinary N Telo peptide 34 BCE/Mmol, P1NP 70ug/l (normal range 20–76)]. Renal function and Total 25OH Vit D were normal. [vit d = 95.4 nmol/l, egfr >90].

Subsequently he became further deconditioned, his BMI increased to 33 kg/m² and motivation remained low; he is now no longer a candidate for consideration of bilateral sequential lung transplantation.

4. Discussion

Multimorbidity is defined as the co-occurrence of multiple chronic or acute diseases and medical conditions within one person. This is becoming more common as CF patients live longer. For instance, CF related low bone mineral density (CFRLBMD) occurs in

34% of CF patients [4] with a multifactorial aetiology. Studies have revealed that 14% of CF patients have evidence of vertebral fractures and 20% non-vertebral fractures [5]. Guidelines on the management of CFRLBMD advocate a combination of both preventive and treatment strategies [6]. However, in following guidelines for patients with multimorbidity there is a danger of not considering the cumulative impact of treatment recommendations as most guidelines were derived from research that automatically excluded patients with multiple co-morbidities.

The subject of this report was a middle aged patient with CF with high multimorbidity and on 17 different medications. Although the term ‘Polypharmacy’ has been used for decades to describe such a situation, a clear definition is lacking. A recent review of the literature revealed 24 different definitions of polypharmacy with ‘a medication not matching diagnosis’ as the most commonly cited definition [7]. It is now recommended to use less ambiguous terminology such as hyperpharmacotherapy or multiple medication use. The presence of drug related problems (DRPs) has been shown to increase approximately linearly with the number of drugs used, for the range of one to more than 11 drugs [8].

Ciprofloxacin, a second generation fluoroquinolone antibiotic (FA), is commonly used to treat a respiratory exacerbation in CF patients. The incidence of Fluoroquinolone induced tendinopathy (FIT) in healthy population is unclear but estimated to ranges between 0.14% and 0.4%. However, higher risks were observed with advanced age, obesity, concurrent use of glucocorticoids, diabetes mellitus, chronic renal disease, chronic lung disease and participation in sports activities [9]. Unfortunately the subject of this report had multiple risk factors for developing FA induced tendinopathy. His achilles tendonitis resulting in weakness and subsequent fall and fracture at the base of his 5th metatarsal bone. The consequences of this were further deconditioning and inability to reduce BMI.

He was also on bisphosphonates, a class of drugs that inhibit bone resorption. Bisphosphonates are the mainstay of management of CFRLBMD and have been shown to increase BMD in CF patients, but there is currently insufficient data to demonstrate effect on fracture incidence. Current European Cystic Fibrosis bone mineralisation guidelines [3] recommend the use of bisphosphonates in CF patients with evidence of significant bone loss, low trauma fracture or continuous systemic oral glucocorticoids for more three months with a BMD less than T/Z score of –1.5.

Side effects include osteonecrosis of the jaw, oesophageal ulceration, bone pain and flu-like symptoms. Atypical fractures are rare but have been reported more with long term treatment thus suggesting re-evaluation of use after five years and consideration of ‘drug holidays’ in selected patients [10]. Another undesirable side effect of long-term systemic bisphosphonate administration is delayed healing of fractures due to delayed maturation and remodelling of callus. This delay can persist even after bisphosphonate administration is stopped. Despite these uncommon but significant adverse events, a local study showed that 41% (n = 16) of patients on long-term bisphosphonate (n = 39) had received treatment for more than five years without break.

The consequences of this poorly healing metatarsal fracture followed by an atypical hip fracture for this patient were grave. The deconditioning and weight gain following the metatarsal fracture had a significant psychological and emotional impact on him and the hip fracture posed a major perioperative risk.

This rare complication of bisphosphonates use has not been previously reported in a patient with CF. It highlights the importance of weighing up all possible risks against benefits when prescribing bisphosphonates. Further research into the optimum duration of treatments is vital in order to aid decision making process.

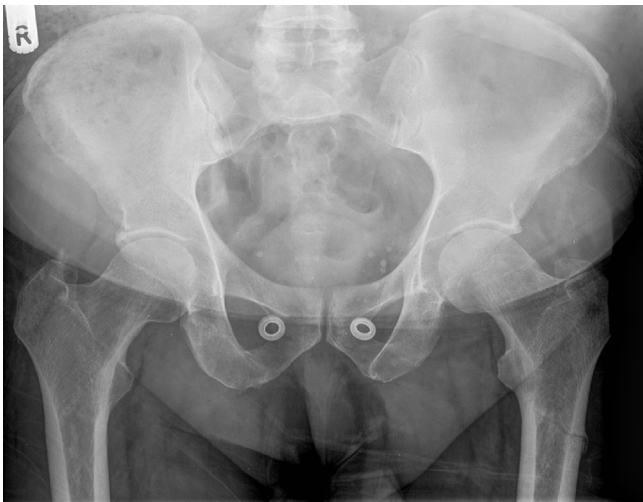


Fig. 1. Atypical fracture left femur.

5. Conclusions

This case illustrates a cascade of problems that ensued from medication side-effects; starting from the glucocorticoid induced low BMD to the ciprofloxacin causing Achilles' tendonitis and subsequent metatarsal fracture and finally an atypical fracture related to bisphosphonate use. It serves as a potent reminder of the increasing challenges of hyperpharmacotherapy in an ageing CF population with multimorbidity.

References

- [1] B.P. O'Sullivan, S.D. Freedman, Cystic fibrosis, *Lancet* 373 (9678) (2009) 1891–1904.
- [2] J.A. Dodge, P.A. Lewis, M. Stanton, J. Wilsher, Cystic fibrosis mortality and survival in the UK: 1947–2003, *Eur. Respir. J.* 29 (3) (2007) 522–526.
- [3] UK. Annual Data Report. CF Trust Annual Report, 2012.
- [4] C.S. Haworth, P.L. Selby, A.K. Webb, M.E. Dodd, H. Musson, L.N.R. Mc, et al., Low bone mineral density in adults with cystic fibrosis, *Thorax* 54 (11) (1999) 961–967.
- [5] J. Paccou, N. Zeboulon, C. Combescure, L. Gossec, B. Cortet, The prevalence of osteoporosis, osteopenia, and fractures among adults with cystic fibrosis: a systematic literature review with meta-analysis, *Calcif. Tissue Int.* 86 (1) (2010) 1–7.
- [6] I. Sermet-Gaudelus, M.L. Bianchi, M. Garabedian, R.M. Aris, A. Morton, D.S. Hardin, et al., European cystic fibrosis bone mineralisation guidelines, *J. Cystic Fibros. Off. J. Eur. Cyst. Fibros. Soc.* 10 (Suppl. 2) (2011) S16–S23.
- [7] R.L. Bushardt, E.B. Massey, T.W. Simpson, J.C. Ariail, K.N. Simpson, Polypharmacy: misleading, but manageable, *Clin. Interv. Aging* 3 (2) (2008) 383–389.
- [8] K.K. Viktil, H.S. Blix, T.A. Moger, A. Reikvam, Polypharmacy as commonly defined is an indicator of limited value in the assessment of drug-related problems, *Br. J. Clin. Pharm.* 63 (2) (2007) 187–195.
- [9] Y. Khaliq, G.G. Zhanel, Fluoroquinolone-associated tendinopathy: a critical review of the literature, *Clin. Infect. Dis. Off. Publ. Infect. Dis. Soc. Am.* 36 (11) (2003) 1404–1410.
- [10] N.B. Watts, D.L. Diab, Long-term use of bisphosphonates in osteoporosis, *J. Clin. Endocrinol. Metab.* 95 (4) (2010) 1555–1565.