

doi: 10.5455/aim.2014.22.371-373

ACTA INFORM MED. 2014 DEC 22(6): 371-373

Received: 11 March 2014 • Accepted: 22 May 2014

© AVICENA 2014

Published online: 19/12/2014

Published print: 12/2014

ORIGINAL PAPER

Ovarian Reserve After Laparoscopic Treatment of Unilateral Ovarian Endometrioma

Jadranka Georgievska¹, Slavejko Sapunov¹, Svetlana Cekovska², Kristin Vasilevska³

University Clinic for Gynecology and Obstetrics, Medical Faculty, Skopje, R. Macedonia¹

Institute of Medical and Experimental Biochemistry, Medical Faculty, Skopje, R. Macedonia²

Institute of Epidemiology and Biostatistics with Medical Informatics, Medical Faculty, Skopje, R. Macedonia³

Corresponding author: Jadranka Georgievska, MD. Address: ul. Dragoviti br. 1-B, 1000 Skopje, R. Macedonia. Phone: +38970305256 E-mail: jadrankageo@yahoo.com

ABSTRACT

Aim: To evaluate the effect of laparoscopic treatment of unilateral ovarian endometrioma on ovarian reserve using ultrasonographic markers, ovarian volume and antral follicle count (AFC), and two biochemical markers, serum levels of Follicle-stimulating hormone (FSH) and Estradiol (E2). **Material and methods:** This prospective study included 40 patients in their reproductive age, between 18 and 40 years old. They were treated laparoscopically for unilateral ovarian endometrioma. Markers of ovarian reserve were investigated before and three months after surgery. Transvaginal ultrasound examination was used for measurement of ovarian volume and AFC. Biochemical markers (FSH and E2 levels) were determined by chemiluminescent tests. **Results:** Ovarian volume was significantly reduced after surgery. There was significant increase of AFC and non-significant increase of E2 levels in treated patients after three months. **Conclusions:** Laparoscopic cystectomy of unilateral ovarian endometrioma decreased ovarian reserve immediately after surgery with decrease of ovarian volume. But ovarian reserve was increased after three months with increase of AFC and estradiol levels.

Key words: laparoscopic cystectomy, ovarian endometrioma, ovarian reserve

1. INTRODUCTION

Ovarian endometrioma is a benign, estrogen-dependant cyst found in 5 to 10% of women in reproductive age. In 20 to 40% it affects women with infertility (1). These women have symptoms as dyspareunia, dysmenorrhea, infertility.

The gold standard for symptomatic women with ovarian endometrioma (diagnostic and therapeutic method) is laparoscopy. Excision (cystectomy) of the cyst is rather recommended because it is associated with a higher pregnancy rate and a lower recurrence rate (2, 3, 4, 5). The most commonly used excision technique is the stripping procedure. It includes stripping of the cystic wall, avoiding removal of the adherent normal ovarian cortex and coagulation for hemostasis. Ovarian reserve is defined as the capacity of the ovary to produce healthy eggs available for maturation and capable for fertilization. It has been reported that ovarian reserve is negatively affected by cystectomy due to removal of normal ovarian tissue (6, 7). The traditional method for evaluation of the ovarian reserve is determination of serum follicle-stimulating hormone and estradiol levels. When ovarian reserve is diminished, the FSH and E2 levels are elevated (8). In clinical practice estimation of the functional ovarian reserve is done with antral follicle count and measurement of ovarian volume. The ovarian volume is calculated with prolate ellipsoid formula (9). Antral follicles are ultrasonographically visible actively growing follicles. They are 2-10 mm in diameter and may be seen and counted with standard transvaginal ultrasonography (10).

This study evaluated the effect of unilateral laparoscopic cystectomy on ovarian reserve. The used markers were ul-

trasonographical, ovarian volume and antral follicle count, and two biochemical markers, serum levels of Follicle-stimulating hormone and Estradiol.

2. MATERIAL AND METHODS

This prospective study was conducted in the period from 01.01.2012 to 31.12.2013 at the University Clinic for Gynecology and Obstetrics in Skopje, Republic of Macedonia. It included 31 patients with age range from 20 to 40 years. All patients had preoperative ultrasound diagnosis of unilateral ovarian endometrioma. Participants were given written and oral information about the surgery and possible complications, and they signed a consent form. The study protocol was approved by the Ethics and Research Committee of the Medical Faculty in Skopje.

The inclusion criteria were age (between 20 and 40 years) and ultrasonographic findings of unilateral ovarian endometrioma (with mean diameter of 4 cm and more). Indications for surgery were chronic pelvic pain or infertility.

Exclusion criteria were: previous adnexal surgery, history for oral contraceptive pill use or hormonal therapy for the last three cycles, other endocrine diseases such as thyroid disease, hyperprolactinemia, diabetes mellitus or adrenal disorders, patients with histopathologic diagnosis for benign ovarian cysts other than endometrioma and patients with Polycystic ovary syndrome. Transvaginal ultrasound examination of every patient in proliferative phase of menstrual cycle with measurement of three perpendicular diameters was done. Ovarian volume was calculated using "prolate ellipsoid formula" = $[D1 \times D2 \times D3 \times 0.523]$, where D1, D2 and D3 were

maximal longitudinal, antero-posterior and transverse diameters. AFC was recorded as the total number of follicles with a diameter smaller than 10 mm. Ge Voluson E8 with a 7.5 MHz vaginal probe was used for ultrasound examination.

Analysis of the biochemical markers for ovarian reserve FSH and E2 on day 3 of the menstrual cycle (MC) before surgery was done. FSH-Immulate 2000 test was used for detection of serum levels of FSH. Immulate 2000 test was used for serum levels of estradiol.

Operative laparoscopy was performed during the proliferative phase of the cycle through insertion of a 10 mm subumbilical trocar and two 5 mm trocars in the lower abdomen. After identification of the cleavage plane, the wall of the cyst was stripped from the surrounding healthy ovarian tissue with two atraumatic grasping forceps. Finally, hemostasis was achieved with electrocoagulation with bipolar forceps with a power of 30W. After the operation the tissue was sent for histological examination to confirm the diagnosis of ovarian endometrioma. All patients were examined after three months in the proliferative phase of the cycle for the same parameters.

Statistical analysis

Data were presented as mean value \pm SD. Statistical significance (for $p < 0.05$) of difference between parameters before surgery and three months after laparoscopy was determined using Student's t-test. For qualitative data were used number and percent. Statistical analyses were performed with Statistics Package for Social Sciences software (SPSS), version 12, for Windows.

3. RESULTS

This study included 31 patients in their reproductive age, between 20–40 years (31 ± 6 years), and BMI with mean values 23 ± 3.6 . Laparoscopic stripping surgical method was used. Baseline characteristics of patients with unilateral endometrioma ovarii are presented in Table 1.

Patients, n	31
Age (years)	31 ± 6
Body mass index (BMI) kg/m ²	$23 \pm 3,6$
Side of endometrioma	
Right ovary, n (%)	14 (45 %)
Left ovary, n (%)	17 (55 %)
Patients with infertility, n (%)	7 (23%)
Patients with chronic pelvic pain, n (%)	24 (77%)

Table 1. Baseline characteristics of patients with unilateral ovarian endometrioma. n.s. not significant; values are mean \pm SD

Ovarian endometrioma was located on the left ovary in 17 patients (55%) and on the right ovary in 14 (45%). Indications for surgery were chronic pelvic pain in 24 cases (77%) and infertility in 7 (23%) cases.

A significant reduction of ovarian volume after three months was found ($p < 0.01$).

The number of AFC in the treated ovary was significantly increased after three months in comparison with the AFC before surgery ($p < 0.001$).

Serum levels of FSH on the third day of menstrual cycle before surgery were 6.74 ± 4.84 mIU/ml and after three months 5.69 ± 3.30 mIU/ml, which was a non-significant decrease of FSH level. On the other hand, estradiol levels were 120.57 ± 90.88 pg/ml before surgery and 135.52 ± 91.30 pg/ml

three months after laparoscopic surgery. There was a slightly non-significant increase of estradiol levels. The results are presented in Table 2.

Variables	Before surgery	Three months after surgery	Student t-test	p
Ovarian volume (ml)	76.64 ± 66.13	12.56 ± 10.81	5.57	< 0.01
AFC (n)	3 ± 1.34	5.48 ± 1.96	-9.34	< 0.001
FSH (mIU/ml)	6.74 ± 4.84	5.69 ± 3.30	1.54	n.s.
Estradiol (pg/ml)	120.57 ± 90.89	135.52 ± 91.30	-0.80	n.s.

Table 2. Ultrasonographic and biochemical parameters for ovarian reserve before and three months after laparoscopic cystectomy of ovarian endometrioma.

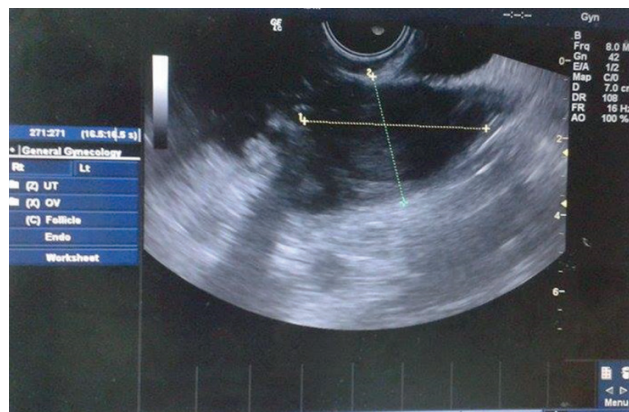


Figure 1 Endometrium of the right ovary

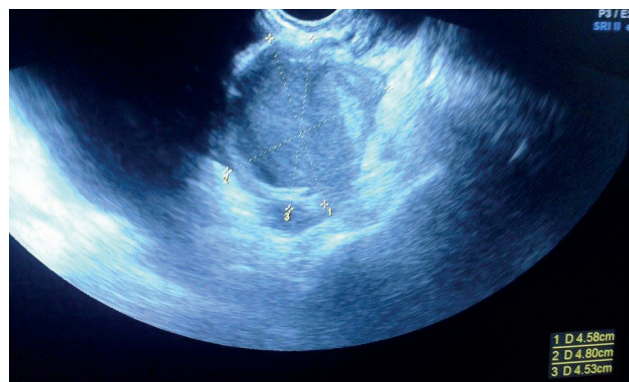

Figure 2. Endometrium of the left ovary

4. DISCUSSION

Today laparoscopy should be considered as the gold-standard treatment of ovarian endometriomas. There is no ideal technique for this treatment (3). Excision of the cyst is recommended. The cause is a higher pregnancy rate and a lower recurrence rate (4).

According to several studies that reported data on the stripping procedure the removal of the cyst wall may result in removal of healthy ovarian tissue with loss of follicles (2, 3, 4). The study of Muzii et al. demonstrated, by histologic analysis, that some ovarian tissue was removed together with the endometrioma (pseudocapsule) in 54% of the cases (5). Benaglia L. et al. found 13% of severe ovarian damage following laparoscopic surgery for unilateral ovarian endometriomas (11).

The results of Candiani M. et al. showed that laparoscopic cystectomy with electrocoagulation was associated with a significant reduction in ovarian reserve after surgery, which was partially a consequence of the damage of the ovarian

vascular system (12). Our study has shown that the ovarian tissue is reduced after surgery. This results are similar with the study of Salem A.H. et al. They found significant reduction in ovarian volume three months after laparoscopic cystectomy because of ovarian endometrioma (13). The significant increase of AFC after three months is similar with the results obtained in the study of Pados et al. They reported an increase of the number of antral follicles six month after laparoscopy (14). FSH levels were decreased after three months follow-up, which showed a good ovarian reserve because the ovary produced more hormones (E2) to inhibit production of FSH. These data are similar with the results of Broekmans FJ et al. (15).

5. CONCLUSION

Laparoscopic surgical treatment of unilateral ovarian endometrioma affected ovarian reserve early after surgery. It led to a significant reduction in ovarian volume. On the other hand, laparoscopic treatment of ovarian endometriomas with stripping increased AFC and estradiol levels after three months. These women had better ovarian function after laparoscopic surgery.

CONFLICT OF INTEREST: NONE DECLARED.

REFERENCES

1. Somigliana E, Vercellini P, Ragni G, Grosignani PG. Should endometriomas be treated before IVF-ICSi cycles? *Hum Reprod Update*. 2006; 12: 57-64.
2. Muzii L, Bellati F, Palaia I, Plotti F, Mancini N, Zullo AM. et al. Laparoscopic stripping of endometriomas: a randomized trial on different surgical techniques. Part 1: Clinical results. *Hum Reprod*. 2005; 20(7): 1981-1986.
3. Beretta P, Franchi M, Chezzi F, Busacca M, Zupi E, Bolis P. Randomized clinical trial of two laparoscopic treatments of endometriomas: cystectomy versus drainage and coagulation. *Fertil Steril*. 1998; 70: 1176-1180.
4. Alborzi S, Momtahan M, Parsanezhad ME, Dehbashi S, Zolghadri J, Alborzi S. A prospective, randomized study comparing laparoscopic ovarian cystectomy versus fenestration and coagulation in patients with endometriomas. *Fertil Steril*. 2004; 82: 1633-
5. Muzii L, Bellati F, Bianchi A, Palaia I, Mancini N, Zullo AM, et al. Laparoscopic stripping of endometriomas: a randomized trial on different surgical techniques. Part II pathological results. *Hum Reprod*. 2005; 20(7): 1987-1992.
6. Yeung PP, Shwayder J, Pasic PP. Laparoscopic management of endometriosis: Comprehensive Review of Best Evidence. *J Minim Invasive Gynecol*. 2009; 16: 269-281.
7. Var T, Batioglu S, Tonguc E, Kahyaoglu I. The effect of laparoscopic ovarian cystectomy versus coagulation in bilateral endometriomas on ovarian reserve as determined by antral follicle count and ovarian volume: a prospective randomized study. *Fertil Steril*. 2011; 95(7): 2247-2250.
8. Park CJ, Bae JG, Kim JI, Rhee JH. Assessment of ovarian volume and hormonal changes after ovarian cystectomy in the different ovarian tumor. *Korean J Reprod Med*. 2008; 35(2): 155-162.
9. Lass A, Skull J, McVeigh E, Margara R. and Winston M.L. Measurement of ovarian volume by transvaginal sonography before ovulation induction with human menopausal gonadotrophin for in-vitro fertilization can predict poor response. *Hum Reprod*. 1997; 12(2): 294-297.
10. Zaitoun MM, Zaitoun MM, El Behery MM. Comparing long term impact on ovarian reserve between laparoscopic ovarian cystectomy and open laparotomy for ovarian endometrioma. *J Ovarian Res*. 2013; 6: 76.
11. Benaglia L, Somigliana E, Vighi V, Ragni G, Vercellini P, Fedele L. Rate of severe ovarian damage following surgery for endometriomas. *Hum Reprod*. 2010; 25(3): 678-682.
12. Candiani M, Barbieri M, Bottani B, Bertulesi C, Vignali M, Agnoli B, et al. Ovarian recovery after laparoscopic enucleation of ovarian cysts: insights from echographic short-term postsurgical follow-up. *J Minim Invasive Gynecol*. 2005; 12(5): 409-414.
13. Salem A.H, Hegab M.H, Elkaffash M.D, Azb H. and Hosny A.T. Assessment of the ovarian reserve before and after laparoscopic surgery using two different techniques for ovarian endometrioma. *J Med Dent Sci*. 2013; 6(5): 43-48.
14. Pados G, Tsolakidis D, Assimakopoulos E. et al. Sonographic changes after laparoscopic cystectomy compared with three-stage management in patients with ovarian endometriomas: a prospective randomized study. *Hum Reprod*. 2010; 25(3): 672-677.
15. Broekmans FL, Kwee J, Hendriks DJ, Mol BW, Lambalk CB. A systematic review of tests predicting ovarian reserve and IVF outcome. *Hum Reprod*. 2006; 12(6): 685-718.