









A Case Report of Cholangiocarcinoma Arising from a Biliary Adenofibroma: Radiologic Findings and Review of Literature

담도선섬유종에서 발생한 담관암:
증례 보고 및 문헌적 고찰

Hyun-Ji Lim, MD¹ , Mi-Suk Park, MD^{2*} , Young Nyun Park, MD³ ,
Sun Il Kim, MD³ , Yeo-Eun Kim, MD¹ , Cheong Hoon Hwang, MD² 

¹Department of Radiology, Seoul Medical Center, Seoul, Korea
Departments of ²Radiology and ³Pathology and Research Institute of Radiological Science, Severance Hospital, Yonsei University College of Medicine, Seoul, Korea

Biliary adenofibromas are rare biliary epithelial tumors that are classified as benign. Nevertheless, some cases have been reported to show malignant transformations. The radiologic findings of biliary adenofibromas and their malignant transformation are not well-established because of their rarity. We present a case of a cholangiocarcinoma arising from a biliary adenofibroma assessed using ultrasonography, CT, and MRI. The differential diagnoses include other hepatic tumors.

Index terms Bile Duct Neoplasms; Adenofibroma; Cholangiocarcinoma

INTRODUCTION



Biliary adenofibroma is a biliary epithelial tumor characterized by tubule-cystic bile duct proliferation lined with non-mucin-secreting biliary epithelium embedded in abundant fibroblastic stroma (1). Biliary adenofibroma was first recognized by Tsui et al. (1) and was accepted as a distinct primary hepatic neoplasm of bile duct origin in the 2010 World Health Organization (WHO) classification. Despite the fact that biliary adenofibroma has been classified as a benign biliary tumor by the WHO, some cases have shown a malignant transition. To date, among the 24 cases in the literature, eight cases showed malignant transformations: three cholangiocarcinomas, one cholangio-

Received March 13, 2020
Revised May 3, 2020
Accepted August 10, 2020

*Corresponding author
Mi-Suk Park, MD
Department of Radiology and
Research Institute of
Radiological Science,
Severance Hospital,
Yonsei University
College of Medicine,
50-1 Yonsei-ro, Seodaemun-gu,
Seoul 03722, Korea.
Tel 82-2-2228-7400
Fax 82-2-393-3035
E-mail RADPMS@yuhs.ac

This is an Open Access article distributed under the terms of the Creative Commons Attribution Non-Commercial License (<https://creativecommons.org/licenses/by-nc/4.0>) which permits unrestricted non-commercial use, distribution, and reproduction in any medium, provided the original work is properly cited.

ORCID iDs

Hyun-Ji Lim 
<https://orcid.org/0000-0001-5537-2360>
Mi-Suk Park 
<https://orcid.org/0000-0001-5817-2444>
Young Nyun Park 
<https://orcid.org/0000-0003-0357-7967>
Sun Il Kim 
<https://orcid.org/0000-0002-3295-9270>
Yeo-Eun Kim 
<https://orcid.org/0000-0002-6876-8871>
Cheong Hoon Hwang 
<https://orcid.org/0000-0001-9911-7310>

cellular carcinoma, two invasive carcinomas, and two adenocarcinomas (2, 3). three cholangiocarcinomas, one cholangiocellular carcinoma, two invasive carcinomas, and two adenocarcinomas. Because of the relatively high incidence of malignant transformation, biliary adenofibroma is one of the candidates for the development of cholangiocarcinoma, along with bile duct adenoma and von Meyenburg complex (VMC) (4). However, radiologic imaging findings of cholangiocarcinoma arising from biliary adenofibroma are not well established due to its scarcity and most reports focus on pathologic findings. We report a case of cholangiocarcinoma slowly arising from a biliary adenofibroma with images obtained using ultrasonography (US), CT, and MRI, along with the differential diagnosis from other hepatic tumors.

CASE REPORT

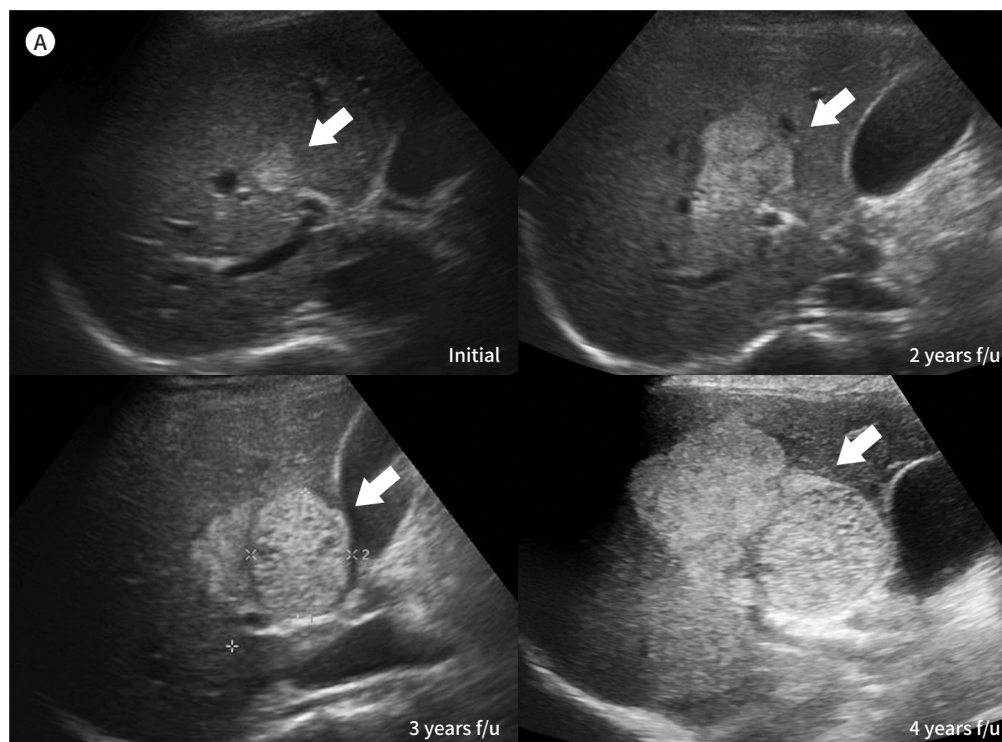
A 44-year-old female with chronic hepatitis B was referred to our hospital for a liver mass incidentally detected on US during hepatocellular carcinoma surveillance. The patient did not have any symptoms. Laboratory tests revealed normal liver function. Her carbohydrate antigen 19-9 was elevated to 50.7 U/mL (normal range, 0–34 U/mL). Other tumor markers, including alpha-fetoprotein, protein induced by vitamin K absence or antagonist-II, and carcinoembryonic antigen were not elevated.

On initial US taken four years ago, there was a small hyperechoic mass with tiny cysts. On

Fig. 1. Intrahepatic cholangiocarcinoma arising from a biliary adenofibroma.

A. Serial ultrasonography images for four years reveal a small hyperechoic mass with a small cystic lesion that increased in size and changed in shape into a bi-lobulated well-defined heterogeneous hyperechoic mass with several small anechoic lesions (arrows) within the left side of the mass.

f/u = follow up



serial USs, the mass increased in size every year, from 1.6 cm × 1.0 cm to 8.5 cm × 5.5 cm. It changed in shaped into a bi-lobulated well-defined heterogenous hyperechogenic mass (Fig. 1A). CT scan revealed a well-circumscribed bi-lobulated tumor of approximately 9 cm in segments 5 and 6 of the liver. The mass was composed of two different components: the right side of the lesion showed arterial hyperenhancement and peripheral washout on venous phases, whereas the left side was hypodense with an enhancing rim on all dynamic phases (Fig. 1B). After 5 months, the patient underwent liver dynamic MRI with gadoterate meglumine (0.1 mmol/kg; Dotarem; Guerbet, Roissy, France). MRI revealed that the size of the mass had increased since the previous CT images were obtained. The right side of the mass showed arterial hyperenhancement and peripheral washout, whereas the left side was hypointense with an enhancing rim on all dynamic phases. The right side of the lesion showed

Fig. 1. Intrahepatic cholangiocarcinoma arising from a biliary adenofibroma.

B. Dynamic CT images show a well-circumscribed bi-lobulated tumor with two different components with a different enhancement pattern.

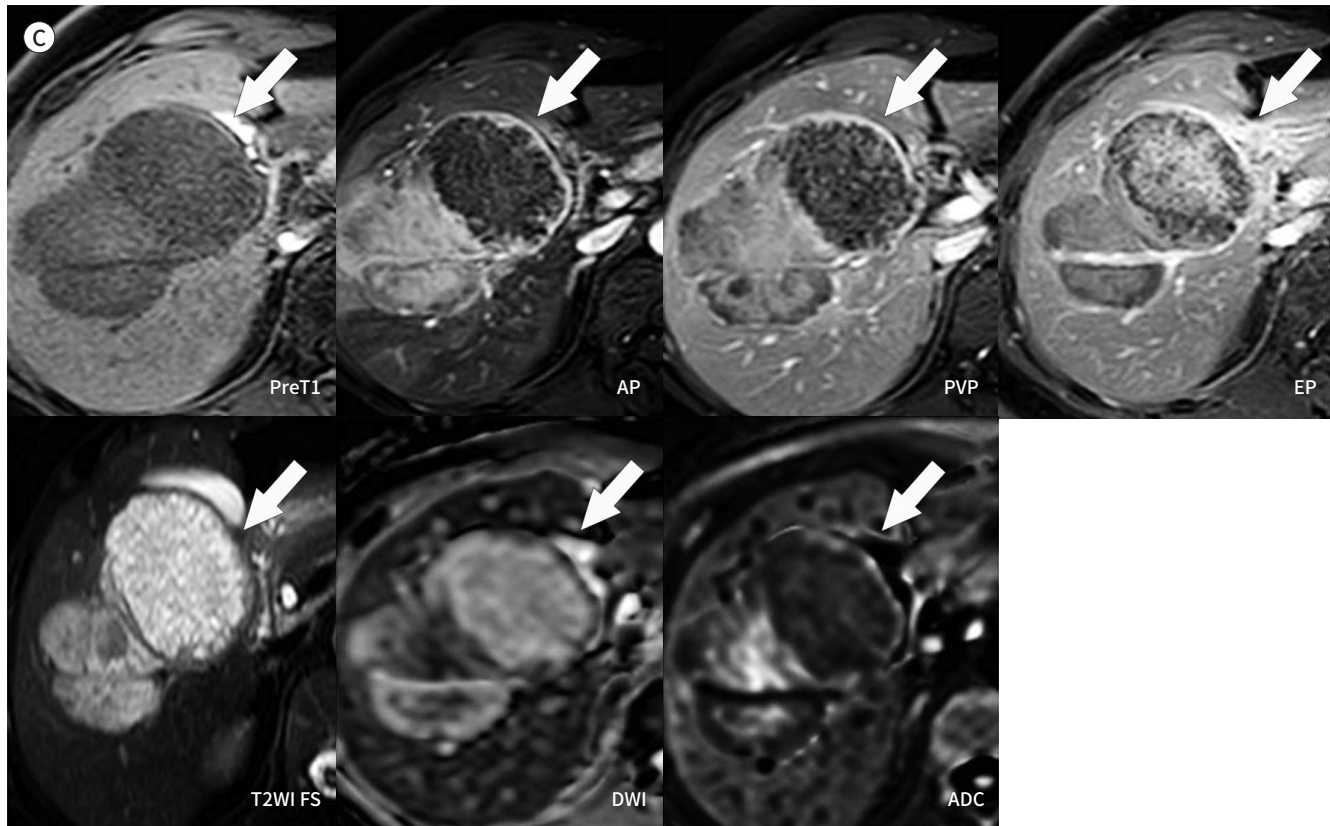
AP = arterial phase, EP = equilibrium phase, PP = portal phase, Pre = pre-contrast phase

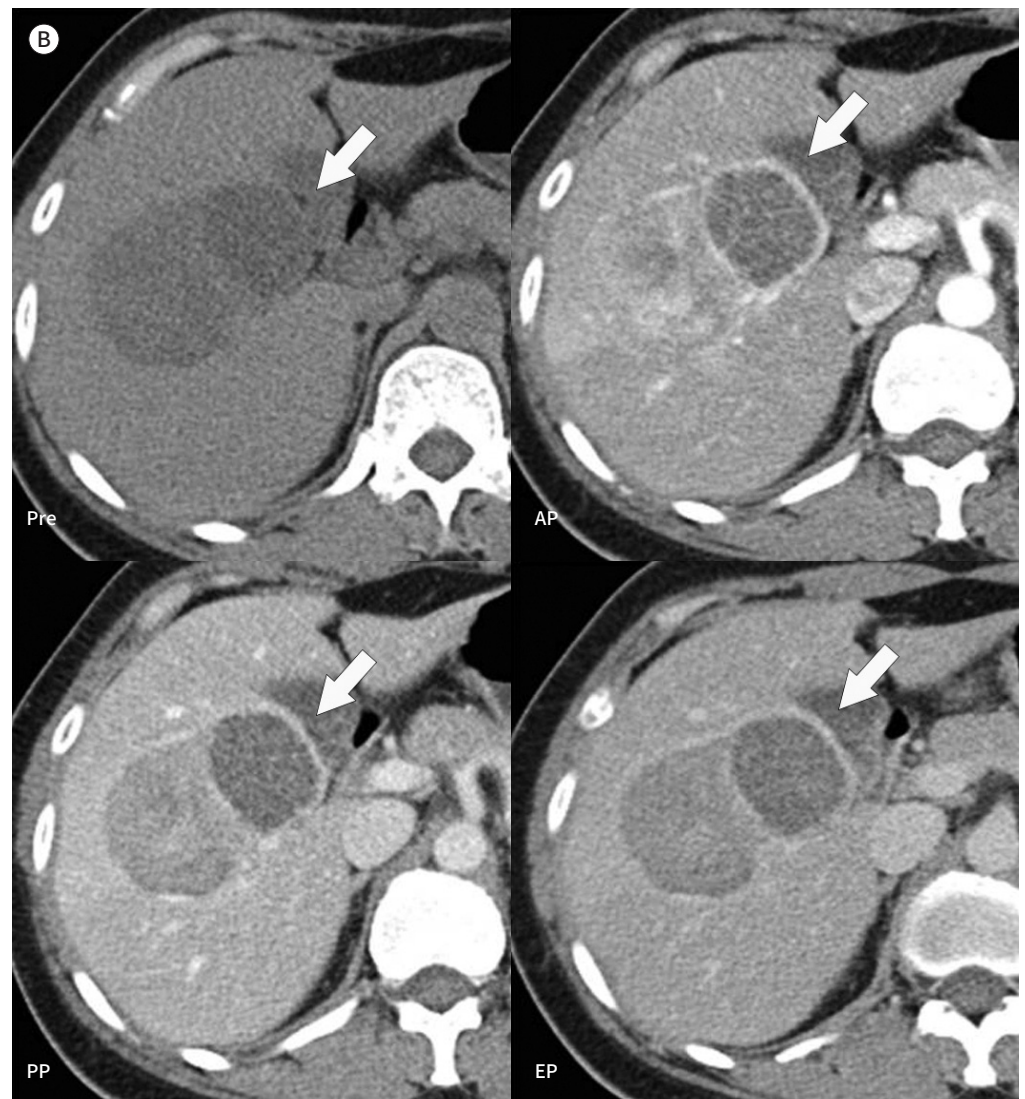

Fig. 1. Intrahepatic cholangiocarcinoma arising from a biliary adenofibroma.

C. MR images show a bi-lobulated tumor composed of a solid tumor on the right side and a microcystic lesion on the left side (arrows).

ADC = apparent diffusion coefficient map, AP = arterial phase, DWI = diffusion-weighted image, EP = equilibrium phase, Pre T1 = pre-contrast phase T1, PVP = portal venous phase, T2WI FS = T2-weighted image with fat saturation



a moderately high signal on T2-weighted imaging (T2WI) and a target appearance on diffusion-weighted imaging (DWI), suggesting a solid tumor. The left side of the lesion showed innumerable tiny bright signal foci on T2WI and free diffusion on DWI, similar to a microcystic lesion (Fig. 1C). The patient underwent a right lobectomy.

Gross pathologic specimen revealed a 9.7 cm × 9.6 cm × 6.7 cm mass (Fig. 1D). The mass showed two distinct histologic patterns. The right side of the mass was confirmed as a well-differentiated, small duct type cholangiocarcinoma and the left side as a biliary adenofibroma. There was no communication with intrahepatic bile ducts. No lymphadenopathy was observed. Microscopic sections showed two different components: a high cellularity with compact proliferation of irregular shaped glands on the right side (cholangiocarcinoma) and low cellularity with predominantly cystic growth pattern on the left side (biliary adenofibroma) (Fig. 1E 1st). Higher magnification of biliary adenofibroma showed variable sized cysts lined by a single layer of non-mucin secreting cuboidal epithelium [hematoxylin and eosin (H&E) stain, × 40] (Fig. 1E 2nd). In biliary adenofibroma, epithelial lining showed bland looking nuclei and amphophilic cytoplasm. Collagenous fibrotic stroma was composed of bland spindle-shaped fibroblasts (H&E stain, × 200) (Fig. 1E 3rd). Higher magnification of cholangiocarcinoma showed high cellularity area with compact proliferation of irregular

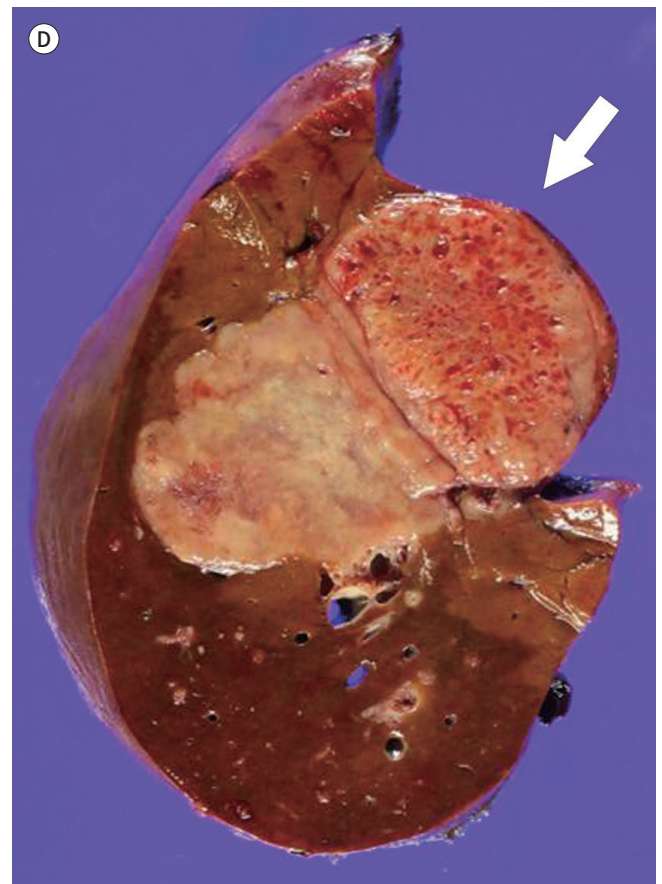


Fig. 1. Intrahepatic cholangiocarcinoma arising from a biliary adenofibroma.

D. The cut surface of the gross pathologic specimen shows two histologic patterns: the right side of the lesion shows a well-differentiated cholangiocarcinoma, while the left side (arrow) shows a biliary adenofibroma with microcystic components.

shaped glands (Fig. 1E 4th). The compact proliferation of small sized glands composed of tumor cells with high nuclear/cytoplasm ratio and prominent nucleoli, indicating well-differentiated cholangiocarcinoma (H&E stain, $\times 200$) (Fig. 1E 5th). Immunohistochemically, the lesion stained positive for Ki-67 (about 30%; 70% in hot spot) and p53, with lower nuclear expression in the biliary adenofibroma. In the area of the cholangiocarcinoma, the mass showed a small duct-type immunoprofile: positive for CD56, negative for S100P and Ncadherin in the tumor cells, and negative for mucicarmin and Alcian blue/periodic acid Schiff for mucin. The background liver showed features of chronic hepatitis consistent with a hepatitis B virus infection. Based on these findings, the mass was confirmed as an intrahepatic cholangiocarcinoma (small duct type) arising from a biliary adenofibroma.

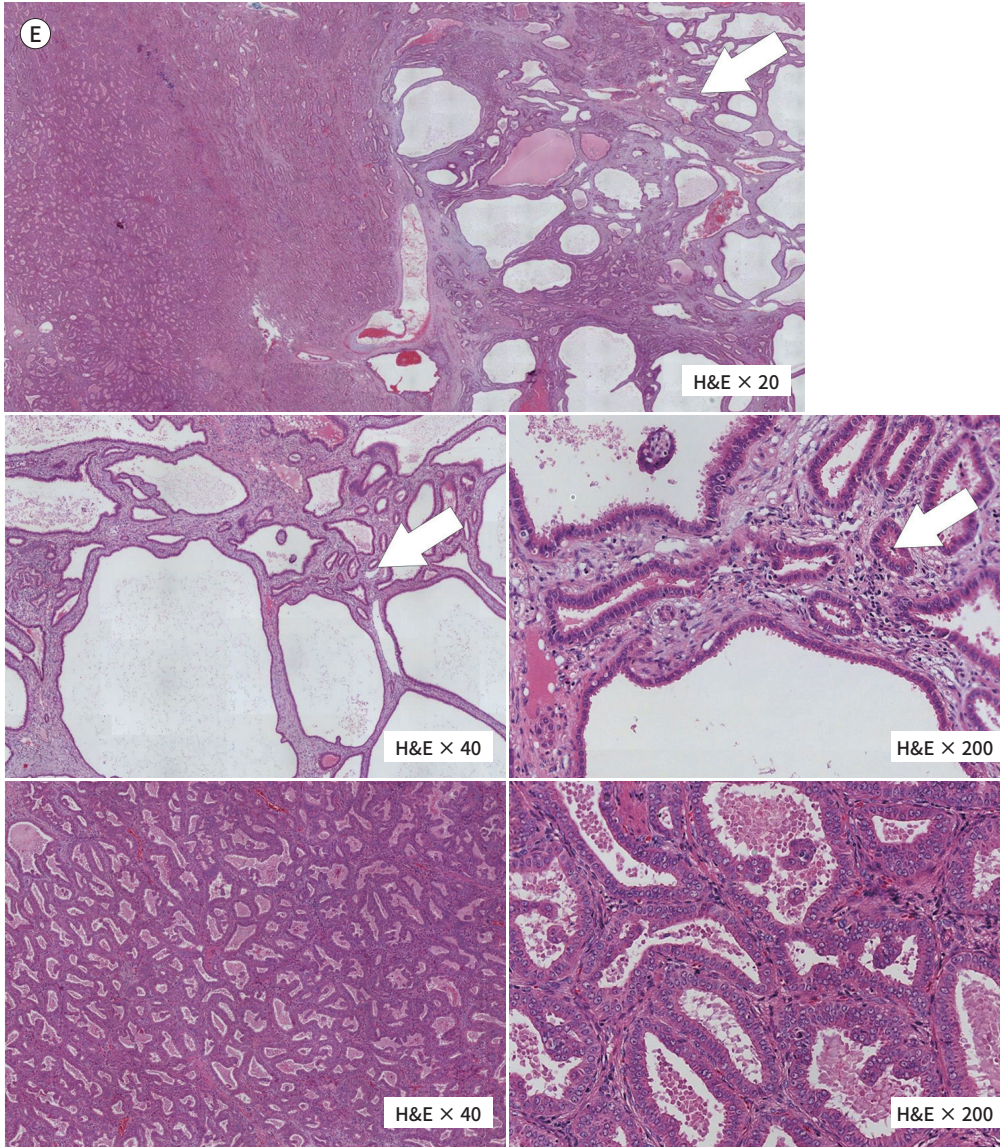
DISCUSSION

We present a rare case of intrahepatic cholangiocarcinoma arising from a biliary adenofibroma with US, CT, and MRI findings.

Supplementary Table 1 (in the online-only Data Supplement) summarized clinical and imaging findings of biliary adenofibroma with malignant transformation. Biliary adenofibroma with malignant transformation usually shows both of cystic and solid component, either mixed or clear boundary (2, 3). Half of the cases show two distinct components; microcystic

Fig. 1. Intrahepatic cholangiocarcinoma arising from a biliary adenofibroma.

E. Microscopic specimen shows two distinct histologic patterns side-by-side (H&E stain, $\times 20$). The right side of the lesion shows compact and high cellularity (cholangiocarcinoma), whereas the left side of the lesion (arrows) shows loose and low cellularity and a predominant cystic growth pattern (biliary adenofibroma). H&E = hematoxylin and eosin



component and heterogenous enhancing solid one (2, 3). Our case showed a bi-loculated mass with a clear boundary between solid and cystic component, side by side. The right side showed a solid enhancing mass, confirmed as small duct-type cholangiocarcinoma, whereas the left side showed a cystic lesion, confirmed as biliary adenofibroma. Typical imaging features of mass-forming intrahepatic cholangiocarcinoma include peripheral rim enhancement or diffuse hypoenhancement (5). Unlike usual cholangiocarcinoma, the solid mass of our case showed non-rim hyperenhancement in the arterial phase. The arterial enhancement pattern is similar to hepatocellular carcinoma, which makes differential diagnosis difficult. However, non-rim arterial hyperenhancement of mass-forming intrahepatic cholan-

giocarcinoma is not uncommon in the clinical setting, especially in the patients with chronic viral liver disease and liver cirrhosis (6). A recently proposed pathologic classification categorize mass-forming intrahepatic cholangiocarcinoma into small duct (peripheral to second-order branches) and large duct (second-order branches or larger) types based on their anatomic location and histopathologic features (6, 7). There have been several reports that arterial hyperenhancement is more frequently observed in small duct type cholangiocarcinoma than in large duct type (6, 7). Our case was a small duct type cholangiocarcinoma in a patient with chronic hepatitis B, which is consistent with known factors related to the atypical (non-rim hyperenhancement) enhancement of cholangiocarcinoma. Unlike typical hepatocellular carcinoma, however, our case showed peripheral washout on venous phases and targetoid appearance on diffusion weighted image, which could be clue to differentiate it from hepatocellular carcinoma (8).

Biliary adenofibroma is a well-defined multiseptated multicystic tumor, ranging from 2.7 cm to 16 cm. On MRI, it shows hyposignal intensity in precontrast T1WI, hypersignal intensity on T2WI, and septal and wall enhancement on contrast administration (2). Cystic appearance of biliary adenofibroma should be differentiated from VMC, which is a type of ductal plate malformation (3). Although rare, malignant transformation of VMCs to intrahepatic cholangiocarcinoma is reported in several cases and it can also shows bilobular mass with cystic and solid portion (9). However, the diagnosis can be made only by histologic confirm (9). VMCs are typically less than 0.5 cm size and most biliary adenofibromas are larger, ranging from 2.7 cm to 16 cm (9). Also, biliary adenofibromas lack typical VMC in the background liver. Other differential diagnoses for biliary adenofibroma include intraductal papillary neoplasm of the bile duct (IPNB), bile duct adenoma, biliary cysts, mucinous cystic neoplasm (MCN), and benign cystic mesothelioma of the liver (2). IPNB necessarily involves communication between the lesion and the bile duct system (3). Biliary adenofibroma lacks communication with the duct. Bile duct adenoma is a well-defined, small sized lesion less than 1 cm, usually located underneath the liver capsule (3). Biliary adenofibroma is usually larger. MCN is a large sized cystic tumor with multilocular appearance, typically up to 15 cm. MCN involves mucinous cytoplasm with ovarian stroma, showing a female predominance (3). Biliary adenofibroma do not contain ovarian stroma. Benign cystic mesothelioma is a rare neoplasm showing large, partially cystic, well-encapsulated lesion. It is characterized by anastomosing cords of tumor cells, separated by large thick wall vessels (10). It can be differentiated by lack of immune response to calretinin antibody (10). In most cases, it is difficult to differentiate these tumors from biliary adenofibroma based on radiologic findings only. Pathologic diagnosis is needed.

In conclusion, biliary adenofibroma is a rare benign tumor but can be associated with malignant tumor, mostly cholangiocarcinoma. Radiologically, if a tumor shows both a microcystic and a solid mass, biliary adenofibroma with malignant transformation should be considered as the differential diagnosis.

Supplementary Materials

The online-only Data Supplement is available with this article at <http://dx.doi.org/10.3348/jksr.2020.0043>.

Author Contributions

Conceptualization, P.M.; data curation, L.H., K.S.I., H.C.H.; supervision, K.Y.; writing—original draft, L.H.; and writing—review & editing, P.M., P.Y.N.

Conflicts of Interest

The authors have no potential conflicts of interest to disclose.

Funding

None

REFERENCES

1. Tsui WM, Loo KT, Chow LT, Tse CC. Biliary adenofibroma. A heretofore unrecognized benign biliary tumor of the liver. *Am J Surg Pathol* 1993;17:186-192
2. Lee S, Kim KW, Jeong WK, Yu E, Jang KT. Magnetic resonance imaging findings of biliary adenofibroma. *Korean J Gastroenterol* 2019;74:356-361
3. Sturm AK, Welsch T, Meissner C, Aust DE, Baretton G. A case of biliary adenofibroma of the liver with malignant transformation: a morphomolecular case report and review of the literature. *Surg Case Rep* 2019;5:104
4. Nakanuma Y, Tsutsui A, Ren XS, Harada K, Sato Y, Sasaki M. What are the precursor and early lesions of peripheral intrahepatic cholangiocarcinoma? *Int J Hepatol* 2014;2014:805973
5. Min JH, Kim YK, Choi SY, Kang TW, Lee SJ, Kim JM, et al. Intrahepatic mass-forming cholangiocarcinoma: arterial enhancement patterns at MRI and prognosis. *Radiology* 2019;290:691-699
6. Aishima S, Oda Y. Pathogenesis and classification of intrahepatic cholangiocarcinoma: different characters of perihilar large duct type versus peripheral small duct type. *J Hepatobiliary Pancreat Sci* 2015;22:94-100
7. Nam JG, Lee JM, Joo I, Ahn SJ, Park JY, Lee KB, et al. Intrahepatic mass-forming cholangiocarcinoma: relationship between computed tomography characteristics and histological subtypes. *J Comput Assist Tomogr* 2018;42:340-349
8. Park HJ, Kim YK, Park MJ, Lee WJ. Small intrahepatic mass-forming cholangiocarcinoma: target sign on diffusion-weighted imaging for differentiation from hepatocellular carcinoma. *Abdom Imaging* 2013;38:793-801
9. Kim HK, Jin SY. Cholangiocarcinoma arising in von Meyenburg complexes. *Korean J Hepatol* 2011;17:161-164
10. Gurrera A, Alaggio R, Leone G, Aprile G, Magro G. Biliary adenofibroma of the liver: report of a case and review of the literature. *Patholog Res Int* 2010;2010:504584

담도선섬유종에서 발생한 담관암: 증례 보고 및 문헌적 고찰

임현지¹ · 박미숙^{2*} · 박영년³ · 김선일³ · 김여은¹ · 황청훈²

담도선섬유종은 매우 드문 담도상피성 종양으로서 양성 종양으로 분류된다. 그럼에도 불구하고, 담도선섬유종으로부터 악성 종양이 발생했다는 몇 개의 증례가 보고되어 왔다. 하지만 담도선섬유종과 그로부터 발생한 악성 신생물에 대한 영상의학적 소견은 잘 알려져 있지 않다. 우리는 담도선섬유종에서 발생한 담관암의 증례를 초음파, 컴퓨터단층촬영, 자기공명영상 사진과 함께 설명하고, 이와 감별할 질환들의 영상의학적 소견을 고찰하고자 한다.

¹서울의료원 영상의학과, 연세대학교 의과대학 세브란스병원 ²영상의학과, ³진단병리과