

Paralytic Ectropion Treatment with Lateral Periosteal Flap Canthoplasty and Introduction of the Ectropion Severity Score

Steven F. S. Korteweg, MD
 Martin W. Stenekes, MD, PhD
 Fiona E. van Zyl, MD
 Paul M. N. Werker, MD, PhD

Background: Paralytic ectropion patients suffer from impairment of function and appearance of the lower eyelid and are at high risk of developing an exposure keratitis. A canthoplasty procedure can reduce the horizontal eyelid laxity and elevate the lower eyelid. We used a periosteal flap from the outer orbit to create a new canthal ligament. This study investigates the long-term outcomes of this technique.

Methods: Cross-sectional outcome study in which 30 cases of paralytic ectropion are treated with a lateral periosteal flap canthoplasty after adequate eyelid shortening. At the desired canthal height, a periosteal flap from the outer temporal orbital rim is mobilized around the rim and sutured in a double-breasted fashion to a tarsal strip. Effect of the operation is measured by comparing preoperative and postoperative photographs for signs of ectropion. For this purpose, a new photograph-based scoring method [the Ectropion Severity Score (ESS)] was developed and evaluated.

Results: The ESS proved to be reliable and sensitive to the presence of ectropion. Significant improvement of the ectropion sequelae was measured after a mean follow-up period of 2 years. In 3 cases (13%), a revision procedure was necessary because of relapse of lower eyelid sagging after a mean time of 1.9 years. In these cases, the periosteal flap could be reused.

Conclusions: The ESS is a useful instrument to score the severity of paralytic ectropion. The periosteal flap canthoplasty is an effective procedure, with durable results in paralytic ectropion patients. The same periosteal flap can be used in a revision procedure. (*Plast Reconstr Surg Glob Open* 2014;2:e151; doi: 10.1097/GOX.0000000000000084; Published online 15 May 2014.)

Lower eyelid position is determined by the relationship of the globe to the bony orbit,¹ the balance between gravity and tissue elasticity,

From the Department of Plastic Surgery, University Medical Center Groningen, Groningen, The Netherlands.

Received for publication July 3, 2013; accepted February 13, 2014.

Presented at Annual Meeting of the Dutch Society of Plastic and Reconstructive Surgery, October 2012, Groningen, The Netherlands.

Copyright © 2014 The Authors. Published by Lippincott Williams & Wilkins on behalf of The American Society of Plastic Surgeons. PRS Global Open is a publication of the American Society of Plastic Surgeons. This is an open-access article distributed under the terms of the Creative Commons Attribution-NonCommercial-NoDerivatives 3.0 License, where it is permissible to download and share the work provided it is properly cited. The work cannot be changed in any way or used commercially.

DOI: 10.1097/GOX.0000000000000084

the support of the medial and lateral canthal ligaments, and the dynamic support of the orbicularis oculi muscle. In this system, the deep lateral canthal tendon plays a key role.²⁻⁴ It inserts inside the orbit at the lateral orbital tubercle (Whitnall's tubercle),⁵ located 2–3 mm posterior to the orbital rim. During aging, tissue elasticity gradually decreases and the static support system elongates. So maintaining the lower eyelid against the ocular surface in elderly depends more and more on the orbicularis oculi muscle. Sudden loss of innervation of this muscle as in facial palsy leads to immediate loss of active support, resulting in a paralytic ectropion, with impairment of function and appearance of the lower eyelid, in-

Disclosure: The authors have no financial interest to declare in relation to the content of this article. The Article Processing Charge was paid for by the authors.

cluding lagophthalmos, scleral show, epiphora, and a high risk of corneal drying out, which may result in exposure keratitis. Prolonged paralysis may lead to vertical shortening of the lower eyelid due to retraction of the anterior lamella.⁴

The goals of reconstructive surgery for paralytic ectropion are reducing the vertical aperture and repositioning of the lower eyelid to the globe to improve eyelid closure, ocular surface lubrication, tear drainage, and a pleasing aesthetic appearance. Because of the tissue laxity and the elongation of the lateral supporting structures in the majority of paralytic ectropion patients, canthoplasty procedures with horizontal eyelid shortening are most suitable. Care must be taken not to shorten the horizontal aperture unduly.

The lateral canthoplasty technique most commonly used for the treatment of paralytic ectropion is the lateral tarsal strip procedure² or one of the many modifications based on this procedure. Canthal tendon reinsertion can be performed in different ways: simple suturing it to the inner orbit periosteum,² suturing it to the outer orbit periosteum,⁶ suturing it through a drilling hole through the orbital wall,³ fixating it by use of a bone anchor,⁷ or by attaching it to a periosteal flap. Adequate placement of a suture inside the orbit is technically challenging and may lead to poor results if this suture tears out.^{8,9} Suturing to the outer orbit periosteum can lead to gapping between the lower lid and the globe. Difficult visualization of the needle¹⁰ and attempts to grasp the inner periosteum places the globe at risk. Drilling a hole at the level of Whitnall's tubercle to reposition the canthal ligament not only places the globe at risk but also requires extra instrumentation. Fine-tuning becomes impossible once the drill hole has been made. The use of a bone anchor has similar disadvantages. Moreover, a revision procedure is difficult as the older anchor already takes the ideal place for a bone anchor.

The use of a periosteal flap to replace the deep lateral canthal ligament has the advantage of being safe (no need to drill a hole or use a needle inside the orbit). The periosteal flap is strong and autogenous and easy to harvest. The vector of the periosteal flap is directed toward Whitnall's tubercle; therefore, it is an anatomical replacement of the normal deep lateral canthal ligament. It allows the repositioning of the eyelid into a more cranial and lateral direction, bringing the eyelid margin back against the ocular surface. It can easily be combined with other procedures and can be performed under local anesthesia.

The periosteal flap was first described in 1953 by Smith¹¹ as a method for lower eyelid reconstruc-

tion. The first report on application of the periosteal flap for correction of ectropion was in 1988 by Dryden and Edelstein.¹² Further reports in literature about paralytic ectropion treatment with a lateral periosteal flap are scarce. This study describes a large series of lateral periosteal flap canthoplasty for the treatment of paralytic ectropion. The purpose of this study was to analyze the outcomes of this operative technique in patients suffering from a paralytic ectropion. A new method for scoring ectropion on photographs is introduced. We hypothesize that the lateral periosteal flap canthoplasty is a reliable method for functional and aesthetic improvement of the paralytic ectropion sequelae with long-lasting results.

PATIENTS AND METHODS

Subjects and Data Collection

A cross-sectional outcome study was conducted on paralytic ectropion patients who underwent lateral periosteal flap canthoplasty at the University Medical Center Groningen (Groningen, The Netherlands) and the Isala Clinics (Zwolle, The Netherlands) between 2001 and 2010. Results were assessed by comparison of preoperative and postoperative photographs. The Institutional Review Board of the University Medical Center Groningen, Groningen, The Netherlands, decided that this study could be performed without formal approval. Each patient gave informed consent before participating. All procedures and data collection were conducted in a manner compliant with the Health Insurance Portability and Accountability Act.

The procedure was performed 64 times in 60 patients, of which 53 patients suffered from a paralytic ectropion; 51 patients were affected unilaterally and 2 patients were affected bilaterally, adding up to a total of 55 cases of paralytic ectropion. The charts were reviewed for demographic and follow-up information. Preoperative photographs were extracted from the electronic medical records. Fourteen cases were excluded because a preoperative photograph was not available or the photograph quality was not sufficient for photograph analysis. Eight additional cases were excluded because these patients deceased (of unrelated causes) and postoperative photographs were not available. Finally, 3 cases were excluded because the lateral periosteal flap canthoplasty was combined with another lower eyelid procedure (cartilage graft or tarsorrhaphy), which makes it impossible to judge the results of the lateral periosteal flap canthoplasty alone. Of the remaining patients (30 cases), all clinical photographs were collected.

Surgical Technique

In most cases, the procedure was performed under local anesthesia using topical oxybuprocaine hydrochloride drops in the conjunctival sac and 1% lidocaine hydrochloride with 1:100,000 epinephrine chloride injected into the lateral lower eyelid, the lateral canthal area, and along the lateral orbital rim. The lateral orbital rim was exposed with a 2-cm subciliary incision extended laterally in Borges's lines. A musculocutaneous flap was elevated and retracted. The inferior lid was cut perpendicular to the gray line approximately 2 mm medial to the lateral canthal angle. Cantholysis was performed by cutting the inferior crus of the deep lateral canthal ligament and releasing the lateral tarsal strap. The redundant length of the lower eyelid was determined by placing it under mild tension and repositioning it relative to the upper eyelid. The superfluous part of the tarsal plate was denuded on all sides. At the desired canthal position, which was usually slightly higher compared to the unaffected side, a 1-cm-long medially based rectangular periosteal flap with a 6-mm base was raised from the outer lateral orbital rim. This periosteal flap was designed to substitute the deep lateral orbital ligament, which anatomically inserts at the lateral orbital tubercle. Therefore, the flap was mobilized around the orbital rim to a point 3 mm into the orbit. The periosteal flap and the lateral end of the denuded tarsus were joined in a double-breasted fashion and sutured using a nonabsorbable Ethilon 5-0 suture (Ethicon, Johnson & Johnson, Amersfoort, The Netherlands) (Fig. 1). The dimensions of the periosteal flap allow for additional fine-tuning of the canthal height as needed. Any periosteal surplus was removed thereafter. Next,

an orbicularis muscle flap was sutured to the lateral orbital rim for further support. Adequate canthal repositioning was obtained by repositioning the gray line of the cut lateral canthal angle to the gray line of the shortened lower eyelid and the skin was sutured using a running Ethilon 6-0 suture, which was removed at the outpatient clinic after 5 days. Intraoperative photographs are shown in Figure 2.

Outcome Parameters

Ectropion is a clinical diagnosis, and several clinical grading systems exist to describe the degree of the condition. Unfortunately, our preoperative data were insufficient to use the currently available grading systems to measure the effect of the operation. Instead, we compared the preoperative and postoperative photographs for apposition of the lower eyelid and aesthetic appearance. No grading system was available in literature to quantify the severity of ectropion seen on photographs. Therefore, we developed the Ectropion Severity Score (ESS), with a maximum score of 8 points. A higher score indicates a worse ectropion. The score takes the severity of ectropion in terms of lateral and medial apposition, scleral show, conjunctival show, and roundness of the eye into account and gives an indication of the functional aspects involved in ectropion by scoring redness, excess tear film, and the position of the lacrimal punctum. The scoring system is summarized in Table 1.

Before the results of the ESS can be interpreted, both sensitivity and reliability of the ESS were investigated. Therefore, 2 investigators (S.F.S.K. and F.E.v.Z.) independently scored the affected eyes on preoperative and postoperative photographs

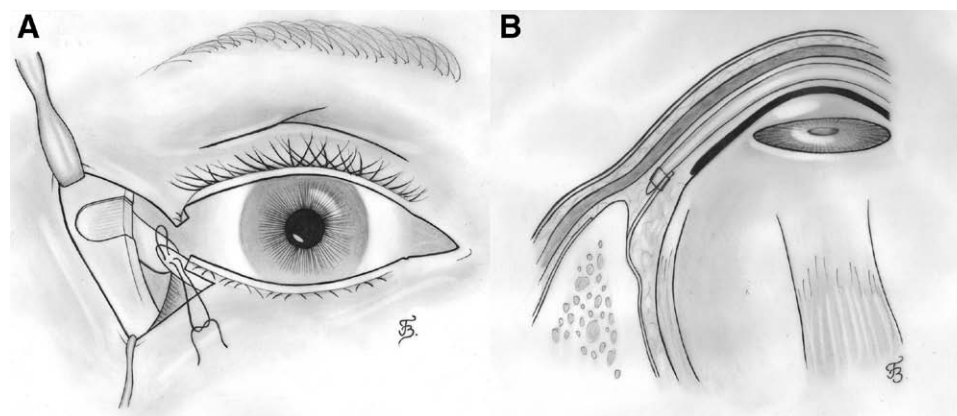


Fig. 1. Schematic representation showing the technique for the lateral periosteal flap canthoplasty. A, Frontal view. A 2-mm skin flap is left on the lateral canthal region. Partially denuded tarsus after cantholysis and horizontal shortening. Periosteal flap from the outer side of the lateral orbita is mobilized around the orbital rim. The periosteal flap and the lateral end of the denuded tarsus are sutured in a double-breasted fashion. B, Transversal view. The periosteal flap is mobilized around the orbital rim to the level of Whitnall's tubercle.

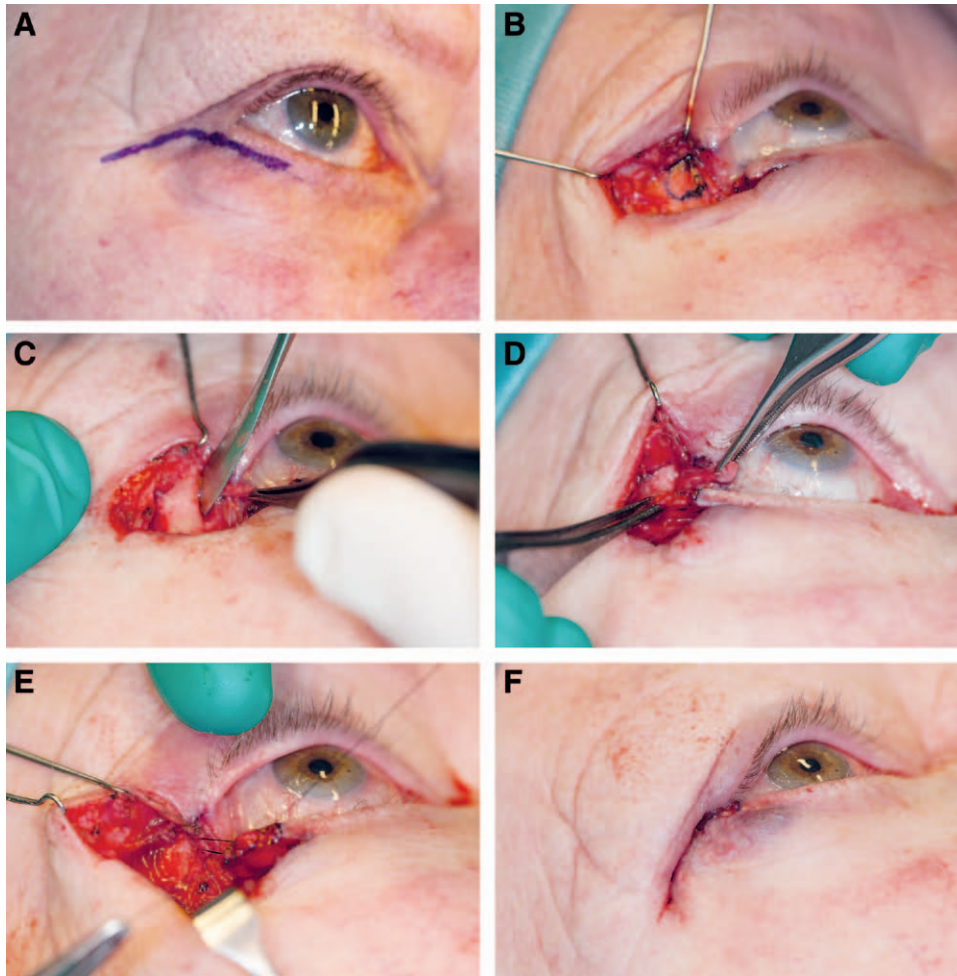


Fig. 2. Intraoperative photographs showing the technique for the lateral periosteal flap canthoplasty. A, Planning of a subciliary incision extended laterally in Borges's lines. B, Planning of the periosteal flap on the outer lateral orbital rim. C, Elevation of the periosteal flap around the orbital rim to a point 3 mm into the orbit. D, Mild tensioning of the lower eyelid against the periosteal flap to determine the redundant length. E, The periosteal flap and the lateral end of the denuded tarsus are sutured in a double-breasted fashion. F, Direct postoperative result.

and the unaffected eyes on the preoperative photographs using the ESS. Reliability was tested by comparison of the preoperative and postoperative scores of these 2 investigators and calculating the correlation between their scores. To test the validity of the ESS, we compared the scores of the affected eyes with the scores of the unaffected eyes on the preoperative photographs. Two patients suffered a bilateral paralytic ectropion: 1 patient due to Möbius syndrome and 1 patient due to a complication after a facelift procedure in another hospital. The latter patient had recent (pre-facelift) photographs available that were used to score the eyelid position bilaterally. The Möbius patient was excluded in the comparison of the ESS of the affected and unaffected eyes, so the comparison was based on 28 cases.

Statistical Analysis

Calculating intraclass correlation of the ESS of both investigators assessed interrater reliability. Sensitivity of the grading system was evaluated by comparing the ESS on the affected side with the healthy side using a paired *t* test. Finally, effects of the lateral periosteal flap canthoplasty were analyzed by comparing pre- and postoperative scores using a paired *t* test. The effects of surgery were calculated for the whole group and a subgroup with a follow-up more than 1 year. All statistical analyses were executed using SPSS 20.0.0 (IBM, Armonk, N.Y.).

RESULTS

A total of 30 cases met the initial inclusion criteria; both primary cases of paralytic ectropion ($n = 18/60\%$) and secondary cases ($n = 12 / 40\%$)

Table 1. Ectropion Severity Score

	Points per Item		
	0	0.5	1
Lateral apposition	Nonaffected	—	Affected
Medial apposition	Nonaffected	—	Affected
Sceral show	No	≤1 mm	>1 mm
Conjunctival show	No	—	Yes
Excess tear film	No	—	Yes
Redness of the eye	No	—	Yes
Round canthus	No	—	Yes
Punctum lacrimale	Invisible	Emerging	Visible
Maximum score			8 points

after a reconstruction technique other than the lateral periosteal flap canthoplasty. A patient overview is given in Table 2. Mean age at the time of operation was 65 years (range, 36–85 years). There were 19 male cases (63%) and 11 female cases (37%). The operation was performed 18 times (60%) on the right side and 12 times (40%) on the left side. All patients had a complete facial nerve paralysis with a mean duration of 14.7 years (range, 3 weeks to 62.9 years) at the time of operation. All operations were performed by a single surgeon (P.M.N.W.). Postoperative photographs were obtained in all cases. The mean follow-up period,

until time of photograph, was 2.0 years (range, 9 weeks to 8.9 years). Long-term results (defined as a follow-up of at least 1 year) were available in 23 cases, with a mean follow-up period of 2.4 years (range, 1–8.9 years).

Correct eyelid apposition was achieved in all patients with the lower eyelid hugging the ocular surface. In 3 cases (13%), a revision procedure was needed because of relapse of lower eyelid sagging after a mean time of 1.9 years. The mean age of these patients at the time of the revision procedure was 64.3 years. In these cases, the periosteal flap could be reused for canthal reinsertion and the lower eyelid was reinforced with a fascia lata sling. Some minor complications occurred. One patient complained of having a narrow palpebral fissure postoperatively, which improved within a couple of weeks. Two patients were found to have a minor granuloma at the suture line. In both patients, the granuloma healed after suture removal.

Interrater reliability of the ESS proved to be excellent [0.96; confidence interval (CI), 0.91–0.98; $P < 0.001$]. With the reliability of the ESS ascertained, further photograph analysis was based on the ESS of 1 investigator (S.F.S.K.). The affected side scored significantly worse ESS compared with the contralat-

Table 2. Patient Overview

Sex	Age	Side	Duration Paralysis		Follow-up		Complications	ESS	
			Year(s)	Month(s)	Year(s)	Month(s)		Preoperative	Postoperative
Male	71	Left	1	9	2	8	Revision with fascia lata	2.5	2
Male	67	Left	21	6	1	4		4.5	4.5
Female	57	Right	5	1	0	4		3.5	0.5
Male	65	Left	1	0	1	2		7	2.5
Female	81	Right	0	1	1	9		6	3.5
Female	56	Left	56	7	0	2		3.5	0
Female	56	Right	56	7	0	2		3	0.5
Male	84	Right	0	11	3	0		8	4
Male	65	Left	47	1	1	0		6.5	2.5
Male	54	Right	0	4	1	5	Revision with fascia lata	6.5	2
Female	66	Right	18	5	6	9		6.5	2
Male	56	Right	9	11	1	2	To tight, self-limiting	6.5	0
Male	85	Right	0	1	2	0		6	0
Male	72	Right	1	2	2	10		5	1
Male	68	Left	10	8	4	9		5	3.5
Male	74	Right	1	7	0	5		4	2.5
Female	73	Left	1	8	1	0		4.5	2
Male	47	Left	0	7	0	5		4.5	2.5
Male	72	Left	0	5	1	3		8	2
Male	62	Right	62	10	2	3		4.5	2
Male	50	Left	45	7	0	6		5.5	4
Male	75	Right	0	10	2	7	Minor granuloma	7	0
Female	68	Right	0	1	1	8		5	0.5
Female	70	Left	0	2	1	10		6.5	2
Female	70	Right	0	2	1	10		5.5	0
Female	36	Left	6	2	8	11		3	0.5
Male	68	Right	11	1	1	5		5.5	1.5
Female	59	Right	14	9	2	0	Revision with fascia lata	4.5	2.5
Male	60	Right	2	7	0	8	Minor granuloma	2	0.5
Male	63	Right	62	4	1	8		6.5	1

eral healthy side (mean difference, 5.0; CI, 4.4–5.6; $P < 0.001$), suggesting that the ESS is sensitive to the existence of ectropion. There was a significant difference in ESS before and after the lateral periosteal flap canthoplasty with a mean improvement of 3.5 points (CI, 2.8–4.2; $P < 0.001$). Improvement of the ESS in the subgroup with a follow-up period of more than 1 year was approximately the same with 3.9 points (CI, 3.1–4.7; $P < 0.001$). Two examples are given in Figures 3 and 4.

DISCUSSION

The aim of this study was to analyze the outcomes of the lateral periosteal flap canthoplasty in patients with paralytic ectropion, based on preoperative and postoperative photographs. For this purpose, the ESS is introduced as a scoring method for scoring ectropion on photographs. This system proved to be reliable and sensitive. We found that the ESS improved significantly after lateral periosteal flap canthoplasty, suggesting that this technique provides an

effective and reliable treatment in paralytic ectropion patients. The results are stable in all cases for at least 1 year.

Paralytic ectropion is a progressive disorder, with the lower eyelid support system continuing to disintegrate over time. This means that even after initial successful treatment, a revision procedure is likely to be needed somewhere in the future. In our study, a revision procedure due to relapse was necessary in 3 cases. In all these cases, the previously elevated periosteal flap could be reused, which reduced the dissection and operation time. However, the periosteum at the donor site has been reported to restore itself,¹² and in case of a revision procedure, a new flap can be raised.

Reports in literature about paralytic ectropion treatment with a lateral periosteal flap are scarce and, therefore, studies cannot be compared. Many paralytic ectropion treatments are based on the lateral tarsal strip procedure.² This procedure does not always adequately address the marked horizon-

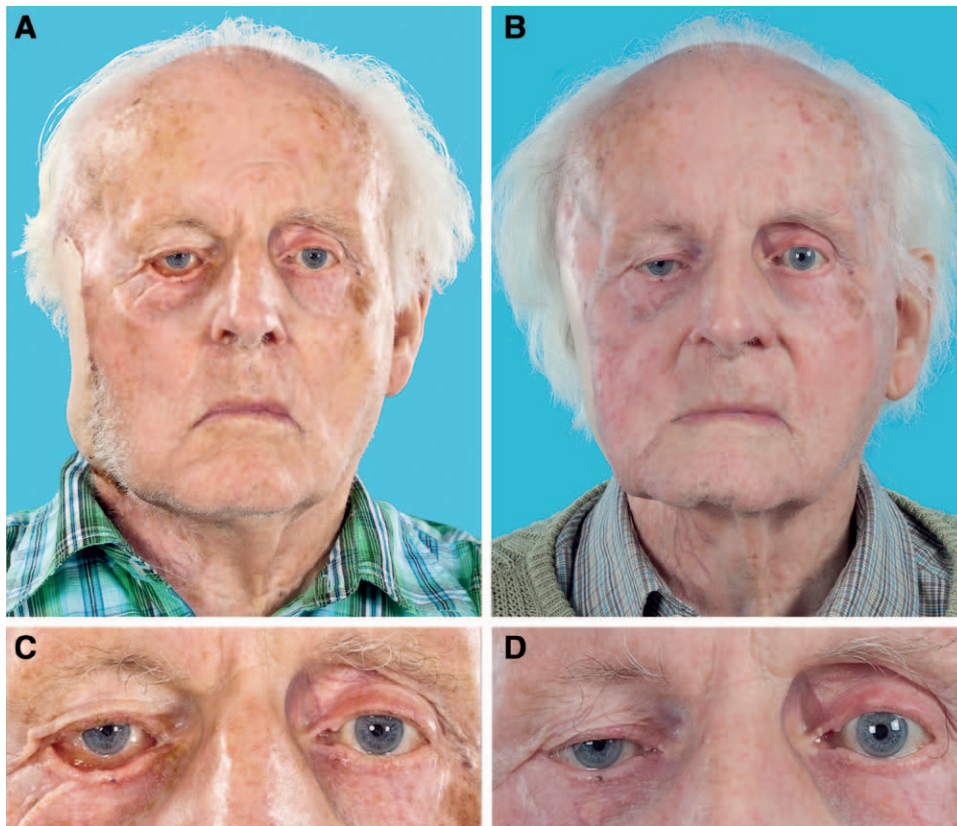

Fig. 3. A, Preoperative photograph of a patient suffering facial paralysis after resection of a large squamous cell carcinoma. A gold weight is already implanted in the upper eyelid and a static correction of the mouth is performed with fascia lata strips. An ESS of 6 was scored (lateral apposition, medial apposition, scleral show, excess tear film, round canthus, and visible punctum). B, Two years later, the lateral periosteal flap canthoplasty was performed. A good apposition of the lower eyelid was obtained (ESS, 0). C, Close-up view of A. D, Close-up view of B.

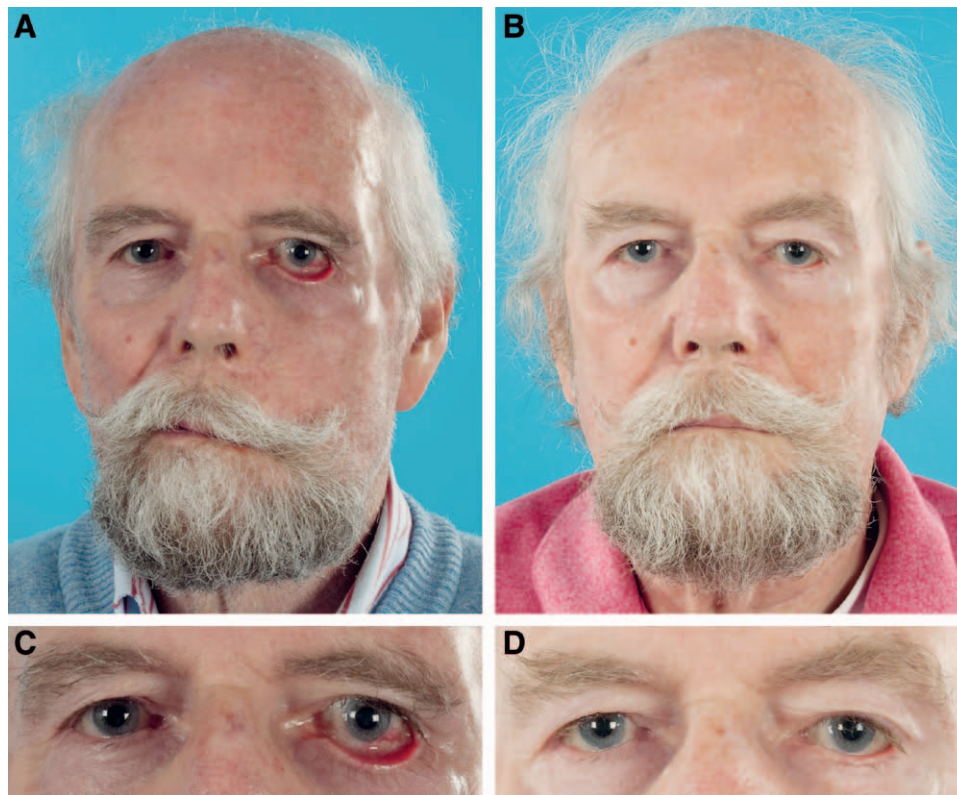

Fig. 4. A, Preoperative photograph of a patient suffering facial paralysis due to a trauma. An ESS of 8 was scored (maximal score). A gold weight is implanted in the upper eyelid at the same time the lateral periosteal flap canthoplasty was performed. B, One year and three months later, the lateral periosteal flap canthoplasty was performed. A moderate apposition of the lower eyelid was obtained. ESS is 2 because of a visible punctum and a slightly decreased lateral apposition. C, Close-up view of A. D, Close-up view of B.

tal eyelid laxity found in unrecovered facial nerve palsy, nor does it always elevate the lower eyelid sufficiently to provide corneal protection. Therefore, Chang and Olver⁶ described the augmented lateral tarsal strip tarsorrhaphy; a long tarsal strip (10–15 mm) which is brought up through the anterior lamella of the upper eyelid then attached high up on the outer aspect of the orbital rim. This is one of the more recent techniques described in literature. Compared with this technique, the lateral periosteal flap canthoplasty is easier to perform and requires less dissection. Furthermore, the periosteal flap is an adequate replacement of the deep lateral canthal tendon. The horizontal laxity can be treated properly and increasing the length of periosteal flap can extend the elevation. Chang and Olver⁶ report a 93% success rate after a mean follow-up of 21 months, which is comparable with our results.

The limitations of this study include the retrospective evaluation of the ectropion severity based on photographs. Clinical ectropion grading scales³ cannot be used in retrospective studies like ours,

unless the results are already noted in the medical files. A new scoring method was necessary to rate the outcome of ectropion repair based on photographs. Assessment depended heavily on the method and quality of photography, which proved to be occasionally inconsistent. Fourteen cases (27%) were excluded because a preoperative photograph was not available or the photograph quality was not sufficient for photograph analysis. Direct postoperative photographs were not available in all cases so the results could not be monitored in time. Although the ESS was tested for reliability, and it proved to be sensitive for the existence of ectropion, a formal validity test was not performed. Another limitation is the short follow-up period in some cases. As a result of the study design, there is a huge difference in follow-up periods between several cases. To overcome part of the problem, we computed the results for the entire group that was included and for a distinct subgroup with more than 1-year follow-up.

The lateral periosteal flap canthoplasty alone is useful in the majority of the paralytic ectropion

patients. Careful preoperative selection of patients seems to be the most important factor to a successful outcome. The position of the globe relative to the lower eyelid and midface needs to be investigated. When the globe prominence is relatively anterior to the lower eyelid and midface (negative vector), lid tightening can bowstring the globe, leading to an increase in scleral show. Several options remain depending on the severity of the globe prominence.¹³ Manual lateral traction on the lateral portion of the lower eyelid mimics the postoperative result. When the ectropion is predominantly medial or has a medial component that cannot be resolved by lateral canthoplasty alone, the medial canthal region should be addressed, or otherwise, it may predispose the patient to epiphora. Manual upward traction to elevate the lower eyelid is used to assess possible vertical shortening and can help differentiate between tightness in the anterior lamella or the middle lamella.^{1,14} Without treatment for vertical tightness, the lower eyelid will not be elevated after a lateral periosteal flap canthoplasty.

The lateral periosteal flap canthoplasty can easily be combined with other periorbital procedures such as a gold weight implant, an upper and lower eyelid blepharoplasty, a browlift, a medial canthoplasty, medial tarsal suspension, a sub-orbicularis oculi fat lift, midface lift, a fascial sling, and a vertical support such as autogenous auricular cartilage and hard palate mucosal grafts.

CONCLUSIONS

Overall, we can state that the lateral periosteal flap canthoplasty leads to significant improvement of paralytic ectropion. The periosteal flap is a strong, autogenous and easy to harvest anatomic replacement of the deep lateral canthal tendon, which can be reused during a revision procedure. The ESS proved to be a reliable instrument to compare the severity of the ectropion on preoperative and postoperative photographs. Prospective analysis of the lateral periosteal flap canthoplasty would contribute greatly to the evidential value of this study.

Paul M. N. Werker, MD, PhD
 Department Plastic Surgery
 University Medical Center Groningen
 P.O. Box 30.001
 NL-9700 RB Groningen
 The Netherlands
 E-mail: p.m.n.werker@umcg.nl

PATIENT CONSENT

Patients provided written consent for the use of their images.

REFERENCES

1. Goldberg RA. Review of prophylactic lateral canthopexy in lower blepharoplasties. *Arch Facial Plast Surg.* 2003;5:272–275.
2. Anderson RL, Gordy DD. The tarsal strip procedure. *Arch Ophthalmol.* 1979;97:2192–2196.
3. Moe KS, Linder T. The lateral transorbital canthopexy for correction and prevention of ectropion: report of a procedure, grading system, and outcome study. *Arch Facial Plast Surg.* 2000;2:9–15.
4. Bergeron CM, Moe KS. The evaluation and treatment of lower eyelid paralysis. *Facial Plast Surg.* 2008;24:231–241.
5. Whitnall SE. On a tubercle on the malar bone, and on the lateral attachments of the tarsal plates. *J Anat Physiol.* 1911;45(Part 4):426–432.
6. Chang L, Olver J. A useful augmented lateral tarsal strip tarsorrhaphy for paralytic ectropion. *Ophthalmology.* 2006;113:84–91.
7. Carmine A, Stefano C, Cristiano M, et al. Lateral canthoplasty by the Micro-Mitek Anchor System: 10-year review of 96 patients. *J Oral Maxillofac Surg.* 2011;69:1745–1749.
8. Charonis GC, Gossman MD. Involutional entropion repair by posterior lamella tightening and myectomy. *Ophthalm Plast Reconstr Surg.* 1996;12:98–103.
9. Vagefi MR, Anderson RL. The lateral tarsal strip mini-tarsorrhaphy procedure. *Arch Facial Plast Surg.* 2009;11:136–139.
10. Weber PJ, Popp JC, Wulc AE. Refinements of the tarsal strip procedure. *Ophthalmic Surg.* 1991;22:687–691.
11. Smith B. A technic for extirpation and replacement of the lateral canthus. *Trans Am Acad Ophthalmol Otolaryngol.* 1953;57:738–742.
12. Dryden RM, Edelstein JP. Lateral palpebral tendon repair for lower eyelid ectropion. *Ophthalm Plast Reconstr Surg.* 1988;4:115–118.
13. McCord CD, Groessl SA. Lower-lid dynamics: influence on blepharoplasty and management of lower-lid retraction. *Oper Tech Plast Reconstr Surg.* 1998;5:99–108.
14. Chong KK, Goldberg RA. Lateral canthal surgery. *Facial Plast Surg.* 2010;26:193–200.