

# Rescue of Failed XEN-45 Gel Implant by Nd:YAG Shock Wave to Anterior Chamber Tip to Dislodge Hidden Intraluminal Occlusion

Ronald L. Fellman, MD, Davinder S. Grover, MD, MPH,  
Oluwatosin U. Smith, MD, and Helen L. Kornmann, MD, PhD

**Purpose:** The purpose of this study was to inform ophthalmic surgeons in a timely manner of the hidden problem of clear intraluminal cellular debris as a cause for XEN-45 failure and to describe low energy neodymium-doped yttrium aluminum garnet (Nd:YAG) laser revision with periluminal anterior chamber tip shockwave treatment to improve flow to the bleb.

**Patients and Methods:** Six patients with visibly patent stent lumen post XEN-45 surgery. These eyes developed rising intraocular pressure (IOP) with a history of excellent prior bleb formation and were treated successfully with Nd:YAG laser shockwave therapy to disperse assumed intraluminal cellular debris. The laser was aimed just anterior and axial to the intracameral tip of the gel stent through a gonioscopy lens.

**Results:** Six patients with an average age of 75 years (60 to 90 y), preoperative IOP of 30 mm Hg (16 to 52 mm Hg) on an average of 2 antiglaucoma medications (0 to 4) underwent periluminal anterior chamber tip shock wave at an average of 12 months (1 to 38 mo) from XEN-45 surgery. The IOP was immediately reduced to an average of 15 mm Hg (8 to 23 mm Hg) and last IOP averaged 15 mm Hg (10 to 23 mm Hg) on 1.5 medications (0 to 4) at 4 months post periluminal anterior chamber tip shock wave.

**Conclusion:** Nd:YAG laser revision of hidden blockage of a XEN-45 gel implant with periluminal anterior chamber tip shockwave treatment can disperse invisible intraluminal cellular debris and improve flow in a failing XEN-45 microstent, especially when distal fibrosis is not excessive.

**Key Words:** XEN-45 gel stent, intraluminal blockage, occult blockage of XEN-45 microstent, Nd:YAG laser revision, postoperative complication

(*J Glaucoma* 2021;30:e338–e343)

The XEN-45 gel implant<sup>1</sup> (Allergan, Dublin, Ireland) is a microinvasive glaucoma procedure that lowers resistance to outflow by shunting aqueous from the anterior chamber to the subconjunctival space through a microstent. Many glaucoma

surgeons have switched to the XEN-45 instead of standard trabeculectomy because it is a much less invasive method to create a bleb and confers a faster visual recovery. A variant of trabeculectomy, the ExPress glaucoma filtration device (Alcon, Ft Worth, TX) is another modality used to create a filtering bleb, although unlike the XEN-45, conjunctival dissection and a scleral flap are still required. Aqueous flow across a standard trabeculectomy is through the edges of a scleral flap with an underlying sclerostomy and peripheral iridectomy. This methodology differs considerably from the ExPress shunt<sup>2</sup> and XEN-45 gel stent that do not require a peripheral iridectomy, but rather shunt aqueous through a device to form a bleb and are dependent on the patency of a small device lumen for aqueous flow. Another key difference between these 2 devices is that the gel stent has a much greater inherent resistance to outflow compared with the ExPress shunt.

The authors observed a subset of XEN-45 patients with an initial excellent intraocular pressure (IOP) and bleb morphology that failed rather abruptly with decreased flow to the bleb and an associated IOP rise. We suspected in these cases a similar postoperative scenario of hidden intraluminal blockage as published with the ExPress shunt, where postoperative neodymium laser near the device tip lowered IOP.<sup>3</sup> In a subset of our patients, neodymium laser periluminal anterior chamber tip shockwave therapy lowered the IOP in some of our failing XEN-45 cases in spite of the fact that the lumen appeared perfectly patent at the slit-lamp. Moreover, an improved bleb morphology was also noted immediately, confirming re-establishment of flow. Coincidentally, the authors have noted that over the past 18 months, certain eyes with a XEN-45 implant where flow cannot be re-established with a traditional needling procedure can be rescued with neodymium laser treatment.

Dispersal of hidden intraluminal debris within the ExPress shunt by neodymium laser has been described as mentioned by Mustafa. However, this has not been reported in the XEN-45 gel stent literature. The authors assumed that a device is patent when the lumen appears clear of debris for its entire length, but we have learned this is not always the case for some patients with the gel stent. A recent report, which added considerable clarity to our understanding of this clinical scenario, described clear intraluminal cellular debris blocking flow near the proximal portion of the XEN-45 gel stent that was invisible to the examiner at the slit lamp and only seen by histopathologic examination.<sup>4</sup>

Slit-lamp visible obstruction of the XEN-45 tip by blood,<sup>5</sup> iris,<sup>6,7</sup> or fibrin<sup>8</sup> is well reported (Fig. 1A). Invisible intraluminal obstruction, however, is less commonly discussed (Fig. 1B). Theoretically, the cause of intraluminal accumulation of occult cellular debris and its dispersal with laser energy may be similar for both the ExPress shunt and the XEN-45 microstent. The authors speculate that the

Received for publication February 12, 2021; accepted March 13, 2021. From the Glaucoma Associates of Texas, Dallas, TX.

Disclosure: D.S.G.: consultant, speaker and research grants from Allergan. O.U.S.: speaker and consultant for Allergan, an AbbVie Company. The remaining authors declare no conflict of interest.

Reprints: Ronald L. Fellman, MD, Glaucoma Associates of Texas, Dallas, TX 75231 (e-mail: rfellman@glaucomaassociates.com).

Copyright © 2021 The Author(s). Published by Wolters Kluwer Health, Inc. This is an open access article distributed under the terms of the Creative Commons Attribution-Non Commercial-No Derivatives License 4.0 (CCBY-NC-ND), where it is permissible to download and share the work provided it is properly cited. The work cannot be changed in any way or used commercially without permission from the journal.

DOI: 10.1097/IJG.0000000000001847

sudden release of energy near the stent tip generated by the laser propels a shockwave<sup>9</sup> that travels hydrodynamically down the lumen dispersing intraluminal cellular debris that was impeding the flow of aqueous. This potentially may lower IOP when distal subconjunctival fibrosis is not excessive. Although our experience with invisible blockage requires more study, we felt it important to make other surgeons aware of this hidden cause of XEN-45 failure in a timely manner. The purpose of this case series is to further describe the clinical scenario of clear intraluminal obstruction in a failing XEN-45 gel stent and to subsequently describe a laser technique for clearing this debris to re-establish aqueous flow into the subconjunctival space.

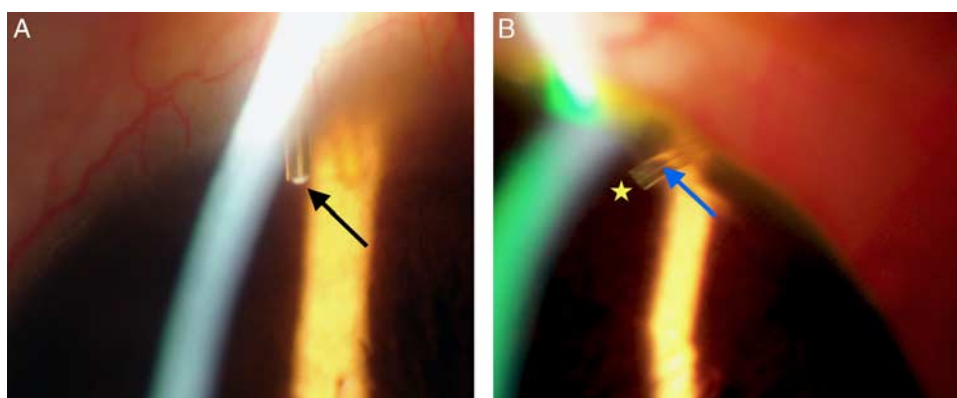
### PATIENTS AND METHODS

Approval was obtained from our institution's central institutional review board. The study was conducted according to the tenets of the Declaration of Helsinki. We identified 6 patients post XEN-45 who underwent successful Nd:YAG shockwave treatment at Glaucoma Associates of Texas between September 2020 and January 2021. The XEN-45 gel stent was done as a standalone procedure or in combination with cataract surgery. Indications for treatment with neodymium laser were at the surgeon's discretion and were consistently in a situation of acute elevated IOP above target level, a shrinking bleb and/or no obvious blockage of the stent in the subconjunctival space. The range of laser energy used was 0.3 to 1.2 mJ and the average number of shots was 8 pulses (range: 8 to 28), or less if a small bubble was seen traveling down the lumen of the tube. In all cases, no debris was detected at the slit lamp obstructing the XEN-45. In the majority of cases, a Gonio lens (MagnaView, Ocular Instruments) was used to align the aiming beam in an axial manner directly anterior to the lumen. The energy was titrated to the point where a small cavitation bubble was produced just anterior to the tip, which usually occurred between 0.4 and 0.8 mJ of energy. A common endpoint was visualization of the cavitation bubble inside the lumen of the stent.

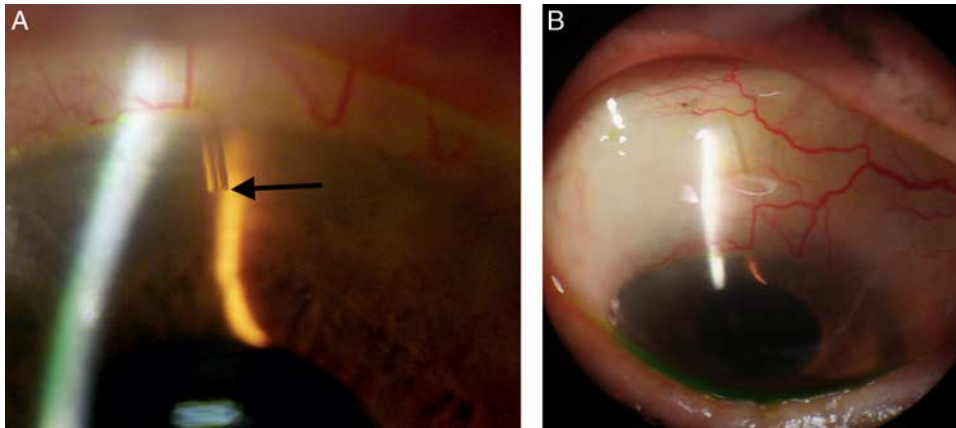
### RESULTS

#### Case 1. Patient With Failed XEN-45 Needling Responsive to PACTS

In mid-August 2019, a 74-year-old Hispanic female with primary open angle glaucoma (POAG) post phacotrabectome oculus dexter (OD) underwent an ab-externo closed conjunctival XEN positioned at 12:30 o'clock with 60  $\mu$ g of mitomycin-C (MMC) under topical anesthesia with 16 mg of inferior sub-Tenons Kenalog. On post operative day (POD) 1, the IOP measured 10 mm Hg OD with a diffuse superior bleb and difluprednate 0.05% and ofloxacin 0.3% was started tid. After 1 week the antibiotic was discontinued. At the 1-month visit, IOP was 10 mm Hg and topical steroid gradually tapered. By the third month, without topical steroid, the IOP rose to 14 mm Hg and fixed combination timolol 0.5%-brimonidine 0.1% (Combigan; Allergan Inc., Irvine, CA) was added followed by travoprost 0.004% with the IOP settling at 10 mm Hg with a diffuse bleb at 4 months. The IOP was stable for several months, but at the postoperative 1-year visit, the IOP rose to 22 mm Hg requiring a bleb needling upon which the IOP decreased only to 19 mm Hg and the surgeon questioned whether flow was re-established through the gel stent. One week after the bleb needling on 2 antiglaucoma medications, the IOP remained at 19 mm Hg. The surgeon then considered whether intraluminal debris was clogging the stent and attempted periluminal anterior chamber tip shock wave (PACTS) treatment. The IOP dropped from 19 to 16 mm Hg along with an immediate improvement in bleb appearance. One month later, the bleb appeared improved and IOP was 12 mm Hg on only travoprost 0.004% qhs and topical steroid twice daily. At 5 months post laser therapy treatment, IOP was 15 mm Hg on travoprost only with a diffuse low bleb confirming aqueous outflow through the stent. In this case, although very difficult to see in the slit lamp photo (Fig. 2A), there was a tiny droplet of whitish material at the anterior chamber tip of the XEN-45. The full extent of this material was only appreciated under high magnification gonioscopy. While this material did not appear to block the lumen, we used the hydrodynamic force



**FIGURE 1.** Contrast the postoperative slit-lamp appearance of visible occlusion of gel stent tip with fibrin plug (A) (not the subject of our series) versus the imperceptible intraluminal cellular debris impeding flow (B) as depicted in our series. A, Obviously visible fibrin plug (black arrow) at tip of XEN-45 easily seen at slit lamp impeding aqueous flow to bleb. This was not the case in any patients in our series. B, Imperceptible clear cellular debris in lumen (blue arrow), invisible to examiner. The XEN-45 appears perfectly patent in every patient in our series. The literature supports histopathologic and imaging evidence of clear cellular debris potentially impeding flow (see manuscript discussion). The yellow star indicates the location of the aiming beam of the neodymium laser used to disperse the intraluminal debris by its shockwave.



**FIGURE 2.** Tiny cellular droplet on tip of XEN (A) and improved flow to bleb 1 week post PACTS (B). A, High magnification of the XEN-45 tip (black arrow) demonstrates a tiny droplet that appears mainly clear. It is difficult to see under the best of circumstances, much less with a slit lamp photograph. However, these tiny tubular deposits may be a clue that cellular debris is depositing in the lumen, even though it appears patent during slit-lamp examination. B, Appearance of bleb 1 week after periluminal anterior chamber tip shockwave treatment. Typically the bleb is slightly more diffuse and usually higher, signs of increased aqueous flow to the bleb. PACTS indicates periluminal anterior chamber tip shock wave.

generated during shockwave treatment and were able to improve flow through the XEN-45 (Fig. 2B).

### Case 2. Impending XEN-45 Failure Rescued With Shockwave Therapy 14 Months Post Gel Stent

In May 2019, a 78-year-old White female with advanced pseudoexfoliation glaucoma on 4 antiglaucoma medications, IOP 16 mm Hg, post phacotrabeculectomy in 2013 underwent an ab-externo closed conjunctival XEN-45, positioned at 1 o'clock with 50  $\mu$ m of MMC OS under topical anesthesia with 16 mg of inferior sub-Tenons Kenalog. On POD 1, the IOP measured 7 mm Hg OS with a diffuse 1+ injected superior bleb and 1+ cells in the AC. Topical prednisolone acetate 1% was started 6 times a day and tapered over 8 weeks and ofloxacin 0.3% was started qid and discontinued at 1 week. The IOP was 10 mm Hg at 1 week and 14 mm Hg at 1-month without antiglaucoma medications. Two months post XEN-45, IOP rose to 17 mm Hg, a different steroid was instituted and tapered over 2 weeks. At 6 months on generic combination timolol 0.5% and dorzolamide 2% qd, the IOP was 12 mm Hg. At 9 months the IOP rose to 23 mm Hg and 1-month later on 4 topical antiglaucoma medications IOP was 16 mm Hg along with a Tenons' cystic bleb appearance. The XEN-45 appeared patent in the anterior chamber; no blockage was seen. Laser shockwave therapy near the gel stent tip was carried out in mid-July 2020, 14 months post XEN-45, on 4 topical glaucoma medications and IOP immediately decreased from 16 to 8 mm Hg along with a marginal increase in bleb circumference but a more dramatic increase in bleb height. Topical steroids were added and slowly tapered, combination generic timolol 0.5% and dorzolamide 2% was continued at qd, and 2 weeks later IOP OS was 12 mm Hg. Two months post laser treatment, IOP was 12 mm Hg and at last follow-up 8 months post laser, IOP was 10 mm Hg on combination timolol/dorzolamide therapy bid.

### Case 3. Laser Shockwave Rescue of XEN-45 During Early Postoperative Course

In early December 2020, a 71-year-old White male with advanced POAG on 3 topical antiglaucoma

medications, IOP 20 mm Hg OS, without prior ocular incisional or laser surgery, underwent a phaco/ab-interno XEN-45 with 70  $\mu$ g of MMC under topical anesthesia with 16 mg of inferior sub-Tenons Kenalog. On POD 1, the IOP measured 17 mm Hg OS with a diffuse 2+ injected superior bleb and 1+ cells in the AC. Topical prednisolone acetate 1% was started 4 times a day along with ofloxacin 0.3% qid. At 1 week the IOP dropped to 6 mm Hg along with an increase in inflammation and steroids were increased to 6 times a day. Two weeks later, the IOP rose to 25 mm Hg associated with bleb shrinkage and laser treatment was performed (3-weeks post XEN-45) with 0.3 mJ, 21 pulses aimed just anterior to the tip. IOP decreased from 25 to 13 mm Hg and stabilized 1 hour later at 18 mm Hg. At 1-month post PACTS, IOP was 11 mm Hg on latanoprost 0.004% and topical steroid bid with a shallow diffuse bleb.

### Case 4. Need for Repeat Rescue Laser Therapy Post XEN-45 in Patient With Pseudoexfoliation Glaucoma

In August 2020, a 90-year-old White female with pseudophakia, advanced pseudoexfoliation glaucoma on 3 antiglaucoma medications, IOP 38 mm Hg, underwent an ab-externo closed conjunctival XEN-45 positioned at 11 o'clock with 80  $\mu$ g of MMC OD under peribulbar anesthesia. On POD 1, the IOP measured 7 mm Hg OD with a diffuse 1+ injected superior bleb and 1+ cells in the AC. Topical prednisolone acetate 1% was started 4 times a day and tapered over 6 weeks. IOP rose to 30 mm Hg at 6 weeks and at 8 weeks a bleb needling was performed and IOP decreased to 17 mm Hg. However, 1-month later IOP increased to 52 mm Hg. 3 months post the original XEN-45 procedure. At this juncture, laser shockwave was performed with 1 mJ of energy and 20 spots. IOP decreased within 15 minutes to 15 mm Hg with visible elevation of the bleb. The patient was stable for 3 months and IOP rose again to 41 mm Hg, again the lumen appeared patent, and a similar laser was repeated with IOP falling to 16 mm Hg and remained at 16 mm Hg at the 1-month visit.

### Case 5. IOP Reduction With Laser Shockwave Therapy 3 Years After Ab Interno XEN-45

In August 2017 a 76-year-old Indian male with advanced POAG on 3 antiglaucoma medications and systemic acetazolamide, IOP 24 mm Hg OS, underwent a second ab interno XEN-45 with 20 µg of MMC under topical anesthesia. On POD 1, the IOP measured 9 mm Hg OS with a well-positioned XEN-45 and a superior diffuse nasal bleb, no wound leak and topical prednisolone acetate 1% was started qid. At 1 week, the IOP was 10 mm Hg, steroid was gradually tapered over 2 months and timolol maleate 0.5% was started once a day. The IOP remained stable OS for 1 year, rose slightly and latanoprost was restarted. The IOP remained between 11 and 15 mm Hg over the next 2 years. The patient presented 3 years after surgery with a 3-day history of increasing blurred vision OS. IOP was 40 mm Hg with reduced bleb size. The patient underwent laser treatment, 6 pulses at 0.8 mJ, with an immediate reduction in IOP down to 14 mm Hg with increase in bleb size. Three days later, on topical steroid only, the IOP was 12 mm Hg. Three months post laser treatment, IOP was 14 mm Hg on timolol 0.5% and topical steroid once a day; the patient had a diffuse low bleb.

### Case 6. Partial IOP Reduction Post Laser Rescue Likely Due to Excessive Distal Fibrosis

In September 2020, a 60-year-old African American male with advanced POAG on 4 topical antiglaucoma medications, IOP 30 mm Hg OD, without prior ocular incisional or laser surgery, underwent a phaco/ab-externo open conjunctival XEN-45 with 60 µg of MMC under peribulbar anesthesia. On POD 1, the IOP measured 8 mm Hg OD with a well-positioned XEN-45 and a superior diffuse bleb, no wound leak and topical prednisolone acetate 1% was started 6 times a day. At the 1-month postoperative visit, the bleb was thicker and still diffuse, but moderately injected and IOP was 32 mm Hg and all 4 glaucoma medications were restarted. At the 2-month visit, IOP was 22 mm Hg and bleb needling reduced IOP to 18 mm Hg. At the 4-month postoperative visit, the IOP was 28 mm Hg and laser treatment was carried out with 12 spots at 0.8 mJ. The IOP decreased to 23 mm Hg and 1 week later was the same. Depending on follow-up IOP, this patient may require further glaucoma surgery. There was a slight increase in bleb function, but overall scarring was thought to be excessive preventing further IOP reduction.

These 6 cases (Table 1), post laser rescue therapy were considered clinically successful demonstrating an improvement in bleb appearance along with a mean preoperative IOP of 30 mm Hg (range: 16 to 52 mm Hg) reduced immediately to 15 mm Hg (range: 8 to 23 mm Hg) and final IOP of 15 mm Hg (range: 10 to 23 mm Hg) at 4 months (range: 1 to 8 mo). A mean of 2 preoperative medications was reduced to 1.5 medications.

## DISCUSSION

Excessive subconjunctival fibrosis is thought to be the most common reason for filtration failure, especially when combined gonioscopy and slit lamp examination show an open sclerostomy as in a trabeculectomy or a patent device lumen as in a XEN-45 gel stent. However, intraluminal blockage also contributes to bleb failure, as described by Mustafa and colleagues who used YAG laser to disrupt occluding material in the ExPress shunt, consequently reestablishing flow through the shunt. The authors suspect a similar cause of clear debris

occlusion for the XEN-45 gel stent as well. With the ExPress shunt, the debris is entirely hidden by the steel casing of the device and the surgeon must assume blockage. The difference in our cases is the surgeon is able to visualize an apparently unobstructed XEN-45 lumen at the slit lamp, but it may actually be clogged with invisible debris. The authors stress this is a critical difference from obviously visible blockage with fibrin or iris or blood, as previously reported (see Fig. 1). Occult blockage is suspected when a sudden rise in IOP occurs in a previously functioning XEN-45 case with a visibly patent lumen or when IOP reduction does not occur after an apparently successful bleb needling. In all of our cases, the XEN-45 device appears perfectly patent throughout its entire length without visible slit lamp evidence of blockage. Proof for occult blockage became readily apparent to us when neodymium laser treatment focused just anterior to the tip of a failing XEN-45 improved flow through the device, similar to the ExPress shunt experience. As mentioned previously by Gillmann, the histopathologic correlation of clear intraluminal debris with an apparently patent stent by slit lamp examination was the defining factor that added clarity to our understanding of this clinical scenario. The mechanism for debris clearance for both devices is likely hydrodynamic energy in the form of a shockwave that travels down the lumen dispersing and clearing invisible intraluminal cellular debris. Even if the obstruction is several millimeters from the anterior tip, the hydrodynamic force from the shockwave may travel several millimeters down the lumen,<sup>10</sup> dispersing debris and reestablishing flow. The physics associated with laser generation of a shockwave is somewhat controversial, but with sufficiently high energy, the expanding plasma drives the shock-wave propagation and cavitation bubble.<sup>11</sup> The hydrodynamic force associated with the shockwave is likely more efficiently propagated down the lumen of the stent with axial alignment from a gonioscopy lens with high magnification and titration of sufficient energy to form a bubble. Oftentimes, this small cavitation bubble is seen traveling down the lumen, a sign that I has re-established flow through the device.

Bleb management after the XEN-45 gel stent is a bit different than classic trabeculectomy. Complications such as bleb failure due to blockage along a narrow artificial lumen may be an issue unique to a stent or shunt compared with the much larger removal of tissue as in a sclerostomy fashioned from native tissue during trabeculectomy. Thus, a different skill set is necessary to care for patients post device related filtration surgery when aqueous must flow through a narrow lumen compared with a much larger sclerostomy as in a trabeculectomy.

The optimal lumen size and length of the XEN-45 gel microstent in a filtering eye has been calculated with formulas based on the physics of flow<sup>12</sup> (Hagen-Poiseuille). However, there may be alterations in these optimal flow principles caused by subconjunctival fibrosis, variable changes in aqueous viscosity and rates of aqueous production, various magnitudes of inherent outflow capacity and an altered blood aqueous barrier related to healing after filtration surgery. Overall, there is likely a complex interplay of these factors, many of which are poorly understood, that may contribute to variable surgical outcomes in all types of filtration surgery. Some of these factors may be more important than others in regard to flow through a lumen. Intraluminal debris that is difficult to see with the slit-lamp has been documented in the XEN-45 gel stent with AS-OCT, which correlates well with our clinical findings.<sup>13</sup>

Most glaucoma surgeons have extensive experience concerning bleb fibrosis as seen during filter revisions. This knowledge is applicable to the XEN-45 experience,

TABLE 1. Summary of PACTS Case Series

Patient	Age (y)	Procedure	DOS	Laser Date	Time From XEN (mo)	Preoperative IOP (mm Hg)	Preoperative Medication	Immediate Postoperative IOP (mm Hg)	Last IOP (mm Hg)	Time From Laser (MO)	Post Gl Med	Prior Ndl-ing	Bleb Appear Post Laser	Prior Surgery
Case 1 F/H POAG (3)	74	XAE OD 60 µg MMC	8/2019	09/2020	13	19	3	16	15	6	1	Y	Moderate improvement	PTome
Case 2 F/C PXF (3)	78	XAE OS 50 µg MMC	5/2019	7/2020	14	16	4	8	10	8	2	N	Moderate improvement	PTrab
Case 3 M/C POAG (3)	71	Phaco-XAI OS 70 µg MMC	12/2020	1/5/2021	1	25	0	13	11	1	1	N	Moderate improvement	None
Case 4 F/C PXF (3)	90	XAE OD 80 µg MMC	8/6/2020	11/16/2020	3 and 6	52 and 41	0	15	16	3	0	Y	Moderate improvement	Phaco
Case 5 M/I POAG (3)	76	XAI (2nd XEN) OS 20 µg MMC	8/2017	10/2020	38	48	1	14	12	3	1	N	Marked improvement	PhacoXEN
Case 6 M/AA POAG (3)	60	Phaco/XAE OD Open-conjunctival 60 µg MMC	9/2020	1/2021	4	28	4	23	23	1	4	Y	Slight improvement	None

C indicates Caucasian; DOS, date of surgery; F, female; Gl, glaucoma medications; H, Hispanic; I, Indian; IOP, intraocular pressure; M, male; MMC, mitomycin-C; MO, months following laser rescue; N, no; Ndl-ing, needling; OD, oculus dexter; PACTS, periluminal anterior chamber tip shock wave; Phaco, phacoemulsification; POAG, primary open angle glaucoma; PTome, phacotrabectome; PTrab, phaco-trabeculectomy; PXF, pseudoexfoliation; XAE, XEN ab-externo; XAI, XEN ab interno; Y, yes.

especially during revisions of failed stents. Importantly, we have seen examples in the operating room where despite successful removal of scar tissue around the distal tip of the device, no flow can be appreciated through the gel stent. In retrospect, it is likely that these stents had intraluminal obstruction, but at the time we were not aware of the potential for this problem. The authors now feel it is essential to rule out intraluminal obstruction before considering surgery unsuccessful.

The method of XEN-45 implantation does not seem to influence the presence of hidden intraluminal debris; thus we consider occult blockage in all gel stent cases. In addition, we now consider periluminal YAG modification of the intracameral portion of the gel stent either before performing a needling procedure or following an unsuccessful needling procedure. Our experience suggests that when the intracameral portion is blocked, one will typically observe a more sudden rise in IOP as opposed to a more gradual rise in IOP which is more classic for subconjunctival filtration failure, although variation is noted.

As initially described by Gillmann, XEN-45 blockage with invisible debris is more common in patients who have a postoperative hyphema after surgery, even when the red blood cells are limited. A hyphema is certainly more common with low IOP in the immediate postoperative period of a XEN-45, especially when the patient has had previous canal surgery of any type, but especially after trabeculotomy or goniotomy. This prior alteration of the blood aqueous barrier may contribute to cellular debris obstructing flow through the microstent; however, we have certainly seen occult blockage in patients without prior canal-based glaucoma surgery. Hidden cellular debris associated with concomitant phacoemulsification may be a factor contributing to XEN-45 failure. Two of our 6 patients had concomitant phacoemulsification and this factor clearly requires further follow-up.

In conclusion, the XEN-45 gel stent allows for one to create a standardized and minimally invasive subconjunctival filtration pathway. Subconjunctival fibrosis is a well-known problem with all types of filtration surgery, prompting the surgeon to constantly visualize the subconjunctival space for bleb contraction and fibrosis. Blockage at the distal end of the gel stent by Tenon's capsule or fibrotic scar tissue is well described, but occult proximal intraluminal obstruction is less well understood. The aim of this report was 2-fold: first, to inform ophthalmic surgeons in a timely manner, of the specific problem of occult intraluminal occlusion as a cause for XEN-45 dysfunction, and second, to describe a technique using low energy neodymium laser treatment near the intracameral tip

portion of the stent to disperse this intraluminal occlusion. It is difficult to ascertain the exact frequency of the accumulation of intraluminal debris because it is hidden and invisible to even the most vigilant observer. Whether this will be a problem with larger lumen micro stents remains to be seen, however, it is likely given that this similar finding has been observed in glaucoma drainage implants and the ExPress shunt. Fortunately, these hidden intraluminal occlusions can be safely and effectively managed in clinic.

## REFERENCES

1. Grover DS, Flynn WJ, Bashford KP, et al. Performance and safety of a new ab interno gelatin stent in refractory glaucoma at 12 months. *Am J Ophthalmol.* 2017;183:25–36.
2. Kanner EM, Netland PA, Sarkisian SR, et al. Ex-PRESS miniature glaucoma device implanted under a scleral flap alone or combined with phacoemulsification and cataract surgery. *J Glaucoma.* 2009;18:488–491.
3. Mustafa M, Shoham-Hazon N, Reiss GR, et al. Neodymium laser treatment of IOP rise following Ex-Press glaucoma device implantation: A retrospective review from 4 institutions. *J Glaucoma.* 2020;29:92–96.
4. Gillmann K, Bravetti GE, Mansouri K. Delayed obstruction of XEN gel stent by cell debris in primary open angle glaucoma: a new insight into the pathophysiology of filtration device failure. *J Curr Glaucoma Pract.* 2019;13:114–115.
5. Ferreira NP, Pinto LA, Marques-Neves C. XEN gel stent internal ostium occlusion: Ab-interno revision. *J Glaucoma.* 2017;26:e150–e152.
6. Olate-Perez A, Perez-Torregrosa V, Serra-Segarra M, et al. Obstruccion proximal del implante XEN: diagnostico y tratamiento [Proximal obstruction of a XEN gel stent: diagnosis and treatment]. *Arch Soc Esp Ophthalmol.* 2108;93:14.
7. Tadrosse AF, Khouri AS. Iridoplasty to treat iris-occluded XEN gel stent. *J Glaucoma.* 2020;29:e91–e92.
8. Gillmann K, Mansouri K, Bravetti GE, et al. Chronic intraocular inflammation as a risk factor for XEN gel stent occlusion: a case of microscopic examination of a fibrin-obstructed xen stent. *J Glaucoma.* 2018;27:739–741.
9. Campanella B, Legnaiolo S, Pagnotta S, et al. Shock waves in laser-induced plasmas. *Atoms.* 2019;57:1–14.
10. Fu L, Wang S, Xin J, et al. Experimental investigation on multiple breakdown in water induced by focused nanosecond laser. *Opt Express.* 2018;26:28560–28575.
11. Pozar T, Petkovsek R. Cavitation induced by shockwave focusing in eye-like experimental configurations. *Biomed Opt Express.* 2020;11:432–447.
12. Sheybani A, Reitsamer H, Ahmed IIK. Fluid dynamics of a novel micro-fistula implant for the surgical treatment of glaucoma. *Invest Ophthalmol Vis Sci.* 2015;56:4789–4795.
13. Rigo J, Castany M, Banderas S, et al. Possible intraluminal obstruction of the XEN45 gel stent observed with anterior segment optical coherence tomography. *J Glaucoma.* 2019;28:1095–1101.